



African Journal of Urology

www.ees.elsevier.com/afju
www.sciencedirect.com



Review

Rare primary retroperitoneal teratoma masquerading as adrenal incidentaloma



J.M. Ratkal^{a,*}, N.J. Shaik^b, D. Salia^b, S.M. Choukimath^a

^a Karnataka Institute of Medical Sciences, Hubli 580024, India

^b Citi Hospital & Research Centre, Hospet, India

Received 1st October 2014; received in revised form 13 November 2014; accepted 16 November 2014

KEYWORDS

Teratomas;
 Retroperitoneal teratomas;
 Adrenal gland;
 Adrenal dermoid;
 Laparoscopic
 adrenalectomy

Abstract

Objectives: To present a rare case of Primary mature cystic teratoma of right adrenal gland in adult female with an aim to review the published literature.

Materials and Methods: The case details of a lady presenting with vague upper abdominal pain and on investigation was found to have a right adrenal mass were collected. The investigations including abdominal CT were suggestive of right adrenal dermoid.

Laparoscopic Adrenalectomy was performed and histopathology confirmed it to be a mature cystic teratoma of adrenal gland.

Discussion: Retroperitoneal mature cystic teratoma are unusual in adults and are mostly secondary tumours and they presenting in adrenal gland is very rare. Primary mature cystic teratoma as an adrenal incidentaloma have been rarely reported. Surgical excision with minimal access has a very good outcome.

Conclusion: Adrenal primary retroperitoneal teratoma is exceedingly rare in adults and carries a definite, though remote risk for malignant transformation. Laparoscopic excision and close follow up are strongly recommended for a good outcome.

© 2015 Pan African Urological Surgeons' Association. Production and hosting by Elsevier B.V. All rights reserved.

Introduction

Primary retroperitoneal teratomas are an uncommon variety of non-seminomatous germ cell tumors. They are made up of well

differentiated parenchymal tissue derived from more than one variety of primary germ cells. These are located in paraxial regions [1], common sites being the gonads (testis and ovaries) followed by extra-gonadal sites such as the intracranial, cervical, mediastinal, retroperitoneal and sacrococcygeal sites [1]. Teratomas are common in children, but their prevalence in adults is exceedingly rare. The adrenal gland is involved in only 4% of primary retroperitoneal teratomas. Herein we report one such case treated laparoscopically at our department and discuss the presenting symptoms, the pathology, diagnosis and surgical management.

* Corresponding author.

E-mail address: jaideeppratkal@gmail.com (J.M. Ratkal).

Peer review under responsibility of Pan African Urological Surgeons' Association.

<http://dx.doi.org/10.1016/j.afju.2014.11.008>

1110-5704/© 2015 Pan African Urological Surgeons' Association. Production and hosting by Elsevier B.V. All rights reserved.

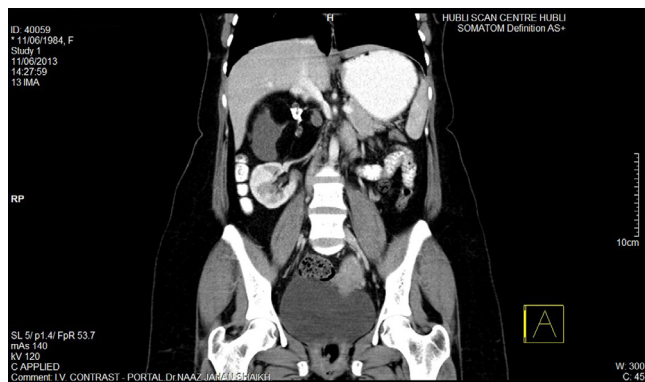


Figure 1 CT scan showing large mixed-density lesion in the right suprarenal area.

Case report

Ultrasound examination of a 29-year-old lady presenting with right flank pain and dysuria revealed a large mixed echogenic mass sized 10 cm in the right suprarenal area. Abdominal computed tomography (CT) further defined it as a large mixed-density lesion of 9–10 cm in diameter, involving the right adrenal gland. It consisted of both cystic and solid elements, showing fat and calcific densities, indicative of an adrenal dermoid (Fig. 1). The right kidney and vena cava were displaced downwards and anteriorly, but with a well-defined plane in between. The biochemical markers used to identify a functioning adrenal tumor, e.g. plasma and urinary metanephrines, urinary 17-ketosteroids and overnight dexamethasone suppression tests, were negative. Laparoscopic adrenalectomy was planned and accomplished with regular port placements. The excised tumor was bagged and removed through a 5 cm suprapubic incision. The specimen measured 10 cm × 5 cm × 6 cm and weighed 130 g (Fig. 2).

The postoperative course was uneventful, and the patient was discharged on the third postoperative day. Histopathology of the tumor revealed a mature teratoma (Fig. 3).

As retroperitoneal teratomas usually are secondary tumors, the abdominal CT and chest X-ray images taken prior to surgery were examined again for evidence of a primary tumor in the ovaries or mediastinum. However, no lesions apart from the adrenal lesion were found, thus confirming the diagnosis of a primary retroperitoneal teratoma.

Discussion

Primary mature teratomas are non-seminomatous germ cell tumors which are made up of well differentiated parenchymal tissue derived from more than one germ cell layer of the developing embryo [1–3]. These tumors involve midline (paraxial) structures with the gonads being the commonest sites. Though frequently found in the pediatric population, the prevalence of such lesions in adults is rare with less than 50 cases reported in the world literature to date. Primary mature teratomas of adrenal origin are exceedingly rare representing 4% of all primary retroperitoneal teratomas [1].

Teratomas arise from uncontrolled proliferation of pluripotent gonadal germ cells and embryonal cells. Teratomas from germ cells

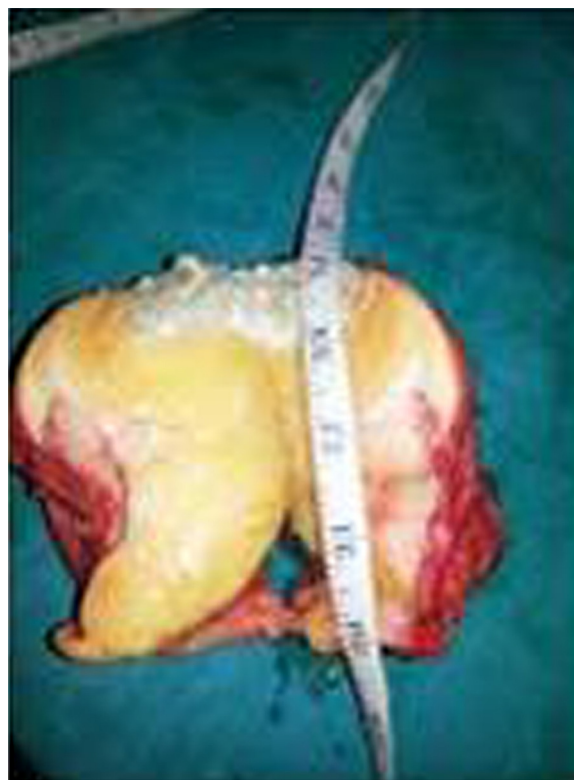

Figure 2 Gross specimen showing calcification.

are usually found in the gonads and are either congenital or acquired, while those from embryonal cells are always congenital and in extragonadal locations [1,4].

According to the location, teratomas can be classified into gonadal and extragonadal teratomas. Gonadal teratomas are commoner; they are mostly primary neoplasms prevailing in adults. Extragonadal teratomas are rare; they are mostly secondary neoplasms rather occurring in the pediatric population. In descending order of frequency, they develop at sacrococcygeal, mediastinal, retroperitoneal and pineal gland sites [5].

Teratomas are also classified into solid, cystic and mixed teratomas according to their consistency. Solid teratomas are mostly parenchymal, while cystic teratomas are like sacs of fluid, semi-fluid or fat. Mixed teratomas contain both.

Furthermore, with regard to the epithelial lining and dermal contents, teratomas, are classified into epidermoid, dermoid and teratoid teratomas. Epidermoid teratomas are lined with stratified squamous epithelium and lack dermal contents, while various dermal contents like hair, sweat and sebaceous glands are found in dermoid teratomas. Teratoid teratomas are lined with respiratory columnar epithelium and contain sebum [4].

Finally, teratomas are also classified into mature and immature teratomas based on the maturation of their tissue constituents. Mature teratomas are benign, commonly found in females and highly variable on histology. Being made up of well differentiated parenchymal tissue, they can be solid, cystic or mixed. Mature cystic teratomas (dermoid cysts) may even consist of partially to completely well-developed organ systems. In contrast, immature teratomas are solid

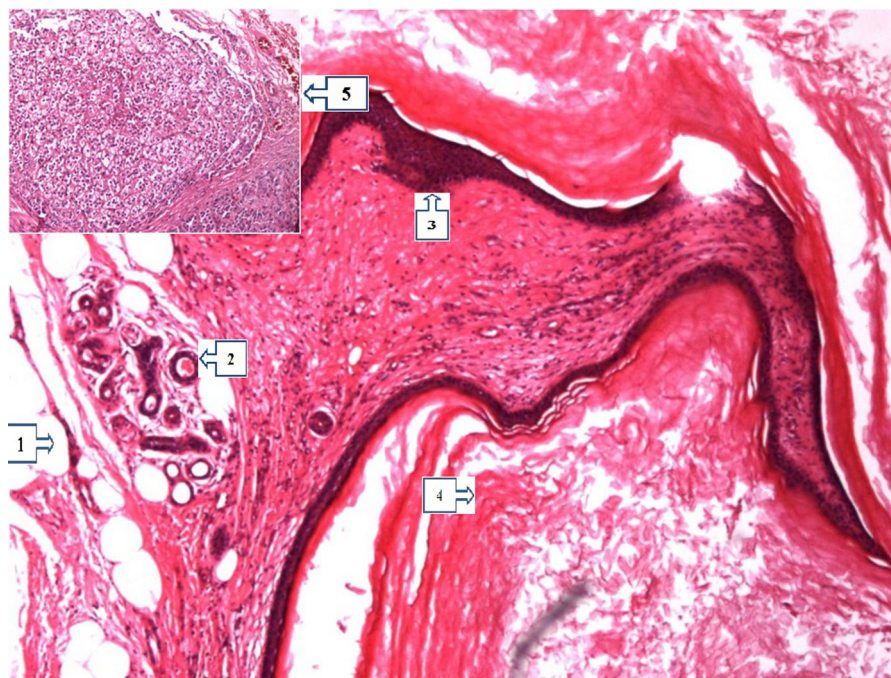


Figure 3 (Histopathology): H&E 40 \times . 1: Fibrofatty tissue; 2: Apocrine glands; 3: Stratified squamous epithelium; 4: Keratin material (sebum); 5: Adrenal gland tissue (inset).

and made up of immature (undifferentiated) parenchymal tissue. They can be possibly benign, possibly malignant or frankly malignant. Any constituent can undergo malignant transformation [8–10].

The majority of retroperitoneal teratomas are secondary neoplasms with male preponderance. Primary retroperitoneal teratomas are extremely rare neoplasms representing 1–11% of all primary retroperitoneal neoplasms, and pediatric age groups are involved the most. Such teratomas rarely occur in adults of the third or fourth decades and are often mistaken for other lipomatous adrenal neoplasms. A male preponderance by a ratio of 1:1.2 is reported in the literature. Location wise, the tumors have a left-side predilection [5,6]. In our case, the tumor arose from the right adrenal of a young adult female.

The majority of retroperitoneal dermoids are asymptomatic, detected incidentally on routine sonography or present with unrelated symptoms like flank pain, dysuria or lower limb/genital swelling due to lymphatic obstruction [7]. Less common presenting symptoms include complications such as secondary infections with abscess formation, traumatic rupture leading to acute peritonitis, or malignant transformations. Teratomas rarely express tumor markers like alfa-fetoprotein, carcinoembryonic antigen and CA 19-9 that may help in following up these patients for recurrence [7].

Several imaging modalities aid in the diagnosis of teratomas, but each has inherent limitations [10]. About 62% of the patients show intralesional or peripheral calcifications within the cyst wall on plain X-ray. 74% of benign lesions show calcifications versus 12.5% of malignant teratomas [11]. Solid, cystic and mixed components can be made out on ultrasound, and the cystic components can further be identified as sebum, nonfat fluid and fetal parts. However, ultrasound findings are limited due to poor identification of fat and calcification which are pathognomonic of teratomas, as reported by Davidson

et al. [10]. CT scan can differentiate between fat, proteinaceous fluid and calcific densities; hence, it delivers more accurate findings than sonography. The presence of fatty portions of the tumor in the horizontal interface with dependent fluid often clinches the diagnosis of a teratoma [12]. CT can also demonstrate the extent of the tumor as well as its relation to the surrounding structures. MRI is superior to both ultrasound and CT as it can accurately define the anatomical relationship between the tumor and the adjacent organs, as well as the local tumor spread. MRI also differentiates the components better and helps in the definitive diagnosis of teratoma [13].

Surgical excision, either by open surgery or by laparoscopy, is the mainstay of treatment and confirms the diagnosis. Laparoscopic or retroperitoneoscopic excision is feasible and offers the advantage of being less morbid and ensuring an early return to work for patients [14–16]. The prognosis is excellent with nearly 100% survival after complete excision.

Regardless of the benign nature of mature teratomas, malignant transformation is a possibility and, therefore, close follow up is required [17]. Our patient is doing well at 6 months of regular follow up.

Conclusion

Adrenal primary retroperitoneal teratoma is exceedingly rare in adults and carries a definite, though remote risk for malignant transformation. Laparoscopic excision and close follow up are strongly recommended for a good outcome.

Conflicts of interest

The authors declare no conflicts of interest.

References

- [1] Bedri S, Erfanian K, Schwaitzberg S, Tischler AS. Mature cystic teratoma involving adrenal gland. *Endocr Pathol* 2002;13(1): 59–64.
- [2] Bahrami SR, Varkarakis IM, Lujan G, Jarrett TW. Primary retroperitoneal teratoma presenting as an adrenal tumour in an adult. *Urology* 2014;69:185e1–2.
- [3] Gatcombe HG, Assikis V, Kooby D. Primary retroperitoneal teratomas: a review of the literature. *J Surg Oncol* 2004;86:107–13.
- [4] Hui JPK, Luk WH, Siu CW, Chan JCS. Teratoma in the region of an adrenal gland in a 77-year-old man. *J Hong Kong Coll Radiol* 2004;7(4):206–9.
- [5] Engel RM, Elkins RC, Fletcher BD. Retroperitoneal teratoma. Review of literature and presentation of an unusual case. *Cancer* 1968;22:1068–73.
- [6] Lambrianides AL, Walker MM, Rosin RD. Primary retroperitoneal teratoma in adults. *Urology* 1987;29:310–2.
- [7] Gupta V, Garg H, Lal A, Vaiphei K, Benerjee S. Retroperitoneum: a rare location of extragonadal germ cell tumor. *Internet J Surg* 2008;17(2) (article 9).
- [8] Bhatti A, Al-Hindi H, Azzam A, Amin T, Abuzaid A. Mature (benign) cystic retroperitoneal teratoma involving the left adrenal gland in a 22-year-old male: a case report and literature review. *Case Rep Oncol Med* 2013;2013:610280.
- [9] Bellin MF, Duron JJ, Curet P, Dion-Voirin E, Grellet J. Primary retroperitoneal teratoma in the adult: correlation of MRI features with CT and pathology. *Magn Reson Imaging* 1991;9(2):263–6.
- [10] Davidson AJ, Hartman DS, Goldman SM. Mature teratoma of the retroperitoneum: radiologic, pathologic and clinical correlation. *Radiology* 1989;172:421–5.
- [11] Bruneton JN, Diard F, Drouillard JP, Sabatier JC, Tavernier JF. Primary retroperitoneal teratoma in adults: presentation of two cases and review of literature. *Radiology* 1980;134:613–6.
- [12] Billmore DF, Grosfeld JJ. Teratoma in childhood, analysis of 142 cases. *J Paediatr Surg* 1986;21:548–51.
- [13] Renato F, Paolo V, Di Girolamo M, Viganò L, Alessandro P, Claudio V, et al. Malignant retroperitoneal teratoma: case report and literature review. *Acta Urol Belg* 1996;64:49–54.
- [14] Chen JC, Khiyami A, McHenry CR. Retroperitoneal cystic teratoma masquerading as an incidentally discovered adrenal mass. *Endocr Pract* 2011;17(5) September–October:e130–4.
- [15] Castillo OA, Vitaglino G, Villetta M, Arellano L, Santis O. Laparoscopic resection of adrenal teratoma. *J Soc Laparosc Surg* 2006;10(4) October–December:522–4.
- [16] Li Y, Zhong Z, Zhao X. Primary mature teratoma presenting as an adrenal tumor in a child. *Urology* 2011;78(3) September:689–91.
- [17] Okulu E, Ener K, Aldemir M, Isik E, Irkkan C, Kayigil O. Primary mature cystic teratoma mimicking an adrenal mass in an adult male patient. *Korean J Urol* 2014;55(2) February:148–51.