



International Journal of Surgery Case Reports

journal homepage: www.casereports.com

A case of a bleeding benign gastrocolic fistula in 2014



Leon Shin-han Winata*, Cherng Huei Kong, Dhan Thiruchelvam

Upper Gastrointestinal Surgery, St Vincent's Hospital, 41 Victoria Parade, Fitzroy, Vic 3065, Australia

ARTICLE INFO

Article history:

Received 20 August 2014

Received in revised form 25 August 2014

Accepted 25 August 2014

Available online 13 October 2014

Keywords:

Endoscopy (digestive system)

Gastric fistula

Melaena

Peptic ulcer disease

ABSTRACT

INTRODUCTION: In the era of proton pump inhibitors in the treatment of peptic ulcer disease, the incidence of a gastrocolic fistula arising from unoperated gastric ulcers is extremely low.**PRESENTATION OF CASE:** We present the case of a 68-year old farmer who presented with melaena and was found to have a benign gastrocolic fistula in the setting of untreated peptic ulcer disease, chronic NSAID ingestion and heavy alcohol intake. The diagnosis was made by gastroscopy. En bloc surgery was undertaken due to the size of the fistula and concomitant significant bleeding of the ulcer which would not have made it amenable to medical management.**DISCUSSION:** The symptoms of a gastrocolic fistula are undifferentiated and the diagnosis can easily be missed in the setting of other complications such as bleeding or perforation of a hollow viscus. Barium enemas are the most accurate for the diagnosis but gastroscopy with biopsy is usually performed to rule out malignancy. The mainstay of treatment is usually surgical, though patients can be medically managed if he/she is not a surgical candidate.**CONCLUSION:** Benign gastrocolic fistulas are rare and its diagnosis is easily missed.© 2014 The Authors. Published by Elsevier Ltd. on behalf of Surgical Associates Ltd. This is an open access article under the CC BY-NC-ND license (<http://creativecommons.org/licenses/by-nc-nd/3.0/>).

1. Introduction

In the era of proton pump inhibitors in the treatment of peptic ulcer disease, the incidence of a gastrocolic fistula arising from unoperated gastric ulcers is extremely low. We present a case of this complication diagnosed on gastroscopy, followed by a discussion on the diagnosis and treatment of this condition in the current literature.

2. Presentation of case

A 68-year old farmer presented to a regional hospital with a syncopal episode and two weeks of melaena and intermittent epigastric pain in the setting of chronic heavy alcohol consumption and ibuprofen use. Initial gastroscopy revealed a large clot overlying a benign looking ulcer. Gastric washout was performed and haemostasis was obtained with adrenaline injection around the base of ulcer. In light of a falling haemoglobin level and hypotension, the patient was transfused with two units of blood and transferred to our tertiary referral centre. On arrival he was clinically stable but required further transfusions as his haemoglobin continued to drop. Repeat gastroscopy revealed a large gastrocolic

fistula adjacent to the ulcer (Fig. 1). This would have been difficult to see at the first scope due to the distortion of the normal gastric anatomy and the position of the ulcer. The gastroscope was just able to pass through the fistula into the colon (Fig. 2). Biopsy of the ulcer edge showed Helicobacter associated chronic active gastritis associated with regenerative changes.

Further history revealed he had similar episodes of epigastric pain over the last four years, for which he had received no treatment. In the last two weeks preceding admission to the hospital, his symptoms had progressed to persistent diarrhoea, intermittent melaena and occasional foul eructations, with an associated weight loss of six kilograms over the past three months. He drank eight bottles of beer daily on at least three occasions a week. He had also been consuming a large amount of ibuprofen over the last 6 months due to a work-related back injury.

Due to his symptoms of bleeding and malnutrition and the size of the gastrocolic fistula, an en bloc resection of the fistula (Billroth II resection and right hemicolectomy) was performed (Fig. 3). He recovered well and was discharged on day 12 post-op.

This case highlights a few points pertinent to the discussion of gastrocolic fistulae associated with benign gastric ulcers.

3. Discussion

Historically, the most common causes of gastrocolic fistulae were colon or gastric malignancies and complications arising from

* Corresponding author. Tel.: +61 03 9288 2211; fax: +61 03 9288 2091.

E-mail addresses: Shinhanwinata@gmail.com, Shin-hanleon.winata@svhm.org.au (L.S.-h. Winata).

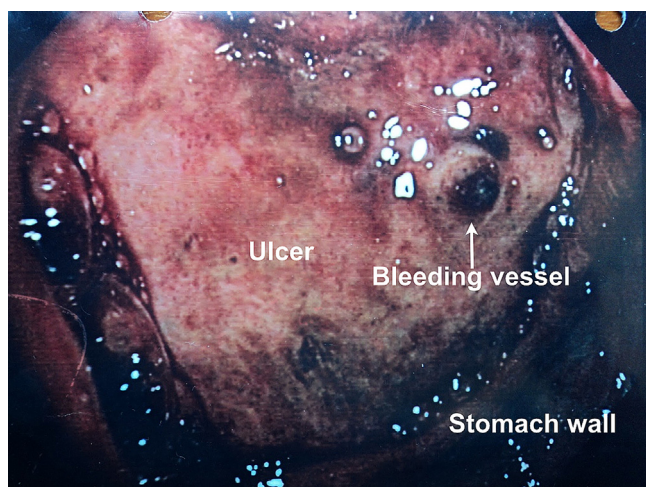


Fig. 1. Gastroscopic view of the bleeding ulcer in the stomach. The fistula has been obstructed from view due to the distortion of the stomach caused by the ulcer.

partial gastrectomy and gastroenterostomy.¹ Gastrocolic fistulas arising from unoperated benign gastric ulcers are rare but well documented. From 1920 when the first case was described to the present, only 120 cases have been documented in the English literature.² The ingestion of NSAIDs or steroids was found to be associated with the development of the fistula in the majority of these patients,^{3,4} as is the case for our patient.

The symptoms of a gastrocolic fistula are undifferentiated and the diagnosis can easily be missed in the setting of other complications such as bleeding or perforation of a hollow viscus.³ The classic triad of weight loss, faecal vomiting and diarrhoea is often quoted but inconsistently observed.⁴⁻⁷ Studies have shown that bleeding in the form of melaena or haematemesis was noted in approximately one third of patients.³

Barium enemas are the most accurate modality in making the diagnosis, with most studies suggesting close to a 100% detection rate.^{6,8} Gastroscopies had a more varied detection rate, with studies quoting a range of 30–70%.^{3,9} However, gastroscopy with biopsy is always recommended after a radiological diagnosis to confirm the presence or absence of malignancy.⁷ In our patient, the ulcer was so large that it had distorted the normal anatomy of the stomach,

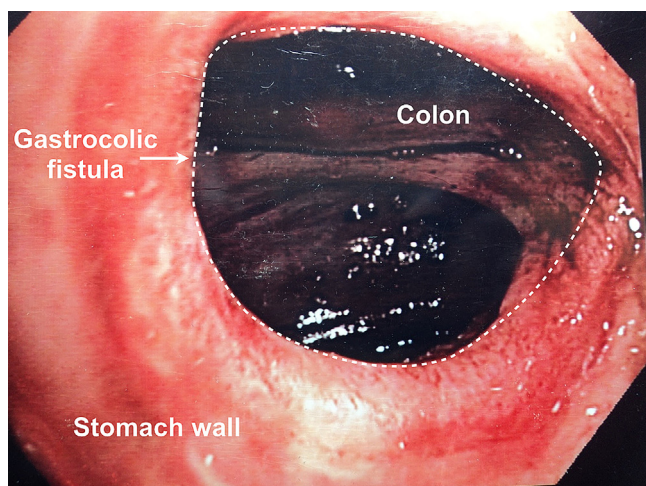


Fig. 2. Gastroscopic view of the colon as viewed through the gastrocolic fistula from the stomach.

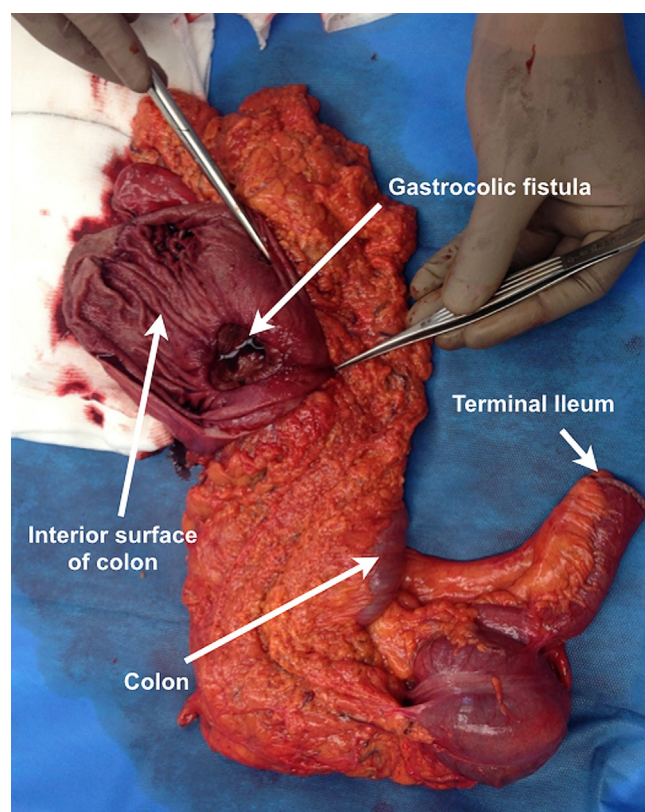


Fig. 3. Image of the gross surgical specimen, showing the fistula as viewed from the lumen of the colon.

thus resulting in the difficulty of detecting the gastrocolic fistula on the initial gastroscopy.

The mainstay treatment of gastrocolic fistulae has classically been surgery, consisting of a distal gastrectomy with hemicolectomy.¹⁰ En-bloc resection of the fistula with primary gastrointestinal reconstruction is recommended as opposed to local fistula resection due to the decreased incidence of recurrence.⁸ Due to the nutritionally depleted status these patients usually present in, there is also a role for pre-operative optimization of nutrition status, with several centres advocating peri-operative nutritional support with TPN and bowel rest.^{2,7}

Recently, reports of successful non-surgical management of gastrocolic fistulas related to NSAID related gastric ulcers have emerged.¹⁰ This consists of ceasing the use of NSAIDs or steroids and commencing a H2-antagonist, with consideration made for TPN.⁸ Successful closure of the fistula was noted, and no recurrences occurred in the short term. This was recommended for patients who were not fit or keen for surgery.² This patient was young and had little comorbidity, and in light of the severity of his bleeding, as well as the size of the fistula, surgery was performed.

4. Conclusion

In the era of proton pump inhibitor use, this complication of peptic ulcer disease is very rare. This case highlights the difficulty of diagnosing a gastrocolic fistula, and how it can be easily missed in the setting of massive gastric bleeding.

Conflict of interest

Nothing to declare.

Funding

No funding required for research.

Ethical approval

Nothing to declare, no research studies performed.

Author contributions

Mr Thiruchelvam and Dr Kong performed the gastroscopy and subsequent surgery. Dr Winata assisted in the surgery and completed the literature review of the topic.

Key learning points

- The symptoms of gastrocolic fistulae are often undifferentiated.
- Barium enemas are the most accurate for diagnosis but gastroscopy should be performed to rule out malignancy.
- The mainstay of treatment of gastrocolic fistulae is surgical.

Acknowledgements

We would like to thank the patient for agreeing to have this care report published. We would also like to thank the surgical team at St Vincent's Hospital for the post-operative care of this patient.

References

1. Tavenor T, Smith S, Sullivan S. Gastrocolic fistula: a review of 15 cases and an update of the literature. *J Clin Gastroenterol* 1993;**16**:189–91.
2. Shaik AS, Singh B, Haffejee AA. Gastrocolic fistula as a complication of benign gastric ulcer. *S Afr Med J* 1999;**89**:1011–4.
3. Soybel DI, Kestenberg A, Brunt EM, Becker JM. Gastrocolic fistula as a complication of benign gastric ulcer: report of four cases and update of the literature. *Br J Surg* 1989;**76**:1298–300.
4. Levine MS, Kelly MR, Laufer I, Rubesin SE, Herlinger H. Gastrocolic fistulas: the increasing role of aspirin. *Radiology* 1993;**187**:359–61.
5. Barrett K, Hii MW, Cade RJ. Benign gastro-colic fistula in a woman presenting with weight loss and intermittent vomiting: a case report. *J Med Case Rep* 2011;**5**:313.
6. Stamatakos M, Karaiskos I, Pateras I, Alexiou I, Stefanaki C, Kontzoglou K. Gastrocolic fistulae: from Hellar till nowadays. *Int J Surg* 2012;**10**:129–33.
7. Thyssen EP, Weinstock LB, Balfe DM, Shatz BA. Medical treatment of benign gastrocolic fistula. *Ann Intern Med* 1993;**118**:433–5.
8. Cody JH, DiVincenti FC, Cowick DR, Mahanes JR. Gastrocolic and gastrojejuno-colic fistulae: a report of twelve cases and review of the literature. *Ann Surg* 1975;**181**:376–80.
9. Casey J, Lorenzo G. Gastrocolic fistula. *J Natl Med Assoc* 1986;**78**:330–2.
10. Iwasaki Y, Jubota K, Shimoda M, Ishikawa K, Satoh N. Formation of gastrocolic fistula during treatment for peptic ulcer. *Dig Endosc* 2009;**21**:208–10.

Open Access

This article is published Open Access at scimedirect.com. It is distributed under the [IJSCR Supplemental terms and conditions](#), which permits unrestricted non commercial use, distribution, and reproduction in any medium, provided the original authors and source are credited.