

PAPP-A with that of a cardiospecific troponin assay were considered eligible for meta-analysis. Potential discrepancies between authors were solved by CM.

Five studies, totalling 2050 patients (1333 cases and 717 controls), met our inclusion criteria (I-squared heterogeneity, 82%).^{1,3–6} Interestingly, the cumulative AUC for troponin alone was marginally but still significantly higher (0.85; 95% CI, 0.78–0.92) than that of PAPP-A alone (0.67; 95% CI, 0.54–0.80; $p = 0.03$) (Fig. 1). Pooled data about sensitivity and specificity could not be calculated, since these were not provided in all studies. In the only one study comparing troponin alone with the combination of troponin and PAPP-A, the AUC obtained with the two biomarker approach was marginally but not significantly improved (i.e., 0.955 versus 0.952; $p = 0.42$).⁶

Taken together, the results of this meta-analysis including 2050 patients with ischemic heart disease suggest that PAPP-A may not be useful in the early diagnosis of AMI as a stand alone test, whereas further studies should be planned to establish its diagnostic accuracy in combination with a cardiospecific troponin immunoassay.

REFERENCES

1. Gururajan P, Gurumurthy P, Nayar P, et al. Pregnancy associated plasma protein-A (PAPP-A) as an early marker for the diagnosis of acute coronary syndrome. *Indian Heart J.* 2012;64:141–145.
2. Bayes-Genis A, Conover CA, Overgaard MT, et al. Pregnancy-associated plasma protein A as a marker of acute coronary syndromes. *N Engl J Med.* 2001 Oct 4;345(14):1022–1029.

3. Khan DA, Sharif MS, Khan FA. Diagnostic performance of high-sensitivity troponin T, myeloperoxidase, and pregnancy-associated plasma protein A assays for triage of patients with acute myocardial infarction. *Korean J Lab Med.* 2011;31:172–178.
4. McCann CJ, Glover BM, Menown IB, et al. Novel biomarkers in early diagnosis of acute myocardial infarction compared with cardiac troponin T. *Eur Heart J.* 2008;29:2843–2850.
5. Body R, Pemberton P, Ali F, et al. Low soluble P-selectin may facilitate early exclusion of acute myocardial infarction. *Clin Chim Acta.* 2011;412:614–618.
6. Schaub N, Reichlin T, Meune C, et al. Markers of plaque instability in the early diagnosis and risk stratification of acute myocardial infarction. *Clin Chem.* 2012;58:246–256.

Giuseppe Lippi*

Unità Operativa Diagnostica Ematochimica,
Dipartimento di Patologia e Medicina di Laboratorio, Azienda
Ospedaliero-Universitaria di Parma, Via Gramsci,
14, 43126 Parma, Italy

Camilla Mattiuzzi

Servizio Governance Clinica, Ospedale di Trento, Italy

Gianfranco Cervellin

Unità Operativa Pronto Soccorso e Medicina d'Urgenza,
Azienda Ospedaliero-Universitaria di Parma, Italy

*Corresponding author. Tel.: +39 0521 703050, +39 0521 703197.

E-mail addresses: glippi@ao.pr.it, ulippi@tin.it,
giuseppe.lippi@univr.it

Rejoinder

To the Editor,

We have read with interest the letter written by Dr. Giuseppe Lippi about our article on “Pregnancy-associated plasma protein A (PAPP-A)”. Dr. Lippi has concluded that PAPP-A alone cannot be used as a marker for diagnosis of acute MI and it has to be used in combination with troponin and we have also concluded the same. Area Under the time concentration Curve (AUC) for discrimination between ischemic and non-

ischemic subsets improved only when PAPP-A was used in combination with troponin and CK-MB.

Prema Gurumurthy

Director – Academics, FLL Hospital and
Dr K M Cherian Heart Foundation, India
E-mail address: prema.fll@gmail.com

DOI of original article: <http://dx.doi.org/10.1016/j.ihj.2012.10.005>

Successful Medtronic Champion 8072 pacemaker pulse generator destructive-replacement for lead-pin/lead-port clip aperture misalignment

Medtronic introduced low-cost Champion VVI pacing devices for use in countries such as India a few years ago and were subsequently withdrawn. These devices are still being encountered when patients with devices present themselves for battery replacement. Figures 1 and 2 show the method of finger pressure application over the implantable pulse generator (IPG) header in order to align the pair of apertures for correct lead-pin insertion or removal and Figure 3 depicts

a correctly engaged lead-pin. Although very simple in design we describe a problem faced at pacemaker IPG replacement due to lead-pin misalignment in the lead-port.

A 52-year-old patient implanted with such a VVI pacemaker (Model no, 8079, SN PGE005827C) in 2003 was found to have a stuck lead-pin in the IPG lead-port due to misalignment with the second (deeper) of the two holes present in the self-retaining spring clip of the lead-port at IPG

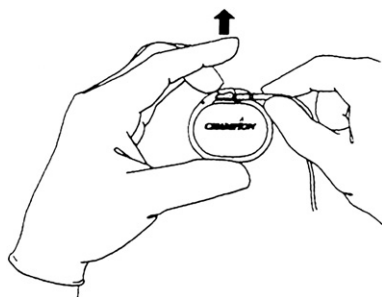


Fig. 1 – The lead-tip holder spring clip releasing method. Line diagrams from the Medtronic Champion pacemaker User’s manual, © Medtronic, Inc.

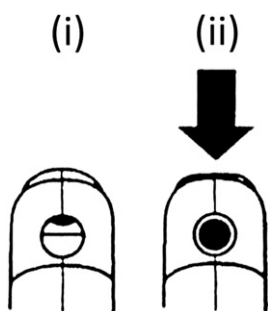


Fig. 2 – An end-on view of the lead-tip port with (i) closed position and (ii) black arrow marking open or aligned apertures. Line diagrams from the Medtronic Champion pacemaker User’s manual, © Medtronic, Inc.

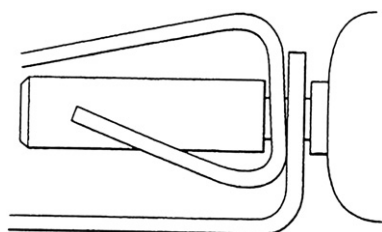


Fig. 3 – A properly positioned lead-tip in profile view. Line diagrams from the Medtronic Champion pacemaker User’s manual, © Medtronic, Inc.




Fig. 4 – Explanted IPG with a demonstration lead positioned in the lead-tip holder clip and the separated header remnant. Inset shows a close-up of the misaligned lead-tip.

replacement for battery depletion. This could be visualized through the semi-transparent header material. Tearing away the soft header material exposed the apposing jaws inside the clip for forcing them apart and freeing the lead-pin without undue traction on the lead thus preserving the lead integrity for connection to a new Medtronic Relia VVI IPG. Figure 4 demonstrates the lead-pin misalignment described above. Any attempt at trying to force the lead-pin out by traction on the lead body itself could have resulted in significant inadvertent damage to the lead insulation or the conductor. Identifying this problem would be all the more important in a pacemaker dependent patient since a damaged lead could result in abrupt loss of ability to pace using that lead.

To our knowledge, destructive removal of depleted Champion IPG in order to protect the lead from damage in patients with misaligned lead-tip/lead-port clip apertures has not been reported and being aware of this possibility helps avoid an unnecessary new lead insertion.

David Chase

Assistant Professor, Department of Cardiology,
Pacing and Electrophysiology Service,
Christian Medical College Hospital, Vellore, Tamilnadu, India
E-mail address: davsuchi@gmail.com