

Mitral Valve Surgery in Advanced Heart Failure

Thomas G. Di Salvo, MD, MPH, MBA,* Michael A. Acker, MD,† G. William Dec, MD,‡
John G. Byrne, MD*

Nashville, Tennessee; Philadelphia, Pennsylvania; and Boston, Massachusetts

The appropriateness and timing of mitral valve surgery in patients with advanced heart failure and severe mitral regurgitation remains controversial. Recent surgical results provide evidence for beneficial effects on left ventricular remodeling and functional capacity. Given the absence of randomized trials comparing the outcomes of mitral valve surgery to medical therapy, however, clinical decision making regarding surgery for these fragile patients poses a dilemma to thoughtful clinicians. This paper reviews the pathophysiology of mitral regurgitation in heart failure and proposes an integrated approach to management. (J Am Coll Cardiol 2010;55:271-82)

© 2010 by the American College of Cardiology Foundation

The appropriateness of mitral valve (MV) surgery for patients with severe mitral regurgitation (MR) and advanced heart failure (HF) remains embroiled in controversy (1). Proponents and skeptics both have highlighted unresolved issues including the approach to “functional” MR (2-5), the benefit of repair of moderate ischemic MR in patients undergoing coronary artery bypass grafting (6,7), mitral valve repair (MVR) versus MV replacement (6), and the long-term outcomes of surgery for functional MR compared with medical therapy (8,9). Until the Cardiac Surgical Clinical Trials Network reports the results of ongoing randomized, prospective trials (10), clinical decision making devolves to existing observational series and anecdotal experience.

This paper reviews salient aspects of MR pathophysiology and the experience in MV surgery in advanced HF. It concludes with a suggested approach to the management of this challenging patient group.

Importance of MR in HF

Significant MR occurs in 30% of patients with myocardial infarction (11) and in 35% to 50% of patients with chronic HF (12). Observational studies report an approximately twofold increase in mortality with significant MR with perhaps a lesser contribution in patients with advanced HF (7,13). Increasing MR is associated with proportionally increasing mortality among patients with chronic HF (5). The presence of MR doubles mortality in patients after

post-myocardial infarction and decreases survival in graded fashion in patients undergoing PCI (14).

Definition of severity. Severe MR corresponds to >50% of total left ventricular (LV) stroke volume (the regurgitant fraction) ejected into the left atrium through the regurgitant orifice (Table 1) (15). Moderate and mild degrees of MR correspond to regurgitant fractions of 30% to 50% and <30%, respectively. Flow through the regurgitant orifice area depends on the orifice area, the square root of the pressure gradient between the left ventricle and the left atrium, the duration of systolic flow, and a derived “discharge” coefficient. The regurgitant orifice area may be dynamic in response to developed LV pressure, LV end-diastolic volume, and LV geometry (11). For example, MR is less during midsystole, when maximal LV closing forces occasion greater MV coaptation than during the early and late phases of systole.

Normal MV Function

Normal MV function depends on the structural integrity and coordinated action of the 6 anatomic components of the mitral apparatus (Fig. 1): the MV annulus, anterior and posterior mitral leaflets, chordae tendinae, anterolateral and posteromedial papillary muscles, subtending myocardium at the insertion of papillary muscles, and overall ventricular geometry. The MV leaflet closure at the normal coaptation sites depends on the various forces that act upon these components: annular contraction, leaflet tethering forces transduced via the chordae, papillary muscles, and subtending myocardium, and the “closing forces” transduced by LV contraction. As stated by Levine and Schwammenthal (11), the “equilibrium” of the mitral leaflets in normal “closed” position throughout systole is determined by the balance of these forces acting upon these anatomic components.

From *Vanderbilt University, Nashville, Tennessee; †University of Pennsylvania, Philadelphia, Pennsylvania; and ‡Massachusetts General Hospital, Boston, Massachusetts. Dr. Acker is a consultant with Acorn Cardiovascular.

Manuscript received February 27, 2009; revised manuscript received August 7, 2009, accepted August 10, 2009.

Abbreviations and Acronyms

- CABG** = coronary artery bypass graft surgery
- CRT** = cardiac resynchronization therapy
- HF** = heart failure
- LV** = left ventricular
- LVEDD** = left ventricular end-diastolic diameter
- LVEF** = left ventricular ejection fraction
- MR** = mitral regurgitation
- MRI** = magnetic resonance imaging
- MV** = mitral valve
- MVA** = mitral valve annuloplasty
- MVR** = mitral valve repair
- NHBLI** = National Heart, Lung, and Blood Institute
- NYHA** = New York Heart Association

Features of normal anatomy and function are worth additional brief comment. The posterior one-third of the mitral annulus is contractile, and provides an important “cincturing” of the annulus during systole. The cross-sectional tissue area of the mitral leaflets is approximately twice that required to span the normal annulus orifice—thus, limited “redundancy” exists assuming normal annular dimensions. Although preservation of chordal continuity is important for overall ventricular function, selective transection of basal chordae may not be associated with ventricular dysfunction and provides partial leaflet untethering (16).

Pathophysiology of MR

MR may result from structural or functional abnormalities of the components of the mitral apparatus and/or the forces that act upon them (Fig. 1). In the absence of intrinsic abnormalities of the tissue composition or anatomy of the MV apparatus, ventricular remodeling accounts for most instances of severe MR (2,11). Because progressive ventricular remodeling also results from chronic volume overload in severe MR (17,18), significant MR begets progressive ventricular remodeling, which in turn begets progressive MR (17).

Several authors have emphasized that in patients with advanced LV remodeling and HF, severe MR represents a “ventricular disease” masquerading as a valvular disease (2,11). This realization poses a critical and challenging management issue. Although relief of MR unloads the left ventricle, if the stage of LV adverse remodeling is irreversible, MR correction may not provide significant benefit. It is critical, therefore, to undertake MV surgery only for patients in whom some cardiac plasticity (19) or “reverse remodeling viability” yet remains. As discussed in the following text, it has proven difficult with existing diagnostic tools to conclude which ventricles possess reverse remodeling viability.

Several authors have emphasized that in patients with advanced LV remodeling and HF, severe MR represents a “ventricular disease” masquerading as a valvular disease (2,11). This realization poses a critical and challenging management issue. Although relief of MR unloads the left ventricle, if the stage of LV adverse remodeling is irreversible, MR correction may not provide significant benefit. It is critical, therefore, to undertake MV surgery only for patients in whom some cardiac plasticity (19) or “reverse remodeling viability” yet remains. As discussed in the following text, it has proven difficult with existing diagnostic tools to conclude which ventricles possess reverse remodeling viability.

Etiology of MR

Nonischemic MR. “Functional” MR results primarily from tethering of the MV leaflets due to ventricular remodeling, specifically, increased LV dilation and sphericity (11). Contractile dysfunction alone in the absence of ventricular dilation or increased sphericity does not result in significant MR (20). Ventricular dilation and increased sphericity affect papillary muscle displacement and a relative lateral redirection of the tethering forces normally perpendicular to the

mitral annular plane. This redirection of tethering forces results in incomplete leaflet coaptation.

In ventricular dysfunction, tethering length (the distance from papillary muscle tips to anterior mitral annulus) is the only independent predictor of MR (20). Increased LV sphericity also results in greater MR (21,22). Annular dilation and reduced closing forces primarily “modify” tethering, but are not the predominant mechanisms of MR (11). In the chronically volume overloaded ventricle, constitutive increases in LV wall stress eventually effect a decrease in contractility (23) and a corresponding reduction in the annular and closing forces that may otherwise lessen MR due to tethering alone.

Ischemic MR. In animal models, papillary muscle ischemia alone does not result in significant MR (24). Although controversial, the most important mechanism of ischemic MR is likely MV leaflet tethering due to post-infarction remodeling induced displacement of the papillary muscles (25). This most commonly occurs with posterior displacement of the posteromedial papillary muscle in inferior or posterior transmural infarctions. Annular dilation and reduced closing forces due to reduced contractility also likely play lesser, primarily “modifying” roles in ischemic MR (11).

Ventricular remodeling. Chronic severe MR incurs increased ventricular wall stress due to increased diastolic loading (15). The left ventricle adapts during a typically long compensated state marked by eccentric ventricular hypertrophy and enhanced ventricular compliance. Synthesis of increased sarcomeres in series effects eccentric hypertrophy. Such “elongated” myocytes preserve ventricular compliance and accommodate increased pre-load with preservation of pre-load recruitable reserve.

After a variable period of time (as little as 2 to 4 months in animal models but probably longer in humans), the left ventricle progresses through this transitional stage to a chronically decompensated stage (2). During this transitional stage, several lines of evidence demonstrate alterations in myocyte and extracellular matrix biology demarking the physiological adaptive limits of eccentric hypertrophy (15). Myocardial gene expression shifts from a compensatory hypertrophic paradigm to a fibrotic and apoptotic paradigm (17,26). In the chronically decompensated state in animal models, significant myocyte “drop-out” with hypertrophy of surviving myocytes and increased interstitial fibrosis occur (Fig. 2) (23). Although the determinants of progressive ventricular contractile dysfunction and noncompliance are more complex than simply myocyte drop-out and matrix

Table 1 Mitral Regurgitation Severity by Echocardiography

Echo Parameter	Mild	Moderate	Severe
Vena contracta width (cm)	<0.3	0.3–0.69	≥0.7
Regurgitant volume (ml/beat)	<30	30–59	≥60
Regurgitant fraction (%)	<30	30–49	≥50
Effective regurgitant orifice area (cm ²)	<0.2	0.2–0.39	≥0.40

Reprinted with permission from Mehra et al. (5).

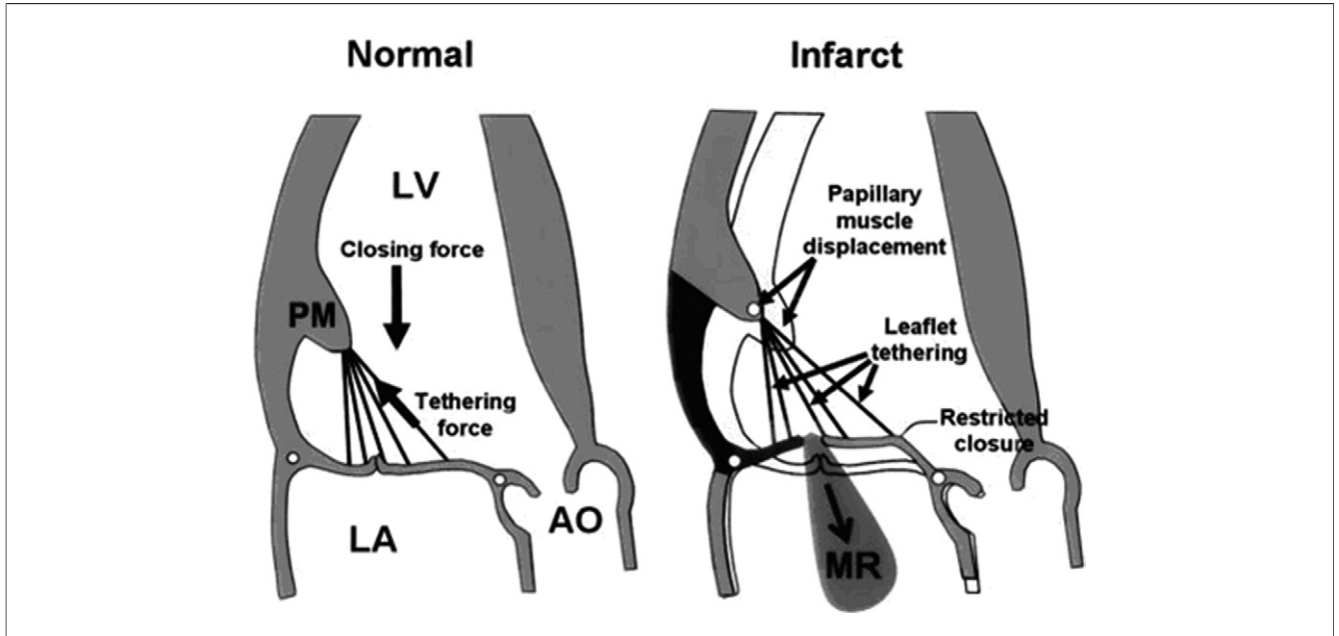


Figure 1 Mechanisms of MR

(Left) Balance of forces acting on mitral leaflets in systole. (Right) Effect of papillary muscle (PM) displacement. Dark shading indicates inferobasal myocardial infarction; light shading indicates normal baseline. Reprinted with permission from Levine and Schwammenthal (11). AO = aorta; LA = left atrium; LV = left ventricle; MR = mitral regurgitation.

fibrosis, eventually a terminally remodeled, hypocontractile, noncompliant ventricle evolves.

Therapeutic Options

Medical therapies. To the extent that medical therapies affect reserve geometric remodeling (reduction in LV dilata-

tion or sphericity), they should restore proportionally the normally perpendicular orientation of the papillary muscles to the annulus and thereby reduce MR. By reducing LV load, various intravenous and oral vasodilators (nitroprusside, angiotensin-converting enzyme inhibitors, hydralazine, and isosorbide dinitrate) in concert with loop diuret-

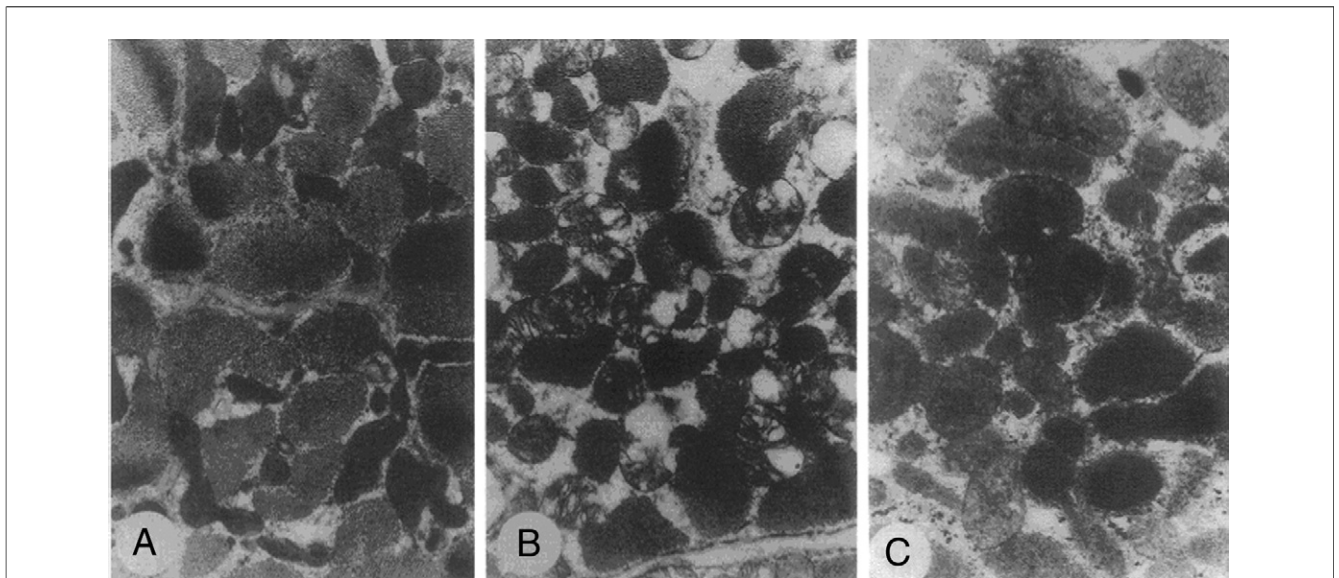


Figure 2 Histological Changes in a Canine Model of Chronic Severe Mitral Regurgitation

Reprinted with permission from Carabello *et al.* (23).

ics may, in selected patients, reduce MR by as much as 1 to 2 echocardiographic grades (27,28) and substantially reduce vena contracta width (29).

The antiapoptotic and fibrosis inhibition effects of neurohormonal antagonists (angiotensin-converting enzyme inhibitors, angiotensin receptor-blockers, beta-blockers, aldosterone antagonists) have been well described for chronic HF. There is only modest evidence to date that renin-angiotensin system inhibition provides substantial benefit beyond vasodilation per se in severe MR (2,5). There are compelling experimental and human data, however, that beta-adrenergic blockade attenuates LV remodeling in chronic severe MR. Atenolol attenuates the increase in LV mass, lowers LV filling pressures, improves contractile performance in both the intact heart and isolated cardiomyocytes, increases myofibril cell content, and improves myocardial histology in a canine model of severe MR (Fig. 2) (30). Carvedilol reduces the MR ratio (MR jet area/left atrium area) by $\approx 20\%$ via reverse remodeling (31). There is as yet no conclusive evidence that neurohormonal antagonists specifically improve clinical outcomes once severe ventricular dysfunction ensues.

Positive intravenous inotropes reduce MR. In an echocardiographic series, 61% of patients with LV ejection fraction $< 50\%$ had improvement in MR grade during dobutamine echocardiography (32). Inotropes, however, are not feasible for chronic use, and play a limited role in MR management outside of the acute hospital setting. Intra-aortic balloon counterpulsation may reduce MR acutely and prove life saving in patients with acute severe mitral regurgitation. Ventricular assist devices also reduce or abolish MR.

Cardiac resynchronization therapies (CRTs). CRT reduces functional MR acutely (33,34) and chronically in selected patients by 1) decreasing effective regurgitant orifice area by as much as nearly 50%; 2) increasing LV dP/dt (ratio of change of ventricular pressure to change in time) and LV closing forces; and 3) partially reversing LV remodeling and reducing MV apical tethering (35,36). Chronically, more extensive LV remodeling from CRT appears to lead to proportionally greater reductions in MR. More than half of the responders to CRT sustain reductions of at least 1 grade in MR for at least 6 months (37). Kanzaki et al. (34) have shown that realignment of contractile timing of the papillary muscles is partially responsible for a significant reduction in MR severity in the setting of left bundle branch block and cardiac dyssynchrony. Significant MR recurs if effective CRT is interrupted or discontinued.

Surgical Options

Current consensus indications for MR surgery. The current updated American College of Cardiology/American Heart Association valve disease guidelines (1) include an appropriately cautious but generally supportive recommendation for consideration of MV surgery in patients with

advanced HF, but only if MVR or MV replacement with chordal sparing are options. The authors conclude that “. . . even though such a patient is likely to have persistent LV dysfunction, surgery is likely to improve symptoms and prevent further deterioration of LV function. . .” (1).

Prior published studies. To date, there has been neither 1) a randomized prospective trial of MV surgery compared with medical therapy in patients with severe MR and advanced HF; 2) a trial of different repair techniques; nor 3) a comparison of MVR versus MV replacement. The National Heart, Lung, and Blood Institute (NHBLI) Cardiothoracic Surgical Trials Network is currently conducting 2 prospective, randomized multicenter clinical trials of MV surgery: 1) coronary artery bypass graft surgery (CABG) alone versus CABG plus MVR in moderate MR; and 2) mitral repair versus chordal-sparing MV replacement in patients with severe ischemic MR (10). Many experienced surgeons at high-volume centers currently perform isolated MV surgery for severe, symptomatic ischemic MR in patients with prior CABG and no available targets for redo revascularization. In many such patients, symptoms improve even without a readily demonstrable improvement in LV function. It is hoped that the NHLBI trials will inform decision making in this difficult patient group.

Prior published series of MV surgery in patients with advanced HF are summarized in Table 2 (9,38–48). Since studies to date are retrospective, observational, and mostly single center, they all suffer from potential referral, selection, ascertainment, and reporting biases and limited generalizability. Studies to date have mingled patients with ischemic and nonischemic cardiomyopathy, and patients undergoing simultaneous coronary artery bypass surgery. Most studies have reported center-specific techniques for repair.

Despite these limitations, review of the cumulative published experience supports a few broad conclusions. First, for carefully selected patients with advanced HF, MV surgery (particularly MV annuloplasty) appears reasonably safe, with reported 30-day mortality rates in the majority of studies between 1.6% and 5%. Second, most series have reported modest but statistically significant reverse remodeling (increases in left ventricular ejection fraction [LVEF], LV end-diastolic volume, LV end-systolic volume, and LV sphericity indexes) and more striking improvements in functional class and quality of life. Some, but not all, studies have reported improved exercise capacity. Third, with current annuloplasty techniques, moderate or greater MR occurs in as many as 35% of patients within 1 year of surgery (49–51). Lee et al. (52) have examined mechanisms of recurrent MR after MVR for nonischemic cardiomyopathy. Recurrent ($\geq 2+$ MR) was associated with greater distal mitral anterior leaflet angle, greater coaptation depth and tenting area, larger LV volumes, and poorer LVEF. Mitral annular dimension and post-operative exaggeration in posterior leaflet angle were similar. The authors conclude that posterior leaflet tethering is invariable after MV annuloplasty and post-operative mitral competence is highly de-

Table 2 Prior Surgical Series

Author (Ref. #)	Year	n	IDCM (%)	CABG (%)	NYHA Functional Class III/IV (%)	LVEF (%)	LVEDD (cm)	Operation	30-Day Mortality (%)	Survival (%)	NYHA Baseline to Follow-Up
Geidel et al. (45)	2007	121	16	70	N/A	30 ± 9	63 ± 8	MVA in all	3.3	91% at 30 months	3.4 to 1.5
Calaffore et al. (42)	2007	49	25	67	49/51	27 ± 7	N/A	MVA in 29; MVR in 20	4.2	78% at 5 yrs	3.5 to 2.2
Acker et al. (38)	2006	193	94	0	72/5	24 ± 9	70 ± 9	MVA 85; MVR 15	1.6	85% at 2 yrs	2.82 to 2.25
De Bonis et al. (44)	2005	77	34	51	75/25	28 ± 4	68	MVA in 23; ETE + MVA in 54	3.8	91% at 2.7 yrs	3.4 to 1.4
Wu et al. (9)	2005	126	29	0	N/A	23 ± 7	65 ± 8	MVA in all	4.8	60% at 5 yrs	N/A
Shah et al. (48)	2005	101	84	0	N/AA	34 ± 9	61 ± 9	MVA in all	2.9	70% at 5 yrs	N/A
Calaffore et al. (41)	2004	102	0	91	68/30	37 ± 12	N/A	MVA in 82; MVR in 20	3.9	74% at 5 yrs	3.2 to 2.1
Gummert et al. (46)	2003	66	80	0	N/A	23 ± 6	69 ± 10	MVA in all	6.1	66% at 5 yrs	3.0 to 2.0
Rothenburger et al. (47)	2002	31	66	33	21/10	23 ± 7	66 ± 8	MVA in 16; MVR in 15	6.5	77% at 5 yrs	3.3 to 2.1
Bitran et al. (39)	2001	21	0	100	90/10	<25	N/A	CABG + MVA	0.0	86% at 2 yrs	67% I-II, 17% III
Bishay et al. (40)	2000	44	30	0	34/27	28 ± 6	65 ± 8	MVA in 35; MVR in 9	2.3	67% at 5 yrs	2.8 to 1.2
Chen et al. (43)	1998	81	23	77	N/A	<30	N/A	MVA in most	11.0	38% at 5 yrs	3.3 to 1.6

CABG = coronary artery bypass graft surgery; ETE = edge-to-edge; IDCM = idiopathic dilated cardiomyopathy; LVEDD = left ventricular end-diastolic dimension; LVEF = left ventricular ejection fraction; MVA = mitral valve annuloplasty; MVR = mitral valve repair; N/A = not available; NYHA = New York Heart Association functional class.

pendent on distal anterior leaflet mobility. Reverse remodeling, particularly of the posterior wall, is associated with longer repair durability after annuloplasty (49,53-56). Use of rigid rather than flexible annuloplasty rings is associated with a lower likelihood of recurrent MR requiring reoperation (57). Fourth, the repair versus replacement risk-benefit ratio remains unclear in advanced HF patients given the higher failure rate but lower risk of MVR relative to the lower failure rate but higher risk of MV replacement. Fifth, the mortality benefit of mitral valve annuloplasty (MVA) or MVR in either ischemic or nonischemic HF compared with conventional medical and device therapies is not yet established.

A few studies are worthy of detailed comment. Wu et al. (9) performed a propensity analysis on a selected subset of 126 consecutive patients (mean age 65.5 ± 9.6 years, LV end-diastolic diameter [LVEDD] 65 ± 8 mm, LVEF 23 ± 7%) with severe MR and advanced HF who underwent MVA (undersized annuloplasty ring) at the University of Michigan between 1995 and 2002. Thirty-day mortality was 4.8%. MVA treated as a time-dependent covariate was not an independent predictor of the combined clinical outcome of death, LV assist device implantation, or United Network for Organ Sharing status 1 listing for cardiac transplantation (Fig. 3). Freedom from the combined end point was ≈50% at 5 years.

Limitations of this study include the time period (1995 to 2002) and lack of information regarding follow-up interventions. During the study period, a variety of annuloplasty rings (including flexible and partial rings) were used, poten-

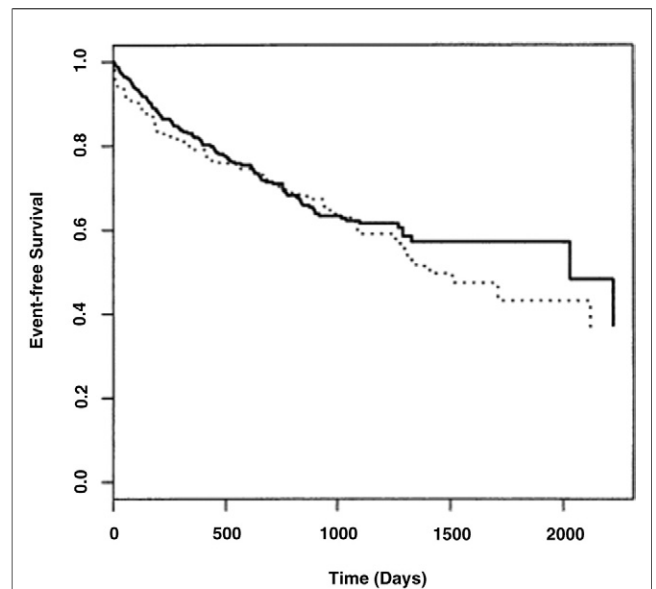


Figure 3 Survival for MVA Versus Medical Therapy in the University of Michigan Cohort

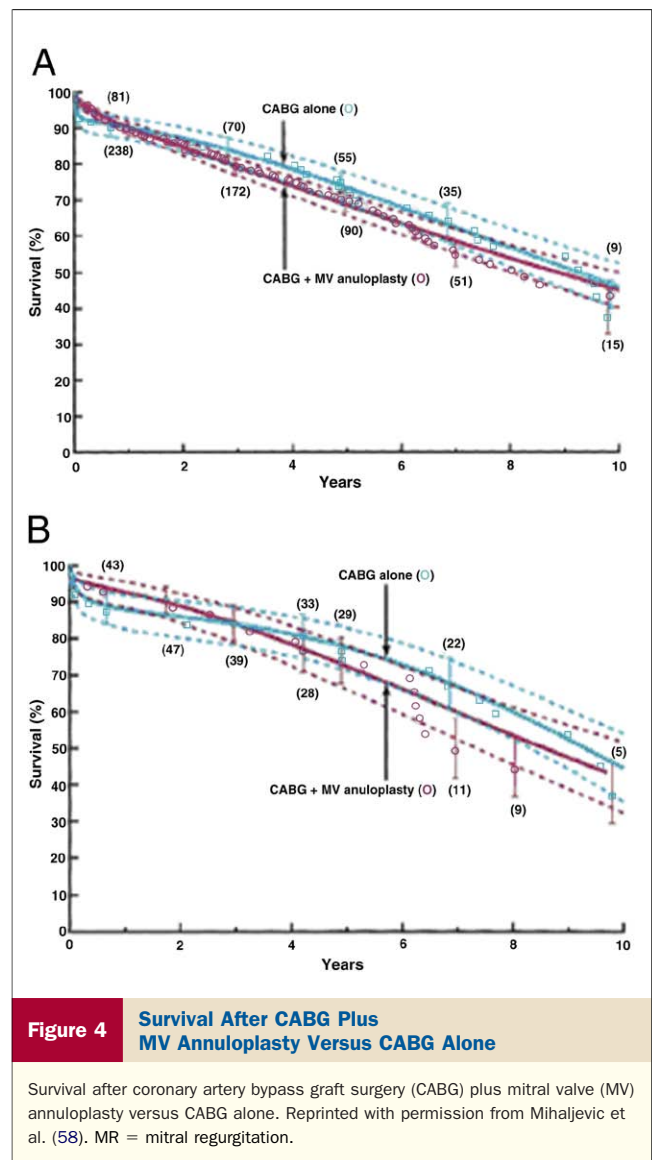
Survival for mitral valve annuloplasty (MVA) group (dotted line) versus medical therapy (solid line) in the University of Michigan cohort. Reprinted with permission from Wu et al. (9).

tially modifying the outcome of MVR. There was significant underutilization of beta-blockers (33%), spironolactone (15%), and implantable cardioverter-defibrillators (18%) in the MVA patients compared with contemporary practice. The proportion of patients in either group after surgery who received interventions subsequently shown to impact mortality in advanced HF (e.g., beta-blockers, implantable cardioverter defibrillators, biventricular permanent pacemakers) is not provided. Despite these limitations, the study has sounded a cautionary note that the mortality benefit for MVA may not be pronounced.

In an uncontrolled observational study, Mihaljevic et al. (58) evaluated the effect of MV annuloplasty for moderate to severe MR among patients undergoing CABG. From 1991 to 2003, 390 patients with 3+/4+ MR underwent CABG alone (n = 100) or CABG plus MVA (n = 290). Groups were propensity matched for extent of coronary artery disease, demographics, and regional wall motion. New York Heart Association (NYHA) functional class improved in both groups and remained improved at 5-year follow-up; 25% of both groups had NYHA functional class III/IV symptoms. One-, 5-, and 10-year survival rates did not differ: 88%, 75%, and 47% after CABG alone and 92%, 74%, and 39% for CABG and MVR, respectively (Fig. 4). Limitations included the nonrandomized assignment to surgical therapy, lack of echocardiographic data on all patients who underwent isolated CABG, lack of contemporary HF therapy, and absence of pre-operative myocardial viability measures or post-operative remodeling parameters. The high recurrence rate cited in this series may be attributable in part to use of partial Cosgrove annuloplasty rings.

Several large observational series of patients with ischemic MR undergoing repair or replacement with and without CABG have been reported. The Dion group (59) reported that CABG combined with MVR employing a restrictive annuloplasty ring resulted in low mortality, improvement in symptoms, reverse remodeling, and minimal MR recurrence at 4 years. These favorable results were reported only if the pre-operative LVEDD was <65 mm by echocardiography. Some series from high-volume surgical centers have reported no difference in mortality between MVR and MV replacement in patients with ischemic MR (60), including no difference in outcome between MVR and MV replacement in older class IV patients with ischemic MR (61).

A more optimistic tone for surgery for nonischemic MR was sounded from the trial designed to evaluate the efficacy of the Acorn CorCap (Acorn Cardiovascular, St. Paul, Minnesota), a LV passive restraint device. Acker et al. (38) reported the outcome of 193 patients enrolled in the MVA or MVR stratum of the Acorn study, 102 randomly allocated to MVA alone and 91 to MVA plus CorCap. Repair was performed via an undersized MV annuloplasty ring in 84.2%, and MVR in 15.8%. Mean LVEDD was 69.7 ± 8.8 mm, LVEF $23.9 \pm 8.9\%$, peak VO_2 14.1 ± 4.3



$mg \cdot kg^{-1} \cdot min^{-1}$, and NYHA functional class II, III, and IV were 23.3%, 71.55%, and 5.2% of subjects, respectively. The demographics were unusual for a HF cohort: 54.4% were female, 39.9% were nonwhite minority patients, and 93.8% had nonischemic cardiomyopathy. The MR severity graded 0 to 4 by the core echocardiography laboratory was found in 7.4%, 10.6%, 23.3%, 25.9%, and 32.8%, respectively.

The 30-day mortality was 1.6% and survival at 1 and 2 years was 86.5% and 85.2%, respectively (Fig. 5). There was significant evidence of reverse remodeling: MR grade decreased 2.66 to 0.59 ($p < 0.0001$) at 18 months, and at 24 months, LVEF increased by 4.1% ($p = 0.03$), mean sphericity index increased by 0.197 ($p < 0.0001$) and mean LV mass decreased $72.81 g/m^2$ ($p < 0.0001$). Compared with patients having MVR alone, MVR plus CorCap patients had greater improvements in sphericity index and systolic and diastolic ventricular volumes, but not MR grade (62). The NYHA functional class declined from a baseline

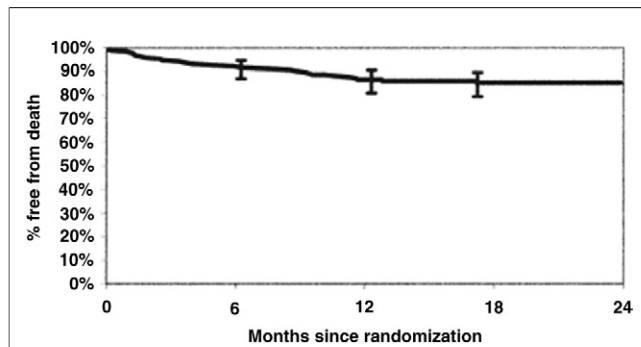


Figure 5 2-Year Survival for Acorn Study Cohort

Reprinted with permission from Acker et al. (38).

of 2.82 to 2.25 at 24 months ($p < 0.0001$). There was no significant change in peak VO_2 at 12 months. In summary, the investigators concluded that there is “clear benefit to the surgical elimination of mitral regurgitation” and that the CorCap device appeared to provide “significant additional benefit,” with incremental improvements in remodeling. A subsequent report showed sustained benefits in indices of reverse remodeling at 3-year follow-up, with a crude mortality rate of $\approx 27\%$ (62,63). Five-year follow-up results from the MR subgroup of the Acorn trial have been presented but not yet published (64). At 5 years, only 19% of patients evidenced recurrence of $>2+$ MR. Evidence of significant remodeling persisted and included the significant improvement of LVEF noted at 18 months. Because only 7% of these patients had ischemic MR, these favorable Acorn trial results pertain to patients with nonischemic MR.

As compelling as these findings are, there are several caveats. First, the degree of MR was 3 to 4+ in only 60% of the population, and 23% of the subjects were in NYHA functional class II. Despite the evidence of reverse remodeling and improvement in quality of life, there was no significant increase in peak VO_2 (perhaps due to beta-blocker therapy for 80.3% of the study population). The investigators specifically excluded from the study patients with any 4 of the following criteria: severe LV enlargement (LVEDD ≥ 80 mm), marked exercise limitation (peak $\text{VO}_2 \leq 13 \text{ ml}\cdot\text{kg}^{-1}\cdot\text{min}^{-1}$), systolic BP ≤ 80 mm Hg, atrial fibrillation, HF duration ≥ 8 years, exercise-induced increase in systolic blood pressure $\leq 10\%$, 6-min walk test ≤ 350 m, prior cardiac surgery, blood urea nitrogen ≥ 100 mg/dl, and cachexia (5). Despite these caveats and selective inclusive criteria, the low perioperative risk and 3-year outcomes are encouraging and provide some “proof of principle” evidence for LV passive restraint devices (8).

Current Unresolved Controversies

Selection of candidates. While it is clear that the failing ventricle would benefit from relief of severe MR, unanswered questions remain regarding appropriate patient selection, acceptable perioperative mortality, and long-term

survival benefit (Table 3) (4). As the thoughtful clinician formulates a recommendation, 2 pre-operative candidate selection issues in particular consistently arise: 1) minimization of perioperative risk; and 2) LV reverse remodeling viability. Candidates should have favorable surgical and medical considerations (Table 3), and resultant low predicted perioperative morbidity and mortality (ideally $<2\%$) (5). Long-term reduction in morbidity and mortality should be at least comparable to that with current medical and device therapy. One would, therefore, preferentially recommend MV surgery for advanced HF patients with some evidence—however indirect by existing tools—of LV reverse remodeling viability (Table 3).

Clinical Outcomes

Surgical. From existing surgical series, patients with concurrent CABG and MVR tend to fare better than patients undergoing MVR alone, although the operative risk is higher (6% to 12%) (11). In studies to date, post-infarction patients who undergo MV surgery for severe MR with simultaneous LV remodeling procedures (LV aneurysm plication, excision, or exclusion) appear to have more durable relief of MR, although the complexity of these combined operations increases risk, and this approach has not been prospectively compared with MV surgery alone. Patients with passive, reversible pulmonary artery hypertension due to chronic severe MR generally fare well after successful MV surgery. However, patients with fixed pulmonary vascular resistance, nonreversible pulmonary artery hypertension, and chronic advanced RV dysfunction are high, if not prohibitive, risk candidates for MV surgery. Patients who have had prior cardiac surgery are at inherently higher risk. Other potential clinical factors increasing risk from the Acorn trial were discussed in preceding text.

Table 3 Abbreviated Criteria for Selection of Appropriate Operative Candidates

Favorable surgical considerations	
Coronary artery disease and concurrent revascularization	
Ventricular reconstruction (e.g., Dor)	
Reversible pulmonary hypertension	
No prior operations	
Favorable medical considerations	
NSR (or likelihood of restoration)	
“Tolerance” of reasonable doses of vasodilators and beta-blockers	
Preservation of renal function	
Absence of hyponatremia	
Absence of refractory right heart failure	
Absence of cachexia	
Favorable LV reverse remodeling viability	
Absence of severe ventricular dilation (LVEDD >80 mm)	
Lower sphericity index	
Preservation of LV torsion	
Presence of contractile reserve	
Beneficial response to cardiac resynchronization	

LV = left ventricle; LVEDD = left ventricular end-diastolic diameter; NSR = normal sinus rhythm.

Medical. The following clinical features are associated with worse prognosis in advanced HF: persistent resting tachycardia, low proportional pulse pressure, tolerance of low doses or recent reduction in doses of vasodilators or beta-blockers, hyponatremia, elevation of blood urea nitrogen and serum creatinine in the absence of intrinsic renal disease, prolonged QRS duration, cardiac cachexia, and refractory right ventricular failure (65). These clinical features also belie a higher surgical risk and likely lesser degree of LV reverse remodeling viability.

Reverse remodeling viability. Although uncommonly available as routine measures, a higher LV sphericity index, less preservation of LV torsion during systole, and greater degrees of myocardial fibrosis likely belie more limited reverse remodeling viability. Left ventricle sphericity can be calculated by echocardiography at end diastole and end systole as the volume of the left ventricle divided by the volume of a sphere with a diameter equal to the left ventricle longest axis in the apical view (49). Left ventricle torsion may be measured by magnetic resonance imaging (MRI) “tagging” techniques. Gadolinium-enhanced MRI can quantitate myocardial fibrosis (66).

The degree of LV contractile reserve as assessed by exercise or inotropic stimulation is a predictor of LV function after MVR in minimally symptomatic patients (67), acute-onset and chronic symptomatic HF (68), and aortic stenosis with ventricular dysfunction (69,70). As such, assessment of LV contractile reserve should likely play a more important role in the recommendation of MV surgery in advanced HF. Failure to respond to CRT despite acceptable LV lead configuration may also be an indirect “marker” of limited LV contractile reserve and/or remodeling viability.

Based upon experimental models, overall ventricular remodeling parallels myocyte and extracellular matrix remodeling. We currently lack, however, sophisticated direct or indirect measures of myocyte and matrix remodeling—a “molecular remodeling index”—for clinical use. In the future, an integrated approach of biomarker panels (inflammation, oxidative stress, extracellular matrix remodeling, neurohormonal activation, myocyte injury, and myocyte stress) (71) complemented by molecular myocardial imaging (66,72,73) and/or endomyocardial biopsy (myocyte number and size, myocardial fibrosis, proteomics, and genomics) (74) may refine clinical recommendation.

An integrated approach. A suggested stepwise approach to clinical management and decision making appears in Table 4. Medical therapy should be optimized for all patients, with optimization confirmed for selected patients with right-side heart catheterization. All suitable candidates should undergo CRT. After optimization of medical therapy and CRT, the degree of MR should be reassessed. If MR remains severe and the patient remains symptomatic, then MV surgery should be considered.

The clinical features informing 1) prognosis; 2) reverse remodeling viability; 3) perioperative risk; and 4) the anticipated durability of repair should all be weighed carefully. Gadolinium-enhanced and dobutamine stress MRI may verify and quantitate MR severity, ventricular dimensions and function, fibrosis, and contractile reserve. Ideal operative candidates possess lesser degrees of LV sphericity and fibrosis and possess contractile reserve. For patients for whom cardiac MRI is not possible, dobutamine stress echocardiography is reasonable.

A frank discussion should then follow with the patient regarding the surgical indication, perioperative risk, and

Table 4 Suggested Approach to the Management of Severe MR in Advanced Heart Failure

<p>1. Optimize medical therapy</p> <p>Angiotensin-converting enzyme inhibitor/angiotensin receptor-blocker, beta-blockers, aldosterone antagonists, flexible sliding-scale diuretic program, hydralazine-isosorbide dinitrate</p> <p>Define adequacy of medical therapy by cardiac catheterization in selected instances</p> <p>Ensure compliance with medical therapy and lifestyle accommodations</p>
<p>2. Evaluate for revascularization in patients with coronary artery disease</p>
<p>3. Provide CRT</p> <p>Indications: LV ejection fraction <35%, QRS interval >120 ms, New York Heart Association functional class III to IV</p> <p>Reassess clinical response and MR severity</p>
<p>4. Reconfirm the severity of MR</p> <p>“Definitive” imaging modality after optimizing medical therapy, revascularization, and CRT with cardiac magnetic resonance imaging or echocardiography</p>
<p>5. For patients who remain intolerably symptomatic, define perioperative risk and surgical options</p> <p>Ideally, perioperative risk should be $\leq 2\%$ on the basis of composite medical and surgical factors</p> <p>Ideal candidates will have heart failure duration <5 years, resting heart rate <100 beats/min, systolic blood pressure >80 mm Hg with normal proportional pulse pressure, serum sodium >135 mmol/dl, blood urea nitrogen >100 mg/dl, creatinine >2.5 mg/dl, normal total bilirubin, LV end-diastolic diameter <80 mm, peak $\text{VO}_2 >14 \text{ mg}\cdot\text{kg}^{-1}\cdot\text{min}^{-1}$, 6-min walk test >350 m, no cachexia, no prior cardiac surgery, reversible pulmonary hypertension, no refractory right heart failure</p>
<p>6. Estimate LV reverse remodeling viability on the basis of aggregate clinical data</p>
<p>7. Discuss mitral valve surgery frankly with the patient and family</p> <p>Issues to discuss: 1) perioperative risk; 2) durability of planned correction; and 3) clinical outcomes on the basis of available data: functional capacity, long-term LV remodeling and function, and mortality.</p>

CRT = cardiac resynchronization therapy; LV = left ventricular; MR = mitral regurgitation.

expected outcomes. For most patients with advanced HF and severe MR, studies to date suggest that MV surgery should result in a modest improvement in LV function, a modest degree of reverse remodeling, and a significant improvement in functional capacity by 1 or more NYHA functional classes. There is no evidence as yet that MV surgery in advanced HF reduces mortality.

Surgical Considerations

MV surgery may be performed via a sternotomy or thoracotomy. A less invasive right thoracotomy approach may minimize tissue dissection and inflammation (75–78). A modified Maze procedure is frequently performed to enhance the probability of maintaining normal sinus rhythm. In patients undergoing MVR or MV replacement, concurrent repair of the tricuspid valve by annuloplasty in cases of severe tricuspid regurgitation associated with dilation of the tricuspid valve annulus is currently a class I indication (1).

The respective roles of MVR versus MV replacement in patients with advanced HF continue to evolve. Compared with patients undergoing MV replacement with chordal preservation, patients undergoing MVR have lower perioperative mortality but a higher failure rate (up to 30% at 1 to 2 years). Because most series to date have reported patients undergoing MVR rather than MV replacement, the lack of demonstrated mortality benefit to date in MV surgery in advanced HF may reflect, at least in part, the less durable relief of MR afforded by MVR rather than MV replacement.

Selected centers combine MV annuloplasty with an edge-to-edge Alfieri repair to provide more complete MVR than either technique may provide alone (44). In experienced centers, the edge-to-edge Alfieri repair has been performed in instances of mitral leaflet coaptation depth ≥ 1 cm by echocardiography. Although the Alfieri technique improves coaptation in instances of MV leaflet flail or prolapse, it may increase tension on tethered leaflets not otherwise “unstressed” by concurrent annuloplasty (11). The edge-to-edge repair can restrict the mitral orifice and potentially lead to mitral stenosis if thickening of the leaflets is present or develops. Of more concern, the rate of recurrent moderate/severe MR has been reported as high as 30% (79).

The normal MV annulus has a saddle-shape configuration, and the resultant increase in leaflet curvature likely reduces leaflet stress (80). By echocardiography and MRI, patients with MR exhibit flattening of the annulus due to reduction in the saddle-horn height. Such flattening may increase leaflet closing stress and contribute to MR. Standard annuloplasty rings are planar and do not conform to the normal saddle-shaped MV annulus. Development of 3-dimensional annuloplasty rings with better conformation to the saddle-shaped annulus may provide additional reduction in leaflet closing stress and MR.

Evolving Approaches

Given the central importance of ventricular remodeling, there is great interest in combining MVR or MV replacement with ventricular remodeling procedures (Table 5). Mitral annuloplasty rings continue to evolve. The most recent ones are cause specific and geometrically shaped to accommodate the underlying pathology, not to replace the “normal” MV annulus (81). A large variety of newer rings are now available and undergoing clinical evaluation for their durability in MVR. Evolving surgical options (11) include such variations in ring annuloplasty design, infarct or aneurysm plication, excision or exclusion (e.g., Dor procedure), external restraint devices (e.g., CorCap), internal LV or papillary muscle “cinching” devices (e.g., CoApsys), papillary muscle repositioning (82), nonbiological material LV buttressing (83), and leaflet lengthening procedures. Given the reported failure rates of current annuloplasty techniques, LV remodeling procedures performed in concert with annuloplasty will be necessary to provide durable correction in many patients.

Evolving devices for percutaneous mitral repair fall into 1 of 3 main mechanistic categories: 1) leaflet side-to-side apposition; 2) annulus cinching; and 3) external restraint (84,85). Such devices, if capable of providing durable results with low periprocedural risk, may prove successful nonoperative alternatives to MVR.

After successful MV surgery, the remodeling LV may yet benefit from novel restorative therapies. Overexpression of SERCA2a by intracoronary gene transfer preserved systolic function and improved ventricular remodeling in a porcine

Table 5 Current and Evolving Options for Mitral Valve Surgery in Advanced Heart Failure

1. Mitral repair
Annulus (annuloplasty)
Ring (rigid, flexible; undersized)
Asymmetrical
Percutaneous techniques
Leaflets
Edge-to-edge leaflet (Alfieri)
Leaflet lengthening
Chordae
Basal chordae resection
Papillary muscle
Scar excision with papillary muscle “reimplantation”
Internal slings
Surgical “buckles”
External bands
Mesh patches
Ventricular “reshaping” (with annuloplasty)
Infarct plication
Infarct excision and patching (e.g., Dor)
Localized infarct patch with epicardial balloon
External restraint (e.g., Acorn CorCap)
2. Mitral replacement with chordal sparing

MR HF model (86). Cell replacement therapies may also hold promise (87).

Future Challenges

Given the heterogeneity of remodeling, it is unlikely that a “one size fits all” option will evolve for the durable correction of severe MR in patients with advanced HF. Surgeons and interventional cardiologists will require a portfolio of options for more targeted, individualized repair of the annulus, leaflets, chordae, and the remodeled ventricle. Adherence to criteria similar to those proposed by Lee et al. (52) may afford a more rational approach to the decision between repair and replacement based upon pre-operative echocardiographic criteria. The NHLBI trial in progress will provide greater insight into the selection, risks, and outcomes of MVR versus MV replacement in patients with ischemic MR. Just as more elegant measures of myocardial viability improved recommendations regarding coronary revascularization (88), more elegant measures of LV reverse remodeling viability may improve recommendations for severe MR in patients with advanced HF. Future measures of reverse remodeling viability may aggregate biomarkers, novel molecular imaging modalities (72,73), and genomic and proteomic assays of myocardial tissue.

Reprint requests and correspondence: Dr. Thomas G. Di Salvo, Vanderbilt Heart and Vascular Institute, 1215 21st Avenue, MCE 5th Floor, Suite 5037, Nashville, Tennessee 37232. E-mail: thomas.g.disalvo@vanderbilt.edu.

REFERENCES

1. Bonow RO, Carabello BA, Chatterjee K, et al. 2008 focused update incorporated into the ACC/AHA 2006 guidelines for the management of patients with valvular heart disease: a report of the American College of Cardiology/American Heart Association Task Force on Practice Guidelines (Writing Committee to Develop Guidelines for the Management of Patients With Valvular Heart Disease). *J Am Coll Cardiol* 2008;52:e1–142.
2. Carabello B. The current therapy for mitral regurgitation. *J Am Coll Cardiol* 2008;52:319–26.
3. Romano MA, Bolling SF. Update on mitral repair in dilated cardiomyopathy. *J Card Surg* 2004;19:396–400.
4. Blom AS, Acker MA. The surgical treatment of end-stage heart failure. *Curr Probl Cardiol* 2007;32:553–99.
5. Mehra MR, Reyes P, Benitez RM, Zimrin D, Gammie JS. Surgery for severe mitral regurgitation and left ventricular failure: what do we really know? *J Card Fail* 2008;14:145–50.
6. Thourani VH, Weintraub WS, Guyton RA, et al. Outcomes and long-term survival for patients undergoing mitral valve repair versus replacement: effect of age and concomitant coronary artery bypass grafting. *Circulation* 2003;108:298–304.
7. Trichon BH, Felker GM, Shaw LK, Cabell CH, O'Connor CM. Relation of frequency and severity of mitral regurgitation to survival among patients with left ventricular systolic dysfunction and heart failure. *Am J Cardiol* 2003;91:538–43.
8. Grossi EA, Croke GA. Mitral valve surgery in heart failure: insights from the Acorn clinical trial. *J Thorac Cardiovasc Surg* 2006;132:455–6.
9. Wu AH, Aaronson KD, Bolling SF, Pagani FD, Welch K, Koelling TM. Impact of mitral valve annuloplasty on mortality risk in patients with mitral regurgitation and left ventricular systolic dysfunction. *J Am Coll Cardiol* 2005;45:381–7.
10. Cardiothoracic Surgical Trials Network. Available at: <http://www.ctsurgerynet.org/>. Accessed August 6, 2009.
11. Levine RA, Schwammenthal E. Ischemic mitral regurgitation on the threshold of a solution: from paradoxes to unifying concepts. *Circulation* 2005;112:745–58.
12. Allen LA, Felker GM. Advances in the surgical treatment of heart failure. *Curr Opin Cardiol* 2008;23:249–53.
13. Patel JB, Borgeson DD, Barnes ME, Rihal CS, Daly RC, Redfield MM. Mitral regurgitation in patients with advanced systolic heart failure. *J Card Fail* 2004;10:285–91.
14. Ellis SG, Whitlow PL, Raymond RE, Schneider JP. Impact of mitral regurgitation on long-term survival after percutaneous coronary intervention. *Am J Cardiol* 2002;89:315–8.
15. Gaasch WH, Meyer TE. Left ventricular response to mitral regurgitation: implications for management. *Circulation* 2008;118:2298–303.
16. Messas E, Guerrero JL, Handschumacher MD, et al. Chordal cutting: a new therapeutic approach to ischemic mitral regurgitation. *Circulation* 2001;104:1958–63.
17. Beeri RY, Yosefy C, Guerrero JL, et al. Mitral regurgitation augments post-myocardial infarction remodeling. *J Am Coll Cardiol* 2008;51:476–86.
18. Neilan TG, Ton-Nu TT, Kawase Y, et al. Progressive nature of chronic mitral regurgitation and the role of tissue Doppler-derived indexes. *Am J Physiol Heart Circ Physiol* 2008;294:H2106–11.
19. Hill JA, Olsen EN. Cardiac plasticity. *N Engl J Med* 2008;358:1370–80.
20. Otsuji Y, Handschumacher MD, Schwammenthal E, et al. Insights from three-dimensional echocardiography into the mechanism of functional mitral regurgitation: direct in vivo demonstration of altered leaflet tethering geometry. *Circulation* 1997;96:1999–2008.
21. Kono I, Sabbah HN, Rosman H, et al. Left ventricular shape is the primary determinant of functional mitral regurgitation in heart failure. *J Am Coll Cardiol* 1992;20:1594–8.
22. Sabbah HN, Kono T, Stein PD, et al. Left ventricular shape changes during the course of evolving heart failure. *Am J Physiol* 1992;263:H266–70.
23. Carabello BA, Nakano K, Corin W, et al. Left ventricular function in experimental volume overload hypertrophy. *Am J Physiol* 1989;256:H974–81.
24. Kaul S, Spotnitz WD, Glasheen WP, et al. Mechanism of ischemic mitral regurgitation: an experimental evaluation. *Circulation* 1991;84:2167–80.
25. Otsuji Y, Levine RA, Takeuchi M, et al. Mechanism of ischemic mitral regurgitation. *J Cardiol* 2008;51:145–56.
26. Beeri R, Yosefy C, Guerrero JL, et al. Early repair of moderate ischemic mitral regurgitation reverses left ventricular remodeling: a functional and molecular study. *Circulation* 2007;116 Suppl 1:288–93.
27. Hamilton MA, Stevenson LW, Child JS, et al. Sustained reduction in valvular regurgitation and atrial volumes with tailored vasodilator therapy in advanced congestive heart failure secondary to dilated (ischemic or idiopathic) cardiomyopathy. *Am J Cardiol* 1991;67:259–63.
28. Stevenson LW, Belli D, Brovere-McKay G, et al. Effects of afterload reduction (diuretics and vasodilators) on left ventricular volume and mitral regurgitation in severe congestive heart failure secondary to ischemic or idiopathic dilated cardiomyopathy. *Am J Cardiol* 1987;60:654–8.
29. Kizilbash AM, Willett DL, Brickner ME, et al. Effects of afterload reduction on vena contracta width in mitral regurgitation. *J Am Coll Cardiol* 1998;32:427–31.
30. Tsutsui H, Spinale FG, Nagatsu M, et al. Effects of chronic beta-adrenergic blockade on the left ventricular and cardiocyte abnormalities of chronic canine mitral regurgitation. *J Clin Invest* 1994;93:2639–48.
31. Lowes BD, Gill EA, Abraham WT, et al. Effects of carvedilol on left ventricular mass, chamber geometry, and mitral regurgitation in chronic heart failure. *Am J Cardiol* 1999;83:1201–5.
32. Heinle SK, Tice FD, Kisslo J. Effect of dobutamine stress echocardiography on mitral regurgitation. *J Am Coll Cardiol* 1995;25:122–7.
33. Breithardt OA, Sinha AM, Schwammenthal E, et al. Acute effects of cardiac resynchronization therapy in functional mitral regurgitation in advanced systolic heart failure. *J Am Coll Cardiol* 2003;41:765–70.
34. Kanzaki H, Bazaz R, Schwartzman D, Doki K, Sate LE, Gorscan J. A mechanism for immediate reduction in mitral regurgitation after

- cardiac resynchronization therapy. *J Am Coll Cardiol* 2004;44:1619-25.
35. Abraham WT. Cardiac resynchronization therapy. *Prog Cardiovasc Dis* 2006;48:232-8.
36. Auricchio A, Abraham WT. Cardiac resynchronization therapy: current state of the art. *Circulation* 2004;109:300-7.
37. Ypenburg C, van Bommel RJ, Borleffs CJ, et al. Long-term prognosis after cardiac resynchronization therapy is related to the extent of left ventricular reverse remodeling at midterm follow-up. *J Am Coll Cardiol* 2009;53:483-90.
38. Acker MA, Bolling S, Shemin R, et al. Mitral valve surgery in heart failure: insights from the Acorn clinical trial. *J Thorac Cardiovasc Surg* 2006;132:568-77.
39. Bitran D, Merin O, Klutstein, et al. Mitral valve repair in severe ischemic cardiomyopathy. *J Card Surg* 2001;16:79-82.
40. Bishay ES, McCarthy PM, Cosgrove DM, et al. Mitral valve surgery in patients with severe left ventricular dysfunction. *Eur J Cardiothorac Surg* 2000;17:213-21.
41. Calafiore AM, Di Mauro M, Gallina S, et al. Mitral valve surgery for chronic ischemic mitral regurgitation. *Ann Thorac Surg* 2004;77:1989-97.
42. Calafiore AM, Gallina S, Di Mauro M, et al. Mitral valve procedure in dilated cardiomyopathy: repair or replacement? *Ann Thorac Surg* 2001;71:1146-53.
43. Chen FY, Adams DH, Aranki SF, et al. Mitral valve repair in cardiomyopathy. *Circulation* 1998;98 Suppl 2:II24-7.
44. De Bonis M, Lapenna E, La Canna G, et al. Mitral valve repair for functional mitral regurgitation in end-stage dilated cardiomyopathy: role of the "edge-to-edge" technique. *Circulation* 2005;112 Suppl 1:I402-8.
45. Geidel S, Lass M, Krause K, et al. Early and late results of restrictive mitral valve annuloplasty in 121 patients with cardiomyopathy and chronic mitral regurgitation. *Thorac Cardiovasc Surg* 2008;56:262-8.
46. Gummert JF, Rahmel A, Bucerius J, et al. Mitral valve repair in patients with end stage cardiomyopathy: who benefits? *Eur J Cardiothorac Surg* 2003;23:1017-23.
47. Rothenburger M, Rukosujew A, Hammel D, et al. Mitral valve surgery in patients with poor left ventricular function. *Thorac Cardiovasc Surg* 2002;50:351-4.
48. Shah AS, Hannish SA, Milano CA, et al. Isolated mitral valve repair in patients with depressed left ventricular function. *Ann Thorac Surg* 2005;80:1309-14.
49. Hung J, Papakostas L, Tahta SA, et al. Mechanism of recurrent ischemic mitral regurgitation after annuloplasty: continued LV remodeling as a moving target. *Circulation* 2004;110 Suppl 2:II85-90.
50. McGee ED, Gillinov AM, Blackstone EH, et al. Recurrent mitral regurgitation after annuloplasty for functional ischemic mitral regurgitation. *J Thorac Cardiovasc Surg* 2004;128:916-24.
51. Marwick TH. Restrictive annuloplasty for ischemic mitral regurgitation: too little or too much? *J Am Coll Cardiol* 2008;51:1702-3.
52. Lee AP, Acker M, Kubo SH, et al. Mechanisms of recurrent functional mitral regurgitation after mitral valve repair in nonischemic dilated cardiomyopathy. Importance of distal anterior leaflet tethering. *Circulation* 2009;119:2606-14.
53. De Bonis M, Lapenna E, Verzini A, et al. Recurrence of mitral regurgitation parallels the absence of left ventricular reserve remodeling after mitral repair in advanced dilated cardiomyopathy. *Ann Thorac Surg* 2008;85:932-9.
54. Kuwahara E, Otsuji Y, Iguro Y, et al. Mechanism of recurrent/persistent ischemic/functional mitral regurgitation in the chronic phase after surgical annuloplasty: importance of augmented posterior leaflet tethering. *Circulation* 2006;114 Suppl 1:I1529-34.
55. Matsunaga A, Tahta SA, Duran CM. Failure of reduction annuloplasty for functional ischemic mitral regurgitation. *J Heart Valve Dis* 2004;13:390-7.
56. Zhu F, Otsuji Y, Yotsumoto G, et al. Mechanism of persistent ischemic mitral regurgitation after annuloplasty: importance of augmented posterior mitral leaflet tethering. *Circulation* 2005;30 Suppl 1:I1396-401.
57. Spoor MT, Geltz A, Bolling SF. Flexible versus nonflexible mitral valve rings for congestive heart failure: differential durability of care. *Circulation* 2006;114 Suppl 1:I67-71.
58. Mihaljevic T, Lam BK, Rajeswaran J, et al. Impact of mitral valve annuloplasty combined with revascularization in patients with functional ischemic mitral regurgitation. *J Am Coll Cardiol* 2007;49:2191-201.
59. Braun J, van de Viere NR, Klatz RJM, et al. Restrictive mitral annuloplasty cures ischemic mitral regurgitation and heart failure. *Ann Thorac Surg* 2008;85:430-7.
60. Enriquez-Sarano, M, Schaff HV, Frye RL. Mitral regurgitation: what causes the leakage is fundamental to the outcome of valve repair. *Circulation* 2003;108:253-6.
61. Gillinow AM, Wierup PN, Blackstone EH, et al. Is repair preferable to replacement for ischemic mitral regurgitation? *J Thorac Cardiovasc Surg* 2001;122:1125-41.
62. Starling RC, Jessup M, Oh JK, et al. Sustained benefits of the CorCap cardiac support device on left ventricular remodeling: three-year follow-up results from the Acorn clinical trial. *Ann Thorac Surg* 2007;84:1236-42.
63. Mann DL, Acker MA, Jessup M, et al. Clinical evaluation of the CorCap cardiac support device in patients with dilated cardiomyopathy. *Ann Thorac Surg* 2007;84:1226-35.
64. Jessup MA, Acker MA, Bolling S, et al. Mitral valve repair in heart failure: 5-year follow-up from the mitral valve repair stratum of the Acorn trial. *J Am Coll Cardiol* 2009;53 Suppl 1:A418.
65. Hunt SA, Abraham WI, Chin MH, et al. ACC/AHA 2005 guideline update for the diagnosis and management of chronic heart failure in the adult: a report of the American College of Cardiology/American Heart Association Task Force on Practice Guidelines (Writing Committee to Update the 2001 Guidelines for the Evaluation and Management of Heart Failure). *J Am Coll Cardiol* 2005;46:e1-82.
66. Vohringer M, Mahrholdt H, Yilmaz A, et al. Significance of late gadolinium enhancement in cardiovascular magnetic resonance imaging (CMR). *Herz* 2007;32:129-37.
67. Leung DY, Griffin BP, Steward WJ, et al. Left ventricular function after valve repair for chronic mitral regurgitation: predictive value of preoperative assessment of contractile reserve by exercise echocardiography. *J Am Coll Cardiol* 1996;28:1198-205.
68. Piechota W, Gielerek G. The prognostic value of stress tests in chronic heart failure. *Cardiol J* 2007;14:340-6.
69. Bermejo J, Yotti R. Low-gradient aortic valve stenosis: value and limitation of dobutamine stress testing. *Heart* 2006;93:298-302.
70. Grayburn PA. Assessment of low-gradient aortic stenosis with dobutamine. *Circulation* 2006;113:604-6.
71. Braunwald E. Biomarkers in heart failure. *N Engl J Med* 2008;358:2148-59.
72. Shirani J, Dilsizian V. Imaging left ventricular remodeling: targeting the neurohumoral systems. *Nature Clin Prac Cardiovasc Med* 2007;5 Suppl:S57-62.
73. van den Borne SW, Isobe S, Verjans JW, et al. Molecular imaging of interstitial alterations in remodeling myocardium after myocardial infarction. *J Am Coll Cardiol* 2008;52:2017-28.
74. Cooper LT, Baughman KL, Feldman AM, et al. The role of endomyocardial biopsy in the management of cardiovascular disease: a scientific statement from the American Heart Association, the American College of Cardiology, and the European Society of Cardiology. *Circulation* 2007;116:2216-33.
75. Wang D, Wang Q, Wu Q, et al. Mitral valve replacement through a minimal right vertical infra-axillary thoracotomy versus standard median sternotomy. *Ann Thorac Surg* 2009;87:704-8.
76. Grossi EA, Galloway AC, LaPietra A, et al. Minimally invasive mitral valve surgery: a 6-year experience with 714 patients. *Ann Thorac Surg* 2002;74:660-3.
77. Aybek T, Dogan S, Risteski PS, et al. Two hundred forty minimally invasive mitral operations through right minithoracotomy. *Ann Thorac Surg* 2006;81:1618-24.
78. Walther T, Falk V, Mohr FW. Minimally invasive mitral valve surgery. *J Cardiovasc Surg* 2004;45:487-95.
79. Bhudia SK, McCarthy PM, Smedira NG, Lam BK, Rajeswaran J, Blackstone EH. Edge-to-edge (Alfieri) mitral repair: results in diverse clinical settings. *Ann Thorac Surg* 2004;77:1598-606.
80. Kaji S, Nasu M, et al. Annular geometry in patients with chronic ischemic mitral regurgitation: three-dimensional magnetic resonance imaging study. *Circulation* 2005;112 Suppl 1:409-14.
81. Fedak PW, McCarthy PM, Bonow RO. Evolving concepts and technologies in mitral valve repair. *Circulation* 2008;117:963-74.
82. Hung J, Chaput M, Guerrero JL, et al. Persistent reduction of ischemic mitral regurgitation by papillary muscle repositioning: struc-

- tural stabilization of the papillary muscle-ventricular wall complex. *Circulation* 2007;116 Suppl 1:I259–63.
83. Hung J, Solis J, Guerrero JL, et al. A novel approach for reducing ischemic mitral regurgitation by injection of a polymer to reverse remodel and position displaced papillary muscles. *Circulation* 2008;118 Suppl 1:S263–9.
84. Tops LF, Kapadia SR, Tuzcu M, et al. Percutaneous valve procedures: an update. *Curr Prob Cardiol* 2008;33:417–57.
85. Mack MJ. New techniques for percutaneous repair of the mitral valve. *Heart Fail Rev* 2006;11:259–68.
86. Kawase Y, Ly HQ, Prunier F, et al. Reversal of cardiac dysfunction after long-term expression of SERCA2a by gene transfer in a pre-clinical model of heart failure. *J Am Coll Cardiol* 2008;51:1112–9.
87. Messas E, Bel A, Morichetti MC, et al. Autologous myoblast transplantation for chronic ischemic mitral regurgitation. *J Am Coll Cardiol* 2006;47:2086–93.
88. Camici PG, Prasad SK, Rimoldi OE. Stunning, hibernation and assessment of myocardial viability. *Circulation* 2008;117:103–14.

Key Words: mitral regurgitation ■ heart failure ■ cardiac surgery.