

Available online at www.sciencedirect.com

journal homepage: <http://www.journals.elsevier.com/hellenic-journal-of-cardiology/>

CASE REPORT

P-wave alternans in a patient with hyponatremia



Georgios Tsiaousis, MD, MSc^{a,*},
Nikolaos Fragakis, MD, PhD, FESC^b

^a Private Cardiology Practice, 14A Ath. Diakou Str., 52100 Kastoria, Greece

^b Third Department of Cardiology, Hippokrateion Hospital, Aristotle University Medical School, 49 Konstantinoupolos Str., 54642 Thessaloniki, Greece

Received 1 December 2014; accepted 25 December 2015

Available online 25 June 2016

KEYWORDS

ECG changes;
indapamide;
electrolyte disorders

Abstract We describe an unusual electrocardiographic (ECG) case of an alternating P-wave configuration that spares other ECG components. Hyponatremia due to chronic indapamide use was proposed as a plausible cause of this ECG phenomenon because its correction led to the recovery of a steady P-wave morphology.

© 2016 Hellenic Cardiological Society. Publishing services by Elsevier B.V. This is an open access article under the CC BY-NC-ND license (<http://creativecommons.org/licenses/by-nc-nd/4.0/>).

1. Introduction

Hyponatremia is generally considered an electrolyte disorder with the least characteristic electrocardiographic changes.¹ However, it occurs rather frequently among elderly patients who receive indapamide, especially women, and can accompany potassium and magnesium depletion.² Alternans is described as the ECG phenomenon of a fluctuating configuration of various ECG-components,

usually the T-wave and the QRS complex. Here, we report a case of alternating P-wave morphology in a patient with hyponatremia.

2. Case presentation

A 73-year-old female patient was referred for fatigue and an unusual appearance of P-waves on resting ECG by her family physician. Her past medical history included arterial hypertension that was adequately controlled with valsartan, amlodipine, and indapamide.

Upon the initial assessment, she was hemodynamically stable and her cardiac exam revealed only a mild systolic murmur at the aortic position; pulmonary and abdominal exams were unremarkable, and the patient was euvolemic. Her resting ECG showed an alternating P-wave morphology that fluctuated from a completely negative configuration

* Corresponding author. Georgios Tsiaousis, MD, MSc, Private Cardiology Practice, 14A Ath. Diakou Str., 52100 Kastoria, Greece. Tel.: +30 6972257887; fax: +30 2467081015.

E-mail addresses: gtsiaousis@gmail.com (G. Tsiaousis), fragakis.nikos@goolemail.com (N. Fragakis).

Peer review under responsibility of Hellenic Cardiological Society.

to a totally positive configuration that also exhibited various intermittent morphologies (Fig. 1A). Echocardiographically, a mild calcific mitral stenosis was demonstrated along with aortic sclerosis, left ventricle (LV) wall hypertrophy, preserved LV ejection fraction, and the absence of pulmonary hypertension. Her laboratory workup revealed hyponatremia (125 mmol/L) and potassium and magnesium concentrations close to the lower limit of normal (3.5 mmol/L and 1.8 mmol/L, respectively). Indapamide was interrupted, and the patient was put on water restriction, low-dose furosemide, and potassium and magnesium supplementation. During the follow-up visit six weeks later, the patient showed clinical improvement with comparable hemodynamic indices and the same body weight. Serum sodium levels had returned to normal (140 mmol/L), potassium and magnesium levels were practically unchanged

(3.8 mmol/L and 1.9 mmol/L, respectively), and the ECG showed stable P-wave morphology (Fig. 1B).

3. Discussion

Spodick classically defined electrical alternans "as an alternation of the configuration of the electrocardiographic complexes arising from the same pacemaker and being independent of periodic extracardiac phenomena".³ It usually involves the QRS-complex or the T-wave, but occasionally other ECG-components can be involved separately or all together simultaneously ("total alternans"). The ratio of alternating ECG-complexes is usually, but not always, 1:1, while a "varying electrical alternans" with an inconsistent ratio of alternating ECG-phenomena has also been described.⁴ P-wave alternans is extremely rare,

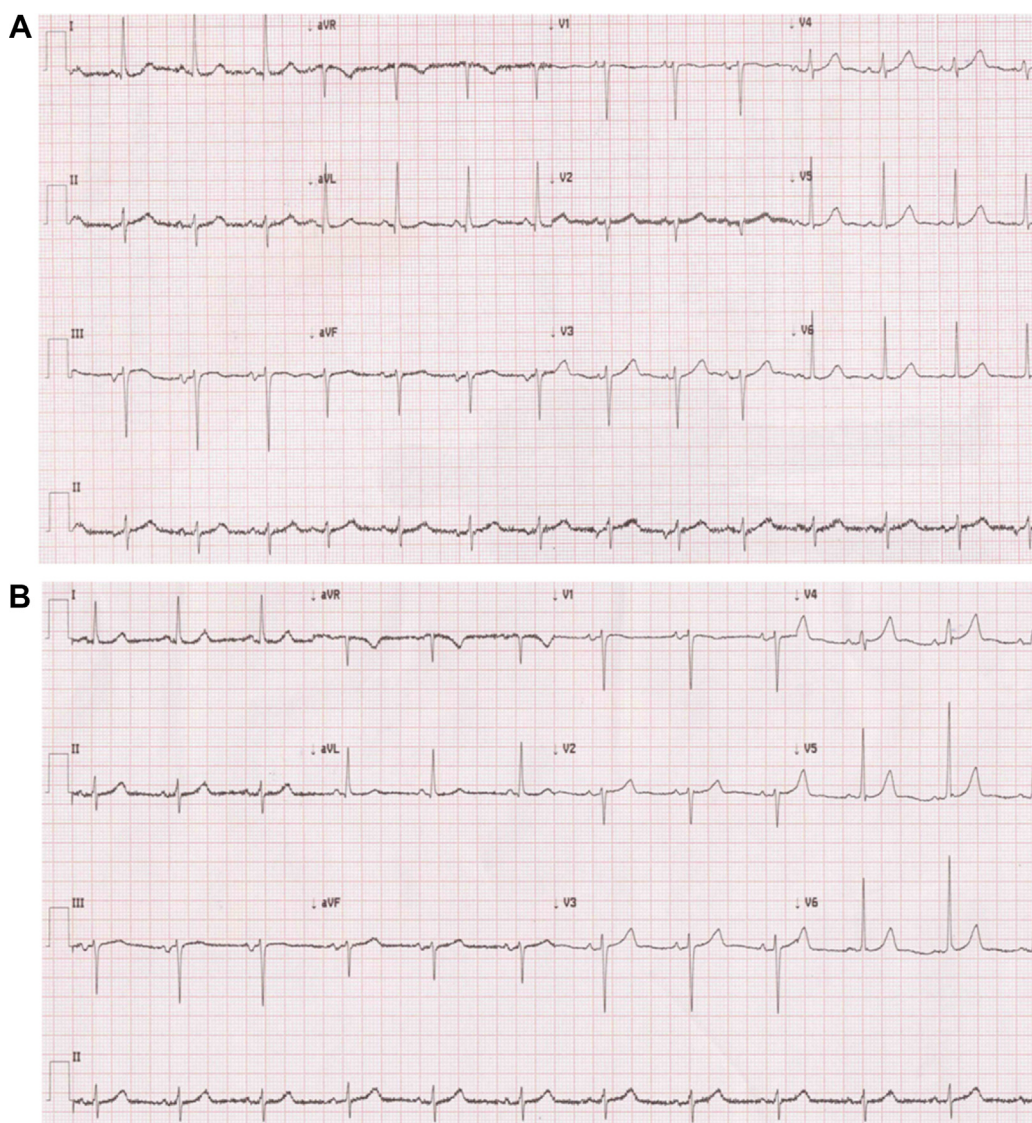


Figure 1 (A) Resting ECG showing the varying morphology of the P-wave, which is better seen in continuous lead II as it fluctuates from a completely negative configuration to a totally positive configuration with various intermittent morphologies, including an isodiphasic pattern. The PR duration was unchanged and the PP intervals were equal. (B) Steady P-wave morphology after correcting the hyponatremia.

especially as an isolated finding. In the present case, the PR and PP intervals remained stable, which ruled out other potential ECG diagnoses and/or mechanisms, such as an ectopic firing focus or a wandering pacemaker. Fulfilling the criteria of the original Spodick definition, this was considered an alternans phenomenon confined only to the P-wave that exhibited a varied ratio of alternation.

Although many generations of cardiologists have considered electrical alternans an exclusive result of cardiac tamponade, it has actually been found to exhibit a strikingly low predictive sensitivity for either pericardial effusion or tamponade, much lower than that of PR-segment depression and low ECG voltage.⁵ As for the rarely reported electrical alternans that includes the P-wave, it has indeed been anecdotally linked to electrolyte disorders,^{6,7} but it has never been attributed to hyponatremia as the main underlying disorder. However, in our patient, hyponatremia was the most pronounced electrolyte disorder (potassium and magnesium were low, but within normal limits). Moreover, during the initial assessment and follow-up, we ruled out the following potential causes of alternans: pericardial effusion, hypothermia (another “classical” cause of bizarre ECG presentations, especially when accompanied with electrolyte abnormalities)⁸, high ventricular afterload, and altered fluid status, the latter of which, along with rapid electrolyte shifts, has been associated with alterations in P-wave duration and amplitude in patients undergoing hemodialysis.⁹

4. Conclusion

Here, we reported a case of P-wave morphological changes that could be characterized as a rare example of alternans confined to the P-wave. After exclusion of other possible mechanisms, including hemodynamic, biochemical, or pathophysiological, and being aware that a strict cause-and-effect relationship cannot easily be proven in a clinical setting for a given patient, we attributed the phenomenon to hyponatremia for two reasons: i) correction was indeed

accompanied with the re-establishment of stable P-wave morphology, and ii) electrolyte disorders, although rarely, have been linked to the electrical alternans phenomena in previous studies. Fluctuating P-wave morphology, regardless of whether it is related to formal electrical alternans, should not be overlooked, but should raise suspicion about biochemical or other derangements.

Conflict of interest

None declared.

References

1. El-Sherif N, Turitto G. Electrolyte disorders and arrhythmogenesis. *Cardiol J*. 2011;18:233–245.
2. Yong TY, Huang JE, Lau SY, Li JY. Severe hyponatremia and other electrolyte disturbances associated with indapamide. *Curr Drug Saf*. 2011;6:134–137.
3. Spodick DH. Electric alternation of the heart: its relation to the kinetics and physiology of the heart during cardiac tamponade. *Am J Cardiol*. 1962;10:155.
4. Niarchos AP. Electrical alternans in cardiac tamponade. *Thorax*. 1975;30:228–233.
5. Eisenberg MJ, de Romeral LM, Heidenreich PA, Schiller NB, Evans Jr GT. The diagnosis of pericardial effusion and cardiac tamponade by 12-lead ECG. A technology assessment. *Chest*. 1996;110:318–324.
6. García Hernández N, Espinosa Caletí B. Total electrical alternans and changes in auricular repolarization in a newborn infant. *Arch Inst Cardiol Mex*. 1996;66:345–349.
7. Ishikawa K, Tateno M. Alternans of the repolarization wave in a case of hypochloremic alkalosis with hypopotassemia. *J Electrocardiol*. 1976;9:75–79.
8. Milkas A, Tsioufis K, Dimitriadis K, et al. An ECG Diagnosis Only for the Cold-Hearted. *Hellenic J Cardiol*. 2016;57(1):59–61.
9. Drighil A, Madias JE, Yazidi A, et al. P-wave and QRS complex measurements in patients undergoing hemodialysis. *J Electrocardiol*. 2008;41:60.