

Contents lists available at ScienceDirect

Trauma Case Reports

journal homepage: www.elsevier.com/locate/tcr

Case Report

Traumatic isolated perforation of lower oesophagus

Z. Mzoughi*, A. Djebbi, R. Bayar, I. Hamdi, L. Gharbi, T. Khalfallah

Department of Digestive and Hepatobiliary Surgery, Mongi Slim Hospital, La Marsa, Tunisia

ARTICLE INFO

Article history:

Accepted 2 September 2016

Available online 28 September 2016

Keywords:

Oesophageal perforation

Trauma

Pneumomediastinum

High falling

ABSTRACT

One of the rarest cases of non-iatrogenic oesophageal perforation is falling from height. We report a case of a 26 year old man with oesophageal perforation resulting from a fall of 12 meter height. A pneumomediastinum in the absence of a pneumothorax and contrast extravasation from the oesophagus on CT evoked a perforation of the aerodigestive tract. No other injuries were seen. A non-operative management was pursued with good outcomes.

© 2016 The Authors. Published by Elsevier Inc. This is an open access article under the CC BY-NC-ND license

(<http://creativecommons.org/licenses/by-nc-nd/4.0/>).

Introduction

Falling from height represents an unusual cause of oesophageal perforation. The mechanism in such high energy trauma is a brutal increase of the intra-abdominal pressure with closed glottis [1]. Diagnosis should be evoked when CT scan shows pneumomediastinum without respiratory lesion.

Patient and observation

We here in present a case of a 26 year old man, working as a building painter, victim of a 12 meter height fall. Upon arrival in the emergency department, the patient complained of retrosternal pain with no breathing problems. The patient heart rate was 90/min, his blood pressure was 110/80 mm Hg, and his respiratory rate was 18/min. Cardiopulmonary auscultation and electrocardiogram were normal. Abdominal examination showed epigastric tenderness.

Laboratory tests were normal showing a haemoglobin level at 12 g/dl, negative troponin and correct pancreatic blood tests. A body scan showed pneumomediastinum without pneumothorax or rib fractures (Fig. 1). There were no other associated injuries. A barium oesophagram showed a contrast extravasation

* Corresponding author.

E-mail address: mzeineb@yahoo.com (Z. Mzoughi).

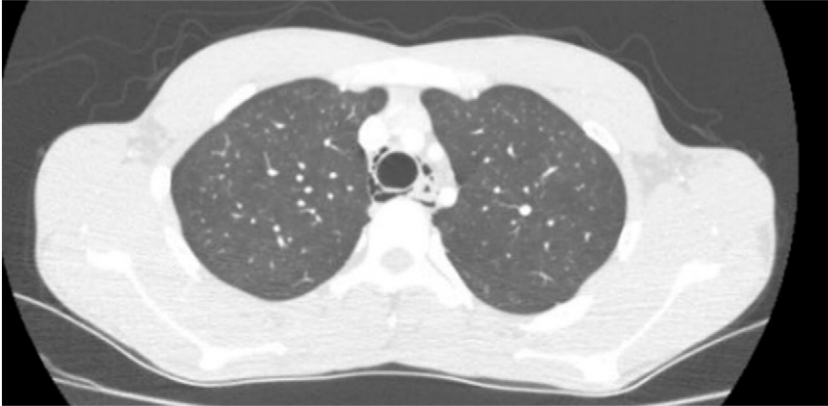


Fig. 1. CT scan showing pneumomediastinum.

in the lower oesophagus (Fig. 2). Conservative treatment was performed. It consisted of a preventive intravenous antibiotherapy, oral care and a strict parenteral nutrition.

The patient had no chest pains or digestive symptoms. The day 10 control oesophagram showed a complete regression of pneumomediastinum and no evidence of contrast extravasation (Fig. 3). Normal diet was well tolerated. The patient had no complains after one month.

Discussion

The use of CT scan has proved to be extremely efficient in early diagnosis of oesophageal perforation especially when traditional clinical signs (tachycardia, tachypnoea, dysphagia...) are missing. The injury mechanism as falling from height is important to consider. An oesophagram is indicated in the presence of a pneumomediastinum on CT scan. It shows an extravasation of the contrast medium.

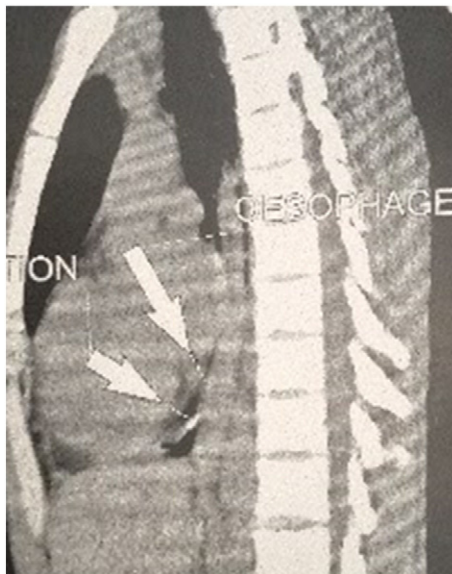


Fig. 2. Barium oesophagram showing contrast extravasation on the lower oesophagus.

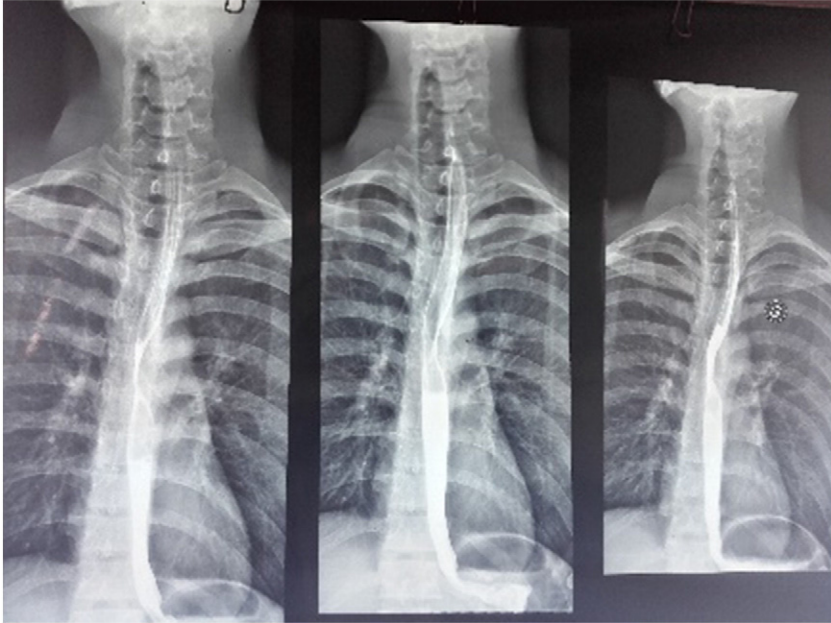


Fig. 3. Ten day's barium oesophagram showing regression of pneumomediastinum and no more contrast extravasation.

Conservative management has showed to be successful in select group of patients having no clinical signs of sepsis, like our patient, or in case of belatedly detected lesions [2]. Endoscopic placement of an oesophageal prosthesis would allow a faster refeeding [3]. Surgery remains the treatment of choice in case of any clinical instability, which ideally should be realised within the first 24 h. Survival rate goes down when treatment is delayed.

Conclusion

Non-iatrogenic oesophageal perforation, especially when is isolated, can be difficult to diagnose. Investigating and treating trauma patients should always be based on their mechanism of injury. CT scan should be done in all high falling traumas.

Conflict of interest

The author has no conflict of interest to declare.

References

- [1] N.S. Blencowe, S. Strong, A.D. Hollowood, Spontaneous oesophageal rupture, *BMJ* 346 (2013) 3095.
- [2] S.B. Vogel, W.R. Rout, T.D. Martin, P.L. Abbitt, Esophageal perforation in adults: aggressive, conservative treatment lowers morbidity and mortality, *Ann. Surg.* 241 (1016–1021) (2005) 1021–1023.
- [3] J.T. Wu, K.L. Mattox, M.J. Wall Jr., Esophageal perforations: new perspectives and treatment paradigms, *J. Trauma* 63 (5) (2007) 1173–1184.