

Contents lists available at [ScienceDirect](http://ScienceDirect.com)

Respiratory Medicine Case Reports

journal homepage: www.elsevier.com/locate/rmcr

Case report

Sarcoidosis patient with lupus pernio and infliximab-induced myositis: Response to Acthar gel

Ying Zhou ^{a, b}, Elyse E. Lower ^a, Huiping Li ^b, Robert P. Baughman ^{a, *}^a Department of Internal Medicine, University of Cincinnati Medical Center, 1001 Holmes, Eden Ave, Cincinnati, OH, 45267, USA^b Department of Respiratory Medicine, Shanghai Pulmonary Hospital, Tongji University School of Medicine, Shanghai, 200433, China

ARTICLE INFO

Article history:

Received 12 September 2015

Received in revised form

5 November 2015

Accepted 8 November 2015

Keywords:

Sarcoidosis

Myositis

Infliximab

Acthar

ABSTRACT

Infliximab is an effective treatment for sarcoidosis patients with persistent disease despite glucocorticoids and immunosuppressive therapy. Patients receiving infliximab can experience side effects, inducing an autoimmune reaction. Treatment is unclear for sarcoidosis patients who develop autoimmune reactions to infliximab. We report a case of a patient with advanced sarcoidosis who developed a myositis type reaction to infliximab characterized by diffuse muscle achiness and weakness and marked elevations in serum creatinine phosphokinase (CPK) and aldolase. Manifestations of sarcoidosis and myositis improved after Acthar treatment. This is the first report of successful treatment with Acthar in a patient with advanced sarcoidosis with an autoimmune reaction to infliximab.

© 2015 The Authors. Published by Elsevier Ltd. This is an open access article under the CC BY-NC-ND license (<http://creativecommons.org/licenses/by-nc-nd/4.0/>).

1. Introduction

Infliximab has been effective for sarcoidosis patients with persistent disease despite glucocorticoids and immunosuppressive therapy [1]. Infliximab may lead to significant side effects, including the induction of an autoimmune reaction. Therapy is unclear for patients who develop autoimmune reactions [2,3]. We report a patient with advanced sarcoidosis who developed a myositis reaction to infliximab that was successfully treated with Acthar gel.

2. Case report

In 1997 a 34-year-old African-American female patient was diagnosed with sarcoidosis after presenting with shortness of breath, cough, erythema nodosum on her legs, sinuses, uveitis, and arthritis in legs and neck. Biopsies of her leg lesions and sinuses demonstrated noncaseating granulomas, chest x-ray examination revealed adenopathy, and spirometry was within normal range.

The leg nodules resolved with initial treatment with prednisone but they recurred along with new nodules when the drug was withdrawn. She subsequently required prednisone doses ranging from 10 to 40 mg prednisone a day. In 2009, while on 10 mg prednisone a day, she developed lupus pernio with painful nodules

appearing on her cheeks and nose as well as nodules on her forearms. Despite prednisone at 40 mg per day and methotrexate, the skin lesions were uncontrolled. After a few months with minimal response, she was started on infliximab and methotrexate was discontinued because of nausea. The skin lesions improved gradually.

In 2014 her disease became more complicated when she developed diffuse muscle achiness and weakness in her legs, arms and back. The symptoms progressed despite good control of her skin lesions. Blood testing demonstrated a positive ANA with a titer of 1:640 and anti-Jo-1 antibody was present. Screening for other auto-antibodies including, anti-synthetase antibodies, was negative. Markedly elevated levels were detected for serum creatinine phosphokinase (CPK) to 3421 U/L (reference range: 30–223 U/L) (Fig. 1) and aldolase 27.5 U/L (reference range: 3.3–10.3 U/L). High resolution CT scan showed no evidence for new or advancing interstitial lung disease. Positive emission tomography was not performed. After being diagnosed with infliximab-induced myositis, infliximab was discontinued, prednisone was increased to 40 mg a day and azathioprine 100 mg a day was prescribed. After three months, the CPK level decreased to 990 U/L, but the muscle achiness and weakness did not improve. Patient noted severe side effects from the high dose prednisone including weight gain, Cushingoid features, serious sleep disturbances, and mood changes.

The patient started treatment with Acthar gel 80IU twice weekly in October 2014, concomitantly with prednisone 15 mg a day and azathioprine 100 mg a day. After six months of treatment, the skin

* Corresponding author.

E-mail address: baughmrp@ucmail.uc.edu (R.P. Baughman).

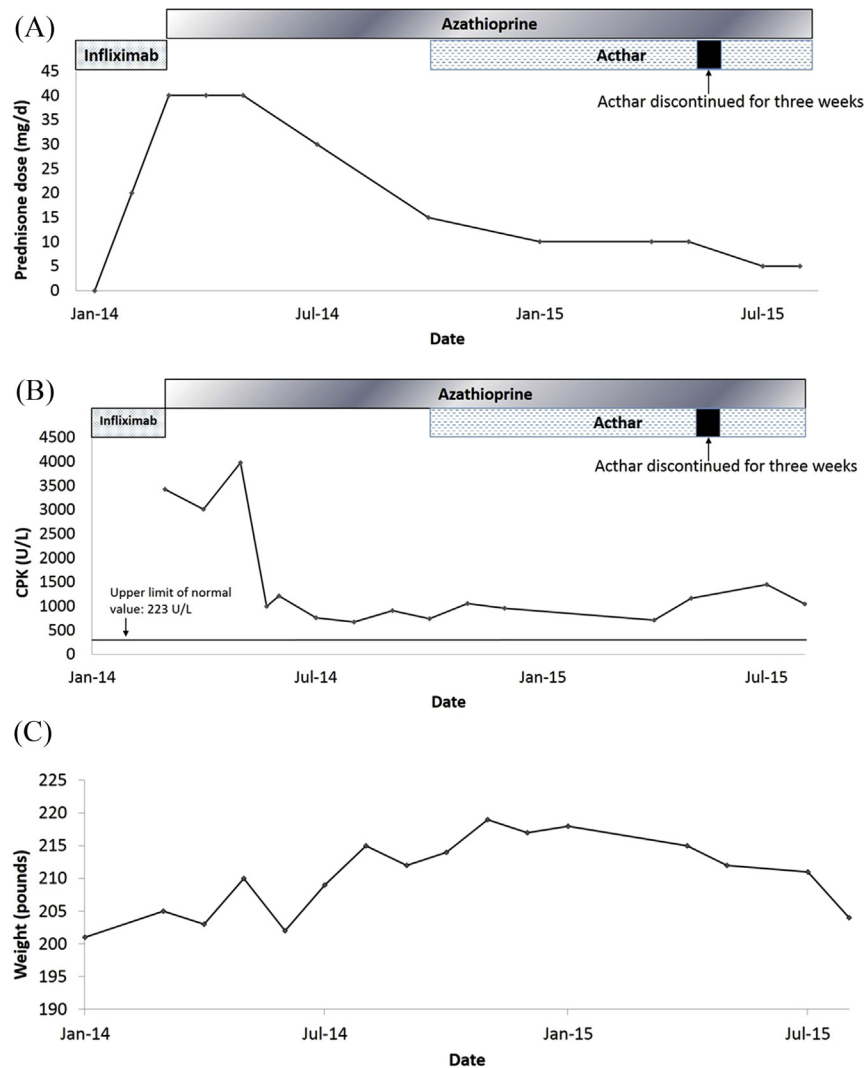


Fig. 1. Changes in various features over time with various treatments for sarcoidosis and myositis noted: (A) prednisone dose mg per day change by date; (B) creatinine phosphokinase (CPK, U/L); and (C) weight (pounds).

lesions had markedly improved with resolution of the facial lesions. She no longer experienced any musculoskeletal aches and muscle strength increased significantly. Serum CPK levels decreased to 707 U/L and aldolase normalized at 9 U/L. The patient's steroid side effects improved after the prednisone dose was reduced to 10 mg/d. She tolerated Acthar well without any significant side effects. In May 2015, Acthar gel was discontinued for three weeks due to insurance issues. Unfortunately, muscle achiness and weakness recurred and the serum CPK increased to 1449 U/L. Her skin nodules worsened on her legs. Acthar treatments were reinstated. After two months, she felt well with muscle symptoms resolved, skin lesions in near complete remission, and serum CPK reduced to 1041 U/L. At the same time, the prednisone dose was reduced to 5 mg a day, which enabled her to lose an additional 15 pounds. To date, the patient has otherwise tolerated Acthar gel treatment well.

3. Discussion

Sarcoidosis is a systemic disease that is histologically characterized by the formation of noncaseating granulomas in various organs [4]. The treatment of sarcoidosis is a challenge because the

etiology remains unknown. For most patients in whom systemic treatment is suggested, glucocorticoids remain the initial drugs of choice [5]. Although some sarcoidosis disease manifestations such as lupus pernio may respond poorly to glucocorticoids since many patients cannot tolerate the long-term treatment due to toxicity. There are several steroid-sparing agents which can be prescribed as second or third-line therapies. These include cytotoxic agents as methotrexate or azathioprine, anti-TNF agents as infliximab, or rituximab [2,6,7].

Infliximab (Remicade) is a chimeric monoclonal antibody against tumor necrosis alpha (TNF- α), which should be effective in sarcoidosis because TNF- α can be released by macrophages in active sarcoidosis and play a crucial role in the development of the sarcoidosis granuloma [8]. Infliximab has been reported effective in patients with both chronic pulmonary sarcoidosis and extrapulmonary disease [1,9].

Our patient developed the skin lesions lupus pernio from sarcoidosis. This disease manifestation is usually considered chronic and often poorly controlled by usual therapy [10]. Infliximab has been reported more effective than glucocorticoids and/or anti-metabolites in treating lupus pernio [11]. In this case, we found

infliximab to be beneficial in treating the skin manifestation which had not responded well to high doses of prednisone and prolonged use of methotrexate. After starting infliximab, the skin lesions improved for more than 3 years with no further prednisone.

Unfortunately after more than three years on single agent infliximab, the patient developed a clinical scenario compatible with drug-induced myositis. Anti-TNF drugs have been increasingly associated with the autoimmune syndromes, including lupus, vasculitis, and interstitial lung disease [12,13]. Anti-TNF-induced myositis including anti-Jo-1 antibody has been reported, but is rare [14–18]. The mechanism of how anti-TNF induced myositis is inconsistent. The most commonly cited reason is the development of an autoimmune process [12]. In addition, TNF and its receptors are overexpressed in myositis, suggesting a contribution of TNF to the pathogenesis of the disease [19]. However, blocking TNF- α could lead to disease flares in patients with inflammatory myopathies by altering the Th1 and Th2 balance [20,21]. This patient developed myositis while receiving only infliximab for her sarcoidosis. She developed new auto antibodies against both ANA and Jo-1. Both CPK and aldolase levels decreased after discontinuing the treatment. Although the reinstatement of high doses of prednisone and azathioprine controlled her symptoms, unacceptable toxicity developed, including weight gain. This led to the search for an alternative treatment for the symptoms of both sarcoidosis and myositis.

Acthar (corticotropin) was the first medication approved by the Food and Drug Administration (FDA) in the United States for the treatment of sarcoidosis [22,23]. The original sole mechanism of action was believed to be the stimulation of the adrenal gland to release glucocorticoids. However, recent studies have demonstrated that Acthar gel has direct anti-inflammatory activities and immunological effects through stimulating alternative melanocortin receptors (MCRs) [24–26]. Several reports demonstrate Acthar gel efficacy in treating multiple sclerosis and systemic lupus erythematosus [24,27]. In addition, the drug has been reported beneficial in treating some cases of advanced sarcoidosis [28]. Levine et al. reported successful treatment of five patients with refractory dermatomyositis or polymyositis [29].

This is the first report of successful treatment with Acthar gel for both manifestations of sarcoidosis and infliximab-induced myositis. We observed resolution of the sarcoidosis skin lesions, including her lupus pernio. After nine months of Acthar gel use, improvement in myositis symptoms occurred including musculoskeletal aches and muscle strength along with near normalization of serum CPK and aldolase levels. When Acthar treatment was discontinued, both muscle symptoms and enzyme levels rebounded which responded to reinstatement of Acthar gel. During the nine months of treatment, the patient tolerated the drug well without any side effects, suggesting that this treatment regimen may be more tolerable than high-dose prednisone. The encouraging result from this case suggests that Acthar gel should be considered as a therapy option for sarcoidosis or infliximab induced autoimmune diseases.

References

- [1] R.P. Baughman, M. Drent, M. Kavuru, M.A. Judson, U. Costabel, R. du Bois, et al., Infliximab therapy in patients with chronic sarcoidosis and pulmonary involvement, *Am. J. Respir. Crit. Care Med.* 174 (7) (2006) 795–802.
- [2] M. Drent, J.P. Cremers, T.L. Jansen, R.P. Baughman, Practical eminence and experience-based recommendations for use of TNF- α inhibitors in sarcoidosis, *Sarcoidosis Vasc. Diffus. Lung Dis. Off. J. WASOG/World Assoc. Sarcoidosis Other Gran. Disord.* 31 (2) (2014) 91–107.
- [3] M. Ramos-Casals, P. Brito-Zeron, S. Munoz, M.J. Soto, B.S. Group, A systematic review of the off-label use of biological therapies in systemic autoimmune diseases, *Medicine* 87 (6) (2008) 345–364.
- [4] Statement on Sarcoidosis, Joint Statement of the American Thoracic Society (ATS), the European Respiratory Society (ERS) and the World Association of Sarcoidosis and Other Granulomatous Disorders (WASOG) adopted by the ATS Board of Directors and by the ERS Executive Committee, February 1999, *Am. J. Respir. Crit. Care Med.* 160 (2) (1999) 736–755.
- [5] R.P. Baughman, H. Nunes, N.J. Sweiss, E.E. Lower, Established and experimental medical therapy of pulmonary sarcoidosis, *Eur. Respir. J.* 41 (6) (2013) 1424–1438.
- [6] R.P. Baughman, D.B. Winget, E.E. Lower, Methotrexate is steroid sparing in acute sarcoidosis: results of a double blind, randomized trial, *Sarcoidosis Vasc. Diffus. Lung Dis. Off. J. WASOG/World Assoc. Sarcoidosis Other Gran. Disord.* 17 (1) (2000) 60–66.
- [7] E.E. Lower, R.P. Baughman, Prolonged use of methotrexate for sarcoidosis, *Arch. Intern. Med.* 155 (8) (1995) 846–851.
- [8] H. Fehrenbach, G. Zissel, T. Goldmann, T. Tschernig, E. Vollmer, R. Pabst, et al., Alveolar macrophages are the main source for tumour necrosis factor- α in patients with sarcoidosis, *Eur. Respir. J.* 21 (3) (2003) 421–428.
- [9] M.A. Judson, R.P. Baughman, U. Costabel, S. Flavin, K.H. Lo, M.S. Kavuru, et al., Efficacy of infliximab in extrapulmonary sarcoidosis: results from a randomised trial, *Eur. Respir. J.* 31 (6) (2008) 1189–1196.
- [10] R.P. Baughman, M.A. Judson, A. Teirstein, E.E. Lower, K. Lo, R. Schlenker-Herceg, et al., Chronic facial sarcoidosis including lupus pernio: clinical description and proposed scoring systems, *Am. J. Clin. Dermatol.* 9 (3) (2008) 155–161.
- [11] E. Stagaki, W.K. Mountford, D.T. Lackland, M.A. Judson, The treatment of lupus pernio: results of 116 treatment courses in 54 patients, *Chest* 135 (2) (2009) 468–476.
- [12] M. Ramos-Casals, P. Brito-Zeron, S. Munoz, N. Soria, D. Galiana, L. Bertolaccini, et al., Autoimmune diseases induced by TNF-targeted therapies: analysis of 233 cases, *Medicine* 86 (4) (2007) 242–251.
- [13] M. Ramos-Casals, P. Brito-Zeron, M.J. Soto, M.J. Cuadrado, M.A. Khamashta, Autoimmune diseases induced by TNF-targeted therapies, *Best Pract. Res. Clin. Rheumatol.* 22 (5) (2008) 847–861.
- [14] J. Musial, A. Undas, M. Celinska-Lowenhoff, Polymyositis associated with infliximab treatment for rheumatoid arthritis, *Rheumatology* 42 (12) (2003) 1566–1568.
- [15] Y. Ishikawa, N. Yukawa, K. Ohmura, Y. Hosono, Y. Imura, D. Kawabata, et al., Etanercept-induced anti-Jo-1-antibody-positive polymyositis in a patient with rheumatoid arthritis: a case report and review of the literature, *Clin. Rheumatol.* 29 (5) (2010) 563–566.
- [16] R. Klein, M. Rosenbach, E.J. Kim, B. Kim, V.P. Werth, J. Dunham, Tumor necrosis factor inhibitor-associated dermatomyositis, *Arch. Dermatol.* 146 (7) (2010) 780–784.
- [17] S.W. Liu, N.F. Velez, C. Lam, A. Femia, S.R. Granter, H.B. Townsend, et al., Dermatomyositis induced by anti-tumor necrosis factor in a patient with juvenile idiopathic arthritis, *JAMA Dermatol.* 149 (10) (2013) 1204–1208.
- [18] Y. Ishikawa, N. Yukawa, D. Kawabata, K. Ohmura, T. Fujii, T. Usui, et al., A case of antisynthetase syndrome in a rheumatoid arthritis patient with anti-PL-12 antibody following treatment with etanercept, *Clin. Rheumatol.* 30 (3) (2011) 429–432.
- [19] T. Shimizu, Y. Tomita, K. Son, S. Nishinarita, S. Sawada, T. Horie, Elevation of serum soluble tumour necrosis factor receptors in patients with polymyositis and dermatomyositis, *Clin. Rheumatol.* 19 (5) (2000) 352–359.
- [20] M. Dastmalchi, C. Grundtman, H. Alexanderson, C.P. Mavragani, H. Einarsdottir, S.B. Helmers, et al., A high incidence of disease flares in an open pilot study of infliximab in patients with refractory inflammatory myopathies, *Ann. Rheum. Dis.* 67 (12) (2008) 1670–1677.
- [21] M.L. Eloranta, S. Barbasso Helmers, A.K. Ulfgren, L. Ronnblom, G.V. Alm, I.E. Lundberg, A possible mechanism for endogenous activation of the type I interferon system in myositis patients with anti-Jo-1 or anti-Ro 52/anti-Ro 60 autoantibodies, *Arthritis Rheum.* 56 (9) (2007) 3112–3124.
- [22] M.A. Miller, H.E. Bass, Effect of Acthar-c (ACTH) in sarcoidosis, *Ann. Intern. Med.* 37 (4) (1952) 776–784.
- [23] M. Sones, H.L. Israel, M.B. Dratman, J.H. Frank, Effect of cortisone in sarcoidosis, *Trans. Stud. Coll. Physicians Phila.* 18 (4) (1951) 143.
- [24] B.G. Arnason, R. Berkovich, A. Catania, R.P. Lisak, M. Zaidi, Mechanisms of action of adrenocorticotrophic hormone and other melanocortins relevant to the clinical management of patients with multiple sclerosis, *Mult. Scler.* 19 (2) (2013) 130–136.
- [25] R. Gong, The renaissance of corticotropin therapy in proteinuric nephropathies, *Nat. Rev. Nephrol.* 8 (2) (2012) 122–128.
- [26] S.A. Brod, V. Bauer, Z. Hood, A.C.T.H. Oral, (H.P. Acthar(R)Gel) inhibits IL-1 and IL-17 secretion in humans, *Biomed. Pharmacother. = Biomed. Pharmacother.* 66 (1) (2012) 36–39.
- [27] J. Fiechtner, T. Montroy, Treatment of moderately to severely active systemic lupus erythematosus with adrenocorticotrophic hormone: a single-site, open-label trial, *Lupus* 23 (9) (2014) 905–912.
- [28] R.P. Baughman, J.B. Barney, L. O'Hare, E.E. Lower, A retrospective pilot study examining the use of Acthar gel in sarcoidosis patients, *Respir. Med.* (2015) (in press).
- [29] T. Levine, Treating refractory dermatomyositis or polymyositis with adrenocorticotrophic hormone gel: a retrospective case series, *Drug Des. Dev. Ther.* 6 (2012) 133–139.