

change the National Kidney Foundation guidelines recommending early start (estimated glomerular filtration rate over 10 ml/min per m²) fail to consider the fact that dialyzer clearances have not been shown to relate to patient survival in two randomized controlled trials.² Indeed it is illogical to think that small-molecule dialyzer clearance provides a more significant benefit than a patient's own residual renal function, which provides middle molecular as well as other kidney-specific benefits. Early dialysis leads to loss of this important predictor of survival and is another reason why we caution the nephrology community to examine the wisdom of the trend to start dialysis early.

1. Bargman J. The CANUSA study and the importance of residual kidney function in dialysis patients. *Kidney Int* 2010; **77**: 931.
2. Rosansky SJ, Clark WF, Eggers P *et al.* Initiation of dialysis at higher GFRs: is the apparent rising tide of early dialysis harmful or helpful? *Kidney Int* 2009; **76**: 257–261.

Steven J. Rosansky¹, Richard J. Glassock²,
Paul W. Eggers³ and William F. Clark⁴

¹Department of Nephrology, WJBD VA Hospital, Columbia, South Carolina, USA; ²Department of Medicine, The Geffen School of Medicine at UCLA, Laguna Niguel, California, USA; ³Department of Digestive and Kidney Diseases, National Institute of Diabetes and Digestive and Kidney Diseases, Kidney and Urology Branch, Bethesda, Maryland, USA and ⁴Department of Medicine, London Health Sciences Centre, London, Ontario, Canada

Correspondence: Steven J. Rosansky, Department of Nephrology, WJBD VA Hospital, 6439 Garners Ferry Road, Columbia, South Carolina 29209, USA. E-mail: sjrcra@yahoo.com

Kidney International (2010) **77**, 931–932; doi:10.1038/ki.2010.36

The Authors Reply: We read with interest the report ‘Milky ascites is not always chylous,’¹ in which the authors attribute milky ascites in a patient with calcified sclerosing peritonitis to massive intraperitoneal amounts of calcium-hydroxyphosphate-apatite crystals and colloidal calcium-phosphate-fetuin-A complexes (calciprotein particles). We have some questions, as this is at most a seldom presentation of encapsulating peritoneal sclerosis (EPS).^{2,3} First, the authors mention that the patient's peritoneal permeability was suggestive of sclerosing peritonitis. Although this does not seem unlikely given both a long-term exposure to peritoneal dialysis (PD) and the peritoneal calcifications, a diagnosis of EPS relies on clinical and radiological grounds: bouts of recurrent, intermittent, or persisting episodes of intestinal obstructions^{2,3} with, on computed tomography scan, the presence of peritoneal thickening and calcifications, bowel wall thickening, tethering and bowel dilations, and intra-abdominal fluid loculations.⁴ Did this patient have clinical or radiological evidence of EPS? Second, more data on ascites volume, density, and concentration of other constituents (creatinine, protein, etc.) could determine whether the patient is having compartmentalized ascites (‘loculation’), with no exchanges across the peritoneal

membrane, or ‘dynamic’ recently generated ascites. The former, but not the latter, might explain the markedly elevated concentrations of calciprotein particles. Finally, it would have been of interest to test *in vitro*, in a test tube, the apparition of a similar ‘milky’ coloration by mixing huge amounts of calciprotein particles with a PD used effluent.

Given the increasing incidence of EPS,^{2,3} more data from the present case might help clinicians to recognize this complication.

1. Olde Loohuis KM, Jahnen-Dechent W, van DW. The case mid R: milky ascites is not always chylous. *Kidney Int* 2010; **77**: 77–78.
2. Brown MC, Simpson K, Kerssens JJ *et al.* Encapsulating peritoneal sclerosis in the new millennium: a national cohort study. *Clin J Am Soc Nephrol* 2009; **4**: 1222–1229.
3. Chin AI, Yeun JY. Encapsulating peritoneal sclerosis: an unpredictable and devastating complication of peritoneal dialysis. *Am J Kidney Dis* 2006; **47**: 697–712.
4. Tarzi RM, Lim A, Moser S *et al.* Assessing the validity of an abdominal CT scoring system in the diagnosis of encapsulating peritoneal sclerosis. *Clin J Am Soc Nephrol* 2008; **3**: 1702–1710.

Lionel A. Van Overmeire^{1,2}, Marie J. Rommelaere²
and Eric J. Goffin²

¹Department of Nephrology, University of Liège, University Hospital of Liège, Liège, Belgium and ²Department of Nephrology, Université Catholique de Louvain, Brussels, Belgium

Correspondence: Eric J. Goffin, Department of Nephrology, Université Catholique de Louvain, Cliniques universitaires Saint-Luc, Brussels 1200, Belgium. E-mail: eric.goffin@uclouvain.be

Kidney International (2010) **77**, 932; doi:10.1038/ki.2010.47

Tunnelled dialysis catheter tip migration in obese and large-breasted individuals: an alternative tunnelling technique as partial solution to the problem

To the Editor: In his article, Karam¹ describes the case of an obese woman with cephalad migration of the tunneled catheter tip, due to the movements of her large breast. We have observed four similar cases, with repeated catheter migration despite different tunnel sites, or suture of the Dacron cuff to the subcutaneous tissue. An alternative solution has proven efficacious in preventing catheter migration, using a double catheter with separate channelization of its two external extremities (marked as c and d in Figure 1). The surgical technique differs, as a short skin incision (b) allows the intermediate exit of the twin catheters, using the manufacturer's tunneler; a second tunneler allows for two separate exit sites. In this way, the reversed-Y morphology provides stable catheter fixation, precluding its

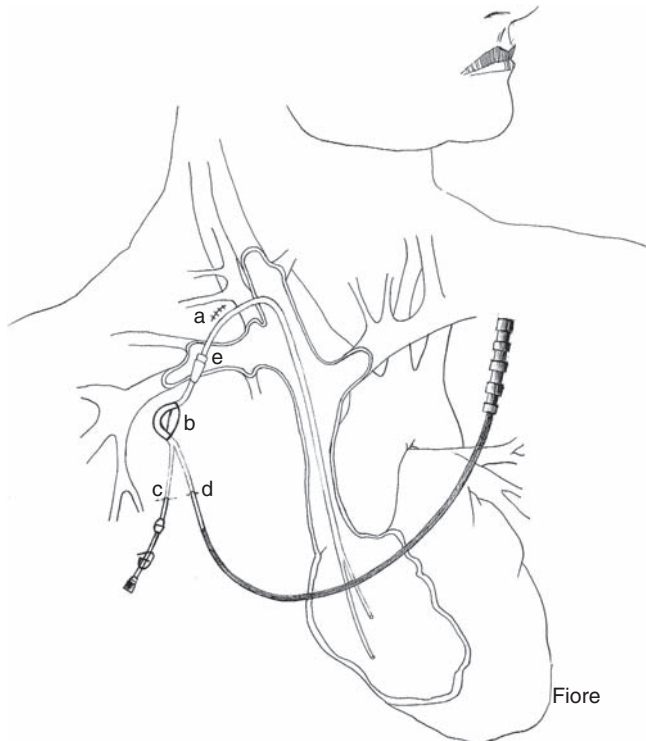


Figure 1 | Schematic drawing of the surgical technique for permanent double catheter with separate channelization of its two extremities: jugular (a) and intermediate (b) skin incisions; separate exit sites of the external branches of the catheter (c and d); Dacron cuff (e).

outside migration, except in extreme cases of forced traction or severe tissue damage between the two exit sites.

However, up to now an optimal solution for catheter fixation is still lacking; we have proposed an alternative method² whereby a special catheter sheath allows the passage of the catheter and provides its arrest; besides providing a more stable connection to patient tissues, it allows catheter substitution without surgical intervention, and precise regulation to reach an optimal position in the cardiac atrium.

ACKNOWLEDGMENTS

I thank Deborah Gilmore (debetgi@gmail.com) for English revision and Fiorella Sbizzera (nochipa2002@yahoo.it) for the hand-drawing.

1. Karam JL, Haddad FF, Medawar W *et al.* Tunneled dialysis catheter tip migration in obese and large breasted individuals. *Kidney Int* 2009; **75**: 760.
2. Bosticardo GM, Morellini V, Cravero R *et al.* Chemical or mechanical lock for tunnelled dialysis central venous catheters? *JVAccess* 2009; **10**: 68.

Gianmario M. Bosticardo¹

¹Department of Nephrology, ASL Biella, Biella, Italy

Correspondence: Gianmario M. Bosticardo, Department of Nephrology, ASL Biella, Via Caraccio 5, Biella 13900, Italy.

E-mail: nefrologia.dialisi@aslbi.piemonte.it

Kidney International (2010) **77**, 932–933; doi:10.1038/ki.2010.49