



Available online at
ScienceDirect
www.sciencedirect.com

Elsevier Masson France
EM|consulte
www.em-consulte.com/en



Original article

Reducible valgus flat-foot: Assessment of posterior subtalar joint surface displacement by posterior arthroscopy during sinus tarsi expansion screwing



N. Tarissi, A. Vallée, F. Dujardin, F. Duparc, X. Roussignol*

Rouen University Hospital, 1, rue de Germont, 76031 Rouen, France

ARTICLE INFO

Article history:

Accepted 17 September 2014

Keywords:

Flat-foot
 Subtalar joint
 Arthroscopy
 Anatomy

ABSTRACT

Introduction: Subtalar arthroereisis corrects childhood and adult reducible valgus flat-foot in certain indications. Inserting an expansion screw in the sinus tarsi simultaneously corrects the calcaneal valgus of the talocalcaneal divergence and first-ray pronation if these are reducible. The displacement induced in the posterior subtalar joint (decoaptation, translation, rotation) is, however, poorly known. The present study involved arthroscopic assessment of posterior subtalar joint surface displacement during insertion of a talocalcaneal arthroereisis screw, with the hypothesis that displacement varies in three dimensions according to screw size.

Material and method: Eight specimens were used for the study. All ankles were supple, taken from adult subjects. A 4.5-mm arthroscope was used and measurements were taken with a graduated palpator in the posterior subtalar joint. Three sinus tarsi expansion screws of incremental diameter were assessed. Before and after insertion measurements were made of posterolateral and posteromedial talar exposure on the calcaneus, anteroposterior and lateromedial translation, and talocalcaneal joint-line opening.

Results: Medial rotation, varization and anterior translation of the calcaneus were comparable in all cases. Mean lateral opening of the posterior subtalar joint was 0.88 mm with 8-mm screws and 1.25 mm with 16-mm screws. Significant differences between 8 and 16 mm screws were found for lateral subtalar joint opening ($P=0.028$) and for lateromedial translation ($P=0.004$).

Conclusion: Sinus tarsi expansion screwing corrects hindfoot valgus and talocalcaneal divergence by inducing medial translation of the calcaneus under the talus and talar medial rotation and varization, proportional to screw size (medial translation and lateral opening of the subtalar joint).

Level of evidence: III.

© 2014 Elsevier Masson SAS. All rights reserved.

1. Introduction

Reducible flat-foot in children or in adults may require surgery. Various correction procedures have been described, including subtalar arthroereisis [1–9]. The objective (Fig. 1) is to reduce calcaneal valgus and talocalcaneal divergence [10–12]. The actual 3D displacements induced in the posterior subtalar joint, however, are poorly known:

- is there valgus correction by lateral opening of the talocalcaneal joint?
- what mechanism underlies talocalcaneal divergence correction?

To the best of our knowledge, only Husain et al. [13] and Arancio et al. [14] have studied these relationships. The present study sought to make an arthroscopic assessment of posterior subtalar joint relations following insertion of a sinus tarsi expansion screw by studying the displacement of predefined landmarks. The study hypothesis was that displacements varied in 3 dimensions according to screw size.

2. Material and method

Eight specimens from adult subjects were studied: 4 right and 4 left lower limbs, amputated at the knee. All ankles were supple: reducible calcaneal valgus, absence of equinus, dorsiflexion $>15^\circ$, plantar flexion $>30^\circ$. The limb was held in a vise in ventral decubitus. A 4-mm arthroscope and 4-mm shaver were

* Corresponding author. Tel.: +33 6 21 61 55 29.

E-mail address: Xavier.Roussignol@chu-rouen.fr (X. Roussignol).

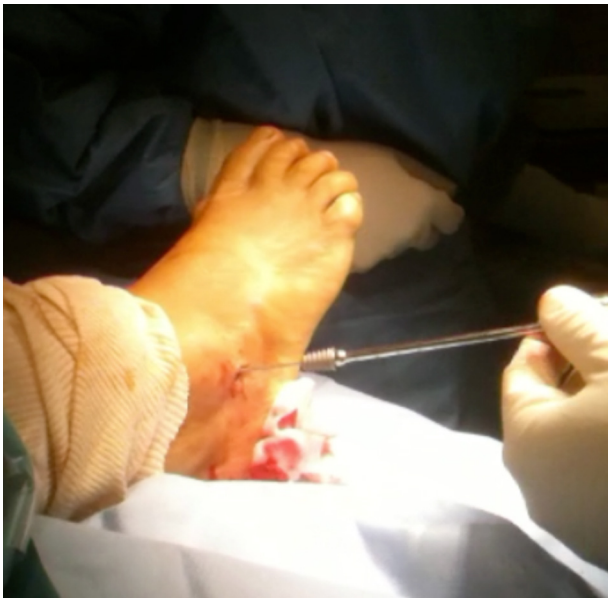

Fig. 1. Intra-operative view of expansion screw positioning in the sinus tarsi.

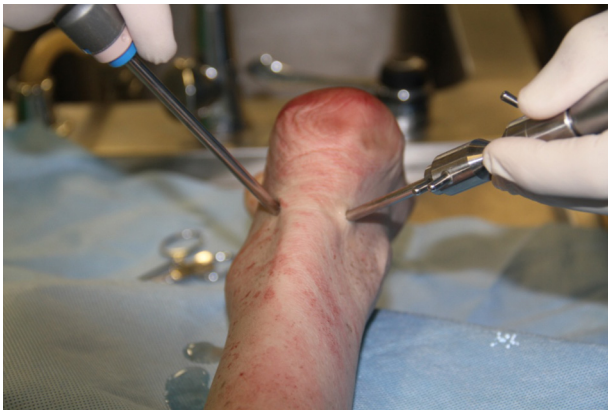

Fig. 2. Posterior ankle arthroscopy with medial and lateral para-Achilles instrumentation.

used. Measurements were taken using a palpation hook with 0.5-mm graduations, with the foot in neutral flexion-extension.

The posterior subtalar joint was approached by posterior arthroscopy following van Dijk et al. [15], with a posterolateral Achilles and posteromedial instrumental approach (Fig. 2). After subtalar joint exposure and debridement by shaver, posterior talar and calcaneal landmarking was performed by lancet (Fig. 3).

On each talar and calcaneal bone segment, 3 points were landmarked by the lancet tip (Fig. 4):

- most lateral posterior calcaneal (C lat) and talar (T lat) landmark;
- central posterior calcaneal (C cen) and talar (T cen) landmark;
- medial posterior calcaneal (C med) and talar (T med) landmark.

The tibiotalar joint space between the 3 landmarks was measured before screw insertion (Fig. 5).

Three expansion screws of length 16 mm and incremental diameter (8, 14 and 16 mm) were successively used to obtain maximal differential range of motion. A 20-mm skin incision was performed over the sinus tarsi and the screw was inserted into the sinus.

Before and after each screw insertion, the graduated hook (Fig. 6) was used to measure (in mm):

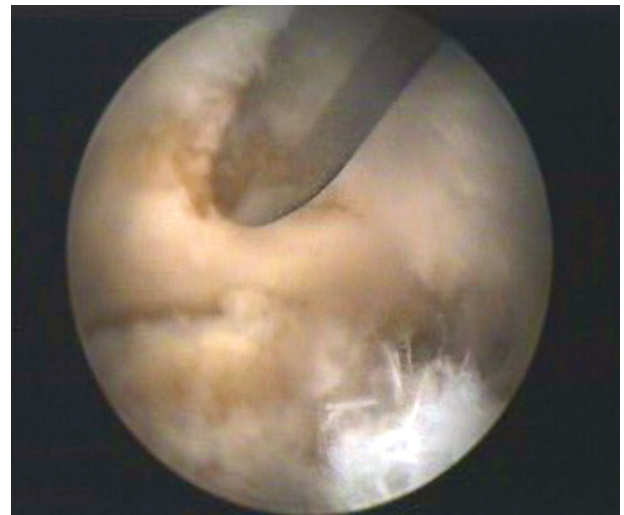

Fig. 3. Arthroscopic view of posterior subtalar joint. Posteromedial talar landmarking.

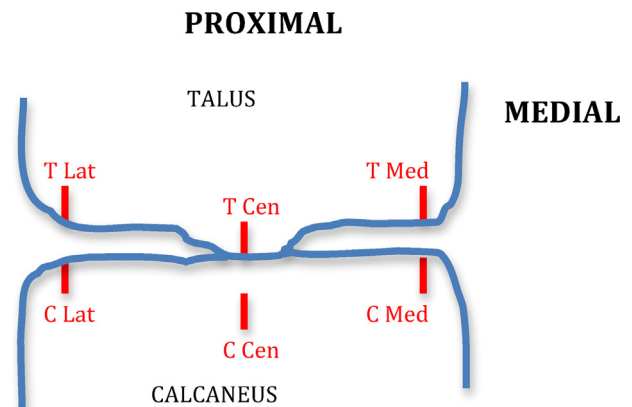


Fig. 4. Posterior arthroscopic view.

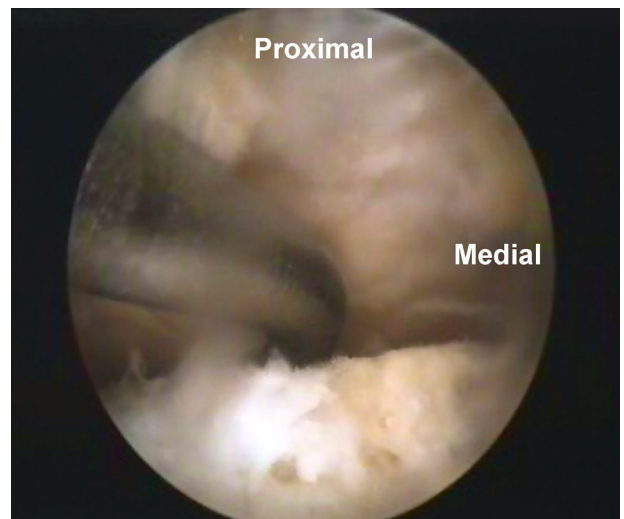


Fig. 5. Measurement of joint space between talus (above) and calcaneus (below).

- maximal posterolateral and posteromedial joint incongruence of the talus over the calcaneus: positive if the calcaneal joint surface extends beyond the talar joint surface and negative if the calcaneal joint surface no longer covers the talus;

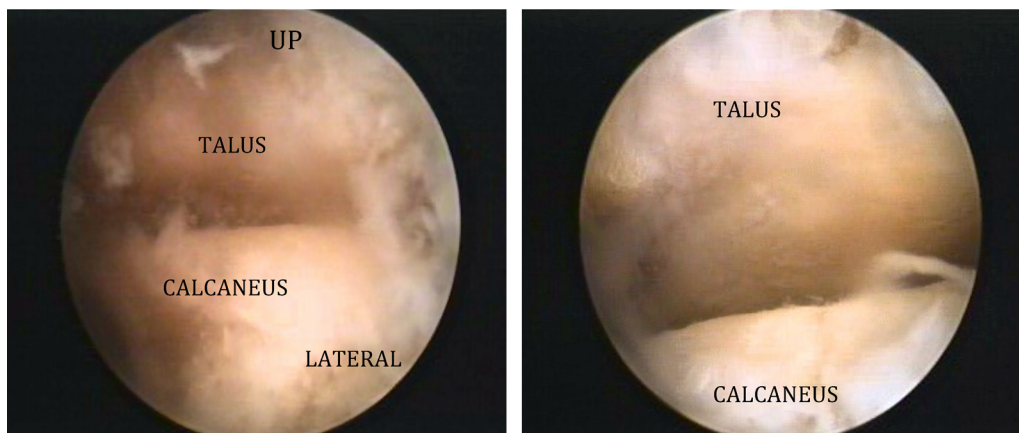


Fig. 6. Subtalar opening before and after screw insertion.

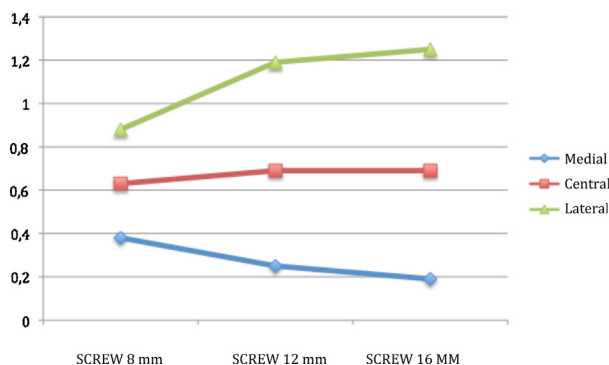


Fig. 7. Mean subtalar opening (mm) according to screw size.

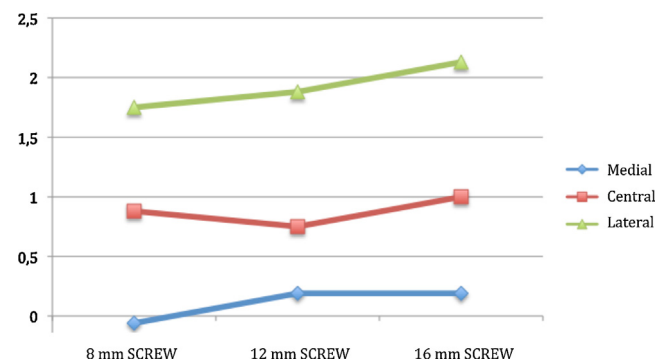


Fig. 8. Mean sagittal translation of the calcaneus (mm) according to screw size.

- calcaneal anteroposterior translation with respect to the talus, measuring the anterior translation of the medial, central and lateral calcaneal landmarks with respect to the corresponding talar landmarks: positive if the calcaneal landmark was displaced anteriorly with respect to the talar landmark;
- joint decoaptation or impingement between the medial, central and lateral calcaneal and talar landmarks;
- lateromedial translation of the central calcaneal landmark with respect to the central talar landmark, taken as fixed: positive for medial translation.

Data were analyzed on non-parametric Friedman test, with α risk = 0.05, on NCSS v.2007 and StatXact software.

3. Results

Results are presented in Table 1. All ankles showed comparable calcaneal displacement in internal rotation around a posteromedial fixed point, varization and anterior translation.

Before screw insertion, mean spontaneous joint space was 1 mm. Mean lateral posterior subtalar joint opening (Fig. 7) was 0.88 mm (range, 0.5–1.5) with 8-mm screws and 1.25 mm (0–2) with 16-mm screws. Conversely, the medial part of the joint showed impingement, with a mean joint space of 0.38 mm (0–1) with 8-mm screws and 0.19 mm (0–0.5) with 16-mm screws; in 5 ankles, medial joint space was abolished by 16-mm screws, causing direct contact between the two surfaces.

Calcaneal medial rotation under the talus was systematic (8/8 ankles), inducing positive lateral incongruence and anterior translation (Fig. 8), predominating in the lateral calcaneus. These two elements constitute the reduction of talocalcaneal divergence.

Eight and 16-mm screws showed significant differences for:

- lateral opening of the posterior subtalar joint ($P = 0.028$), 16-mm screws inducing greater opening;
- medial translation of the calcaneus ($P = 0.004$), 16-mm screws inducing greater translation.

4. Discussion

Sinus tarsi expansion screwing in reducible valgus flat-foot appears to be a logical attitude in view of the displacements obtained in the subtalar joint, which combat the acquired deformity.

Idiopathic valgus flat-foot results from collapse of the longitudinal medial arch. According to Meary and Judet [16,17], primary talar valgus ($> 10^\circ$) causes the talus to slide downward, forward and inward, increasing talocalcaneal divergence and shifting stress onto the medial column, impairing capsule and tendon stability mechanisms. The resulting abnormalities associate the talar valgus with increased talocalcaneal divergence and talar anterolisthesis over the calcaneus, relative lengthening of the medial column, tibiotalar equinus, shortening of the lateral column, compensatory forefoot supination-abduction, talar bone dysmorphia and sometimes lower limb torsion disorder [16–20].

Numerous surgical solutions [1] have been described. In 1952, Grice [21] reported extra-articular subtalar fusion with a corticocancellous graft, initially in children with poliomyelitis, later extended to childhood valgus flat-foot [22,23], with satisfactory results [24], although the procedure was relatively invasive. Later, subtalar arthroereisis techniques were developed. In 1958, Enklaar [25] reported the first subtalar implant, comprising a conical fragment of ivory. In 1961, Lelièvre [26] reported an autologous

Table 1

Results for subtalar joint movement (mm) induced according to screw size (mm), the talar bone being taken as fixed.

Number	Screw size	Joint incongruence		Sagittal translation			Joint cartilage gap			Lateral-medial translation
		Internal	External	Internal	Central	External	Internal	Central	External	
Foot 1	8	0	3	0	3	4	1	1	1	0.5
	14	0	5	0	3	5	0	1	1.5	1
	16	0	6	0	4	6	0	1	2	1.5
Foot 2	8	0	1	0	1	1	1	1	1	0
	14	1	3	2	2	3	1	1	1.5	1
	16	1	4	2	3	3	0.5	1	2	1
Foot 3	8	0	4	−0.5	0	2	0.5	1	1	1
	14	0	4	0	1	3	0.5	1	2	2
	16	0	1	0	1	3	0.5	0.5	0	4
Foot 4	8	0	1	0	−0.5	1	0	0	0.5	0
	14	0	1	0	−0.5	1	0	0	0.5	1
	16	0	1	−0.5	−0.5	2	0	0	1	1
Foot 5	8	0	0.5	0	0	0.5	0	0	0	0
	14	0	0.5	0	0	0.5	0	0	0	0.5
	16	0	0.5	0	0	0.5	0	0	0.5	0.5
Foot 6	8	0	3	0	1.5	3	0	0.5	1	0.5
	14	0	0	−0.5	−0.5	0	0.5	1	1	1
	16	0	0	−0.5	−0.5	0	0.5	1	1.5	1
Foot 7	8	0	3	0	1.5	2	0	0.5	1	0
	14	0	3	0	0.5	2	0	0.5	1.5	0.5
	16	0	3	0	0.5	2	0	1	1.5	0.5
Foot 8	8	−0.5	1	0	0.5	0.5	0.5	1	1.5	0
	14	0	1	0	0.5	0.5	0	1	1.5	1
	16	0.5	1	0.5	0.5	0.5	0	1	1.5	1
Means	8	0	2.06	−0.06	0.88	1.75	0.38	0.63	0.88	0.25
	14	0	2.19	0.19	0.75	1.88	0.25	0.69	1.19	1
	16	0	2.06	0.19	1	2.13	0.19	0.69	1.25	1.33
<i>P</i>		0.37	0.94	1	0.76	0.26	0.81	1	0.028	0.004

cylindrical cortical graft in the sinus tarsi to correct talar valgus. Later still came prosthetic implants: Silastic®, then acrylic (Valenti, 1976 [27]), steel (Grassin, 1978), and expanding acrylic and metal endo-orthoses (Giannini, 1985 [28]). The implant used in the present study was a widely used titanium model (ProStop®, Arthrex).

Indications for subtalar arthroereisis were initially restricted to childhood deformity but in recent years have been extended to adults on condition that the deformity is perfectly reducible, the foot is supple and there is no subtalar or mid-tarsal osteoarthritis. Subtalar arthroereisis may be associated to complementary procedures, such as calcaneal tendon lengthening, medial translation osteotomy of the calcaneus or repair and reinforcement of the posterior tibial tendon, depending on etiology and clinical presentation [25]. The principle consists of obtaining direct action on the pathological movement induced by the evolutive deformity by reducing talocalcaneal divergence so as to reconstitute the medial arch. Medium-term clinical results in adults appear to be good, with correction of the valgus flat-foot and resumption of normal foot-wear [29,30]. Jardé et al. [30] reported 24 good or very good results at a mean 4 years' follow-up.

The present anatomic study confirmed the movements induced by sinus tarsi expansion screwing. The calcaneus systematically underwent displacement associating medial translation, medial rotation and varization with respect to the talus. The greater the screw diameter, the greater the lateral opening of the posterior subtalar joint and the medial translation of the calcaneus ($P < 0.05$). Mean lateral opening, however, never exceeded 1.3 mm (Table 1), suggesting that it is not lateral filling by the screw that corrects the calcaneal valgus, in which case lateral opening of the subtalar joint would be greater than 5 mm. Correction of calcaneal valgus is thus essentially due to the correction of talocalcaneal divergence.

Increasing screw diameter seems to induce impingement with respect to the medial part of the talocalcaneal joint-line. The impact of this on possible osteoarthritic degeneration is unknown,

reported follow-up being insufficient. A complementary study could be performed using pressure sensors to assess it more precisely. Martinelli et al. [31] performed a similar study on the tibiotalar joint and found improved pressure distribution after subtalar arthroereisis in reducible flat-foot, but without recovering normal pressure thresholds. To the best of our knowledge, no such study has been made of the subtalar joint. It would be interesting to assess the trade-off between loss of reduction correction on ablating the distal screw and possible stress reduction in the internal part of the subtalar joint.

The risk of osteoarthritis associated with talocalcaneal arthroereisis screwing is as yet unclear: mean follow-up in most series was 4 years [7,9,30].

Beyond a certain diameter, increasing screw size seems no longer to be correlated with the quality of deformity correction. Saxena et al. [32] sought to assess retrospectively the real sizes of the sinus tarsi and of implanted screws: mean sinus tarsi diameter was 8 ± 7 mm and mean screw diameter 10.1 mm, much less than that of screws that are recommended and generally used.

5. Conclusion

The present anatomic study determined the complex pattern of movement induced by sinus tarsi expansion screwing in the treatment of reducible valgus flat-foot: varization, medial translation and medial rotation of the calcaneus under the talus. The technique thus corrects hindfoot valgus and talocalcaneal divergence.

This movement should be taken into account during treatment and in choosing the screw size. Complementary studies could assess screw impact on medial subtalar compartment stress or measure the equinus induced in the hindfoot by the sinus tarsi expansion screw, which was not possible in the present study of specimens amputated below the knee.

Disclosure of interest

The authors declare that they have no conflicts of interest concerning this article.

References

- [1] Peters PA, Sammarco GJ. Arthroereisis of the subtalar joint. *Foot Ankle* 1989;10(1):48–50.
- [2] Van Ooij B, Vos Stan CJ, Saouti R. Arthroereisis of the subtalar joint: an uncommon complication and literature review. *J Foot Ankle Surg* 2012;51(1):114–7.
- [3] Fernández de Retana P, Alvarez F, Bacca G. Is there a role for subtalar arthroereisis in the management of adult acquired flat-foot? *Foot Ankle Clin* 2012;17(2):271–81.
- [4] Wicart P, Toullec E. Pied plat valgus idiopathique. In: Seringe R, Besse J-L, Wicart P, SOFCOT, editors. *Les déformations du pied de l'enfant et de l'adulte*. Elsevier Masson; 2010 [336 p.].
- [5] Highlander P, Sung W, Weil Jr L. Subtalar arthroereisis. *Clin Podiatr Med Surg* 2011;28(4):745–54.
- [6] Metcalfe SA, Bowling FL, Reeves ND. Subtalar joint arthroereisis in the management of pediatric flexible flat-foot: a critical review of the literature. *Foot Ankle Int* 2011;32(12):1127–39.
- [7] Yen-Douangmala D, Vartivarian M, Choung JD. Subtalar arthroereisis and its role in pediatric and adult population. *Clin Podiatr Med Surg* 2012;29(3):383–90.
- [8] Vedantam R, Capelli AM, Schoenecker PL. Subtalar arthroereisis for the correction of planovalgus foot in children with neuromuscular disorders. *J Pediatr Orthop* 1998;18(3):294–8.
- [9] Schon LC. Subtalar arthroereisis: a new exploration of an old concept. *Foot Ankle Clin* 2007;12(2):329–39 [vii].
- [10] Addante JB, Chin MW, Loomis JC, Burleigh W, Lucarelli JE. Subtalar joint arthroereisis with SILASTIC silicone sphere: a retrospective study. *J Foot Surg* 1992;31(1):47–51.
- [11] Smith DK, Gilula LA, Totty WG. Subtalar arthrosis: evaluation with CT. *AJR Am J Roentgenol* 1990;154(3):559–62.
- [12] Fernández de Retana P, Alvarez F, Viladot R. Subtalar arthroereisis in pediatric flat-foot reconstruction. *Foot Ankle Clin* 2010;15(2):323–35.
- [13] Husain ZS, Fallat LM. Biomechanical analysis of Maxwell-Brancheau arthroereisis implants. *J Foot Ankle Surg* 2002;41(6):352–8.
- [14] Arangio GA, Reinert KL, Salathe EP. A biomechanical model of the effect of subtalar arthroereisis on the adult flexible flat-foot. *Clin Biomech* 2004;19(8):847–52.
- [15] Van Dijk CN, Scholten PE, Krips R. A 2-portal endoscopic approach for diagnosis and treatment of posterior ankle pathology. *Arthroscopy* 2000;16(8):871–6.
- [16] Regnauld B. *Le pied*. Berlin: Springer Verlag; 1986.
- [17] Meary R. Symposium sur le pied plat. *Ann Orthop Ouest* 1969;1:55–71.
- [18] Doncker ED, Kowalski C. *Cinésiologie et rééducation du pied*. Masson; 1979 [182 p.].
- [19] Gauthier G. Biomechanical disorder in flat-foot. *Rev Chir Orthop Reparatrice Appar Mot* 1977;63(8):736–9.
- [20] Henceroth 2nd WD, Deyerle WM. The acquired unilateral flat-foot in the adult: some causative factors. *Foot Ankle* 1982;2(5):304–8.
- [21] Grice DS. An extra-articular arthrodesis of the subastragalar joint for correction of paralytic flat feet in children. *J Bone Joint Surg Am* 1952;34(4):927–56.
- [22] Mallon WJ, Nunley JA. The Grice procedure. Extra-articular subtalar arthrodesis. *Orthop Clin North Am* 1989;20(4):649–54.
- [23] Glancy GL. Surgical management of the flat-foot. *Instr Course Lect* 1988;37:111–5.
- [24] Leidinger B, Heyse TJ, Fuchs-Winkelmann S, Paletta JRJ, Roedl R. Grice – Green procedure for severe hindfoot valgus in ambulatory patients with cerebral palsy. *J Foot Ankle Surg* 2011;50(2):190–6.
- [25] Leemrijse T, Valtin B. *Pathologie du pied et de la cheville*. Masson; 2009 [827 p.].
- [26] LeLièvre J. Current concepts and correction in the valgus foot. *Clin Orthop Relat Res* 1970;70:43–55.
- [27] Valenti V. Artrorisi sottoastragale con ortesi acrilica nel trattamento del piede piatto valgo dell'infanzia. *Minerva Ortop* 1976;27:309.
- [28] Giannini S, Girolami M, Ceccarelli F. The surgical treatment of infantile flat-foot. A new expanding endo-orthotic implant. *Ital J Orthop Traumatol* 1985;11(3):315–22.
- [29] Needleman RL. A surgical approach for flexible flatfeet in adults including a subtalar arthroereisis with the MBA sinus tarsi implant. *Foot Ankle Int* 2006;27(1):9–18.
- [30] Jardé O, Alovor G, Coursier R, Patout A, Baschti K. Pied plat réductible traité par la vis d'expansion du sinus du tarse. À propos de 30 cas. *Med Chir Pied* 2005;21(1):39–45.
- [31] Martinelli N, Marinozzi A, Schulze M, Denaro V, Evers J, Bianchi A, et al. Effect of subtalar arthroereisis on the tibiotalar contact characteristics in a cadaveric flat-foot model. *J Biomech* 2012;45(9):1745–8.
- [32] Saxena A, Nguyen A. Preliminary radiographic findings and sizing implications on patients undergoing bioabsorbable subtalar arthroereisis. *J Foot Ankle Surg* 2007;46(3):175–80.