

ENDOVASCULAR AND SURGICAL TECHNIQUES

Retroperitoneal Endoscopic Iliofemoral Cross-over Graft for Critical Limb Ischaemia

G. Stansby*, I. M. Williams and A. Darzi

Academic Surgical and Regional Vascular Unit, Imperial College School of Medicine and St. Mary's Hospital, Praed Street, London W2 1NY, U.K.

Introduction

Iliofemoral cross-over graft for critical limb ischaemia is well proven as a method of lower limb revascularisation. This report details a case where iliofemoral bypass grafting was performed endoscopically using a retroperitoneal technique which, to the authors' knowledge, has not been described previously.

Surgical Technique

The patient had rest pain in the left foot with no necrosis. Angiography had shown an occlusion of the left iliac and proximal left common femoral artery. The patient was placed supine on the operating table with a urinary catheter inserted. A 2 cm vertical infra-umbilical incision was made and a balloon dissector (Origin Medsystems, Menlo Park, California, U.S.A.) was inserted behind the rectus muscles and in front of the post rectus sheath to create the retroperitoneal space, which was maintained with CO₂ insufflation to 15 mmHg. Two further 10 mm and one 5 mm port were inserted in the right iliac fossa, midway between the pubic tubercle and the umbilicus and at the left deep inguinal ring (Fig. 1).

The right common and external iliac arteries were dissected free from the underlying vein and a proximal and distal tape applied for control. The external iliac

artery was of good quality and used as the donor vessel. Once sufficient external iliac artery was mobilised, two bulldog clamps were introduced into the retroperitoneal space via a 10 mm port and applied. An arteriotomy was made, and a 6 mm externally supported polytetrafluoroethylene (PTFE) graft was introduced via the port in the left groin. The graft and artery were apposed and anastomosed with two 4/0 prolene continuous sutures commencing at the heel. Two further single interrupted prolene sutures were required to complete haemostasis. After routine flushing, the vascular clamps were removed with excellent graft flow. A vertical incision was made in the left groin using the port site incision and an end to side anastomosis to the common femoral artery performed. After the procedure there were excellent right and left femoral pulses. Total operating time was 250 min and the blood loss was estimated to be 300 ml. The post-operative angiogram demonstrated good flow in the graft (Fig. 2).

Discussion

Recent studies have shown transfemoral placement of prosthetic aortoiliac grafts is possible, eliminating the need for an abdominal incision.¹ However, laparoscopic techniques have not yet become routine in vascular surgery.

In this case, retroperitoneal insufflation enabled excellent exposure of the iliac vessels and easy access for endoscopic suturing of the graft to the artery. Others have described ipsilateral iliofemoral bypass,

* Please address all correspondence to: Mr G. Stansby, Department of Vascular Surgery, 10th Floor, QEQM Building, St. Mary's Hospital, Praed Street, Paddington, London W2 1NY, U.K.

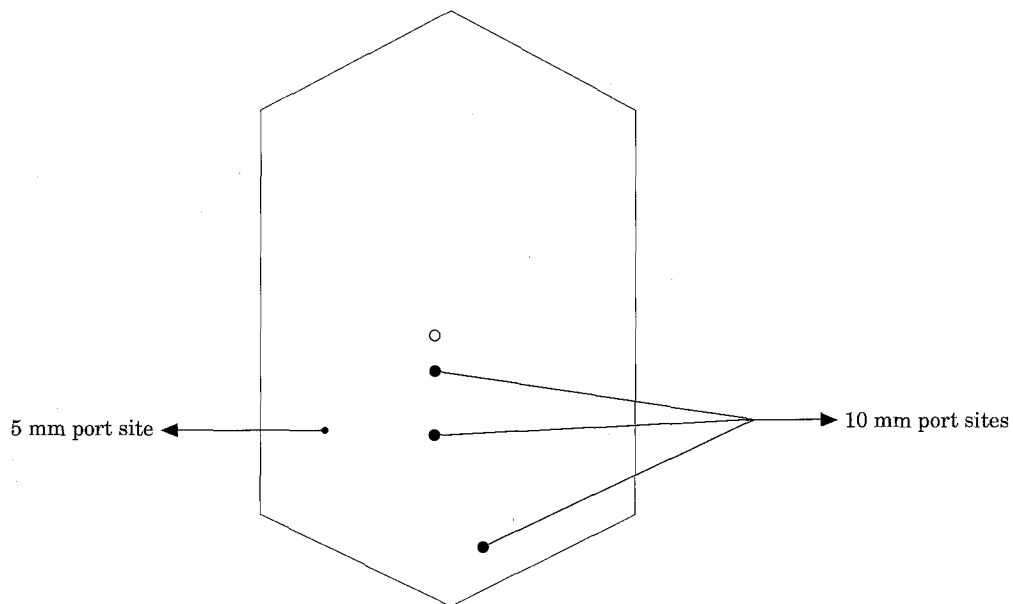


Fig. 1. Sites of entry for the three 10 mm and single 5 mm ports.

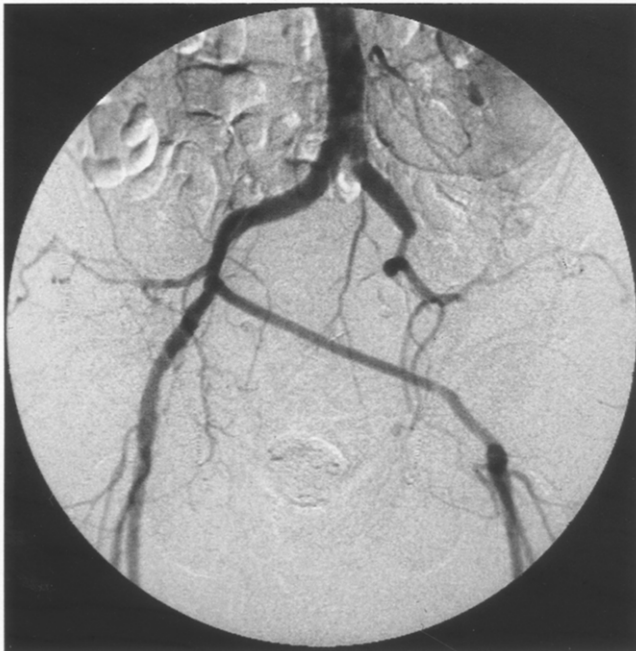

Fig. 2. Angiogram showing the completed right ilio to left femoral cross-over graft with 6 mm PTFE.

though not totally by the retroperitoneal method with similar operating times to this report.² There are also reports of laparoscopic aortobifemoral bypass successfully performed, though principally in the animal model.^{3,4} This initial experience demonstrates that laparoscopic suturing of prosthetic graft to native artery can be safely performed. There was certainly the impression of a benefit in this patient, as he was ambulant the day following surgery and was discharged on the fourth postoperative day. With further experience and improved instrumentation, including vascular clamps, operating times will shorten. However, it remains to be seen whether this technique offers any significant advantage over the traditional open technique.

References

- 1 PARODI JC, PALMAZ JC, BARONE HD. Transfemoral intraluminal graft implantation for abdominal aortic aneurysms. *Ann Vasc Surg* 1991; 5: 491-499.
- 2 BERENS ES, HERDE JR. Laparoscopic vascular surgery: four case reports. *J Vasc Surg* 1995; 22: 73-79.
- 3 AHN SS, BRAITHWAITE BD, PETRIK PV, CLEM M. Laparoscopic aortofemoral bypass. *Br J Surg* 1995; 82: 560.
- 4 DION YM, KATKHOUDA N, ROULEAU C *et al.* Laparoscopy-assisted aortobifemoral bypass. *Surg Laparosc Endosc* 1993; 3: 425-429.

Accepted 6 December 1996