

Endovascular Treatment of a Traumatic Pseudo Aneurysm of the Middle Meningeal Artery

Qaisar A. Shah and Robert W. Hurst

We describe a case of traumatic pseudoaneurysm of middle meningeal artery in a patient after a head trauma. The aneurysm was associated with epidural hemorrhage and was treated successfully with coil embolization.

Introduction

Middle meningeal artery (MMA) aneurysms are rare. They can present with epidural, sub-dural, subarachnoid, intra-parenchymal, and intra-ventricular bleeding. [1] The natural history of the MMA aneurysm is unknown but when they present in the setting of trauma and associated hemorrhage they are usually treated aggressively. We present a case of a patient who presented with MMA pseudoaneurysm and associated epidural hemorrhage and was successfully treated with coil embolization.

Case Report

A 30-year-old female was transferred from an outside hospital after she suffered a motor vehicle crash. She was found to have a left hemiparesis at the scene and withdrawal to pain on the right side. Computed tomography (CT) scan showed multiple facial, orbital and skull based fractures, 2 cm right temporal epidural hemorrhage, right subarachnoid hemorrhage, and multiple right hemispheric brain contusions (Figure 1). The epidural hemorrhage was small with no mass effect and because of its asymptomatic nature, and the patient's multiple other injuries, no immediate neurosurgical treatment was considered appropriate.

The patient improved over three days before demonstrating worsening of left hemiparesis. Angiogram at the outside hospital showed right carotid artery dissection with occlusion at the supraclinoid segment. She was transferred to our institution.

On arrival, her initial evaluation showed spontaneous eye opening, equal, round and reactive pupils, 2/5 strength in

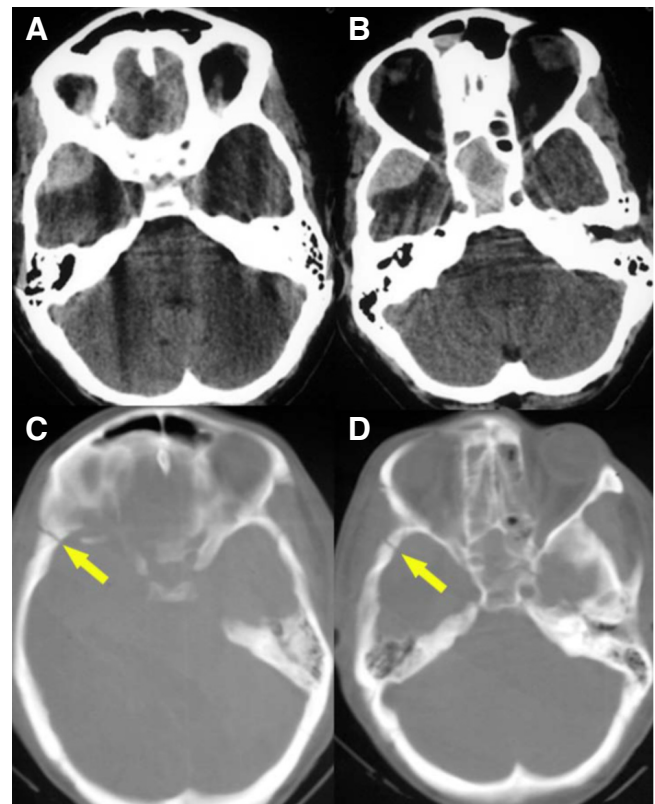


Figure 1. A & B. Non-contrast head CT, showing right temporal epidural hemorrhage. C & D. Bone window showing fracture of the right temporal bone.

Citation: Shah QA, Hurst RW. Endovascular treatment of a traumatic pseudo aneurysm of the middle meningeal artery. *Radiology Case Reports*. [Online] 2006;1:22.

Copyright: © Qaisar A. Shah. This is an open-access article distributed under the terms of the Creative Commons Attribution-NonCommercial-NoDerivs 2.5 License, which permits reproduction and distribution, provided the original work is properly cited. Commercial use and derivative works are not permitted.

Abbreviations: MMA, middle meningeal artery, CT, computed tomography, NF2, neurofibromatosis type 2, NBCA, n-butylcyanoacrylate, PVA, polyvinyl alcohol particles

Qaisar A. Shah (E-mail: qaisarshah@gmail.com) is from the Hospital University of Pennsylvania, Department of Neurology, Philadelphia, PA, United States of America.

Robert W. Hurst is from the Hospital University of Pennsylvania, Department of Radiology, Philadelphia, PA, United States of America.

DOI: 10.2484/rcr.v1i3.22

Endovascular Treatment of a Traumatic Pseudo Aneurysm of the Middle Meningeal Artery

left upper and lower extremity, normal strength on the right, with normal sensation. The next day she had an acute deterioration with unresponsiveness, fixed and dilated left pupil with decerebrate posturing on the left side. Her repeat CT scan of the head showed massive right middle cerebral artery infarction. Patient was stabilized with mannitol infusion, intubation with hyperventilation under ICP monitoring. On day six she developed an expanding right cheek hematoma. A repeat angiogram showed a pseudoaneurysm of the right facial artery as well as a 1.5 cm pseudoaneurysm of the anterior division of the right MMA (Figure 2a). Because of the potential to cause re-hemorrhage, the microcatheter was placed into the MMA under roadmapping. No selective microcatheter angiogram of the MMA was done for concern over increasing pressure in the aneurysm.

The Boston Scientific Tracker Microcatheter and Boston Scientific 5 mm fibered coils- a total of 8 coils were used to embolize pseudoaneurysms of both the right facial and MMA (Figure 2b). Coils were placed in both frontal and parietal branches of the MMA, the most distal in the frontal branch just proximal to the aneurysm. Coils in both branches were designed to prevent retrograde filling of the aneurysm, which was not observed on the post embolization angiogram (Figure 2c). Coils were brought back to close the main trunk of the MMA as well. The patient's neurological condition improved over the course of next week and she was discharged to a rehabilitation center with minimal residual left hemiparesis.

Discussion

Pseudoaneurysms of the MMA are rarely reported lesions, most often caused by trauma. Only about forty

traumatic MMA aneurysms have been reported in the literature, nearly all of which have been associated with a fracture involving the sphenoid or temporal bone in the region of the MMA [2,3]. Non-traumatic MMA aneurysms are even less common [2] and are virtually always associated with an identifiable underlying condition such as meningioma, Paget's disease, angioma, moyamoya, cavernous hemangioma, hypertension, posterior cerebral artery occlusion, dural arteriovenous malformation, or neurofibromatosis type 2 (NF2) [4-7]. Both traumatic and nontraumatic

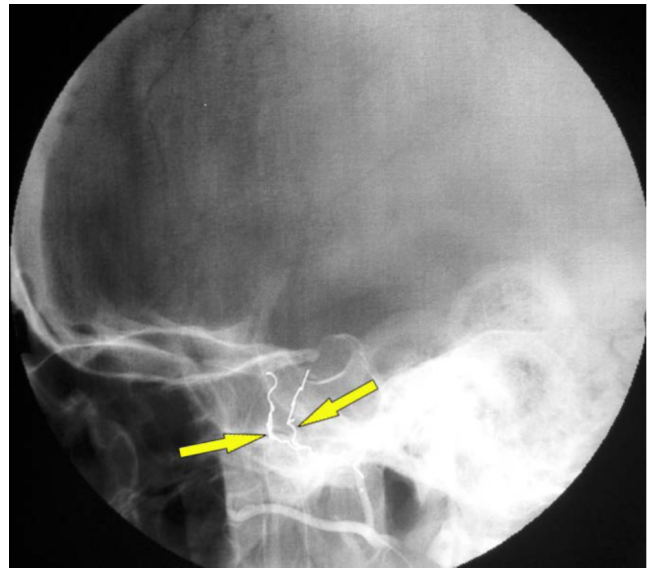


Figure 2b. Post-procedure conventional angiogram showing complete obliteration of pseudoaneurysms of both right middle meningeal and facial artery.

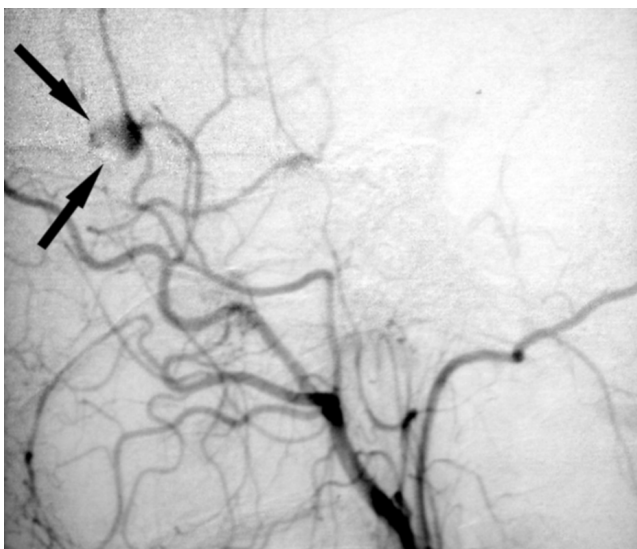


Figure 2a. Conventional angiogram showing a 1.5 cm pseudoaneurysm of the anterior division of the right middle meningeal artery.

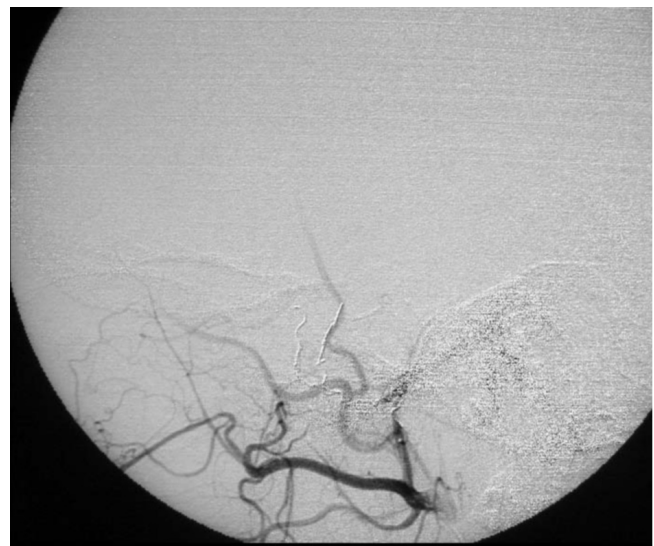

Figure 2c. Post-procedure conventional angiogram showing complete obliteration of pseudoaneurysms of both right middle meningeal and facial artery.

Endovascular Treatment of a Traumatic Pseudo Aneurysm of the Middle Meningeal Artery

MMA aneurysms are usually associated with epidural, subdural, subarachnoid, intra-cerebral, or intra-ventricular hemorrhage [8,9]. The mortality rate with traumatic pseudoaneurysm has been reported to be as high as 20-25% [2].

Histologically, a traumatic MMA pseudoaneurysm results from partial transection of the arterial wall, which because of its location, can cause epidural hemorrhage. The site of the rupture is repaired by the clot formation which contains the intraluminal blood. The sac develops by fibrous organization of the clot within a few days. Thus traumatic pseudoaneurysm may cause either early or delayed hemorrhages over a time course reported from one to thirty days in duration [2,10].

Traumatic pseudoaneurysm of the MMA was first reported by Schulze in 1957 [11]. The natural course of traumatic pseudoaneurysm is not well known, however the lesions have been associated with spontaneous rupture leading to severe hemorrhage as well as spontaneous resolution [12,13]. The potential for delayed hemorrhage with potentially fatal outcome however, has led to recommendations for aggressive treatment, particularly if associated with hemorrhage. Surgical options include ligation of the MMA, coagulation of the vessel, or resection [14].

Endovascular techniques provide additional treatment options, all of which involve MMA sacrifice with obliteration of the aneurysm. There is however, no general agreement on the choice of the specific embolic agent used to close the aneurysm and vessel. There have been case reports of the use of various materials for embolization including, gelatin sponge plugs, straight and fibered platinum coils, N-Butylcyanoacrylate (NBCA) and polyvinyl alcohol particles (PVA) [5,6,9,10,15,16]. All procedures carry a small but definite risk of immediate complications including aneurysm rupture and coil migration as well as delayed complications including rebleeding should the aneurysm remain open.

In our case the MMA aneurysm was found while performing a conventional angiogram for embolization of the facial artery. The epidural hematoma provided definite evidence of hemorrhage and it was deemed necessary to treat the MMA aneurysm as well. Coil embolization provided the ideal solution for treatment of both facial and MMA aneurysms at the same time without an additional neurosurgical procedure. Post procedure injection of the external carotid artery showed an excellent result with complete obliteration of both anterior and posterior division of the MMA and no filling of the pseudoaneurysm.

Conclusion

Traumatic pseudoaneurysm can be devastating, and should be considered in patients who present with head trauma and intracranial hemorrhage. While the choice of treatment is still under investigation, an endovascular approach appears reasonable in selected patients with MMA aneurysm of either traumatic or non-traumatic origin.

References

1. Berk, M.E., Aneurysm of the middle meningeal artery. *Br J Radiol*, 1961. 34: p. 667-8. [[PubMed](#)]
2. Bruneau, M., et al., Traumatic false aneurysm of the middle meningeal artery causing an intracerebral hemorrhage: case report and literature review. *Surg Neurol*, 2002. 57(3): p. 174-8; discussion 178. [[PubMed](#)]
3. Rumbaugh, C.L., R.T. Bergeron, and T. Kurze, Intracranial vascular damage associated with skull fractures. Radiographic aspects. *Radiology*, 1972. 104(1): p. 81-7. [[PubMed](#)]
4. Koebbe, C.J. and M.B. Horowitz, A rare case of a ruptured middle meningeal aneurysm causing intracerebral hematoma in a patient with moyamoya disease. *AJNR Am J Neuroradiol*, 2004. 25(4): p. 574-6. [[PubMed](#)]
5. Lama, M. and C. Mottolese, Middle meningeal artery aneurysm associated with meningioma. *J Neurosurg Sci*, 2000. 44(1): p. 39-41. [[PubMed](#)]
6. Lesley, W.S., M.R. Thomas, and S.I. Abdulrauf, N-butylcyanoacrylate embolization of a middle meningeal artery aneurysm in a patient with neurofibromatosis type 2. *AJNR Am J Neuroradiol*, 2004. 25(8): p. 1414-6. [[PubMed](#)]
7. Ushikoshi, S., et al., Ruptured aneurysm of the middle meningeal artery associated with occlusion of the posterior cerebral artery. Case report. *J Neurosurg*, 1996. 84(2): p. 269-71. [[PubMed](#)]
8. Albert, F.K., P. Oldenkott, and E. Sigmund, [Subarachnoid hemorrhage and intracerebral hematoma in injury of the middle meningeal artery (aneurysma spurium)]. *Zentralbl Neurochir*, 1989. 50(3-4): p. 153-6. [[PubMed](#)]
9. Kawaguchi, T., et al., Traumatic lesions of the bilateral middle meningeal arteries--case report. *Neurol Med Chir (Tokyo)*, 2002. 42(5): p. 221-3. [[PubMed](#)]
10. Jay, J., et al., Posttraumatic pseudoaneurysm of the extracranial middle meningeal artery. *Arch Otolaryngol*, 1985. 111(4): p. 264-6. [[PubMed](#)]
11. Schulze, A., [Unusual forms of epidural hematoma.]. *Zentralbl Neurochir*, 1957. 17(1): p. 40-7. [[PubMed](#)]
12. Shah, Q., J. Friedman, and A. Mamourian, Spontaneous resolution of traumatic pseudoaneurysm of the middle meningeal artery. *AJNR Am J Neuroradiol*, 2005. 26(10): p. 2530-2. [[PubMed](#)]
13. Srinivasan, A., H. Lesiuk, and M. Goyal, Spontaneous resolution of posttraumatic middle meningeal artery pseudoaneurysm. *AJNR Am J Neuroradiol*, 2006. 27(4): p. 882-3. [[PubMed](#)]

Endovascular Treatment of a Traumatic Pseudo Aneurysm of the Middle Meningeal Artery

14. Sandin, J.A., 3rd, et al., Intracerebral hemorrhage caused by the rupture of a nontraumatic middle meningeal artery aneurysm. Case report and review of the literature. *J Neurosurg*, 1999. 90(5): p. 951-4. [[PubMed](#)]
15. Meder, J.F., et al., Traumatic aneurysms of the internal and external carotid arteries. One case and a review of the literature. *J Neuroradiol*, 1992. 19(4): p. 248-55. [[PubMed](#)]
16. O'Neill, O.R., S.L. Barnwell, and D.J. Silver, Middle meningeal artery aneurysm associated with meningioma: case report. *Neurosurgery*, 1995. 36(2): p. 396-8. [[PubMed](#)]