




ELSEVIER

Contents lists available at [ScienceDirect](http://ScienceDirect.com)

## Urology Case Reports

journal homepage: [www.elsevier.com/locate/eucr](http://www.elsevier.com/locate/eucr)

## Oncology

## Voluminous Incidental Oncocytic Neoplasm of the Adrenal Gland With Uncertain Malignant Potential



Marouene Chakroun<sup>a,\*</sup>, Waïd Kerkeni<sup>a</sup>, Yosra Zidi<sup>b</sup>, Haroun Ayed<sup>a</sup>,  
Abderrazak Bouzouita<sup>a</sup>, Mohamed Riadh Ben Slama<sup>a</sup>, Sihem Rammeh<sup>a</sup>,  
Amine Derouiche<sup>a</sup>, Mohamed Chebil<sup>a</sup>

<sup>a</sup> Department of Urology, Charles Nicolle Hospital, Tunis, Tunisia<sup>b</sup> Department of Pathology, Charles Nicolle Hospital, Tunis, Tunisia

## ARTICLE INFO

## Article history:

Received 16 May 2016

Accepted 19 May 2016

## Keywords:

Adrenal gland

Oncocytic neoplasm

Uncertain malignant potential

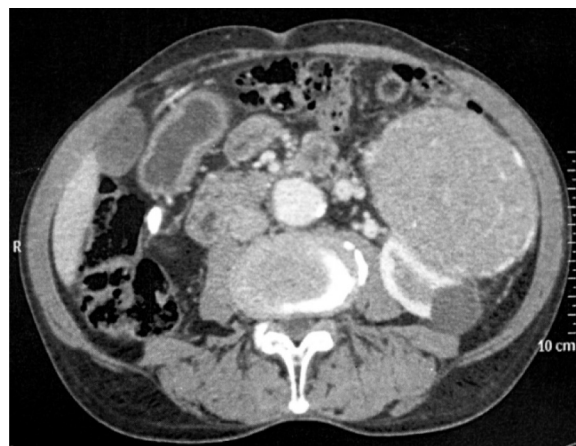## ABSTRACT

A 74-year-old man presented with right flank pain and a palpable mass in the left flank. Blood pressure was normal. Contrast-enhanced computed tomography (CT) showed a 17 × 16 × 12 cm retroperitoneal mass over the left kidney, solid and heterogeneous. There were also 3 retro aortic lymph nodes and bilateral renal lithiasis. Twenty four-hour urinary metanephrines and normetanephrines were normal. The patient underwent a resection of the mass with left adrenalectomy by a lumbar incision. Histological findings revealed an adrenal oncocytic neoplasm (AON) with uncertain malignant potential. Six months after surgery, CT control showed neither local nor distant recurrence.

© 2016 The Authors. Published by Elsevier Inc. This is an open access article under the CC BY-NC-ND license (<http://creativecommons.org/licenses/by-nc-nd/4.0/>).

A 74-year-old man presented with right flank pain and a palpable mass in the left flank. Blood pressure was normal. CT showed a 17 × 16 × 12 cm retroperitoneal mass, over the left kidney, solid, with significant contrast enhancement (Figs. 1 and 2). There were 3 retro aortic lymph nodes and bilateral renal lithiasis, the right kidney was not functional. Serum potassium and daily urinary metanephrines and normetanephrines were normal. The patient underwent a resection of the mass by a lumbar incision. Histological findings revealed an adrenal oncocytic neoplasm (AON) with uncertain malignant potential (Fig. 3). Six months after surgery, CT control showed neither local nor distant recurrence.

AON are extremely rare, tumors with uncertain malignant potential are rarer.<sup>1</sup> They are usually detected in female at the fourth decade.<sup>2</sup> Most of these tumors are non-functioning.<sup>3</sup> Imaging findings are generally non specific.<sup>4</sup> Adrenalectomy is the standard of treatment. Laparoscopy can be performed when there is no evidence of invasion into surrounding tissue and no adenopathy.<sup>5</sup> The average diameter is 8 cm. Microscopic examination shows eosinophilic and granular cells arranged in trabecular, tubular or

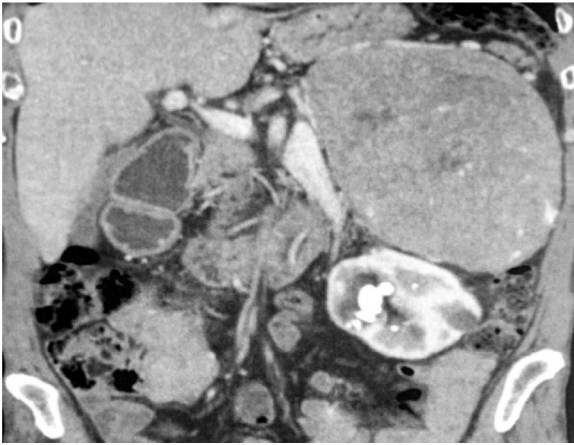


**Figure 1.** Contrast computed tomography showing a voluminous and heterogeneous supra-renal left mass.

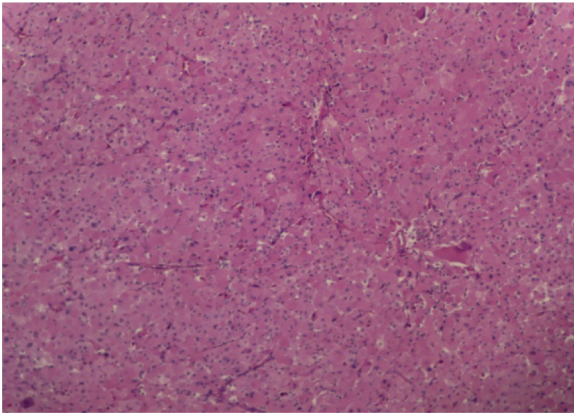
papillary patterns.<sup>6</sup> According to Weiss criteria, AONs may be in 3 histological categories. Prognosis depends on these criteria. For tumors with uncertain malignant potential, only evolution may determinate it.

\* Corresponding author.

E-mail address: [chakrounmarouene@yahoo.fr](mailto:chakrounmarouene@yahoo.fr) (M. Chakroun).



**Figure 2.** Contrast computed tomography showing a voluminous and heterogeneous supra-renal left mass.



**Figure 3.** The tumor cells have an oncocytic appearance with abundant eosinophilic, granular cytoplasm and nuclear pleomorphism.

### Conflict of interest

There is no conflict of interest.

### References

1. Mearini L, Del Sordo R, Costantini E, et al. Adrenal oncocytic neoplasm: a systematic review. *Urol Int.* 2013;91:125–133.
2. Lin BT, Bonsib SM, Mierau GW, et al. Oncocytic adrenocortical neoplasms. A report of seven cases and review of the literature. *Am J Surg Pathol.* 1998;22:603–614.
3. Wong DD, Spagnolo DV, Bisceglia M, et al. Oncocytic adrenocortical neoplasms – A clinicopathologic study of 13 new cases emphasizing the importance of their recognition. *Hum Pathol.* 2011;42:489–499.
4. Shah RK, Oto A, Ozkan OS, et al. Adrenal oncocytoma: US and CT findings. *JBR-BTR.* 2004;87:180–182.
5. Rosenkrantz AB, Do RK, Hajdu CH. Imaging appearance of bulk fat within an oncocytic adrenocortical neoplasm, a rare and potentially malignant tumour. *Br J Radiol.* 2010;83:204–207.
6. Schittenhelm J, Ebner FH, Harter P, Bornemann A. Symptomatic intraspinal oncocytic adrenocortical adenoma. *Endocr Pathol.* 2009;20:73–77.