

ORIGINAL RESEARCH

Atherosclerosis in Ancient Egyptian Mummies

The Horus Study

Adel H. Allam, MD,* Randall C. Thompson, MD,†‡ L. Samuel Wann, MD,§
Michael I. Miyamoto, MD, MS,¶|| Abd el-Halim Nur el-Din, PhD,#**
Gomaa Abd el-Maksoud, PhD,# Muhammad Al-Tohamy Soliman, PhD,††
Ibrahem Badr, PhD,‡‡ Hany Abd el-Rahman Amer, PhD,†† M. Linda Sutherland, MD,§§
James D. Sutherland, MD, MS,||| Gregory S. Thomas, MD, MPH||¶¶
*Cairo, Alexandria, and Giza, Egypt; Kansas City, Missouri; Milwaukee, Wisconsin; and
Mission Viejo, San Diego, Newport Beach, Laguna Hills, and Orange, California*

OBJECTIVES The purpose of this study was to determine whether ancient Egyptians had atherosclerosis.

BACKGROUND The worldwide burden of atherosclerotic disease continues to rise and parallels the spread of diet, lifestyles, and environmental risk factors associated with the developed world. It is tempting to conclude that atherosclerotic cardiovascular disease is exclusively a disease of modern society and did not affect our ancient ancestors.

METHODS We performed whole body, multislice computed tomography scanning on 52 ancient Egyptian mummies from the Middle Kingdom to the Greco-Roman period to identify cardiovascular structures and arterial calcifications. We interpreted images by consensus reading of 7 imaging physicians, and collected demographic data from historical and museum records. We estimated age at the time of death from the computed tomography skeletal evaluation.

RESULTS Forty-four of 52 mummies had identifiable cardiovascular (CV) structures, and 20 of these had either definite atherosclerosis (defined as calcification within the wall of an identifiable artery, $n = 12$) or probable atherosclerosis (defined as calcifications along the expected course of an artery, $n = 8$). Calcifications were found in the aorta as well as the coronary, carotid, iliac, femoral, and peripheral leg arteries. The 20 mummies with definite or probable atherosclerosis were older at time of death (mean age 45.1 ± 9.2 years) than the mummies with CV tissue but no atherosclerosis (mean age 34.5 ± 11.8 years, $p < 0.002$). Two mummies had evidence of severe arterial atherosclerosis with calcifications in virtually every arterial bed. Definite coronary atherosclerosis was present in 2 mummies, including a princess who lived between 1550 and 1580 BCE. This finding represents the earliest documentation of coronary atherosclerosis in a human. Definite or probable atherosclerosis was present in mummies who lived during virtually every era of ancient Egypt represented in this study, a time span of $>2,000$ years.

CONCLUSIONS Atherosclerosis is commonplace in mummified ancient Egyptians. (J Am Coll Cardiol Img 2011;4:315–27) © 2011 by the American College of Cardiology Foundation

From the *Al Azhar Medical School, Cairo, Egypt; †St. Luke's MidAmerica Heart Institute, Kansas City, Missouri; ‡University of Missouri-Kansas City School of Medicine, Kansas City, Missouri; §Wisconsin Heart Hospital, Milwaukee, Wisconsin; ||Mission Internal Medical Group, Mission Viejo, California; ¶University of California, San Diego School of Medicine, San Diego, California; #Cairo University, Cairo, Egypt; **Bibliotheca Alexandrina, Alexandria, Egypt; ††National Research Center, Giza, Egypt; ‡‡Institute of Restoration, Alexandria, Egypt; §§Newport Diagnostic Center, Newport Beach, California; |||South Coast Radiologic Medical Group, Laguna Hills, California; and the ¶¶University of California, Irvine School of Medicine, Orange, California. This work was funded by the Paleocardiology Foundation from contributions by Siemens, the National Bank of Egypt, St. Luke's Hospital Foundation, and various individual donors. All authors have reported that they have no relationships to disclose.

Manuscript received January 8, 2011; revised manuscript received January 26, 2011, accepted February 1, 2011.

Cardiovascular diseases are the world's largest killers, claiming >17 million lives in 2010. Our 21st century epidemic of cardiovascular disease continues to spread from wealthy, developed areas of the world to poorer, developing countries (1). Deaths due to cardiovascular diseases, primarily related to an increase in the prevalence of atherosclerosis, is projected to increase to >23 million per year by 2030 (2). As the diet, lifestyle, and environmental risk factors for the development of atherosclerosis spread from developed nations to the rest of the world, cardiovascular disease follows. It is tempting to conclude that atherosclerotic cardiovascular disease is exclusively a disease of modern society and did not affect our ancient ancestors. The findings of the present study provide evidence to the contrary.

Atherosclerosis was first identified in ancient Egyptians when Johann Nepomuk Czermak found calcific aortic atherosclerosis during an autopsy of the mummy of an elderly Egyptian woman in 1852 (3). One hundred years ago, Sir Marc Armond Ruffer also identified histologic evidence of atherosclerosis in the aorta as well as in other large arteries on autopsies performed on multiple 3,000-year-old Egyptian mummies (4). In 1931, Allen Long examined the heart of Lady Teye, a mummy in the collection of the Metropolitan Museum in New York, who lived during the 21st dynasty (1070 to 945 BCE), finding histologic evidence of coronary atherosclerosis, with intimal thickening and calcification in the epicardial coronary arteries, as well as areas of fibrosis in the myocardium consistent with prior myocardial infarction (5). Anatomists and physicians commonly performed autopsies of Egyptian mummies a century ago, but these have since fallen out of favor given the destructive nature of the process.

Atherosclerosis emanates from a complex interplay of genes and environment (6-8), and the etiology of the ongoing epidemic is certainly multifactorial. However, the study of ancient Egyptian mummies may provide unique insights into the ancestral origins of atherosclerosis. We (9,10) and others (11) have begun to use modern X-ray computed tomography (CT) to examine these ancient humans in a nondestructive fashion. We report here our findings using CT to systematically search for evidence of arterial calcification as a marker for cardiovascular disease in 52 ancient Egyptian mummies.

METHODS

Study population. We, the Horus study team, performed whole body 6-slice CT using a Siemens Emotion 6 (Florsheim, Germany) on 45 mummies housed in (or in the case of 2 of these mummies, brought to) the Egyptian National Museum of Antiquities in Cairo. We selected adult mummies for inclusion from multiple historical eras from the museum's collection of 120 to 140 mummies on the basis of their apparent good state of preservation, which was expected to increase the likelihood that intact vascular tissue would be present. We did not randomly select mummies for inclusion. The vascular bed findings of mummies #1 through #22 have been reported in brief previously (9). In the current publication, the cardiovascular findings of these mummies, as well as the additional 30 mummies, are described in greater detail after comprehensive review of the entire 52-mummy cohort.

We scanned 42 mummies specifically for this study in February 2009 and May 2010. We also included 3 additional mummies housed in the Egyptian National Museum of Antiquities. They were included in this study because cardiovascular tissue was known to be present in 2 mummies, and 1 mummy was the subject of a post-graduate thesis of 1 of the authors (I.B.).

We obtained demographic information through an extensive search of museum and other resources by a team of experienced Egyptologists and experts in mummy restoration (I.B., G.A.M., and A.H.N.). We determined sex through biological anthropologic assessment of the genital/reproductive organs and morphology of the pelvis, femur, and skull. A biologic anthropologist (M.A.T.S.) estimated the age at death through integrative assessment of the architectural changes in the clavicle, humerus, and femur (12,13). If all of these bones were available, and each method resulted in the same age, he estimated a specific age. If only 2 of 3 methods were concordant, he estimated an age range. If bones were available for only 2 methods and were concordant, he also provided an age range. If only 2 methods were applicable and were discordant, he provided a larger age range.

The Egyptian/U.S. research team submitted a formal scientific proposal, written in Arabic, for each individual expedition to the Supreme Council of Antiquities of Egypt, a body of 70+ professors of Egyptology. The team was granted approval for each proposal, including the ability to image the mummies, by majority vote. We obtained clinical

ABBREVIATIONS AND ACRONYMS

CT = computed tomography

CV = cardiovascular

informed consent from the contemporary human patients whose CT images we used for comparison.

CT imaging. We used the Siemens Emotion 6 scanner to image the 45 mummies at the Museum of Antiquities. We imaged the thorax, abdomen, pelvis, and extremities at 130 kv with 1.25 mm collimation and 50% overlap. We imaged the head and neck at 130 kv with 0.6 mm collimation and 50% overlap. Using a similar technique with a GE LightSpeed-Plus 4-slice scanner (Pewaukee, Wisconsin), we also scanned 6 Egyptian mummies at the Bowers Museum (Santa Ana, California) and were provided the images from a GE LightSpeed Ultra 8-slice scanner of another Egyptian mummy currently housed at the Nelson-Atkins Museum (Kansas City, Missouri). Therefore, the total sample comprised 52 mummies.

Image interpretation. Seven experienced cardiovascular imaging physicians (A.H.A., M.I.M., J.D.S., M.L.S., G.S.T., R.C.T., and L.S.W.) collaboratively identified cardiovascular tissue and ascertained the presence or absence of calcification in the vessel walls and heart. Image reformatting and measurements of the thickness and X-ray attenuation (Hounsfield units) of various structures were made using a Siemens multimodality imaging workstation. The Apple platform OsiriX DICOM viewing software (version 3.81, Geneva, Switzerland) was also utilized to facilitate consensus image review. Vascular tissue and the heart were identified by their anatomic position in the body and relationship to contiguous structures, enhanced by the use of 3-dimensional multiplanar reconstruction and maximum intensity projection reconstructions. The presence of calcification in the vessel wall was defined qualitatively by comparing multiple regions within visualized cardiac and vascular tissue to one another. Noncontrast CT images obtained from 2 contemporary patients with known vascular disease were included for comparison and illustration and to help identify anatomic landmarks.

As described previously (9), calcification in the vessel wall of a clearly identifiable artery was considered diagnostic of atherosclerosis. Calcification along the expected course of an artery was considered to be probable atherosclerosis.

Arterial vascular regions were divided into the 5 distinct beds modified from the method of Allison et al. (14): the carotid, coronary, aortic, iliac, and femoral/popliteal/tibial (termed peripheral) vascular beds.

Statistical analysis. Statistical analysis was performed using SPSS software (version 16 for Mac,

Chicago, Illinois). A p value <0.05 was considered significant. We investigated possible sex differences in age at death, and atherosclerosis status, using Student t and chi-square tests, respectively. We also used individual binary logistic regressions to determine whether the odds of having atherosclerosis would increase with advancing age and be greater in later chronological eras. We used chi-square to test the potential (11,15) that priests/priestesses would be more likely to have atherosclerosis than non-clergy. Lastly, among the subset of mummies who had atherosclerosis, we tested the hypothesis that older mummies would have a more severe form of the disease (as defined by greater number of vascular beds affected) using chi-square. For this analysis, we divided the sample into those younger versus older than 40 years, as this age threshold is consistent with an accepted risk factor for coronary artery disease and was roughly equivalent to the mean age of death in the present sample.

RESULTS

Sample characteristics. The demographics and cardiovascular findings of the 52 ancient Egyptian mummies are displayed in Table 1. Online Supplemental Table 1 complements this table with the place of excavation and the museum ascension number. The mummies lived between 1981 BCE and 364 CE. Mean estimated age at death was 38.1 ± 12.0 years (ranging from 10 to 60+ years). Sex could be determined for all except for the youngest 2 mummies who were prepubescent. The mean age at death did not differ by sex (40.0 ± 10.2 years for the 33 men, and 37.6 ± 12.4 years for the 17 women, $p = 0.26$). We determined the social position for 25 mummies, and each of these was of high socioeconomic status. Again, although the social position of the remaining 27 mummies is unknown, the financial costs of mummification suggest that they too were likely of high socioeconomic status. We determined the place of excavation for 43 mummies. Each of these was excavated either near the Nile River or at an oasis in Upper Egypt, an area that is now the southern part of modern Egypt.

Computed tomography images demonstrated identifiable vascular tissue in 43 mummies. An intact heart or heart remnants could be identified in 31 mummies. One mummy had an intact heart without vessels present, yielding 44 mummies with cardiovascular (CV) tissue who could be evaluated for atherosclerosis (27 male, 16 female, 1 unknown).

Table 1. Mummy Demographic Data and Cardiovascular Findings

Mummy #/ Sex/ Age (yrs)	Name	Social Position/ Occupation	Period	Period Years	Vascular Tissue (● = Present)	○ = Remnants of Heart; ● = Intact Heart	Atherosclerosis (● = Definite; ○ = Probable)	Carotids (▲ = Calcification Seen in Vascular Bed)	Coronaries	Aorta	Iliac	Femoral/ Popliteal/ Tibial
1/F/45–50	Shtwsk	Unknown	Greco-Roman	332 BCE–364 CE	●	●	○					▲
2/F/60+	Unknown	Unknown	Ptolemaic	304–30 BCE	●		○	▲				▲
3/M/50+	Unknown	Unknown	Greco-Roman	332 BCE–364 CE	●		○	▲				▲
4/F/25–30	Unknown	Unknown	Greco-Roman	332 BCE–364 CE	●							
5/F/30–40	Rai	Nurse of Queen	New Kingdom, 18th Dynasty	1570–1530 BCE	●	●	●			▲		
6/M/30–35	Tauhert	Unknown	3rd Intermediate	1070–712 BCE								
7/M/30–35	Unknown	Unknown	Ptolemaic	304–30 BCE	●							
8/F/25–30	Unknown	Unknown	Late	712–343 BCE	●	●						
9/F/25–30	Tarepet	Daughter of Nestefet	Late	712–343 BCE	●							
10/M/50–60	Wedjarenes	Unknown	Late	712–343 BCE	●							
11/M/50–60	Nesmin	Son of Irheru	Ptolemaic	304–30 BCE	●	○	○					▲
12/M/50–60	Djeher	Unknown	Ptolemaic	304–30 BCE	●	●	●	▲	▲	▲		▲
13/M/45–50	Nesitanebetawy	Priest of Amun	3rd Intermediate	1070–712 BCE			○					
14/M/30–35	Tjanefer	Priest of Amun	3rd Intermediate	1070–712 BCE	●	○	●			▲		
15/M/25–30	Nesimut	Priest of Amun	3rd Intermediate	1070–712 BCE								
16/M/25–30	Paduimen	Priest of Amun	3rd Intermediate	1070–712 BCE								
17/M/30–35	Nesinebtawy	Priest of Amun	3rd Intermediate	1070–712 BCE			○					
18/M/30–35	Esankh	Priest of Amun	3rd Intermediate	1070–712 BCE	●							
19/F/25–30	Amanit	Priestess of Hathor	Middle Kingdom, 11th Dynasty	1981–1802 BCE			○					
20/M/30–35	Unknown	Unknown	Ptolemaic	304–30 BCE		●						
21/M/50–60	Anonymous	King's Minister	New Kingdom, 18th Dynasty	1550–1295 BCE	●	○	●					▲
22/F/50–60	Anonymous	Wife of King's Minister	New Kingdom, 18th Dynasty	1550–1295 BCE	●	○	●			▲	▲	▲
23/M/45	Hatiay	Scribe	New Kingdom, 18th Dynasty	1550–1295 BCE	●		●	▲		▲	▲	▲
24/M/25–30	Maiherpri	Nubian Prince	New Kingdom, 18th Dynasty	1550–1295 BCE	●	○						
25/F/40–45	Isis	Singer	New Kingdom, 19th Dynasty	1295–1186 BCE	●							
26/M/50–55	Unknown	Unknown	New Kingdom, 18th Dynasty	1550–1295 BCE	●	●						
27/M/25–30	Unknown	Unknown	New Kingdom, 18th Dynasty	1550–1295 BCE	●	●	●			▲		
28/M/40–45	Unknown	Unknown	Late	ca. 688–332 BCE	●							

Continued on next page

Table 1. Continued

Mummy #/ Sex/ Age (yrs)	Name	Social Position/ Occupation	Period	Period Years	Vascular Tissue (● = Present)	○ = Remnants of Heart; ● = Intact Heart	Atherosclerosis (● = Definite; ○ = Probable)	Carotids (▲ = Calcification Seen in Vascular Bed)	Coronaries	Aorta	Iliac	Femoral/ Popliteal/ Tibial
29/M/45-50	Unknown	Unknown	Late	ca. 688-332 BCE	●	●	●			▲		▲
30/M/45-50	Unknown	Unknown	Late	ca. 688-332 BCE	●							
31/M/45-50	Djedhor, Son of Nesihor	King	Late	380-343 BCE	●	○	○	▲		▲		▲
32/M/30	Unknown	Unknown	Greco-Roman	332 BCE-364 CE	●							
33/F/40-50	Unknown	Queen	New Kingdom, 18th Dynasty	1550-1295 BCE	●	●	○	▲		▲	▲	▲
34/F/40-45	Ahmose- Henttamehu	Queen	2nd Intermediate, 17th Dynasty	1580-1550 BCE	●	●	●			▲		
35/F/40-45	Unknown	Princess	2nd Intermediate, 17th Dynasty	1580-1550 BCE	●	●	●	▲	▲	▲	▲	▲
36/F/20-25	Ahmose- Henutempet	Princess	2nd Intermediate, 17th Dynasty	1580-1550 BCE	●	○						
37/F/19	Unknown	Unknown	Roman	30 BCE-364 CE	●	○						
38/F/45-50	Unknown	Unknown	Unknown	Unknown	●	●	●			▲	▲	
39/M/35-40	Unknown	Unknown	Unknown	Unknown	●	●						
40/M/45-50	Nebsy	Unknown	New Kingdom	ca. 1550-1070 BC								
41/M/35-40	Djedhor	Unknown	Unknown	Unknown	●	●	●	▲		▲		
42/F/45-50	Taditbastet	Unknown	3rd Intermediate, 25th Dynasty	ca. 700 BCE	●	●	○		▲	▲	▲	
43/F/20-25	Shauenimes	Unknown	3rd Intermediate, 22nd Dynasty	945-710 BCE	●	○						
44/M/25-30	Unknown	Unknown	Late	ca. 688-332 CE	●		○					▲
45/?/12	Tjayasetimu	Singer of Interior of Amun	3rd Intermediate, 22nd Dynasty	ca. 900 BCE	●	●						
46/M/45-50	Padiametet	Doorkeeper of Re, Thebes	3rd Intermediate, 25th Dynasty	ca. 700 BCE	●							
47/M/40-45	Shepenmehyt	Sistrum Player Temple of Amun Re	Saite, 26th Dynasty	ca. 600 BCE	●							
48/M/40-50	Irthorru	Priest of Akhmim	Saite, 26th Dynasty	ca. 600 BCE	●	○						
49/?/10	Unknown	Unknown	Roman	ca. 40-55 CE								
50/M/20-25	Unknown	Unknown	Roman	ca. 140-180 CE	●	○						
51/M/45-55	Unknown	Unknown	Late Intermediate	500 BCE	●							
52/M/25-30	Gitbetah	High Priest of Amun	3rd Intermediate, 23rd Dynasty	828-725 BCE	●	○						

Mummies were numbered in the order that they were scanned and/or their images reviewed. This numbering system differs from the one employed in our previous report (9), in which mummies were ordered by estimated chronological age. See the Online Appendix for place of excavation and museum accession number.

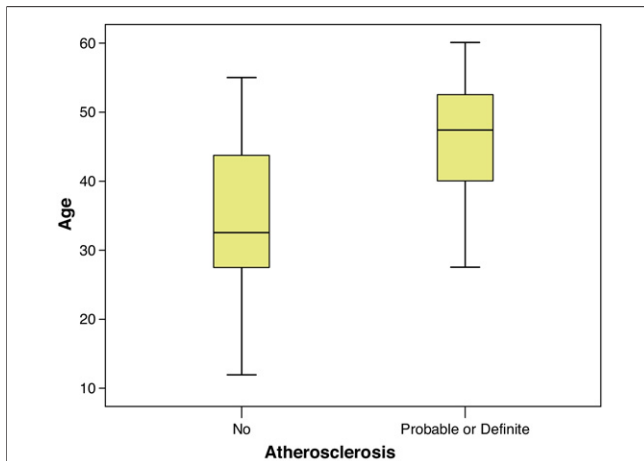


Figure 1. Age at Death of Mummies With and Without Atherosclerosis

Median age at death (line) \pm 25th percentile (shaded box) and range (brackets) of the mummies with vascular tissue but no atherosclerosis and mummies with probable or definite atherosclerosis. The mummies with atherosclerosis were significantly older ($p < 0.002$).

The estimated mean age at death of these 44 mummies was 39.3 ± 11.8 years. The mean age at death of this subset of mummies did not differ by sex (mean age 40.9 ± 10.4 years for men vs. mean age 38.2 ± 12.5 years for women, $p = 0.45$).

Predictors of atherosclerosis. Definite or probable atherosclerosis was seen in 20 (45%) of the 44 mummies in whom cardiovascular tissue was present. Twelve of these 20 mummies had definite atherosclerosis and 8 had probable atherosclerosis.

The 20 mummies with definite or probable atherosclerosis were older (mean age 45.1 ± 9.2

years) than the mummies with CV tissue but no atherosclerosis (mean age 34.5 ± 11.8 years, $p < 0.002$) (Fig. 1). With each year of advancing age, the probability of having atherosclerosis increased by 9.6% ($p = 0.006$).

The frequency of atherosclerosis did not differ between sexes. Of the 20 with atherosclerosis, 11 (55%) were male and 9 (45%) were female ($p = 0.38$).

In mummies with definite or probable atherosclerosis, the average number of vascular beds involved was 2.2 ± 1.3 . Mummies with atherosclerotic involvement of ≥ 3 beds were significantly more likely to be ≥ 40 years of age in comparison with those having involvement of 1 or 2 beds ($p = 0.02$). In fact, all mummies with involvement of ≥ 3 beds were ≥ 40 years old.

Atherosclerosis was most common in the aorta, it was observed in 14 of 44 (32%), followed by the peripheral vessels in 13 of 44 (30%), carotids in 8 of 44 (18%), iliacs in 6 of 44 (14%), and coronaries in 3 of 44 (7%). An example of a mummy with atherosclerosis in each vascular bed is a princess who lived during the Second Intermediate Period (1580 to 1550 BCE) and died in her early 40s (Mummy #35) (Figs. 2 and 3A, Online Videos 1 and 2). An image from a CT scan of the abdominal aorta from a modern patient is shown for comparison (Fig. 3B). Figure 4 shows severe atherosclerotic calcifications in the arteries of the upper leg in a male scribe who lived during the 18th Dynasty. Online Video 3 represents a female mummy recently excavated from Fayuom of an unknown historic period who died in her late 40s, also with atherosclerosis of multiple vascular territories. Of note,

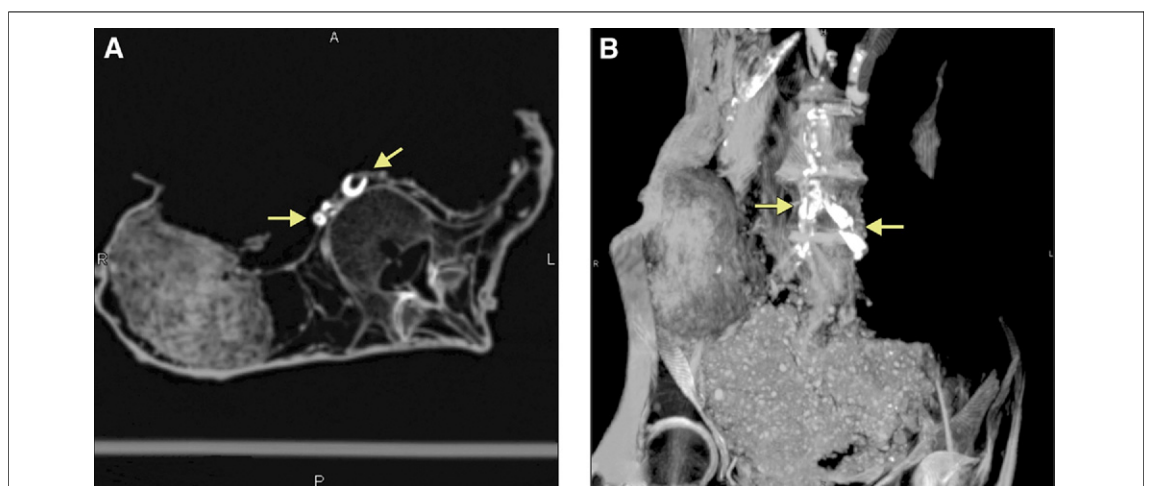

Figure 2. Atherosclerosis in the Common Iliac Arteries

Computed tomography maximum intensity projection showing heavy calcifications (arrows) in the common iliac arteries on (A) axial and (B) coronal projections in the mummy of a princess who lived during the Second Intermediate Period (Mummy #35). Also see Online Video 1.

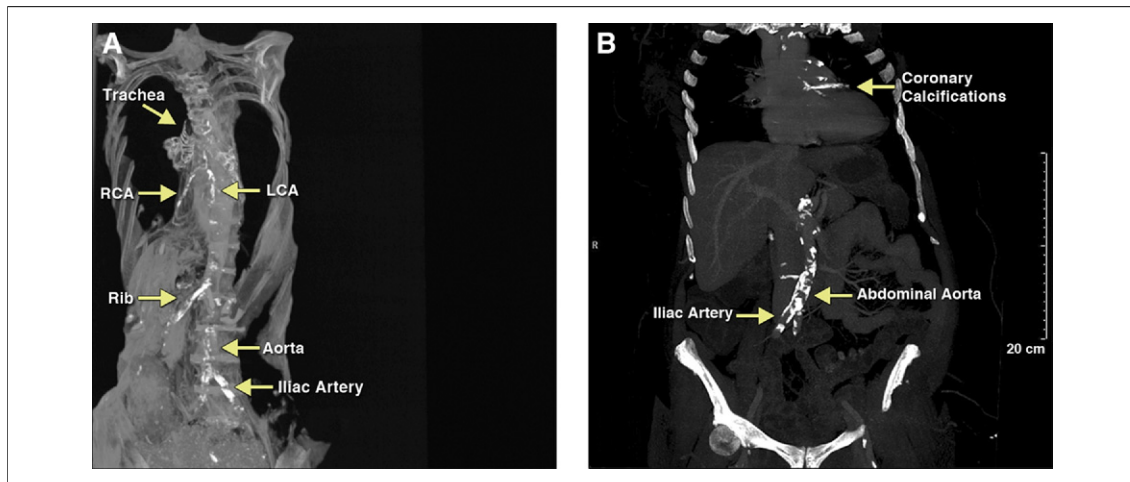


Figure 3. Atherosclerosis in the Coronary, Aortic, and Iliac Arteries

(A) Reoriented coronal thick slab 3-dimensional, multiplanar reconstruction window adjusted for vascular calcification, computed tomography image of the mummy of a princess who lived during the Second Intermediate Period shows calcifications in the coronary and iliac arteries, indicating this person had diffuse atherosclerosis. The posterior descending and posterolateral branches of the right coronary artery can be discerned distal to calcifications of the proximal and mid right coronary (Mummy #35). (B) Computed tomography scan from a modern Egyptian patient showing similar calcifications in the coronary and iliac arteries. Also see [Online Video 2](#). LCA = left coronary artery; RCA = right coronary artery.

we were unable to definitively determine the cause of death for any of the 52 mummies. Representative examples of mummies with carotid, aortic, and peripheral vascular atherosclerosis are shown in [Figures 2 to 6](#).

Cardiac findings. Of the 31 mummies with hearts present, an intact heart was present in 16 (31%) and

heart remnants in 15 (29%), of the 52 mummies imaged. Hearts could be identified in mummies of all historic periods ([Table 1](#)). Two of those with intact hearts had definite coronary atherosclerosis, and 1 had probable coronary atherosclerosis. Examples of coronary artery calcifications are seen in [Online Video 1](#) and in [Figures 3A, 7, and 8A](#). The mean age of mummies with coronary atherosclerosis was 48.3 ± 6.3 years. This is nominally greater than the mean age for the entire sample, although the small sample size precluded us from performing inferential statistics.

Mitral annular calcification was present in 2 (6%) of the 31 mummies with intact or remnant hearts ([Fig. 9](#)).

Socioeconomic status and atherosclerosis. Among the 25 mummies for whom social position could be determined, 10 were priests or priestesses. Atherosclerosis was less common in clergy than in non-clergy ($p = 0.012$).

The historical era in which the individuals lived was known for 41 of the 44 mummies with cardiovascular tissue present. At least 1 mummy with atherosclerosis was found in all eras except the Middle Kingdom, in which only 1 mummy (no vascular tissue present) was available for scanning ([Fig. 10](#)). In a logistic regression, historical era was not predictive of atherosclerosis status ($p = 0.23$). Thus, atherosclerosis was not more prevalent in later historic periods than in earlier ones (odds ratio: 0.74, $p = 0.24$).

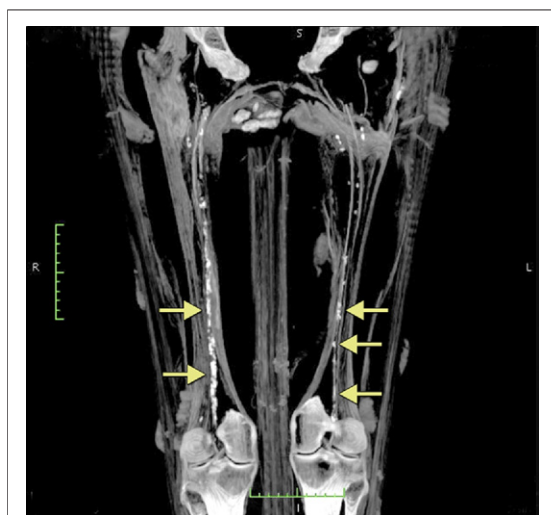


Figure 4. Atherosclerosis in the Superficial Femoral Arteries

Computed tomography maximum intensity projection of the upper legs showing extensive calcifications along the course of the superficial femoral arteries in the mummy of a man who lived during the 18th Dynasty (Hatay, Mummy #23).

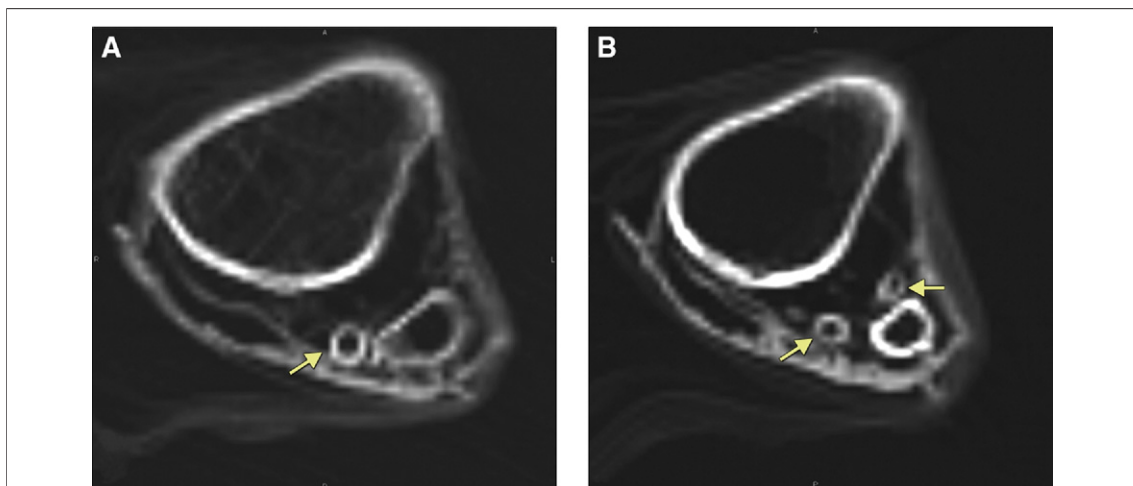


Figure 5. Atherosclerosis in the Popliteal and Tibial Arteries

Axial computed tomography images of the left leg distal to the knee showing (A) calcifications in the popliteal artery (arrow), and (B) in a slightly distal position, showing calcifications in the peroneal artery and the anterior tibial artery (arrows) in the mummy of a woman who lived during the Ptolemaic Period (Mummy #22).

DISCUSSION

We used noninvasive CT scanning in a manner similar to its use in contemporary humans (16) to search for calcified atherosclerotic plaque in the remains of 52 ancient Egyptians. Of the 44 mummies in whom we could identify vascular tissue, 45% had vascular calcification. While the number of subjects we were able to examine is small in comparison with modern epidemiologic studies, our data are consistent with the conclusion that atherosclerosis was common in ancient Egypt.

We saw evidence of calcification in the aorta, peripheral vessels, carotids, iliacs, and coronary arteries. Incomplete preservation of the mummies and embalming techniques that differed in the removal of vessels or organs resulted in our inability to image all vascular beds in each mummy. The aorta, iliac, and peripheral arteries were generally better preserved and available than the coronaries and carotids. It is apparent, however, that vascular calcification affected arteries in many regions of the body in ancient Egyptians, just as it does in contemporary humans. Similar to findings in contem-

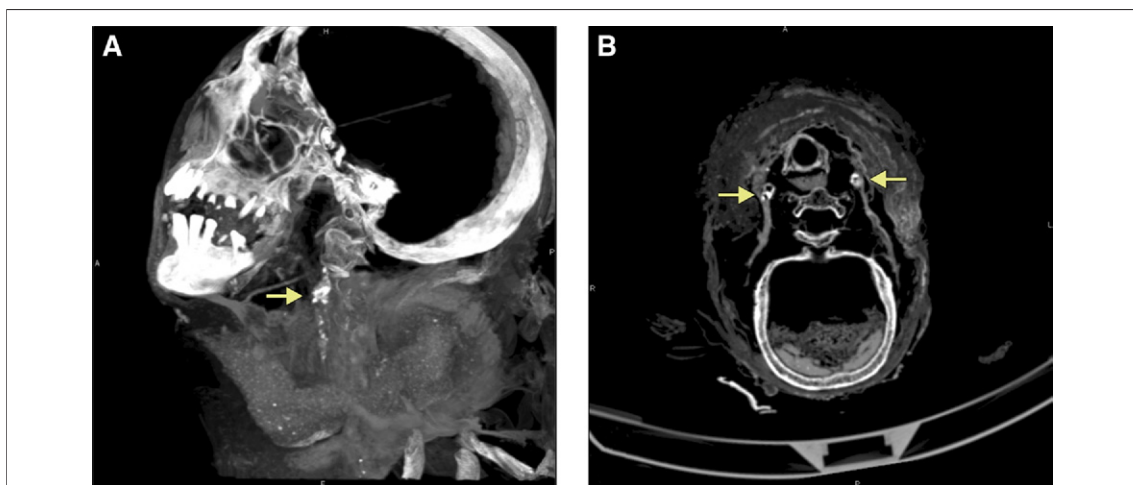


Figure 6. Atherosclerosis in the Carotid Arteries

Computed tomography maximum intensity projection sagittal view (A) showing heavy calcifications in the region of the left carotid artery at the carotid bulb (arrow), and (B) axial view showing heavy calcifications in the region of both the right and left carotid bulbs (arrows) in the mummy of man who lived during the 18th Dynasty (Hatiay, Mummy #23).

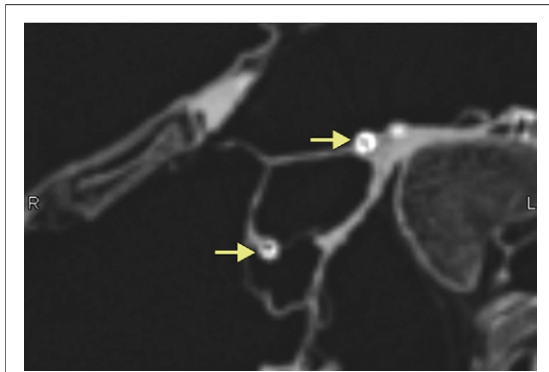


Figure 7. Atherosclerosis in the Left and Right Coronary Arteries

Maximum intensity projection computed tomography image showing calcifications in the left and right coronary arteries (arrows) in the mummy of a princess who lived during the Second Intermediate Period (Mummy #35).

porary humans, arterial calcification in these mummies was more common and extensive as the age at death increased. The prevalence of vascular calcification was similar for men and women.

Our finding of extensive coronary calcification in Mummy #35, a princess living in the 17th Dynasty (1580 to 1550 BCE) of the Second Intermediate Period represents, to our knowledge, the earliest documentation of a human with coronary artery disease (Figs. 3A and 7, Online Videos 1 and 2). Carotid calcification has been infrequently reported in ancient Egyptian mummies (11). In our sample of 44 mummies with cardiovascular tissue, however,

carotid calcification was present in 8 mummies. Our relatively large sample size of mummies undergoing CT imaging extends the investigations of Ruffer (4), Long (5), and earlier investigators (3,11) who documented atherosclerosis in single or small case studies of autopsied ancient Egyptian mummies. Our larger sample, spanning >2 millennia, allowed us to explore the relative frequency and extent of atherosclerosis rather than simply its existence.

We identified calcification of the mitral annulus in 2 mummies, a novel finding. We were unable to visualize the aortic valve leaflets well enough to comment on the presence or absence of valvular calcification, both of which are highly associated with risk factors for atherosclerosis and systemic calcified atherosclerosis (17,18).

We detected evidence of atherosclerosis in almost all the dynastic eras of ancient Egypt. The prevalence of modern day risk factors for atherosclerosis in ancient Egypt is challenging to estimate. Tobacco was unavailable, and without modern transportation, an active lifestyle was likely, but the incidence of hypertension and diabetes mellitus is unknown. Although the diet of a particular ancient Egyptian with or without atherosclerosis is difficult to ascertain, hieroglyphic inscriptions on Egyptian temple walls indicate that beef, sheep, goats, wild-fowl, bread, and cake were regularly consumed (11,15,19). David (11,15) suggested that the ancient Egyptian diet may have been atherogenic, particularly among the clergy who consumed the

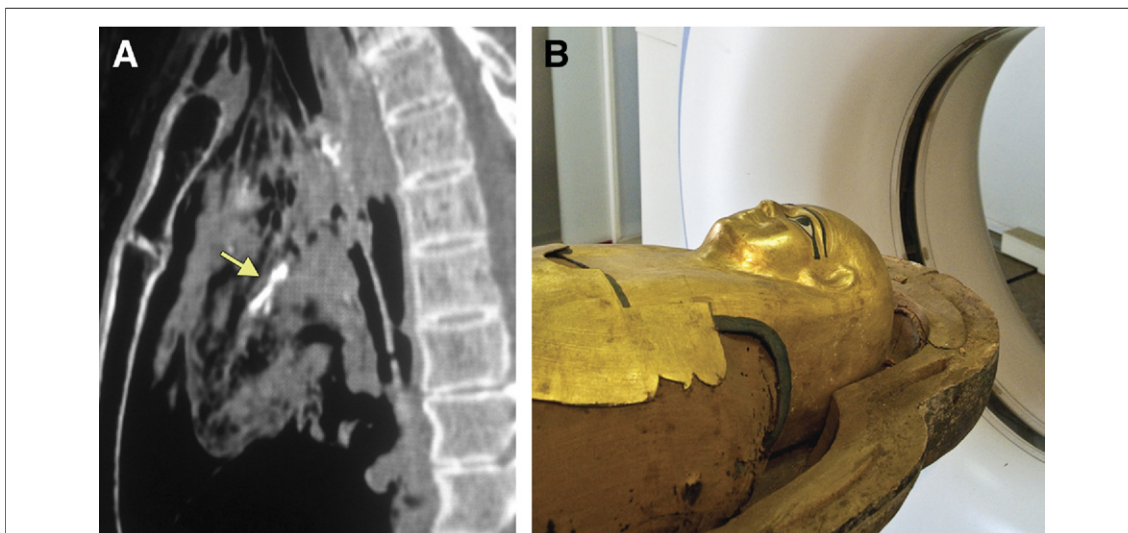


Figure 8. Atherosclerosis in the Left Coronary Artery

(A) Maximum intensity projection computed tomography image showing calcifications of the left coronary artery (arrow). (B) Anthropoid mask of the same mummy, a man who lived during the Ptolemaic Period (Djeher, Mummy #12).

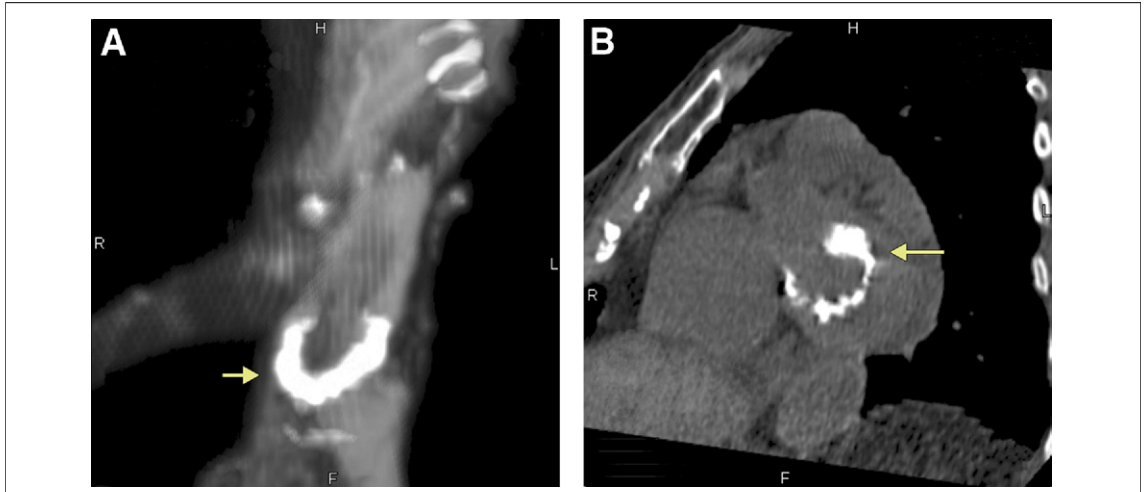

Figure 9. Mitral Annular Calcifications

(A) Heavy calcifications in the region of the mitral annulus (arrow) in the heart of a mummy of a woman who lived in ancient Egypt (Mummy #38). See [Online Video 3](#) for a video of the mitral valve calcification as well as aortic and iliac calcification. (B) Similar appearance of heavy mitral annular calcification (arrow) in a noncontrast computed tomography scan performed in a modern patient.

ritual feasts left by families mourning their deceased relatives. Relative to atherosclerosis, however, in this relatively small subset we found priests and priestesses to have less atherosclerosis than non-clergy. Nevertheless, significant differences may have existed between the food consumed by royalty and other elites and that eaten by common farmers and laborers (19). As the elite were more likely to be mummified after death, caution must therefore be

exercised in generalizing our results to the entire ancient Egyptian population.

Elite and nonelite ancient Egyptians were not hunter-gatherers, however. Profound changes began to occur in human lifestyles and diet around 10,000 years ago with the introduction of agriculture and animal husbandry. Egyptians had formed an organized agricultural society along the Nile that long predated the mummies that we studied. It is

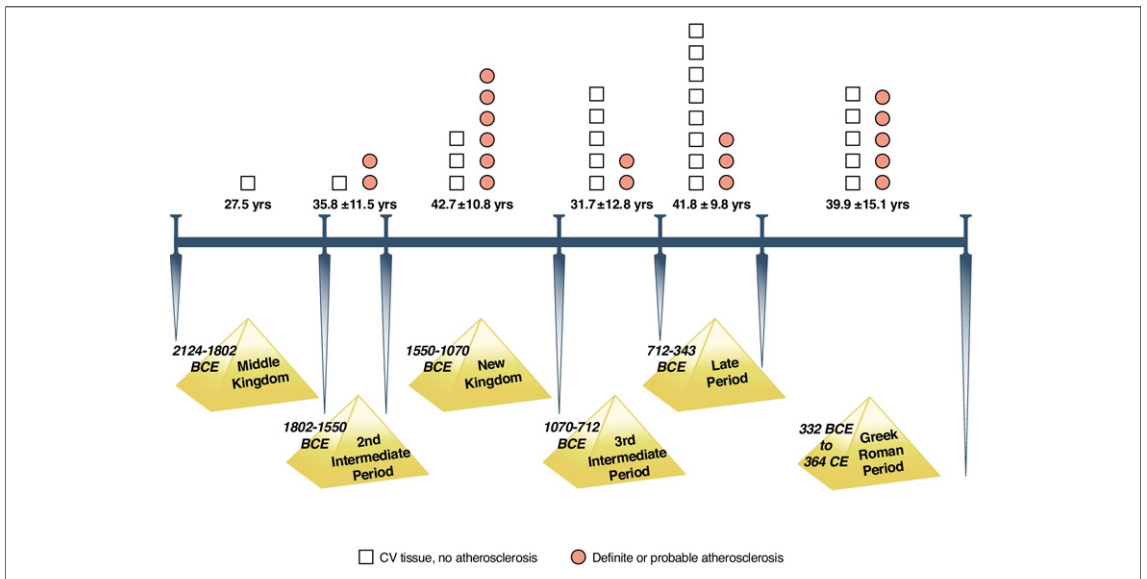


Figure 10. Historical Time Distribution of Atherosclerosis in the Mummies

The presence of identifiable cardiovascular tissue and atherosclerosis found in the mummies is shown in relation to the ancient Egyptian eras in which they lived. Atherosclerosis was found in virtually all time periods represented in the study. Open boxes indicate cardiovascular (CV) tissue, no atherosclerosis; solid circles represent definite or probable atherosclerosis.

plausible that the composition of their diet contributed to the development of atherosclerotic cardiovascular disease (11,15,19,20).

Study limitations. To assess the presence of atherosclerosis, we used CT findings of arterial calcification as a marker. We did so given that vascular calcification is generally regarded as a highly specific, late-stage manifestation of atherosclerosis. Whereas the earliest pathologic manifestations of atherosclerosis include intimal thickening and fatty streaks, complex changes occur as the disease progresses, with structural remodeling of the vessel, cellular infiltrates, lipid accumulation, thrombosis, fibrosis, and calcification involving the media as well as the adventitia (21).

We have no independent pathologic verification that areas of arterial calcification, which we identified by expert consensus interpretation of these noncontrast CT images, actually represent atherosclerotic plaque. Our interpretations are based on our knowledge of arterial anatomy, the similarity of the appearance and observed age-related prevalence of vascular calcification in modern patients and mummies, and the fact that histologic studies showing arterial calcification in a similar vascular distribution in mummies have been previously reported (3-5,11).

For the majority of the mummies, we used a 6-slice scanner to acquire thin CT axial images, reconstructing images in multiple 2- and 3-dimensional planes. Recently developed CT scanners with larger detector arrays for wider coverage per rotation and employing strategies for better temporal resolution could be used but offer little advantage for imaging of the motionless mummies. However, newer machines with improved spatial resolution and machines employing multiple X-ray energies might improve plaque characterization. Dual-energy CT might be useful in differentiating calcium hydroxyapatite associated with atherosclerotic plaque from natron (sodium carbonate decahydrate), a salt used in the mummification process.

Implications. As civilization advanced, humans survived to older ages. Before the modern era, infectious disease, trauma, and famine were the most common causes of death. Perhaps genetic adaptation favored a beneficial inflammatory response to infection, markedly helpful in childhood and through the reproductive years in ancient civilizations, but which potentially promoted the development of atherosclerosis later in life (22,23). We now recognize that inflammation plays an important role both in atherosclerosis (6,8,24) and advancing age (22).

Allison et al. (14) reported the prevalence of vascular calcifications in 650 asymptomatic contemporary men and women (mean age 57.6 years) using whole body CT imaging. Among those age 50 to 60 years, vascular calcification was present in 92% of the men and 72% of the women, and present in 2 or more vascular beds in 80% of the men and 62% of the women. By the time men reached 60 years of age and the women reached 70 years of age, all had calcification in 1 or more vascular beds. A direct comparison of the prevalence of atherosclerosis among the ancient Egyptians imaged in this current study to contemporary humans is difficult given the frequently missing vessel beds and younger age at death among the ancient Egyptians.

Although we could not determine the presence or absence of clinical disease syndromes associated with atherosclerosis in these ancient humans, extrapolation of findings from modern vascular epidemiological studies suggest a significant likelihood of such disease. Many of the mummies we studied had arterial calcification in the pelvis and legs, areas that were relatively better preserved in these ancient humans than the coronaries or carotids. It has been shown that an increasing degree of tibial artery calcification, as measured by CT, identifies increasing severity of peripheral arterial disease and identifies patients with a higher risk for amputation, independent of traditional risk factors (25). Calcification of the lower extremity arteries, more common in diabetic patients and patients with renal failure, is a strong predictor of adverse outcomes due to associated coronary heart disease (26,27). Arterial calcification was also seen in the aortas and carotid arteries of these mummies. Many studies have shown an association between aortic and coronary atherosclerosis and with aortic aneurysm, renal failure, and stroke, all of which share common risk factors (28). The estimated mean age at the time of death of the mummies we studied was 38.1 ± 12.0 years, a relatively old age 3 millennia ago. Several mummies had such diffuse generalized atherosclerosis that clinical symptoms would seem to have been likely.

Ancient Egyptian hieroglyphic papyri texts mention symptoms consistent with angina, acute myocardial infarction, and congestive heart failure (29). For example, an ancient Egyptian papyrus for physicians comments, "If thou examinist a man for illness in his cardia, and he has pains in his arms, in his breasts and on 1 side of his cardia . . . it is death threatening him" (30). Relief sculptures found in ancient Egyptian tombs have been interpreted as

showing sudden death, with a nobleman collapsing in the presence of his servants (31).

Our findings of frequent arterial calcification suggest that atherosclerotic cardiovascular disease was present and commonplace in ancient Egypt, raising intriguing questions regarding the nature and extent of human predisposition to the development of atherosclerosis.

Acknowledgments

The authors express their thanks to the Supreme Council of Antiquities, Egyptian Ministry of Culture, for allowing us to image these mummies; statistical consultants, Jennifer J. Thomas, PhD, Harvard Medical School/Massachusetts General

and McLean Hospitals and Noah Shamosh, PhD, of an international strategy consulting firm; Mary Hochman, MD, Harvard Medical School/Beth Israel Deaconess Medical Center for providing us with the images of 1 of the mummies; Sallam Lotfy Mohamed, BSc, of Alfaskan, Cairo, Egypt for technical imaging support, and John Labib, BA, of the University of Lincoln, United Kingdom, for his background research and assistance with scanning.

Reprint requests and correspondence: Dr. Gregory S. Thomas, Mission Internal Medical Group, 26800 Crown Valley Parkway, Suite 120, Mission Viejo, California 92691. *E-mail:* gthomas9@mac.com.

REFERENCES

- Reddy KS, Yusuf S. Emerging epidemic of cardiovascular disease in developing countries. *Circulation* 1998; 97:596-601.
- World Health Organization. *World Health Statistics 2010*. Geneva: World Health Organization Press, 2010.
- Czermack J. Description and microscopic findings of two Egyptian mummies. Meeting of the Academy of Science (Beschreibung und mikroskopische Untersuchung Zweier Agypischer Mumien, S.B. Akad. Wiss. Wien), 1852;9:27.
- Ruffer MA. On arterial lesions found in Egyptian Mummies (1580 BC-535 AD). *J Pathol Bacteriol* 1911;16:453-62.
- Long AR. Cardiovascular renal disease: a report of a case three thousand years ago. *Arch Pathol (Chic)* 1931; 12:92-4.
- Ridker PM. On evolutionary biology, inflammation, infection, and the causes of atherosclerosis. *Circulation* 2002;105:2-4.
- Falk E. Pathogenesis of atherosclerosis. *J Am Coll Cardiol* 2005;47: C7-12.
- Ding K, Kullo I. Evolutionary genetics of coronary heart disease. *Circulation* 2009;119:459-67.
- Allam AH, Thompson RC, Wann LS, Miyamoto ML, Thomas GS. Computed tomographic assessment of atherosclerosis in ancient Egyptian mummies. *JAMA* 2009;302:2091-3.
- Allam AH, Nureldin A, Adelmak-soub G, et al. Something old, something new—computed tomography studies of the cardiovascular system in ancient Egyptian mummies. *Am Heart Hosp J* 2010;20:10-3.
- David R. Cardiovascular disease and diet in ancient Egypt. In: Hawass Z, Woods A, editors. *Egyptian Culture and Society: Studies in Honor of Naguib Kanawati*. Annales du Service des Antiquites de l'Egypte. Vol. 1. Cairo, Egypt: Conseil Supreme des Antiquites de l'Egypte, 2010:105-17.
- Buikstra JE, Ubelaker DH. Standards for Data Collection from Human Skeletal Remains. *Arkansas Archeological Survey Research Series No. 44*. Fayetteville, AR: Arkansas Archeological Survey, 1994.
- Walker RA, Lovejoy CO. Radiographic changes in the clavicle and proximal femur and their use in the determination of skeletal age at death. *Am J Phys Anthropol* 1985;68:67-78.
- Allison MA, Criqui MH, Wright CM. Patterns and risk factors for systemic calcified atherosclerosis. *Arterioscler Thromb Vasc Biol* 2004;24: 331-6.
- David R. The art of medicine— atherosclerosis and diet in ancient Egypt. *Lancet* 2010;175:718-9.
- Budoff MJ, Achenbach S, Blumenthal RS, et al. Assessment of coronary artery disease by cardiac computed tomography: a scientific statement from the American Heart Association Committee on Cardiovascular Imaging and Intervention, Council on Cardiovascular Radiology and Intervention, and Committee on Cardiac Imaging. *Circulation* 2006;114:1761-79.
- Allison MA, Cheung P, Criqui MH, Langer RD, Wright CM. Mitral and aortic annular calcification are highly associated with systemic calcified atherosclerosis. *Circulation* 2006;113: 861-6.
- Kanjanathai S, Nasir K, Katz R, et al. Relationships of mitral annular calcification to cardiovascular risk factors: the Multi-Ethnic Study of Atherosclerosis (MESA). *Atherosclerosis* 2010;213:558-62.
- Darby WJ, Ghalloungul P, Grivatti L. *Food: The Gift of Osiris*. Vol 1. London: Academic Press, 1957.
- Cordain L, Eaton SB, Sebastian A, et al. Origins and evolution of the Western diet: health implications for the 21st century. *Am J Clin Nutr* 2005; 81:341-54.
- Stary HC, Chandler AB, Dinsmore RE, et al. A definition of advanced types of atherosclerotic lesions and a histological classification of atherosclerosis. A report from the Committee on Vascular Lesions of the Council on Arteriosclerosis, American Heart Association. *Circulation* 1995;92: 1355-74.
- Finch C. *The Biology of Human Longevity: Inflammation, Nutrition and Aging in the Evolution of Life Spans*. Amsterdam: Academic Press, 2007.
- Sawabe M. Vascular aging: from molecular mechanism to clinical significance. *Geriatr Gerontol Int* 2010;10 Suppl:213-330.
- Finch CE. Evolution of the human lifespan and diseases of aging: roles of infection, inflammation, and nutrition. *Proc Natl Acad Sci U S A* 2010;107 Suppl 1:1718-24.
- Guzman JR, Brinkley DM, Schumacher PM, Donohue RMJ, Beavers H, Qin X. Tibial artery calcification as a marker of amputation risk in patients with peripheral arterial disease. *J Am Coll Cardiol* 2008;51:1967-74.
- Lehto S, Niskanen L, Suhonen, et al. Medial artery calcification. A neglected harbinger of cardiovascular complication in non-insulin dependent diabetes mellitus. *Arterioscler Thromb Vasc Biol* 1996;16:978-83.

27. McCullough PA, Agrawal V, Danielewicz E, Abela GS. Accelerated atherosclerotic calcification and Monckeberg's sclerosis: a continuum of advanced vascular pathology in chronic kidney disease. *Clin J Am Soc Nephrol* 2008;3:1585–98.
28. vander Wall EE, vander Laarse A. Aortic and coronary atherosclerosis: a natural association? *Int J Cardiovasc Imaging* 2009;25:219–22.
29. Wreszinsk W. [Der frosse medizinische Papyrus des Berliner Museums.] Microfilm. Washington, DC: Library of Congress Preservation Microfilming Program, available from Library of Congress Photoduplication Service, 1995. Available at: <http://openlibrary.org/b/OL1050325M/grosse-medizinische-Papyrus-des-Berliner-Museums-%28Pap.-Berl.-3038%29>; Reinhold Scholl, *Der Papyrus Ebers. Die größte Buchrolle zur Heilkunde Altägyptens* (Schriften aus der Universitätsbibliothek 7), Leipzig 2002. Accessed November 20, 2010.
30. Ebbel B. *The Papyrus Ebers*. Copenhagen, Denmark: Levinn and Munksgaard, 1937:48.
31. Bruetsch WL. The earliest record of sudden death possibly due to atherosclerotic coronary occlusion. *Circulation* 1959;20:438–41.

Key Words: arterial calcifications

■ atherosclerosis ■ computed tomography scan ■ coronary artery disease ■ coronary calcification ■ mummies.

APPENDIX

For a supplemental table and Videos 1, 2, and 3 and their legends, please see the online version of this article.