

## Right-sided Bochdalek Hernia Presenting as a Solitary Pulmonary Nodule

Stamatis Katsenos, M.D., Ioannis Kokkonouzis, M.D., Stefanos Lachanis, M.D., and Kostas Psathakis, M.D.

Bochdalek hernia is a well-known disorder, which represents visceral herniation through a posterior diaphragmatic defect. In this report we present an adult man with a right-sided Bochdalek hernia mimicking a solitary pulmonary nodule. Furthermore, we perform a brief review of the literature, with emphasis on novel imaging techniques that establish the diagnosis. In conclusion, Bochdalek hernia should be considered in the differential diagnosis of a posterior diaphragmatic or paraspinal opacity. Correct diagnosis is of paramount importance and can be easily established by non-invasive imaging techniques.

### Introduction

Bochdalek hernia is a well-known disorder, which represents visceral herniation through a posterior diaphragmatic defect. In this report we present an adult man with a right-sided Bochdalek hernia mimicking a solitary pulmonary nodule. Furthermore, we perform a brief review of the literature, with emphasis on novel imaging techniques that establish the diagnosis.

Citation: Katsenos S, Kokkonouzis I, Lachanis S, Psathakis K. Right-sided Bochdalek hernia presenting as a solitary pulmonary nodule. *Radiology Case Reports*. [Online] 2008;3:114.

Copyright: © 2008 Stamatis Katsenos, M.D. This is an open-access article distributed under the terms of the Creative Commons Attribution-NonCommercial-NoDerivs 2.5 License, which permits reproduction and distribution, provided the original work is properly cited. Commercial use and derivative works are not permitted.

Abbreviations: CT, computed tomography; MRI, magnetic resonance imaging

Stamatis Katsenos, M.D. (Email: skatsenos@yahoo.gr), Ioannis Kokkonouzis, M.D., and Kostas Psathakis, M.D., are in the Department of Pneumology, Army General Hospital of Athens, Athens, Greece.

Stefanos Lachanis, M.D., is in the Department of Radiology, Army General Hospital of Athens, Athens, Greece.

Published: January 13, 2008

DOI: 10.2484/rcr.v3i2.114

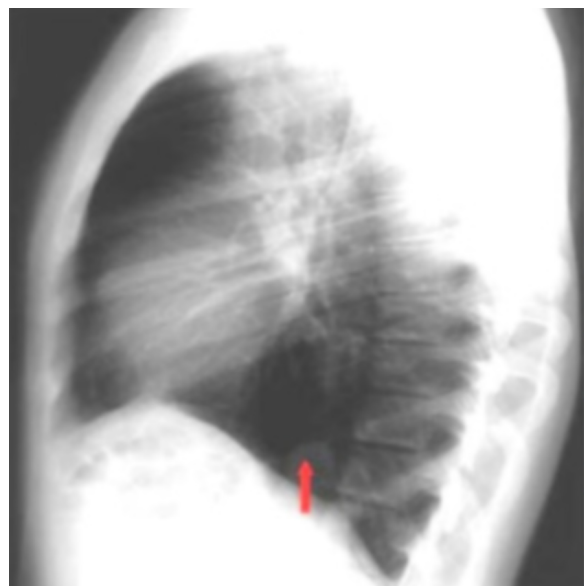


Figure 1. 45-year-old man with Bochdalek hernia. Lateral chest radiograph shows a small round opacity (red arrow) in contact with the posterior portion of the right hemidiaphragm.

## Right-sided Bochdalek Hernia Presenting as a Solitary Pulmonary Nodule

### Case Report

A 45-year-old man, with a history of heavy smoking, was admitted to our department complaining of acute right-sided chest pain of moderate intensity that was not related to breathing or body movements. Previously, he had been in good health. Physical examination and routine blood tests were unremarkable. Arterial blood gases were normal. The posteroanterior chest radiograph was normal, but the lateral view disclosed a round opacity, 2 cm in diameter, in contact with the posterior portion of the right hemidiaphragm which remained unchanged in size or shape with the Valsalva or Müller maneuvers (Fig. 1). A conventional CT of the thorax disclosed an opacity adjacent to the right hemidiaphragm (Fig. 2). During the multislice contrast-enhanced procedure, scanning was interrupted due to a contrast reaction. As several diseases of intrapulmonary origin may have a similar appearance, coronal and sagittal magnetic resonance T1-weighted images (MRI), focusing on the lungs and upper abdomen were obtained, to further characterize the lesion. The MRI study showed that a portion of the liver had herniated posteriorly through a right diaphragmatic muscle defect, confirming the presence of a Bochdalek hernia (Fig. 3). The patient underwent fiberoptic bronchoscopy, because of his smoking history. No intraluminal lesions were found although some slight mucosal inflammation was present throughout the tracheobronchial tree. The patient's chest pain resolved a few days later and was deemed to be irrelevant to the

diaphragmatic hernia. The patient was discharged without any intervention.

### Discussion

The diaphragm forms from four embryological elements: a) septum transversum, b) mesentery of the esophagus, c) pleuroperitoneal membranes and d) ingrowing muscular tissue from the body wall [1]. During the 7th week of development, the pleuroperitoneal folds fuse with the mesentery of the esophagus and migrate anteriorly to join the septum transversum, closing two large posterolateral openings. Failure of closure results in patency of the Bochdalek's foramen. The abdominal contents return from the yolk sac at about the 10th week of development and if they return prior to closure, or if closure is incomplete, herniation can occur [2].

Posterolateral congenital diaphragmatic hernias are commonly termed "Bochdalek hernias" in recognition of Professor Vincenz Alexander Bochdalek, a prominent Czech anatomist who first described the abnormality in 1848 [3]. Nowadays, the term "congenital diaphragmatic hernia" is preferred for hernias presenting in the neonatal period, as a result of large central diaphragmatic defects, which allows the protrusion of abdominal viscera into the thoracic cavity. These cases may behave as life-threatening emergencies, due to the compressive effects of the abdominal contents on the lungs and the mediastinum [4]. The term "Bochdalek hernia" is

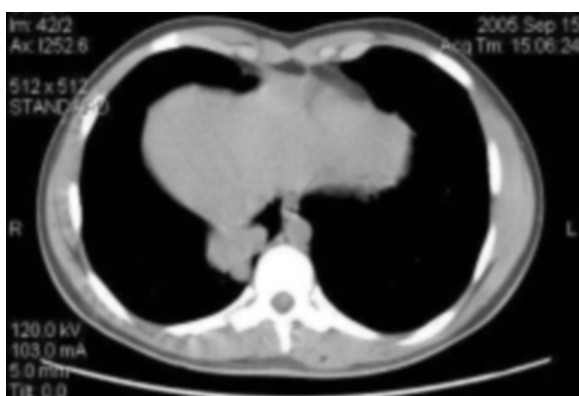


Figure 2A. Axial CT image in soft tissue settings demonstrates an ill-defined opacity adjacent to the right hemidiaphragm.

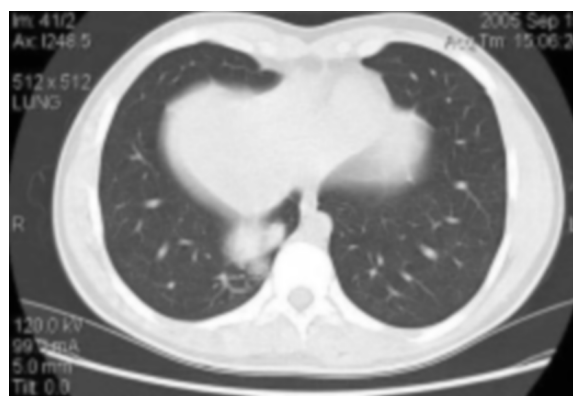

Figure 2B. Axial CT image in lung settings shows the posterior right costophrenic poorly margined lesion.

## Right-sided Bochdalek Hernia Presenting as a Solitary Pulmonary Nodule

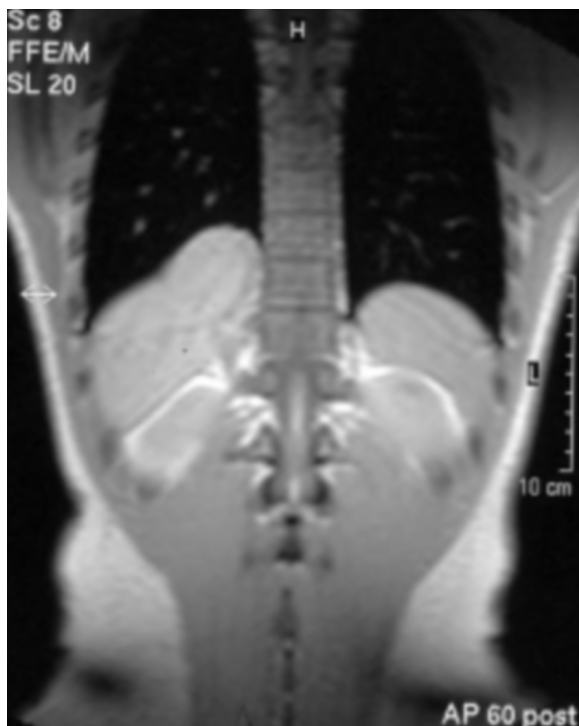


Figure 3A. Coronal T1-weighted MRI reveals a portion of liver herniated through a defect in the posterior right hemidiaphragm.

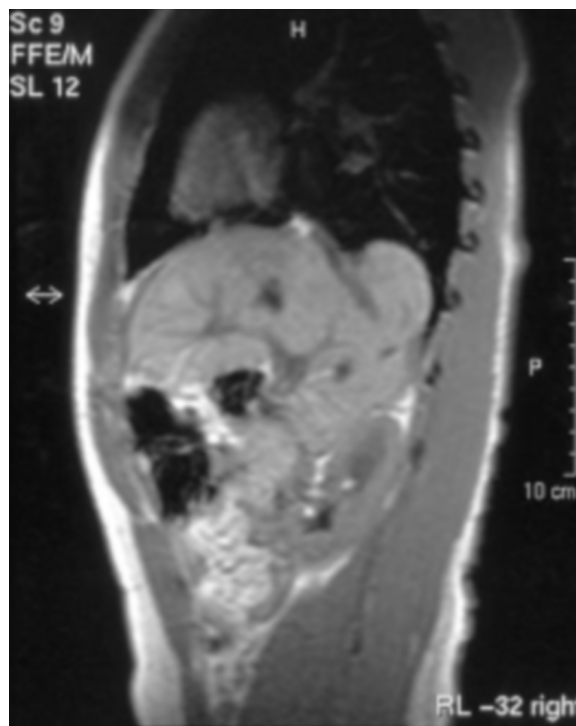


Figure 3B. Sagittal T1-weighted MRI shows the herniated portion of liver.

preferred for more localized herniations through small diaphragmatic defects, usually occurring later in life without obvious symptoms. Triggering factors that have been suggested, include physical exertion, sexual intercourse, childbirth, Valsalva maneuver, large meals and abdominal trauma (including post-operative events) [5].

Estimations of the prevalence of Bochdalek hernia vary between 0.17% and 6% [3,6,7]. The disorder shows a left-sided predominance (2:1-9:1 ratio), attributed to the “protective” effect of the liver [8]. Clinical presentation is variable according to the volume and contents of the hernia sac and the presence or absence of organ strangulation. Patients may be asymptomatic or suffer from nausea, vomiting, abdominal pain, chest pain, cough or respiratory distress. Physical examination is usually unremarkable, but in cases of strangulated viscera, auscultation may reveal abnormal bowel sounds from acute intestinal obstruction [9]. Some authors distinguish between small hernias containing retroperi-

toneal fat and larger hernias. The small fat-containing hernias have no clinical implication, whereas the large ones containing abdominal viscera are associated with increased morbidity and mortality [7]. Bochdalek hernia is often discovered as an incidental finding, as in the case we present.

The diagnosis of the disorder can be established using radiological techniques. Chest radiograph is usually the first imaging procedure but it is of limited value on depicting the diaphragmatic defect [10]. The hernia may appear either as a soft-tissue opacity at the lung base or as a solitary, smooth, round lesion in the posterior costophrenic recess. Contrast studies of the gastrointestinal tract may confirm the diagnosis in some cases [11]. Radionuclide imaging may also be useful in showing herniation into the chest [12]. Abdominal ultrasound sometimes may depict the disruption of diaphragmatic continuity with the associated herniated organs, distinguishing fatty tissue from liver and loops of bowel [13].

## Right-sided Bochdalek Hernia Presenting as a Solitary Pulmonary Nodule

CT is the procedure of choice for demonstrating a Bochdalek hernia. With routine CT scan, Killeen et al. demonstrated sensitivities of 50% for right-sided and 78% for left-sided Bochdalek hernia detection [14]. However, with the advent of multislice CT with multiplanar reformatting of the images, the diagnosis of Bochdalek hernia is simplified, as the diaphragmatic defect and the herniated contents are accurately depicted [10]. Sagittal and coronal reformatted images can exquisitely demonstrate the defect and identify organ entrapment [10,15]. When the diagnosis remains unclear, magnetic resonance imaging should be considered.

Bochdalek hernia can simulate neoplastic disease, pulmonary sequestration, foreign material aspiration, tension pneumothorax, pneumonia, pleuritis or pulmonary tuberculosis [16-18]. Extrapleural lipomas may also present with a similar appearance but they are not accompanied by a diaphragmatic defect or displacement of abdominal viscera [19]. The imaging modalities, already mentioned, accurately establish the diagnosis and obviate the need for further investigative procedures. Surgery represents the treatment of choice, particularly in symptomatic cases, with a high success rate [20]. In adulthood, clinically silent hernias rarely progress to life-threatening surgical emergencies [5]. For this reason we decided to keep our patient under observation without further therapeutic interventions.

In conclusion, Bochdalek hernia should be considered in the differential diagnosis of a posterior diaphragmatic or paraspinal opacity. Correct diagnosis is of paramount importance and can be easily established by non-invasive imaging techniques.

### References

1. Langman J. Medical Embryology. 4th ed. Baltimore, MD: Williams & Wilkins; 1981.
2. Kao CL. Bochdalek hernia in adult. *J Emerg Med* 2002;23:283-284. [PubMed]
3. Salacin S, Alper B, Cekin N, Gulmen MK. Bochdalek hernia in adulthood. A review and an autopsy case report. *J Forensic Sci* 1994;39:1112-1116. [PubMed]
4. Mullins ME, Saini S. Imaging of incidental Bochdalek hernia. *Semin Ultrasound CT MR* 2005;26(1):28-36. [PubMed]
5. Losanoff JE, Sauter ER. Congenital posterolateral diaphragmatic hernia in an adult. *Hernia* 2004;8(1):83-85. [PubMed]
6. Gale ME. Bochdalek hernia: prevalence and CT characteristics. *Radiology* 1985;156:449-452. [PubMed]
7. Mullins ME, Stein J, Saini SS, Mueller PR. Prevalence of incidental Bochdalek's hernia in a large adult population. *Am J Roentgenol* 2001;177(2):363-366. [PubMed]
8. Gaerte SC, Meyer CA, Winer-Muram HT, Tarver RD, Conces DJ. Fat-containing lesions of the chest. *Radiographics* 2002;22:S61-S78. [PubMed]
9. Ozturk H, Karnak I, Sakarya MT, Cetinkursun S. Late presentation of Bochdalek hernia: clinical and radiological aspects. *Pediatr Pulmonol* 2001;31(4):306-310. [PubMed]
10. Eren S, Ciris F. Diaphragmatic hernia: diagnostic approaches with review of the literature. *Eur J Radiol* 2005;54(3):448-459. [PubMed]
11. Niwa T, Nakamura A, Kato T, et al. An adult case of Bochdalek hernia complicated with hemothorax. *Respiration* 2003;70(6):644-646. [PubMed]
12. Quarless SA, Wells CN. Bochdalek hernia, incidental finding on sestamibi parathyroid scan. *Clin Nucl Med* 2005;30(6):436-439. [PubMed]
13. Megremis SD, Segkos NI, Gavridakis GP, et al. Sonographic appearance of a late diagnosed left Bochdalek hernia in a middle-aged woman: case report and review of the literature. *J Clin Ultrasound* 2005;33(8):412-417. [PubMed]
14. Killeen KL, Mirvis SE, Shanmuganathan K. Helical CT of diaphragmatic rupture caused by blunt trauma. *Am J Roentgenol* 1999;173:1611-1616. [PubMed]
15. Sugimura A, Kikuchi J, Satoh M. Bilateral Bochdalek hernias in an elderly patient diagnosed by mag-

## Right-sided Bochdalek Hernia Presenting as a Solitary Pulmonary Nodule

netic resonance imaging. Intern Med 1992;31:281-283. [PubMed]

16. Brooks AP, McLean A, Reznek RH. Diaphragmatic (Bochdalek) hernias simulating pulmonary metastases on computed tomography. Clin Radiol 1990;42(2):102-104. [PubMed]

17. Dalton AM, Hodgson RS, Crossley C. Bochdalek hernia masquerading as a tension pneumothorax. Emerg Med J 2004;21(3):393-394. [PubMed]

18. Kaur G, Singh T. Right-sided diaphragmatic hernia masquerading as staphylococcal pneumonia. Indian J Pediatr 2003;70(9):743-745. [PubMed]

19. Shin MS, Mulligan SA, Baxley WA, Ho KJ. Bochdalek hernia of diaphragm in the adult. Diagnosis by computed tomography. Chest 1987;92(6):1098-1101. [PubMed]

20. Kanazawa A, Yoshioka Y, Inoi O, Murase J, Kinoshita H. Acute respiratory failure caused by an incarcerated right-sided adult Bochdalek hernia: report of a case. Surg Today 2002;32(9):812-815. [PubMed]