

# Mutations in *SLC13A5* Cause Autosomal-Recessive Epileptic Encephalopathy with Seizure Onset in the First Days of Life

Julien Thevenon,<sup>1,2,3,\*</sup> Mathieu Milh,<sup>4,5</sup> François Feillet,<sup>6</sup> Judith St-Onge,<sup>1,3,7</sup> Yannis Duffourd,<sup>1,3</sup> Clara Jugé,<sup>3</sup> Agathe Roubertie,<sup>8,9</sup> Delphine Héron,<sup>10</sup> Cyril Mignot,<sup>10</sup> Emmanuel Raffo,<sup>11</sup> Bertrand Isidor,<sup>12</sup> Sandra Wahlen,<sup>10</sup> Damien Sanlaville,<sup>13,14</sup> Nathalie Villeneuve,<sup>4,15</sup> Véronique Darmency-Stamboul,<sup>16</sup> Annick Toutain,<sup>17</sup> Mathilde Lefebvre,<sup>1,2</sup> Mondher Chouchane,<sup>18</sup> Frédéric Huet,<sup>18</sup> Arnaud Lafon,<sup>19</sup> Anne de Saint Martin,<sup>20</sup> Gaetan Lesca,<sup>13,14</sup> Salima El Chehadah,<sup>1,2</sup> Christel Thauvin-Robinet,<sup>1,2,3</sup> Alice Masurel-Paulet,<sup>1,2</sup> Sylvie Odent,<sup>21</sup> Laurent Villard,<sup>5</sup> Christophe Philippe,<sup>22</sup> Laurence Faivre,<sup>1,2,3</sup> and Jean-Baptiste Rivière<sup>1,3,7,\*</sup>

Epileptic encephalopathy (EE) refers to a clinically and genetically heterogeneous group of severe disorders characterized by seizures, abnormal interictal electro-encephalogram, psychomotor delay, and/or cognitive deterioration. We ascertained two multiplex families (including one consanguineous family) consistent with an autosomal-recessive inheritance pattern of EE. All seven affected individuals developed subclinical seizures as early as the first day of life, severe epileptic disease, and profound developmental delay with no facial dysmorphism. Given the similarity in clinical presentation in the two families, we hypothesized that the observed phenotype was due to mutations in the same gene, and we performed exome sequencing in three affected individuals. Analysis of rare variants in genes consistent with an autosomal-recessive mode of inheritance led to identification of mutations in *SLC13A5*, which encodes the cytoplasmic sodium-dependent citrate carrier, notably expressed in neurons. Disease association was confirmed by cosegregation analysis in additional family members. Screening of 68 additional unrelated individuals with early-onset epileptic encephalopathy for *SLC13A5* mutations led to identification of one additional subject with compound heterozygous mutations of *SLC13A5* and a similar clinical presentation as the index subjects. Mutations affected key residues for sodium binding, which is critical for citrate transport. These findings underline the value of careful clinical characterization for genetic investigations in highly heterogeneous conditions such as EE and further highlight the role of citrate metabolism in epilepsy.

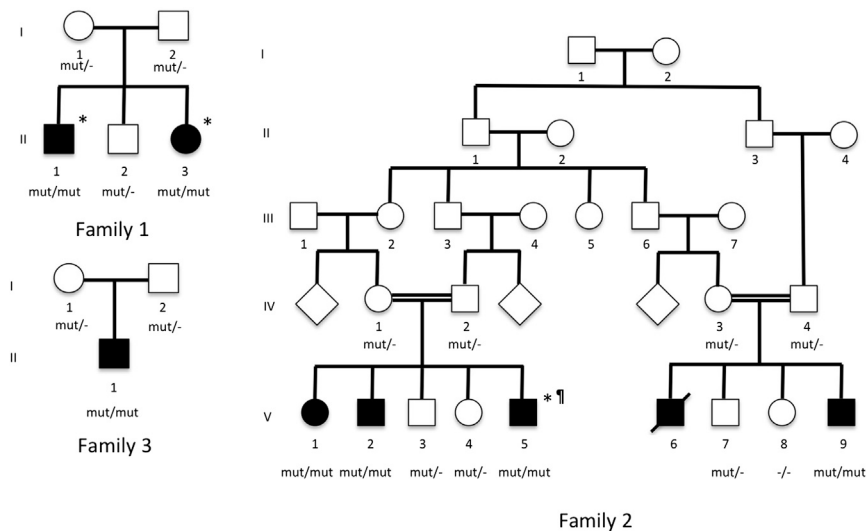
Early-onset epileptic encephalopathy (EOEE) is a highly heterogeneous group of severe epileptic disorders characterized by pharmacoresistant seizures and abnormal interictal electroencephalogram (EEG) that leads to neurological impairment, developmental delay, and high mortality rate.<sup>1–3</sup> Given the extreme etiological heterogeneity of EOEE, clinical, electro-clinical, and genetic classification are of considerable importance for therapeutic management of affected individuals, prognosis, and genetic counseling.<sup>4</sup> Among EOEE, a number of electro-clinical neonatal-onset epileptic syndromes have been described, such as Ohtahara syn-

drome (MIM 308350), early myoclonic epilepsy (MIM 607208), and malignant migrating partial seizures (MIM 614959). Many forms of EOEE nonetheless remain difficult to delineate based on clinical and EEG findings only, and conventional metabolic and genetic screening remain tedious and low yield. This is particularly true for individuals with EOEE and onset of seizures in the first day of life with no evidence of neonatal suffering or environmental causes, because mutations in EOEE-associated genes have been only rarely found in such individuals. Although systematic screening of candidate genes has been shown to increase

<sup>1</sup>Fédération Hospitalo-Universitaire Médecine Translationnelle et Anomalies du Développement (TRANSLAD), Centre Hospitalier Universitaire Dijon, 21079 Dijon, France; <sup>2</sup>Centre de Génétique et Centre de Référence Anomalies du Développement et Syndromes Malformatifs de l'Interrégion Est, Centre Hospitalier Universitaire Dijon, 21079 Dijon, France; <sup>3</sup>Equipe d'Accueil 4271, Génétique des Anomalies du Développement, Université de Bourgogne, 21079 Dijon, France; <sup>4</sup>Service de Neurologie Pédiatrique, Hôpital de la Timone, Assistance Publique des Hôpitaux de Marseille, 13005 Marseille, France; <sup>5</sup>Unité Mixte de Recherche 910, Institut National de la Santé et de la Recherche Médicale, Aix-Marseille Université, 13005 Marseille, France; <sup>6</sup>Service de Médecine Infantile 1, Centre de Référence des Maladies Héritaires du Métabolisme, Centre Hospitalier Universitaire Brabois-Enfants, 54511 Vandœuvre-lès-Nancy, France; <sup>7</sup>Laboratoire de Génétique Moléculaire, Plateau Technique de Biologie, Centre Hospitalier Universitaire Dijon, 21079 Dijon, France; <sup>8</sup>Département de Neurologie Pédiatrique, Hôpital Gui de Chauliac, 34295 Montpellier, France; <sup>9</sup>Institut National de la Santé et de la Recherche Médicale Unité 1051, Institut des Neurosciences de Montpellier, 34172 Montpellier, France; <sup>10</sup>Genetics and Cytogenetics Department, Centre de Référence Déficiences Intellectuelles de Causes Rares, Pitié-Salpêtrière, Assistance Publique des Hôpitaux de Paris, 75013 Paris, France; <sup>11</sup>Unité de Neurologie Pédiatrique, Centre Hospitalier Universitaire Nancy, 54000 Nancy, France; <sup>12</sup>Service de Génétique Médicale, Centre Hospitalier Universitaire Nantes, 44000 Nantes, France; <sup>13</sup>Department of Genetics, Lyon University Hospital, 69000 Lyon, France; <sup>14</sup>Unité Mixte de Recherche 5292, Centre National de la Recherche Scientifique, 69000 Lyon, France; <sup>15</sup>Centre d'Investigation Neurologique Adulte et Pédiatrique pour les Soins en Epileptologie, Centre Saint Paul, Hôpital Henri Gastaut, 13009 Marseille, France; <sup>16</sup>Centre Référent des Troubles du Langage et des Apprentissages, Hôpital d'Enfants, Centre Hospitalier Universitaire Dijon, 21079 Dijon, France; <sup>17</sup>Service de Génétique, Centre Hospitalier Universitaire Tours, 37000 Tours, France; <sup>18</sup>Service de Pédiatrie 1, Centre Hospitalier Universitaire Dijon, 21079 Dijon, France; <sup>19</sup>Service d'Odontologie-Stomatologie, Centre Hospitalier Universitaire de Dijon, 21079 Dijon, France; <sup>20</sup>Service pédiatrie 1, Centre Hospitalier Universitaire de Strasbourg - Hôpital de Hautepierre, 67098 Strasbourg, France; <sup>21</sup>Service de Génétique Clinique, Centre Hospitalier Universitaire Rennes, 35200 Rennes, France; <sup>22</sup>Laboratoire de Génétique Médicale, Centre Hospitalier Universitaire Nancy, 54511 Vandœuvre-lès-Nancy, France

\*Correspondence: [julien.thevenon@chu-dijon.fr](mailto:julien.thevenon@chu-dijon.fr) (J.T.), [jean-baptiste.riviere@u-bourgogne.fr](mailto:jean-baptiste.riviere@u-bourgogne.fr) (J.-B.R.)

<http://dx.doi.org/10.1016/j.ajhg.2014.06.006>. ©2014 by The American Society of Human Genetics. All rights reserved.



**Figure 1. Pedigrees of the Three Families with *SLC13A5* Mutations**

Individuals for whom exome sequencing was performed are indicated by asterisks (\*). The subject with a homozygous *BCKDHB* mutation is indicated by the symbol ◻. Detection of the identified *SLC13A5* variants was performed in all available individuals. *mut/mut* and *mut/+* refer to compound heterozygous and heterozygous carriers of *SLC13A5* mutations, respectively. *+/-* indicate individuals for whom no *SLC13A5* mutation was identified.

diagnostic yield, careful clinical and EEG description of epileptic syndromes is needed for improved management of affected individuals.<sup>5-7</sup>

We ascertained two families comprising seven affected individuals with strikingly similar clinical presentations of EOOE. The pedigrees (families 1 and 2, shown in Figure 1) were highly suggestive of an autosomal-recessive mode of inheritance. For all subjects, brain imaging (including magnetic resonance imaging [MRI] and computerized tomography scanner [CT-scan]), infectious work-up in blood as well as urine and cerebrospinal fluid (CSF), and metabolic work-ups were not conclusive. In family 1, subject 1 (II-1 in Figure 1) was born after an unremarkable full-term pregnancy. American Pediatric Gross Assessment Record (APGAR) was 10/10 with eutocic delivery. Clinical and neurological examinations were reported as unremarkable at birth. At day 1, he experienced a multifocal status epilepticus characterized by long-lasting focal seizures alternately involving right and left temporo-occipital areas. There was no evidence for a materno-fetal infection. Seizures were subclinical (Table 1) albeit almost continuous during the first days of life. Initial EEG revealed oscillating delta-theta waves that increased in amplitude, lasting more than 2 min and restricted to the temporal and occipital brain areas. Interictal EEG was low in amplitude, without suppression bursts. Overall, the recurrence of focal seizures with almost no interictal period for several hours led to the clinical diagnosis of neonatal multifocal status epilepticus. After the age of 2 months, epileptic activity became rarer and responded well to antiepileptic drugs, with persistence of some seizures triggered by fever. Clinical evolution was characterized by a major psychomotor delay with no eye contact and global hypotonia without pyramidal syndrome. No facial dysmorphism was noticed, except for widely spaced teeth. Growth, including occipito-frontal circumference (OFC), was normal. Subject 2 (II-3 in Figure 1) was born after an uneventful pregnancy at 35 weeks of gestation, with birth parameters in normal

range. Delivery was complicated by inhalation of meconial amniotic fluid requiring an initial hospitalization in intensive care unit for assisted ventilation. APGAR was 3/5/7. At 5 days of life, she presented with a status epilepticus, controlled by the association of three antiepileptic drugs. Status epilepticus was well tolerated despite a succession of prolonged, focal seizures with very short interictal periods. Epileptic signs included chewing movements and modification of breath occurring several seconds after the beginning of the EEG discharge. EEG showed rhythmic theta-delta focal discharges originating alternatively from both hemispheres, mostly in the left and right temporal regions (a representative EEG is shown in Figure 2). No truly migrating seizures could be observed. Brain MRI showed no lesions suggestive of a perinatal insult. At 2 years and 4 months of age, clinical examination showed axial hypotonia without peripheral hypertonia or pyramidal syndrome. Ocular contact was good with smiling response. Head was controlled but sitting was not acquired. Voluntary grasping was absent. Growth and OFC were normal. Although subject 2 showed a better psychomotor development than subject 1 indicating some degree of intrafamilial phenotypic variability, both affected individuals from family 1 display a severe EE with absent speech and no sitting position.

Family 2 is an Algerian family harboring two consanguinity loops. In the first nuclear family, three out of five children developed a severe EE. In all children, antenatal period and delivery were unremarkable. Subject 3 (V-1 in Figure 1) presented polymorphic seizures beginning in the first day of life and associating cyanosis, hemibody abnormal movements, upper limbs clonus, and abnormal ocular movements. The first status epilepticus was reported at 1 month of life and required a therapeutic association of three antiepileptic drugs to stabilize a monthly occurrence of seizures. Psychomotor milestones were not acquired, with poor eye contact and no sitting at 5 years of age. Fewer epileptic manifestations were reported over follow-up. No facial dysmorphism was noticed except for widely spaced teeth, also observed in family 1. EEGs were asymmetrically slower on right side. A mild perceptive deafness

**Table 1. Clinical Hallmark of the Epileptic Disease and Psychomotor Acquisitions of the Eight Reported Subjects**

Clinical Hallmarks	Family 1		Family 2				Family 3	
	Subject 1	Subject 2	Subject 3	Subject 4	Subject 5	Subject 6	Subject 7	Subject 8
Epilepsia type	EOEE	EOEE	EOEE	EOEE	EOEE	EOEE	EOEE	EOEE
Age at first seizures	1 day	5 days	1 day	1 day	1 day	1 week	1 week	1 day
Age at first status epilepticus	1 day	5 days	1 month	none	1 day	NA	NA	1 day
Seizure type	subclinical	subclinical	polymorphic	subclinical	subclinical	NA	subclinical	subclinical
Psychomotor acquisitions	profound delay	severe delay	profound delay	severe delay	severe delay	profound delay	profound delay	profound delay
Eye contact	no	yes	poor	yes	yes	yes	yes	yes
Head control	no	yes	yes	yes	yes	yes	yes	yes
Sitting acquired	no	no	no	yes	no	no	no	yes
Speech	none	none	none	none	none	none	none	none

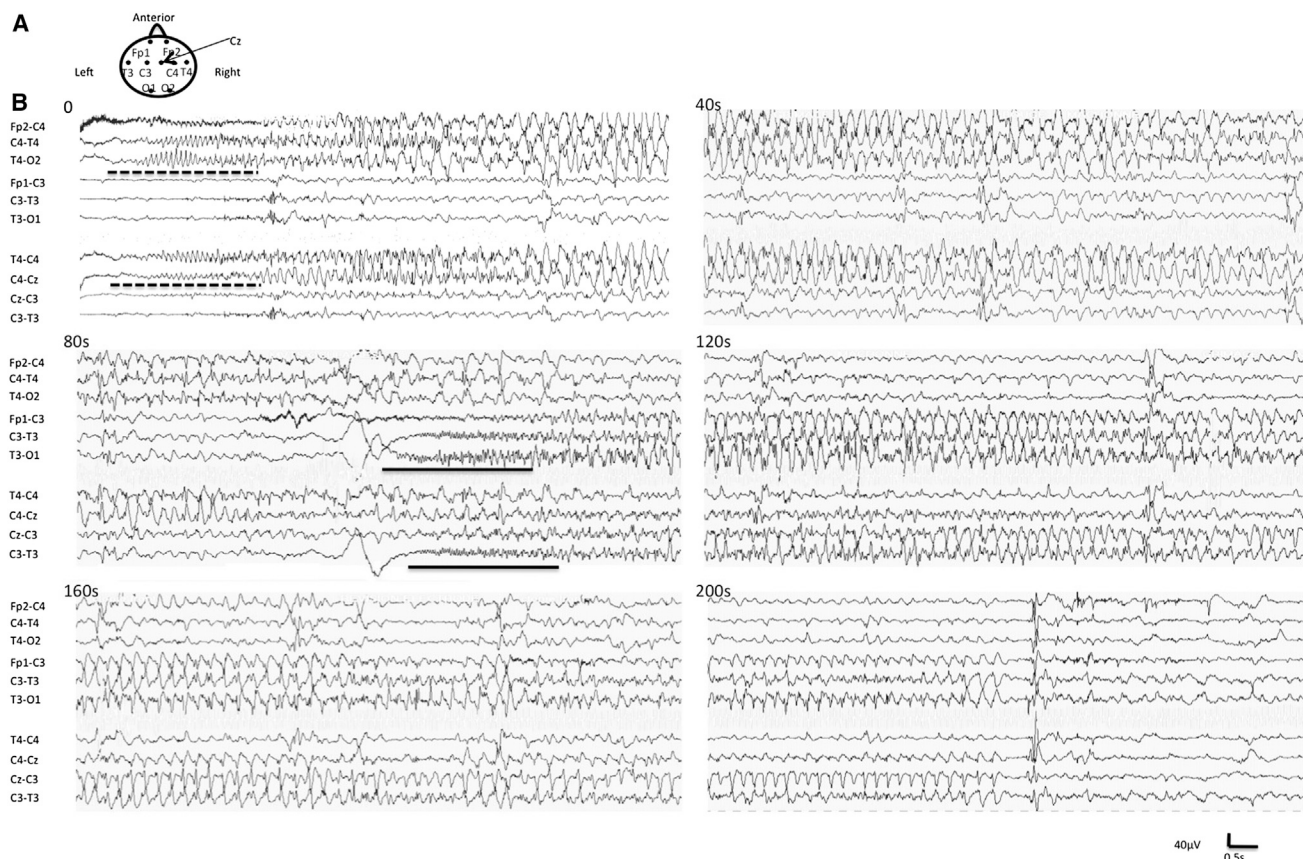
Abbreviations are as follows: EOEE, early onset epileptic encephalopathy; NA, not available.

was reported. Subject 4 (V-2 in Figure 1) was born after an uneventful pregnancy. A perinatal suffering was suspected and required resuscitation. He presented seizures at 8 hr of life. A neonatal subdural hematoma was reported. Given the family history, antiepileptic drugs were introduced early. Psychomotor acquisitions were markedly delayed. At 5 years of age, he was able to say several words. He kept presenting weekly seizures. Neurological examination showed axial hypotonia and peripheral hypertonia with brisk tendon reflexes. No facial dysmorphism was noticed, except for hypodontia. Growth parameters including OFC were in normal range. Subject 5 (V-5 in Figure 1) was born at full term of an uneventful pregnancy. Birth measurements and APGAR were normal. He presented a status epilepticus resistant to standard therapeutics at 20 hr of life. A maple syrup disease (MIM 248600) was diagnosed on plasmatic amino acid chromatographs, which was confirmed by the identification of a homozygous truncating mutation (c.799C>T [p.Gln267\*]) in *BCKDHB* (RefSeq accession number NM\_183050.2, MIM 248611). Segregation analysis in other family members showed that subjects 3 and 4 were heterozygous carriers. Dietary care biochemically controlled perfectly the maple syrup disease, with normal chromatography at follow-up. Evolution was marked by a severe psychomotor delay. Walk had not been acquired by the age of 3 years. Epilepsy was very active in the first months of age with almost continuous subclinical seizures. EEG showed almost continuous sequences of focal seizures involving temporal and occipital regions of both hemispheres alternatively, mostly the left one, with rhythmic, large-amplitude spikes lasting several minutes. There was no suppression burst. After 1 month of age, EEG rapidly improved, and a background activity was recorded and found normal. After 3 months, some asymptomatic, short generalized discharges of spikes were recorded. Subjects 6 and 7 (V-6 and V-9 in Figure 1) presented a severe EE with seizure onset in the first days of life. Subject 6 (V-6 in Figure 1) died at 11 years of age of unknown cause. Sub-

ject 7 (V-9 in Figure 1) presents epileptic seizures at 5 years of age.

We propose that the combination of clinical findings observed in affected individuals from the two families (summarized in Table 1, with additional clinical information in Table S1 available online) define a distinctive epileptic phenotype. Evidence supporting a genetic etiology included (1) the context of familial forms of EE; (2) brain imaging and clinical evolution, which did not support neonatal insult as the cause of the clinical presentation; and (3) the fact that neonatal suffering may be both a consequence of, and a contributing factor to, the observed epileptic disease. Clinical hallmarks comprise nonmotor and pharmacoresistant seizures with onset in the first days of life evolving to pharmacoresistant EE in the first months, profound psychomotor delay, and neonatal EEG showing a recurrent pattern of multifocal long-lasting temporo-occipital seizures involving both hemispheres.

We hypothesized that the observed clinical presentation in the two families was due to mutations in the same gene and performed exome sequencing in three affected individuals (II-1, II-3, and V-5 in Figure 1). Written, informed consent was obtained from all subjects, legal representatives, and relatives before enrollment in the study. The ethics committee at participating institutions approved the research protocol. Genomic DNA was extracted from blood via standard procedures. Whole-exome capture and sequencing were performed at Integrigen from 3 μg of genomic DNA per individual using the SureSelect Human All Exon V5 kit (Agilent). The resulting libraries were sequenced on a HiSeq 2000 (Illumina) according to the manufacturer's recommendations for paired-end 76 bp reads. More than 4.8 gigabases of mappable sequences per individual were generated, resulting in a depth of coverage of at least ten reads for more than 93% of RefSeq coding exons (Table S2). Reads were aligned to the human genome reference sequence (GRCh37/hg19 build



**Figure 2. Subject 2: Epileptic Activity with Long-Lasting Multifocal Bilateral Seizures during the First Week of Life**  
 (A) Schematic representation of the electrode placement according to the international standards in neonate (subject 2 at fifth day of life).  
 (B) Longitudinal (lines 1–6) and transverse montage (lines 7–10) showing a typical seizure beginning in the right hemisphere, temporal region (dotted line), lasting around 100 s and immediately followed by a seizure originating in the left hemisphere, temporal lobe (full trace) beginning at around 100 s and lasting 130 s. Clinically, the discharge was not symptomatic initially, then the neonate displayed chewing movements (20<sup>th</sup> s), discrete clonic jerks of the left limbs (50<sup>th</sup> s), and discrete clonic jerks of the right limbs (130<sup>th</sup> s).

of UCSC Genome Browser) with the Burrows-Wheeler Aligner (BWA, v.0.6.2), and potential duplicate paired-end reads were marked with Picard v.1.77. The Genome Analysis Toolkit (GATK) v.2.6-4 was used for base quality score recalibration, indel realignment, and variant discovery (both single-nucleotide variants and indels).<sup>8</sup> Variants were annotated with SeattleSeq SNP Annotation. Rare variants were identified by focusing on protein-altering and splice-site changes present at a frequency less than 1% in dbSNP 138 and the NHLBI GO Exome Sequencing Project and absent from 50 local exomes of unaffected individuals.

Candidate genes consistent with an autosomal-recessive mode of inheritance were systematically identified based on the presence of at least one rare homozygous or two heterozygous variants as described previously.<sup>9</sup> This strategy led to identification of a single gene mutated in all three affected individuals (Table S3), namely *SLC13A5* (MIM 608305; RefSeq NM\_177550.3), which encodes the only known neuronal cytoplasmic sodium-dependent citrate carrier.<sup>10</sup> Both affected individuals from family 1 were compound heterozygous for two *SLC13A5* missense changes (c.655G>A [p.Gly219Arg] and c.680C>T [p.Thr227Met])

(Figure S1), and subject 5 from family 2 had a homozygous *SLC13A5* missense change (c.1463T>C [p.Leu488Pro]) (Figure S1; Table 2). Cosegregation analysis in all available relatives by standard polymerase-chain-reaction (PCR) protocols using custom intronic primers (Table S4) and capillary sequencing confirmed the association of the identified *SLC13A5* mutations with EOEE in both families (Figure 1).

We then screened *SLC13A5* for mutations in 68 unrelated individuals with EOEE, including 61 subjects with unclassified epilepsy and 7 subjects with suppression-burst EEG patterns. Overall, 29 subjects had onset of seizures in the first week of life combined with severe psychomotor delay, and 15 out of these 29 individuals had been screened for mutations in *STXBP1* and *KCNQ2*, which had failed to identify disease-associated variants. Coding regions of *SLC13A5* were amplified by standard PCR protocols (primer sequences are listed in Table S4). For each individual, PCR products were pooled and libraries were prepared with the Nextera XT DNA Sample Preparation kit (Illumina). Generated libraries were sequenced on a MiSeq instrument (Illumina) according to the manufacturer's

**Table 2. Main Characteristics of *SLC13A5* Mutations**

Families	Genomic Change (hg19)	dbSNP ID	Allele Frequency in ESP	Transcript Change	Protein Change	Sodium Binding Site	GERP Score	Grantham Matrix Score	Polyphen2 (HumVar)	Condel FI Score	CADD Phred Score	Inheritance
Family 1	chr17:g.6606325G>A	none	0/13006	c.680C>T	p.Thr227Met	Na1	5.470	81	1.000	4.195	25.3	compound heterozygous
	chr17:g.6606350C>T	rs144332569 <sup>a</sup>	0/13006	c.655G>A	p.Gly219Arg	Na1	5.470	125	0.998	4.3	19.74	
Family 2	chr17:g.6590960A>G	none	0/13006	c.1463T>C	p.Leu488Pro	Na2	5.150	98	0.997	3.155	21.5	homozygous
	chr17:g.6590960A>G	none	0/13006	c.1463T>C	p.Leu488Pro	Na2	5.150	98	0.997	3.155	21.5	
Family 3	chr17:g.6606325G>A	none	0/13006	c.680C>T	p.Thr227Met	Na1	5.470	81	1.000	4.195	25.3	compound heterozygous
	chr17:g.6606350C>T	rs144332569 <sup>a</sup>	0/13006	c.655G>A	p.Gly219Arg	Na1	5.470	125	0.998	4.3	19.74	
Family 4	chr17:g.6606350C>T	rs144332569 <sup>a</sup>	0/13006	c.655G>A	p.Gly219Arg	Na1	5.470	125	0.998	4.3	19.74	heterozygous <sup>b</sup>

Abbreviations are as follows: hg19, Human Genome version 19; dbSNP ID, database of single nucleotide polymorphism identification; ESP, NHLBI GO Exome Sequencing Project.

<sup>a</sup>Reported in dbSNP 134 with neither frequency nor validation data

<sup>b</sup>No other *SLC13A5* variants were detected in this subject

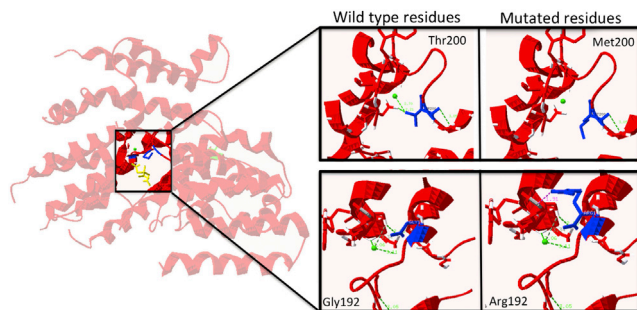
recommendations for paired-end 150 bp reads. Sequencing data processing and variant identification were performed as described above, except that PCR duplicates were not marked. The average sequencing depth of *SLC13A5* coding exons (RefSeq) and splice junctions was 2,158-fold, with 100% of targeted bases covered by at least 10 reads in all subjects. This experiment led to identification of one additional subject with identical compound heterozygous mutations as those found in family 1 (c.655G>A [p.Gly219Arg] and c.680C>T [p.Thr227Met]; family 3 in Figure 1). Single-nucleotide variants flanking the identified mutations seem to argue against identity by descent and support distinct mutational events in families 1 and 3, at least for one of the two variants (Table S5).

In striking similarity with the clinical presentation of affected individuals from families 1 and 2, this subject developed subclinical seizures at 2 hr of life and presented with a severe epileptic disease that evolved to a pharmacoresistant EE associated with major developmental delay (Tables 1 and S1). Highly frequent focal seizures lasting several days were initially noticed, followed by periods of relative stability (with rare occasional seizures) alternating with clusters of seizures occurring once or twice a year. No seizures were recorded by video/EEG. Interictal EEGs were well organized.

An additional heterozygous *SLC13A5* variant (c.655G>A [p.Gly219Arg]) was detected in another subject (family 4, Table 2). Clinical presentation of this affected individual—which comprised seizure onset at 1 month of age and mild psychomotor delay associated with autism spectrum disorder—showed no similarity with the phenotype of affected individuals with recessive *SLC13A5* mutations. In the absence of a second detectable mutation of *SLC13A5* in this individual and given the fact that heterozygous carriers of the p.Gly219Arg mutation in families 1 and 3 are unaffected, we conclude that this mutation alone is unlikely to cause the observed phenotype. No other coding variants were identified in the remaining 66 individuals tested.

Nucleotide-level conservation and impact of amino acid substitutions were assessed by the Genomic Evolutionary Rate Profiling (GERP),<sup>11</sup> Grantham matrix,<sup>12</sup> Polyphen-2 (using the HumVar-trained model),<sup>13</sup> and Combined Annotation-Dependent Depletion (CADD)<sup>14</sup> scores. All mutation sites were found to affect highly conserved nucleotides and amino acids and were predicted as likely deleterious (Table 2, Figure S2). None of the three mutations were reported in the NHLBI GO Exome Sequencing Project. However, one of the mutations was reported in dbSNP v.134, with neither frequency nor validation data (Table 2).

*SLC13A5* encodes a highly conserved homodimeric cytoplasmic sodium-dependent citrate carrier composed of 11 transmembrane domains. Functional and structural work on VcINDY—the bacterial orthologous of *SLC13A5*—showed that sodium binding is required for citrate transport and identified two sodium binding domains:<sup>15</sup> one at residue VcINDY-Gly199 (HsSLC13A5-Gly226) and the second



**Figure 3. In Silico Prediction of the Impact of SLC13A5 Mutations on Sodium Binding**

Left panel represents 3D model of VcINDY, SLC13A5 bacterial ortholog (PDB 4F35). Citrate molecule (yellow) and the first sodium-binding site (green) are shown. Right panels are 6 Å zoomed-in focuses of both wild-type and mutated residues. Protein structure data were loaded in the Swiss-PDB viewer and mutated residues introduced, with the most probable rotamer selected. Hydrogen bonds were computed by standard parameters.

one between residues VcINDY-Glu374 and VcINDY-Cys413 (HsSLC13A5-Glu475 and HsSLC13A5-Phe500, respectively). Intracellular citrate transport was shown to be dramatically reduced when these latter two residues are mutated.<sup>16,17</sup> In addition, systematic mutagenesis of SLC13A5 carboxy-terminal region demonstrated the conformational role of the highly conserved residue HsSLC13A5-Leu488 (rbSLC13A5-Leu502) for dicarboxylic acid binding and transport.<sup>18,19</sup> Strikingly, all three mutations sites reported here affect either the first sodium-binding site (p.Gly219Arg and p.Thr227Met in families 1 and 3) or the second one (p.Leu488Pro in family 2). This hypothesis is further supported by in silico predictions of the impact of p.Gly219Arg and p.Thr227Met mutations on the first sodium binding site, which show a marked disruption of hydrogen bonds (Figure 3). We can therefore speculate that these mutations may affect the ability of SLC13A5 to transport citrate across the plasma membrane to the cytosol by disrupting its ability to bind sodium.

Citrate plays a pivotal role for cellular metabolism and neurotransmitter biogenesis such as glutamate in the brain. Intracellular citrate metabolism is essential for tri-carboxylic acids synthesis and mitochondrial energetic balance, and the rate of fatty-acid synthesis depends on the concentration of citrate in the cytosol, which is mainly controlled by SLC13A5.<sup>20</sup> Disruption of citrate metabolism and transport were previously associated with epilepsy. For instance, mutations in the mitochondrial di- and tri-carboxylic acid transporters *SLC25A1* (MIM 190315) and *SLC25A22* (MIM 609302) cause hydroxyglutaric aciduria (MIM 615182) and early infantile epileptic encephalopathy-3 (MIM 609304), respectively.<sup>21,22</sup> Conversely, increased citrate synthetase activity in rat brain homogenates was observed after convulsing doses of 3-mercaptopropionic acid, thus indicating that high intracellular citrate concentrations may be an endogenous anticonvulsive mechanism.<sup>23</sup> Finally, although *Slc13a5*-knockout mice have no signs of developmental or neurological abnormalities, knockout

mice of two of the five SLC13 family members develop seizures.<sup>15,24,25</sup>

Neonatal epilepsies are highly heterogeneous in terms of etiology and electro-clinical features. Approximately 20% of neonatal-onset EE of genetic origin are caused by mutations in three major genes, namely *STXBPI*<sup>26</sup> (MIM 602926), *KCNQ2*<sup>27</sup> (MIM 602235), and *KCNT1*<sup>28</sup> (MIM 608167). Mutations in these genes are mostly associated with malignant migrating partial seizure<sup>28</sup> or with suppression-burst pattern.<sup>29,30</sup> Here, we describe a form of epilepsy associated with *SLC13A5* mutations and presenting with status epilepticus in the first days of life, EEG patterns showing bilateral, multifocal, long-lasting nonmigrating seizures and severe neurological evolution despite a decrease of seizure frequency concomitant with a rapid improvement of the EEG background activity. Screening a cohort of 29 subjects with seizure onset in the first week of life combined with severe psychomotor delay identified one additional individual with *SLC13A5* mutations and a very similar clinical and EEG presentation as the two index families. Given the rarity of epileptic seizures with onset in the first day of life and the recognizable EEG pattern described here, *SLC13A5* may be considered as an additional gene to be screened in individuals with seizures in the first day of life for molecular diagnosis purposes.

To conclude, we propose the existence of an autosomal-recessive and clinically distinctive EE associated with *SLC13A5* mutations, whose main clinical features comprise seizure onset in the first days of life, subclinical epileptic status, and recognizable EEG patterns with bilateral, multifocal status epilepticus. Altogether, these findings underline the value of careful clinical characterization for genetic investigations in highly heterogeneous conditions such as EE, might have direct implications for the clinical management of this subset of individuals with seizure onset in the first week of life, and further highlight the role of citrate metabolism in epilepsy. Finally, these findings may ultimately open therapeutic perspectives aimed at increasing intracellular citrate concentration, such as ketogenic diet or triheptanoin treatment.<sup>31,32</sup>

### Supplemental Data

Supplemental Data include two figures and five tables and can be found with this article online at <http://dx.doi.org/10.1016/j.ajhg.2014.06.006>.

### Acknowledgments

We wish to thank the subjects and families involved in the study, C.T. Gordon for kind advice, Integragen for the exome sequencing experiments, and the University of Burgundy Centre de Calcul (CCuB) for technical support and management of the informatics platform. This work was supported by the Regional Council of Burgundy and Dijon University Hospital. We also thank the NHLBI GO Exome Sequencing Project and its ongoing studies that produced and provided exome variant calls for comparison: the Lung GO Sequencing Project (HL-102923), the WHI Sequencing

Project (HL-102924), the Broad GO Sequencing Project (HL-102925), the Seattle GO Sequencing Project (HL-102926), and the Heart GO Sequencing Project (HL-103010).

Received: April 9, 2014  
Accepted: June 11, 2014  
Published: July 3, 2014

## Web Resources

The URLs for data presented herein are as follows:

dbSNP, <http://www.ncbi.nlm.nih.gov/projects/SNP/>  
NHLBI Exome Sequencing Project (ESP) Exome Variant Server, <http://evs.gs.washington.edu/EVS/>  
Online Mendelian Inheritance in Man (OMIM), <http://www.omim.org/>  
Picard, <http://picard.sourceforge.net/>  
RefSeq, <http://www.ncbi.nlm.nih.gov/RefSeq>  
SeattleSeq Annotation 138, <http://snp.gs.washington.edu/SeattleSeqAnnotation138/>  
Swiss PDB Viewer, <http://www.expasy.org/spdbv/>  
UCSC Genome Browser, <http://genome.ucsc.edu>  
University of Burgundy Centre de Calcul, <https://haydn2005.u-bourgogne.fr/dsi-ccub/>

## References

1. Dulac, O. (2001). Epileptic encephalopathy. *Epilepsia* 42 (Suppl 3), 23–26.
2. Berg, A.T., Berkovic, S.F., Brodie, M.J., Buchhalter, J., Cross, J.H., van Emde Boas, W., Engel, J., French, J., Glauser, T.A., Mathern, G.W., et al. (2010). Revised terminology and concepts for organization of seizures and epilepsies: report of the ILAE Commission on Classification and Terminology, 2005–2009. *Epilepsia* 51, 676–685.
3. Covanis, A. (2012). Epileptic encephalopathies (including severe epilepsy syndromes). *Epilepsia* 53 (Suppl 4), 114–126.
4. Berg, A.T., Nickels, K., Wirrell, E.C., Geerts, A.T., Callenbach, P.M.C., Arts, W.F., Rios, C., Camfield, P.R., and Camfield, C.S. (2013). Mortality risks in new-onset childhood epilepsy. *Pediatrics* 132, 124–131.
5. Helbig, I., and Lowenstein, D.H. (2013). Genetics of the epilepsies: where are we and where are we going? *Curr. Opin. Neurol.* 26, 179–185.
6. Carvill, G.L., Heavin, S.B., Yendle, S.C., McMahon, J.M., O’Roak, B.J., Cook, J., Khan, A., Dorschner, M.O., Weaver, M., Calvert, S., et al. (2013). Targeted resequencing in epileptic encephalopathies identifies de novo mutations in CHD2 and SYNGAP1. *Nat. Genet.* 45, 825–830.
7. Allen, A.S., Berkovic, S.F., Cossette, P., Delanty, N., Dlugos, D., Eichler, E.E., Epstein, M.P., Glauser, T., Goldstein, D.B., Han, Y., et al.; Epi4K Consortium; Epilepsy Phenome/Genome Project (2013). De novo mutations in epileptic encephalopathies. *Nature* 501, 217–221.
8. McKenna, A., Hanna, M., Banks, E., Sivachenko, A., Cibulskis, K., Kernysky, A., Garimella, K., Altshuler, D., Gabriel, S., Daly, M., and DePristo, M.A. (2010). The Genome Analysis Toolkit: a MapReduce framework for analyzing next-generation DNA sequencing data. *Genome Res.* 20, 1297–1303.
9. Ng, S.B., Buckingham, K.J., Lee, C., Bigham, A.W., Tabor, H.K., Dent, K.M., Huff, C.D., Shannon, P.T., Jabs, E.W., Nickerson, D.A., et al. (2010). Exome sequencing identifies the cause of a mendelian disorder. *Nat. Genet.* 42, 30–35.
10. Pajor, A.M. (2014). Sodium-coupled dicarboxylate and citrate transporters from the SLC13 family. *Pflügers Arch.* 466, 119–130.
11. Cooper, G.M., Goode, D.L., Ng, S.B., Sidow, A., Bamshad, M.J., Shendure, J., and Nickerson, D.A. (2010). Single-nucleotide evolutionary constraint scores highlight disease-causing mutations. *Nat. Methods* 7, 250–251.
12. Grantham, R. (1974). Amino acid difference formula to help explain protein evolution. *Science* 185, 862–864.
13. Adzhubei, I.A., Schmidt, S., Peshkin, L., Ramensky, V.E., Gerasimova, A., Bork, P., Kondrashov, A.S., and Sunyaev, S.R. (2010). A method and server for predicting damaging missense mutations. *Nat. Methods* 7, 248–249.
14. Kircher, M., Witten, D.M., Jain, P., O’Roak, B.J., Cooper, G.M., and Shendure, J. (2014). A general framework for estimating the relative pathogenicity of human genetic variants. *Nat. Genet.* 46, 310–315.
15. Mancusso, R., Gregorio, G.G., Liu, Q., and Wang, D.-N. (2012). Structure and mechanism of a bacterial sodium-dependent dicarboxylate transporter. *Nature* 491, 622–626.
16. Griffith, D.A., and Pajor, A.M. (1999). Acidic residues involved in cation and substrate interactions in the Na<sup>+</sup>/dicarboxylate cotransporter, NaDC-1. *Biochemistry* 38, 7524–7531.
17. Inoue, K., Fei, Y.-J., Zhuang, L., Gopal, E., Miyauchi, S., and Ganapathy, V. (2004). Functional features and genomic organization of mouse NaCT, a sodium-coupled transporter for tricarboxylic acid cycle intermediates. *Biochem. J.* 378, 949–957.
18. Kahn, E.S., and Pajor, A.M. (1999). Determinants of substrate and cation affinities in the Na<sup>+</sup>/dicarboxylate cotransporter. *Biochemistry* 38, 6151–6156.
19. Pajor, A.M. (2001). Conformationally sensitive residues in transmembrane domain 9 of the Na<sup>+</sup>/dicarboxylate co-transporter. *J. Biol. Chem.* 276, 29961–29968.
20. Gopal, E., Miyauchi, S., Martin, P.M., Ananth, S., Srinivas, S.R., Smith, S.B., Prasad, P.D., and Ganapathy, V. (2007). Expression and functional features of NaCT, a sodium-coupled citrate transporter, in human and rat livers and cell lines. *Am. J. Physiol. Gastrointest. Liver Physiol.* 292, G402–G408.
21. Nota, B., Struys, E.A., Pop, A., Jansen, E.E., Fernandez Ojeda, M.R., Kanhai, W.A., Kranendijk, M., van Dooren, S.J.M., Bevova, M.R., Sistermans, E.A., et al. (2013). Deficiency in SLC25A1, encoding the mitochondrial citrate carrier, causes combined D-2- and L-2-hydroxyglutaric aciduria. *Am. J. Hum. Genet.* 92, 627–631.
22. Molinari, F., Raas-Rothschild, A., Rio, M., Fiermonte, G., Encha-Razavi, F., Palmieri, L., Palmieri, F., Ben-Neriah, Z., Kadhom, N., Vekemans, M., et al. (2005). Impaired mitochondrial glutamate transport in autosomal recessive neonatal myoclonic epilepsy. *Am. J. Hum. Genet.* 76, 334–339.
23. Girardi, E., and Lores Arnaiz, G.R. (1985). Citrate synthase activity increases in homogenates of the cerebral cortex from rats treated with the convulsant 3-mercaptopropionic acid. *Neurochem. Int.* 7, 683–688.
24. Birkenfeld, A.L., Lee, H.-Y., Guebre-Egziabher, F., Alves, T.C., Jurczak, M.J., Jornayvaz, F.R., Zhang, D., Hsiao, J.J., Martin-Montalvo, A., Fischer-Rosinsky, A., et al. (2011). Deletion of the mammalian INDY homolog mimics aspects of dietary restriction and protects against adiposity and insulin resistance in mice. *Cell Metab.* 14, 184–195.

25. Bergeron, M.J., Cl emen on, B., Hediger, M.A., and Markovich, D. (2013). SLC13 family of Na<sup>+</sup>-coupled di- and tri-carboxylate/sulfate transporters. *Mol. Aspects Med.* 34, 299–312.
26. Saitsu, H., Kato, M., Mizuguchi, T., Hamada, K., Osaka, H., Tohyama, J., Uruno, K., Kumada, S., Nishiyama, K., Nishimura, A., et al. (2008). De novo mutations in the gene encoding STXBP1 (MUNC18-1) cause early infantile epileptic encephalopathy. *Nat. Genet.* 40, 782–788.
27. Weckhuysen, S., Ivanovic, V., Hendrickx, R., Van Coster, R., Hjalgrim, H., M oller, R.S., Gr onborg, S., Schoonjans, A.-S., Ceulemans, B., Heavin, S.B., et al.; KCNQ2 Study Group (2013). Extending the KCNQ2 encephalopathy spectrum: clinical and neuroimaging findings in 17 patients. *Neurology* 81, 1697–1703.
28. Barcia, G., Fleming, M.R., Deligniere, A., Gazula, V.-R., Brown, M.R., Langouet, M., Chen, H., Kronengold, J., Abhyankar, A., Cilio, R., et al. (2012). De novo gain-of-function KCNT1 channel mutations cause malignant migrating partial seizures of infancy. *Nat. Genet.* 44, 1255–1259.
29. Milh, M., Villeneuve, N., Chouchane, M., Kaminska, A., Laroche, C., Barthez, M.A., Gitiaux, C., Bartoli, C., Borges-Correia, A., Cacciagli, P., et al. (2011). Epileptic and nonepileptic features in patients with early onset epileptic encephalopathy and STXBP1 mutations. *Epilepsia* 52, 1828–1834.
30. Milh, M., Boutry-Kryza, N., Sutura-Sardo, J., Mignot, C., Auvin, S., Lacoste, C., Villeneuve, N., Roubertie, A., Heron, B., Carneiro, M., et al. (2013). Similar early characteristics but variable neurological outcome of patients with a de novo mutation of KCNQ2. *Orphanet J. Rare Dis.* 8, 80.
31. Kovac, S., Abramov, A.Y., and Walker, M.C. (2013). Energy depletion in seizures: anaplerosis as a strategy for future therapies. *Neuropharmacology* 69, 96–104.
32. Borges, K., and Sonnewald, U. (2012). Triheptanoin—a medium chain triglyceride with odd chain fatty acids: a new anaplerotic anticonvulsant treatment? *Epilepsy Res.* 100, 239–244.