

CASE REPORT

Primary Lymphohistiocytic Variant of Anaplastic Large Cell Lymphoma of the Stomach

Chii-Shuenn Yang¹, Guan Chou^{1*}, Yee-Jee Jan^{1,4}, John Wang^{1,4}, Dah-Cherng Yeh², Chieh-Lin Teng³

Departments of ¹Pathology, ²General Surgery and ³Hematology and Oncology, Taichung Veterans General Hospital, and ⁴College of Medicine, Chung Shan Medical University, Taichung, Taiwan, R.O.C.

Here, we report an unusual case of gastric anaplastic large cell lymphoma (ALCL), lymphohistiocytic variant, in a 70-year-old female patient who presented with epigastric pain, tarry stool and body weight loss. Endoscopic and imaging findings revealed a Bormann type II tumor in the stomach with perigastric lymphadenopathy and multiple tumor nodules in the liver. Total gastrectomy and liver biopsy were performed. Histologically, both gastric and hepatic tumors demonstrated anaplastic large neoplastic cells scattered among numerous reactive histiocytes. Immunostaining of these tumor cells reacted positively for CD30, CD3, CD45RO/UCHL1, and negatively for epithelial membrane antigen, CD68, lysozyme, CD15, CD79a, CD138, PAX5 and anaplastic lymphoma kinase. Both the morphologic and immunophenotypic findings supported the diagnosis of gastric ALCL of lymphohistiocytic variant with liver metastasis. This patient then received chemotherapy and was still alive after 17 months of follow-up, without evidence of residual disease. [*J Chin Med Assoc* 2007;70(2):71–75]

Key Words: anaplastic large cell lymphoma, anaplastic lymphoma kinase, lymphohistiocytic variant, stomach

Introduction

Anaplastic large cell lymphoma (ALCL) is a subgroup of non-Hodgkin's lymphoma first described by Stein et al in 1985.¹ It is characterized by large atypical lymphoid cells with pleomorphic and often horseshoe-shaped nuclei and abundant cytoplasm, called hallmark cells. These tumor cells show strong expression of CD30 antigen.² Only T cell or null-cell phenotypes are included in ALCL. The B cell phenotype is excluded and classified as anaplastic large cell variant of diffuse large B cell lymphoma.³ The most common sites of ALCL involvement are the lymph node, followed by skin, bone and soft tissue.⁴

According to molecular and clinical criteria, there are 3 categories of ALCLs: primary systemic ALK(+) ALCL; primary systemic ALK(-) ALCL; and primary cutaneous ALCL. Anaplastic lymphoma kinase (ALK) expression is predominantly caused by the genetic abnormality of t(2;5) translocation. The translocation leads to the nucleophosmin (NPM) gene over 5q35 fusing with the ALK gene over 2p23 and results in the formation of NPM-ALK fusing protein. ALK(+)

ALCL mostly occurs in the first 3 decades of life, with male predominance. It has a better response to chemotherapy and better prognosis for survival, whereas ALK(-) ALCL usually occurs in older patients and has a comparably dismal clinical course.³

Primary gastric ALCLs are extremely rare.^{1,5–18} To our knowledge, only 22 cases have been reported in the English literature, and none of them seemed to be of the lymphohistiocytic variant, which is observed mostly in the first 2 decades of life with initial presentation of superficial lymphadenopathy.¹⁹ We herein report a unique case of primary lymphohistiocytic variant ALCL of the stomach in an elderly patient.

Case Report

A 70-year-old female was referred to our hospital due to epigastric pain, tarry stool, and body weight loss for half a year after March 2004. Physical examination on admission showed neither cutaneous skin lesions nor superficial lymphadenopathy. Hematologic examination results were as follows: white blood cell count,

*Correspondence to: Dr Guan Chou, Department of Pathology, Taichung Veterans General Hospital, 160, Section 3, Taichung-Kang Road, Taichung 407, Taiwan, R.O.C.
E-mail: chii.shuenn@msa.hinet.net • Received: June 30, 2006 • Accepted: December 7, 2006



Figure 1. Gastric mucosa shows an ulcerative lesion with neoplastic cell infiltration throughout the whole layer of stomach (hematoxylin & eosin, 40 \times).

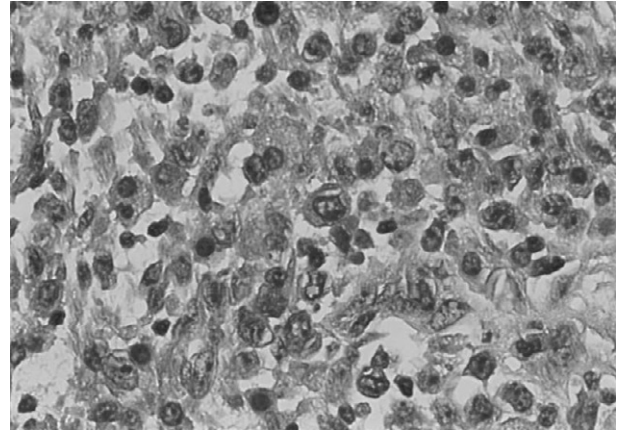


Figure 2. Neoplastic cells show round to oval, large irregular and occasionally kidney-shaped nuclei and single or multiple nucleoli with a mild to moderate amount of cytoplasm (hematoxylin & eosin, 400 \times).

2,180/ μ L; hemoglobin, 7.9 g/dL; hematocrit, 37.8%; platelet count, 11,900/ μ L; aspartate aminotransferase, 332 U/L; alanine aminotransferase, 96 U/L; lactate dehydrogenase, 1,798 U/L; and alkaline phosphatase, 262 U/L. Laboratory data of electrolytes and renal function test were within normal limits. Serologic tests were negative for both the human T cell leukemia virus (HTLV-1) and Epstein-Barr virus (EBV).

An upper gastrointestinal endoscopy was performed, which showed an ulcerative tumor with adjacent superficial ulcer and thickening of the stomach wall, suggesting a malignant neoplasm. Computed tomography showed mild thickening of the stomach wall with perigastric lymphadenopathy and multiple tumor nodules in bilateral lobes of the liver. Due to uncontrolled upper gastrointestinal bleeding, emergent total gastrectomy with regional lymph node dissection and liver biopsy were performed.

The resected specimen of the stomach showed an ulcerative tumor, Bormann type II, 2 \times 2 cm, located in the middle third of the posterior wall, protruding to the lesser sac with serosal invasion. There was also a superficial ulcer adjacent to the main tumor. Marked thickening of the gastric wall from mid-body to antrum, enlarged perigastric lymph nodes, up to 3 \times 2 \times 1 cm, and peritoneal tumor seeding over the greater curvature site and mesentery were found. The specimen of the liver measured 1.3 \times 0.7 \times 0.5 cm.

Histologically, the gastric mucosa showed an ulcerative lesion covered with a layer of inflammatory exudates (Figure 1), and the whole layer of the gastric wall was diffusely infiltrated with discohesive medium- to large-sized atypical cells admixed with a large number of reactive histiocytes, a few lymphocytes and plasma cells. These histiocytes had eccentric, round,

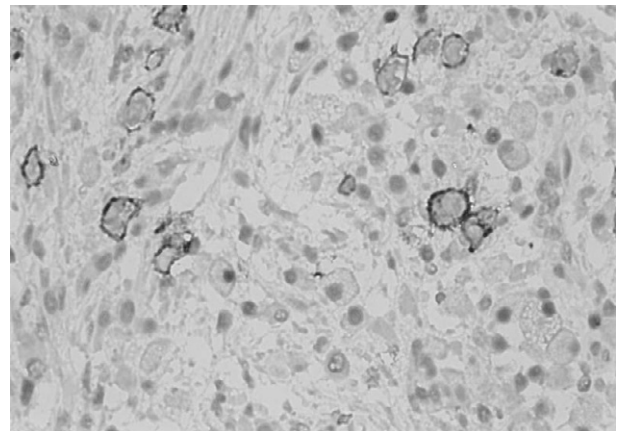


Figure 3. CD30 staining demonstrates positive reactivity on the membrane of lymphoma cells (400 \times).

dense nuclei and acidophilic cytoplasm reminiscent of plasma cells. The neoplastic cells displayed round to oval, large, irregular and sometimes horseshoe- or kidney-shaped nuclei and single or multiple distinct nucleoli with a mild to moderate amount of cytoplasm (Figure 2). Clustering of the neoplastic cells around the blood vessels was also observed. Immunohistochemistry showed that the tumor cells stained positively for CD30 (Figure 3), LCA, CD45RO (UCHL1) and CD3 (Figure 4); negatively for CD20 (L26), CD68, myeloperoxidase (MPO), lysozyme, epithelial membrane antigen (EMA), CD15, CD79a, CD138, PAX5 and ALK. Moreover, the histiocytes showed moderate cytoplasmic staining for CD68 (Figure 5) and lysozyme. The histologic pictures and immunohistochemical characteristics of these tumors in the liver, perigastric lymph nodes and peritoneum were similar to those of the stomach. Based on the morphologic

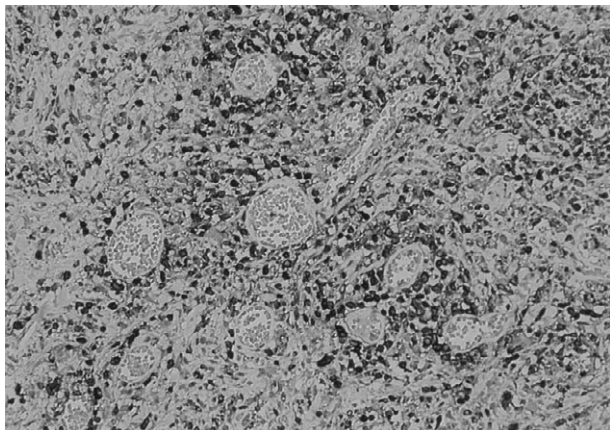


Figure 4. Large-sized neoplastic cells are strongly positive for CD3 and predominate around blood vessels (200 \times).

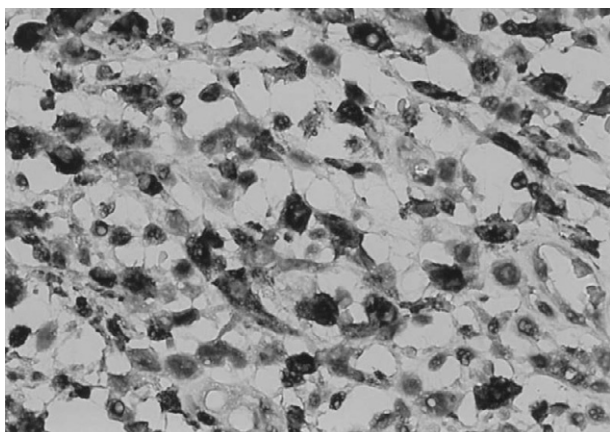


Figure 5. Reactive histiocytes show cytoplasmic staining with CD68 antibody (400 \times).

and immunohistochemical findings, a diagnosis of primary gastric ALCL of lymphohistiocytic variant with involvement of perigastric lymph nodes, peritoneum and liver metastasis was made.

The other workup showed normal chest X-ray and gallium bone scan. The pancreas, spleen and kidney were unremarkable on ultrasonography and bone marrow biopsy was normal. The patient then received postoperative chemotherapy with the CHOP regimen (cyclophosphamide, adriamycin, oncovin, prednisolone). She was still alive without evidence of tumor nodules in the liver and without intra-abdominal lymphadenopathy after 17 months of follow-up.

Discussion

ALCL can be subclassified into common (classic) type (70%), lymphohistiocytic variant (10%), small cell variant (5–10%) and other rare patterns. However, all

cases of ALCL have a variable number of cells with eccentrically placed horseshoe- or kidney-shaped nuclei, often with an eosinophilic region near the nucleus, the so-called hallmark cells.^{2,3} Clinically, most cases of lymphohistiocytic ALCL occur during the first 2 decades of life, at a younger age than the common type of ALCL, and usually present with superficial lymphadenopathy and systemic symptoms.^{19,20} Histologically, lymphohistiocytic ALCL exhibits tumor cells admixed with abundant reactive histiocytes. The neoplastic cells are usually smaller than those of the common type. The reactive histiocytes have prominent acidophilic cytoplasm and an eccentric, dense nucleus and sometimes contain phagocytosed erythrocytes that may mask the neoplastic cells.^{3,19,20} Perivascular cuffing of the tumor cells, which can be reinforced with immunostaining of CD30 or ALK, is a dominant feature and diagnostic hint to this variant of ALCL.² The large anaplastic cells of lymphohistiocytic ALCL can express CD30 and are usually immunoreactive for EMA and ALK, but are nonreactive for histiocytic markers.³ In contrast to the common variant of ALCL, it shows a comparably favorable response to chemotherapy.^{19,20}

The main differential diagnosis includes undifferentiated carcinoma, Hodgkin's lymphoma, and histiocytic sarcoma.^{3,12,19,21} Primary gastric ALCL may sometimes be misdiagnosed as gastric carcinoma from radiologic and endoscopic findings, microscopic pictures or immunohistochemical properties.^{12,14,22–24} The endoscopic and imaging findings of gastric ALCLs vary. They may show a protruding mass with ulceration or an ulcerative tumor. Under such circumstances, it is often difficult to distinguish lymphoma from carcinoma. However, they may occasionally present as a submucosal tumor with/without superficial ulceration, which is quite different from conventional gastric carcinoma.²² Microscopic morphology can be misinterpreted as undifferentiated carcinoma because the tumor cells may show cohesive change, especially in the affected lymph nodes.²³ Immunohistochemically, the neoplastic cells of ALCL may occasionally express cytokeratin and epithelial membrane antigen, whereas LCA (CD45) expression is not always the rule.^{23,25} Therefore, performing immunohistochemistry analyses for cytokeratin, LCA and CD30 antigen simultaneously is suggested when poorly differentiated tumors are encountered.¹²

There may be morphologic overlap between ALCL and Hodgkin's lymphoma. Classical Hodgkin's lymphoma rich in neoplastic cells sometimes has morphologic features indistinguishable from those of ALCL. However, the frequent expression of B cell-specific activation protein BSAP (PAX-5) and essentially no

Table 1. Clinicopathologic and immunohistochemical features of previously reported cases of gastric anaplastic large cell lymphomas

Case	Authors	Year	Age/Sex	Type	LN	ALK	EMA	Tx	Follow-up survival
1	Stein et al	1985	17/M	Null	N/A	N/A	N/A	N/A	N/A
2	Moubayed et al	1987	18/M	T	+	N/A	N/A	S/C	A3 yr
3	Kanavaros et al	1988	58/M	T	+	N/A	-	S/C	A12 mo
4	Chan et al	1989	79/F	T	+	N/A	+	S	DOD 6 wk
5	Paulli et al	1994	75/F	Null	+	N/A	N/A	C	A20 mo
6	Paulli et al	1994	35/M	Null	+	N/A	N/A	S/C	DOD 23 mo
7	Paulli et al	1994	82/F	T	+	N/A	N/A	None	DOD 45 d
8	Yatabe et al	1994	59/M	T	-	N/A	-	S/C	DOD 10 mo
9	Takimoto et al	1994	29/M	T	+	N/A	-	S/C	DOD 31 mo
10	Biernat et al	1994	37/F	T	N/A	N/A	+	N/A	N/A
11	Mori et al	1994	31/M	Null	-	N/A	-	S	A96 mo
12	Mori et al	1994	63/M	Null	-	N/A	-	S	A24 mo
13	Griesser et al	1994	48/M	T	N/A	N/A	(+)	N/A	N/A
14	Griesser et al	1994	36/M	T	N/A	N/A	+	N/A	N/A
15	Griesser et al	1994	79/M	T	N/A	N/A	-	N/A	N/A
16	Griesser et al	1994	80/M	T	N/A	N/A	-	N/A	N/A
17	Griesser et al	1994	79/F	T	N/A	N/A	+	N/A	N/A
18	Nakamura et al	1998	73/F	T	+	N/A	-	S	D7 wk
19	Kahaleh et al	2002	45/M	T	+	-	N/A	S/C	A24 mo
20	Lee et al	2003	68/F	Null	N/A	+	N/A	N/A	N/A
21	Iwamizu-Watanabe et al	2004	72/F	Null	N/A	+	+	S	A84 mo
22	Song et al	2005	50/F	T	+	-	-	S/C	A7 mo

LN = lymph node; ALK = anaplastic lymphoma kinase; EMA = epithelial membrane antigen; Tx = treatment; T = T cell; N/A = not available; (+) = only a few positive tumor cells; S = surgery; C = chemotherapy; A = alive; DOD = died of disease; D = died.

reactivity for ALK may favor a tumor cell-rich Hodgkin's lymphoma rather than ALCL.^{2,3}

Histiocytic sarcoma is a malignant neoplasm showing morphologic and immunologic features similar to those of mature histiocytes. Immunohistochemically, the neoplastic cells can express macrophage markers (lysozyme, CD68), but are nonreactive for CD30, EMA, HMB45 and keratin.²¹

Primary gastric ALCLs are extremely rare. To the best of our knowledge, only 22 cases have been reported so far in the English literature, as summarized in Table 1. These patients ranged in age from 17 years to 82 years, with a mean age of 55 years; there was a slight male predominance (F/M ratio: 9/13). Fifteen cases displayed T cell phenotype and 7 cases showed null cell type. Ten (77%) of 13 patients showed regional lymph node involvement. Histologically, the reactive cells included lymphocytes, histiocytes, plasma cells, neutrophils, and eosinophils. However, none of the cases seemed to feature numerous reactive histiocytes. Most patients underwent surgery with or without subsequent chemotherapy. Only 1 patient was treated with chemotherapy alone. Gastric ALCL has an extremely poor prognosis. Nakamura et al reported that analysis of 12 patients with gastric ALCL (including

1 B cell phenotype) revealed an estimated 5-year survival rate of 13%,¹⁴ whereas a study involving a large series of ALCL patients showed that the 5-year overall survival rate of ALK(+) versus ALK(-) ALCL was 93% versus 37%.²⁶

References

- Stein H, Mason DY, Gerdes J, O'Connor N, Wainscoat J, Pallesen G, Gatter K, et al. The expression of the Hodgkin's disease associated antigen Ki-1 in reactive and neoplastic lymphoid tissue: evidence that Reed-Sternberg cells and histiocytic malignancies are derived from activated lymphoid cells. *Blood* 1985;66:848-58.
- Delsol G, Ralfkiaer E, Stein H, Wright D, Jaffe S. Anaplastic large cell lymphoma. In: Jaffe ES, Harris NL, Stein H, Vardiman JW, eds. *WHO Classification of Tumors of Haematopoietic and Lymphoid Tissue: Pathology & Genetics*. Lyon: IARC Press, 2001: 230-5.
- Stein H, Foss HD, Durkop H, Marafioti T, Delsol G, Pulford K, Pileri S, et al. CD30+ anaplastic large cell lymphoma: a review of its histopathologic, genetic, and clinical features. *Blood* 2000; 96:12:3681-95.
- Brugieres L, Deley MC, Pacquement H, Meguerian-Bedoyan Z, Terrier-Lacombe MJ, Robert A, Pondarre C, et al. CD30+ anaplastic large cell lymphoma in children: analysis of 82 patients enrolled in two consecutive studies of the French Society of Pediatric Oncology. *Blood* 1998;92:3591-8.

5. Moubayed P, Kaiserling E, Stein H. T-cell lymphomas of the stomach: morphological and immunological studies characterizing two cases of T-cell lymphoma. *Virchows Arch A Pathol Anat Histopathol* 1987;411:523-9.
6. Kanavaros P, Lavergne A, Galian A, Houdart R, Bernard JF. Primary gastric peripheral T-cell malignant lymphoma with helper/inducer phenotype: first case report with a complete histological ultrastructural and immunochemical study. *Cancer* 1988;61:1602-10.
7. Chan JK, Ng CS, Hui PK, Leung TW, Lo ES, Lau WH, McGuire LJ. Anaplastic large cell Ki-1 lymphoma: delineation of two morphological types. *Histopathology* 1989;15:11-34.
8. Paulli M, Rosso R, Kindl S, Boveri E, Bonoldi E, Stracca V, Motta T, et al. Primary gastric CD30 (Ki-1)-positive large cell non-Hodgkin's lymphomas: a clinicopathologic analysis of six cases. *Cancer* 1994;73:541-9.
9. Yatabe Y, Mori N, Oka K, Nakazawa M, Asai J. Primary gastric T-cell lymphoma: morphological and immunohistochemical studies of two cases. *Arch Pathol Lab Med* 1994;118:547-50.
10. Takimoto Y, Tanaka H, Tanabe O, Kuramoto A, Sasaki N, Nanba K. A patient with anaplastic large cell lymphoma (Ki-1 lymphoma) showing clonal integration of HTLV-1 proviral DNA. *Leukemia* 1994;8:507-9.
11. Biernat W. Ki-1-positive anaplastic large cell lymphoma: a morphologic and immunologic study of 14 cases. *Pol J Pathol* 1994;45:39-44.
12. Mori N, Yatabe Y, Oka K, Yokose T, Ishido T, Kikuchi M, Asai J. Primary gastric Ki-1 positive anaplastic large cell lymphoma: a report of two cases. *Pathol Int* 1994;44:164-9.
13. Griesser H, Henry M, Boie C, Banerjee D. Large-cell anaplastic lymphoma of the gastrointestinal tract: an immuno- and genotypic study on archival material. *Hematol Pathol* 1994;8:121-34.
14. Nakamura S, Aoyagi K, Ohkuni A, Kimura Y, Tsuneyoshi M, Fujishima M. Rapidly growing primary gastric CD30 (Ki-1)-positive anaplastic large cell lymphoma. *Dig Dis Sci* 1998;43:300-5.
15. Kahaleh M, Hermans P, Buset M, Dargent JL. Primary neutrophil-rich, CD30-positive anaplastic large cell lymphoma of the stomach: case report and review of the literature. *Acta Gastroenterol Belg* 2002;65:237-40.
16. Lee LY, Harpaz N, Strauchen JA. Posttransplant CD30+ (Ki-1) anaplastic large cell lymphoma: a case report and review of the literature. *Arch Pathol Lab Med* 2003;127:349-51.
17. Iwamizu-Watanabe S, Yamashita Y, Yatabe Y, Nakamura S, Mori N. Frequent expression of CD30 antigen in the primary gastric non-B, non-Hodgkin lymphomas. *Pathol Int* 2004;54:503-9.
18. Song HH, Baik GH, Kwon JH, Lee KS, Choi YH, Choi KC, Park YE. A case of primary gastric CD30-positive anaplastic large cell lymphoma. *J Korean Med Sci* 2005;20:1062-5.
19. Pileri S, Falini B, Delsol G, Stein H, Baglioni P, Poggi S, Martelli MF, et al. Lymphohistiocytic T-cell lymphoma (anaplastic large cell lymphoma CD30+/Ki-1 + with a high content of reactive histiocytes). *Histopathology* 1990;16:383-91.
20. Pileri SA, Pulford K, Mori S, Mason DY, Sabatini E, Roncador G, Piccioli M, et al. Frequent expression of the NPM-ALK chimeric fusion protein in anaplastic large-cell lymphoma, lymphohistiocytic type. *Am J Pathol* 1997;150:1207-11.
21. Weiss LM, Dura T, Grogan TM, Favara B, Muller-Hermelink HK, Paulli M, Stein H, et al. Histiocytic sarcoma. In: Jaffe ES, Harris NL, Stein H, Vardiman JW, eds. *WHO Classification of Tumors of Haematopoietic and Lymphoid Tissue: Pathology & Genetics*. Lyon: IARC Press, 2001:278-9.
22. Fenoglio-Preiser C, Munoz N, Carneiro F, Powell SM, Correa P, Ruggie M, Guilford P, et al. Gastric carcinoma. In: Hamilton SR, Aaltonen LA, eds. *WHO Classification of Tumors of the Digestive System: Pathology & Genetics*. Lyon: IARC Press, 2000:39-52.
23. Ross CW, Hanson CA, Schnitzer B. CD30 (Ki-1)-positive, anaplastic large cell lymphoma mimicking gastrointestinal carcinoma. *Cancer* 1992;70:2517-23.
24. Tiu CM, Pan HB, Chou YH, Chiang JH, Chang T. Computed tomography of gastric lymphoma. *J Chin Med Assoc* 1988;42:463-8.
25. Gustmann C, Altmannsberger M, Osborn M, Griesser H, Feller AC. Cytokeratin expression and vimentin content in large cell anaplastic lymphomas and other non-Hodgkin's lymphomas. *Am J Pathol* 1991;138:1413-22.
26. Gascoyne RD, Aoun P, Wu D, Chhanabhai M, Skinnider BF, Greiner TC, Morris SW, et al. Prognostic significance of anaplastic lymphoma kinase (ALK) protein expression in adults with anaplastic large cell lymphoma. *Blood* 1999;93:3913-21.