

ORIGINAL ARTICLE

Computer Simulation of Hemodynamic Changes After Right Lobectomy in a Liver with Intrahepatic Portal Vein Aneurysm

Cheng-Maw Ho,¹ Shun-Feng Tsai,² Reui-Kuo Lin,³ Po-Chin Liang,⁴ Tony Wen-Hann Sheu,³ Rey-Heng Hu,¹ Po-Huang Lee^{1*}

Background/Purpose: Intrahepatic portal vein aneurysm is rare and its natural history is unknown. A 22-year-old healthy man, who wished to donate part of his liver to his diseased father, was incidentally diagnosed to have an intrahepatic portal vein aneurysm. The surgical decision of performing live donor hepatectomy for such a patient is normally difficult. We combined modern imaging reconstruction technologies with scientific computing as a new modality to foresee the risks of surgical complications.

Methods: Cross-sectional computed tomography images were used to reconstruct the three-dimensional image of portal vein distribution using the 3D-Doctor v3.5 software. The reconstructed images were further employed to generate surface and interior meshes with CFX software. Simulated hemodynamic changes in velocity, pressure, and wall stress were determined for the right lobectomy case pre- and postoperatively.

Results: The simulation results indicated that aneurismal pressure would be elevated significantly to 12.03 mmHg after operation. The left segmental portal venous blood flow would increase from 2.95- to 4.25-fold. The area near the branch point of one left segmental portal vein, which supplies blood to liver segment 4, and the portal vein aneurysm would endure high shear stress gradient. The resulting elevated aneurismal pressure may cause the thin wall to enlarge and rupture, while the high shear stress gradient would lead to vascular endothelial cell injury. Living donor surgery was not recommended hemodynamically based on the simulated results.

Conclusion: Scientific computing and modern imaging technologies can be applied together to aid surgeons to make the best decision in difficult clinical situations. [*J Formos Med Assoc* 2007;106(8):617-623]

Key Words: intrahepatic portal vein aneurysm, pressure, simulation, shear stress

Aneurysms in the portal venous system, either in localized fusiform or saccular dilatations, represent only 3% of all aneurysms of the venous system.¹ Portal vein aneurysms are usually asymptomatic and detected incidentally during diagnostic work-up. With the emergence of noninvasive imaging tools, portal vein aneurysm is increasingly found in clinical practice.²⁻⁴ They are known to be located more frequently in the extrahepatic rather than the intrahepatic segment.^{5,6} We encountered a case of

potential live liver donor who was incidentally diagnosed to have an intrahepatic portal vein aneurysm with the right deviated umbilical portion (Figure 1A). To determine if the operation would be safe, a scientific tool was employed as an aid to help us make the right surgical decision. To this end, the computing-and-imaging technique was proposed in this study and was demonstrated to be a useful modality in the current difficult clinical selection of the live liver donor.

©2007 Elsevier & Formosan Medical Association

Departments of ¹Surgery and ⁴Medical Imaging, National Taiwan University Hospital, ²Department of Marine Engineering, National Taiwan Ocean University, and ³Department of Engineering Science and Ocean Engineering, National Taiwan University, Taipei, Taiwan.

Received: October 31, 2006
Revised: December 13, 2006
Accepted: April 10, 2007

***Correspondence to:** Professor Po-Huang Lee, Department of Surgery, National Taiwan University Hospital, 7 Chung-Shan South Road, Taipei 100, Taiwan.
E-mail: pohuang@ha.mc.ntu.edu.tw

Methods

Patient

A 22-year-old healthy male was admitted for live liver donor evaluation for his father who was diagnosed to have end-stage liver disease.

Liver imaging

Serial transverse scans of the liver were taken with a GE CT/T 8800 (GE Medical Systems, Milwaukee, WI, USA) at 3-mm intervals. All slices of the liver were traced on an exact direct proportion between weight and area. The paper weight of all the hepatic areas was measured with a microestimation balance, and the total area of them was gained from the proportional line. Portal phase images were captured to facilitate the computer-assisted simulation. An intrahepatic portal vein aneurysm is shown in Figure 1B.

Portal vein velocity measurement

The sonographic examination was performed using an ultrasound HDI 3500 system (Advanced Technology Laboratories Inc., Bothell, WA, USA)

with a 3.75-MHz sector transducer. A longitudinal image of the portal vein was obtained. The portal vein color Doppler was recorded under an angle of less than 50°. The main portal vein velocity was measured to be 10 cm/sec (Figure 1C).

Visual vascular reconstruction

Image segmentation was conducted to divide the image into different subregions. With the help of AMIRA® 4.0 (Mercury Computer Systems Inc., Chelmsford, MA, USA), segmentation was made by firstly selecting voxels and then assigning them to a particular material. The labels were stored in a *LabelField*. The *Segmentation Editor* enables us to edit the resulting label field so as to render the polygonal surfaces using the *SurfaceGen* module.

Computer-assisted data processing

Our blood flow simulations used mesh generated from the portal vein geometric model using the computational fluid dynamics package CFX® mesh generator software (CFX-F3D; AEA Technology, Harwell, UK). CFX mesh generator supports the fully automatic generation of meshes starting from

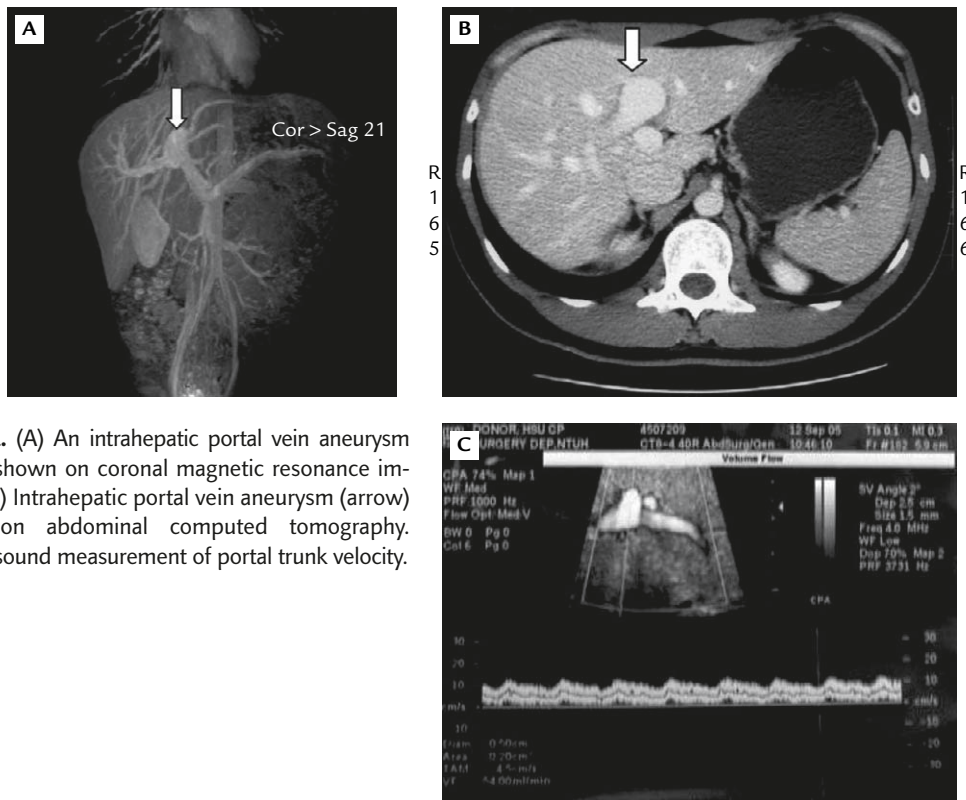


Figure 1. (A) An intrahepatic portal vein aneurysm (arrow) shown on coronal magnetic resonance imaging. (B) Intrahepatic portal vein aneurysm (arrow) shown on abdominal computed tomography. (C) Ultrasound measurement of portal trunk velocity.

domain definitions including non-manifold geometric models and discrete representations. CFX is implemented as a validated toolkit system^{7,8} that supports the mesh generation and modification procedures including: (1) automatic anisotropic size control, (2) boundary layer meshing for portal flows, and (3) adaptive mesh refinement.

The model was simplified in that it does not take into account the full structures and branches of the portal vein. The vessel was hypothesized to be inelastic and without consideration of the neighboring effect of liver parenchyma. Boundary conditions specified at the portal outflows were hypothesized to be stress-free. Blood flow was Newtonian flow. The right portal vein was removed from the portal vein model so as to be able to make a comparison of the hemodynamic results for the model constructed prior to the operation. Our aim was to assess the feasibility of the living donor right lobectomy. The velocity, pressure, and shear stress distributions could be scientifically computed pre- and postoperatively from the working equations governing the mass and movement conservations.

Results

An aneurysm, 2.4 cm in diameter, was observed at the umbilical portion of the left portal vein. Figure 2 shows the reconstructed three-dimensional image of the left portal vein aneurysm. The pre- and postoperative portal veins, schematically represented in Figures 3A and 3B, respectively, were constructed by using the CFX mesh generator

software. The simulated velocity, pressure and shear stress distributions are separately shown in Figures 4, 5 and 6, respectively. The simulated results indicated that aneurysmal pressure would be elevated significantly to 12.03 mmHg after operation. The left segmental portal venous blood flow would increase from 2.95- to 4.25-fold. The area near the branch point of one left segmental portal vein, which supplies blood to liver segment 4, and the portal vein aneurysm would endure high shear stress gradient. The area near the junction of one left segmental portal vein (labeled L3 in Figure 3A), which supplies blood to liver segment 4, and the portal vein aneurysm would bear high wall shear stress gradient. The pre- and postoperative changes in blood flow patterns are more precisely summarized in the Table. The resulting elevated

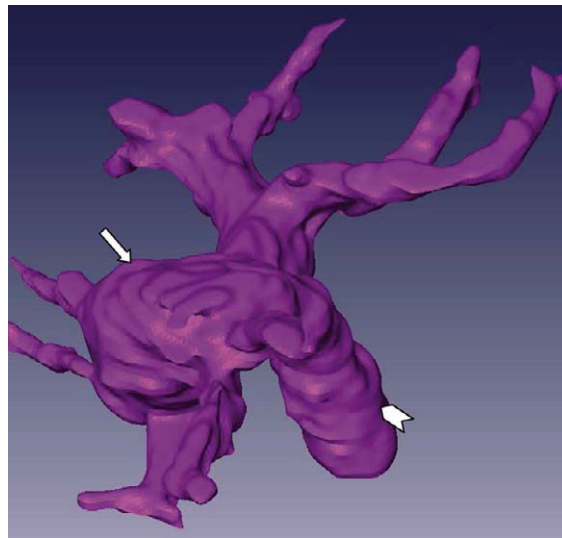


Figure 2. The reconstructed intrahepatic portal vein aneurysm (arrow). The main portal vein is marked with an arrowhead.

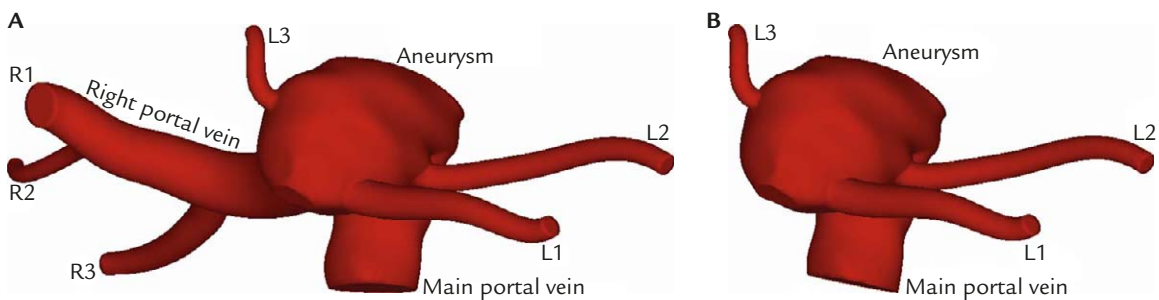


Figure 3. (A) Reconstructed geometric model of the portal vein with aneurysm. (B) The postoperative reconstructed geometric model of the portal vein.

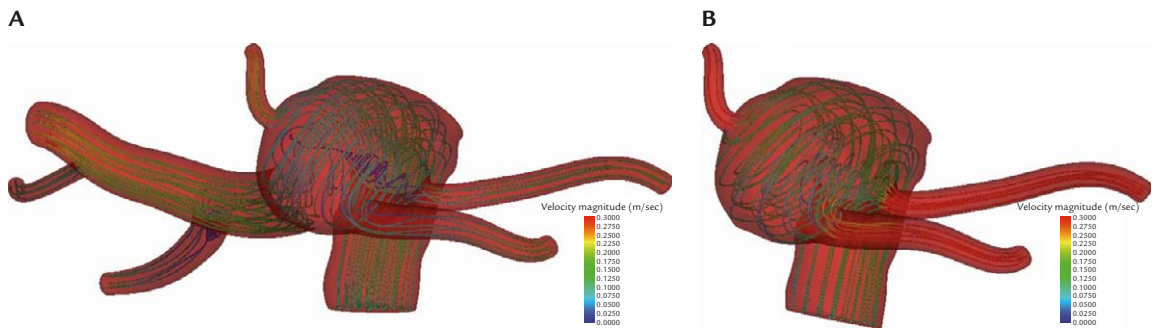


Figure 4. Simulated particle tracers in the portal vein branches and aneurysm: (A) preoperatively; (B) postoperatively.

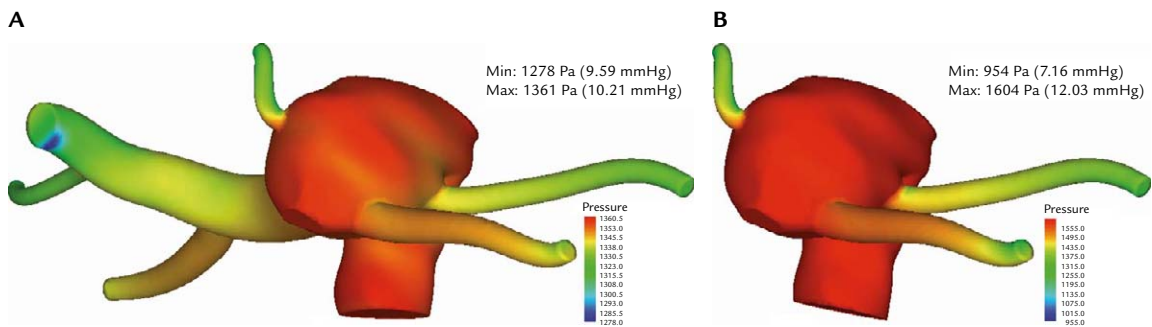


Figure 5. Simulated pressure contours in the portal vein branches and aneurysm: (A) preoperatively; (B) postoperatively. The predicted maximal aneurismal pressure increased from 10.21 mmHg preoperatively to 12.03 mmHg postoperatively.

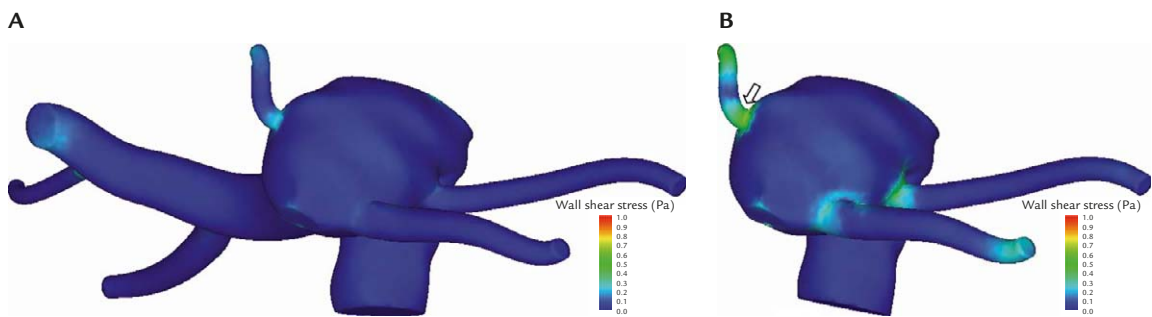


Figure 6. Simulated shear stress contours in the portal vein branches and aneurysm: (A) preoperatively; (B) postoperatively. The branch point of the left medial segmental portal vein with the blood supplying liver segment 4 and portal vein aneurysm endured high shear stress gradient postoperatively (arrow).

Table. Predicted portal vein flow rates pre- and postoperatively

Studied vessel*	Preoperative flow rate (kg/sec)	Simulated postoperative flow rate (kg/sec)	Ratio of simulated postoperative flow rate to original flow rate
Main portal vein	0.01583	0.01583	1
Right portal vein	0.01348	—	—
R1	0.0113686	—	—
R2	0.00076527	—	—
R3	0.0113686	—	—
L1	0.0017745	0.00701343	3.95
L2	0.00164634	0.00700215	4.25
L3	0.00152723	0.00451874	2.95

*Vessel sectors as marked in Figure 3.

aneurismal pressure may cause the thin wall to enlarge and rupture, while the high shear stress gradient would lead to vascular endothelial cell injury. This patient was not recommended to be a live liver donor for his father based on the simulation results. The size of the aneurysm remained unchanged after 12 months of follow-up.

Discussion

In our study, aneurismal pressure was observed to elevate to 12.03 mmHg postoperatively. Portal vein pressure normally ranges between 5 and 10 mmHg. Under portal hypertension (> 12 mmHg), the aneurysm may be enlarged and this could result in complications such as rupture. Portal vein aneurysm is a structure with a thin wall with markedly reduced tunica intima and media.⁹ In Brock et al's report,¹⁰ it is a heterogeneous structure with some areas of irregular media. Evidence that could support the hypothesis of portal hypertension is demonstrated in the work of Mucenic et al.¹¹ They showed that portal vein aneurysm diameter was significantly reduced after splenectomy in the case of hepatosplenic schistosomiasis. According to Laplace's law, aneurismal wall tension (T) is expressed as the transmural pressure (TP) multiplied by the radius of the aneurysm (r) divided by aneurismal wall thickness (w):

$$T = TP \times r/w$$

The diameter of the portal vein aneurysm at the umbilical portion, ranging from 1.5 to 2.2 cm, is normally smaller than that of extrahepatic aneurysm.⁵ As the size of the aneurysm grows with the thinning of the vessel wall, wall tension increases and can result in a greater risk of aneurismal perforation. This observation is consistent with the previous ones that larger aneurysm size accompanies a higher risk of complications.^{1,2,4,12-14}

The area in the vicinity of the branch point of the left segmental portal vein (labeled L3 in Figure 3A) and portal vein aneurysm bears high shear stress gradient postoperatively. The physiologic

range of the shear stress in a normal vein discussed in Ishida et al's study¹⁵ was 1–6 dyne/cm². Physiologically, the shear stress will activate mechanosensors (e.g. integrins, caveolae, receptor tyrosine kinase) which, in turn, could transduce physical stimuli to biochemical signals through Akt/PKB and MAPK pathways.^{16,17} These signals will activate shear-stress mediated transcription factors and regulate the expression of genes such as the shear stress responsive element (SSRE) and the antioxidant response element (ARE),^{15,18,19} which could further cause nitric oxide production, heme oxygenase-1 (HO-1) and transforming growth factor- β (TGF- β) induction.^{16,20} These factors will inhibit thrombosis, coagulation, and migration of leukocytes, while at the same time promote endothelial cell survival.^{16,20-23} Adequate shear stress, therefore, has an antithrombotic effect.^{19,23-26} Of special interest is the favorable effects of disturbed flow on thrombosis at some branch points and geometric alterations. These sites share the common characteristics of hemodynamic disturbance, including the very small shear stress, oscillating shear stress, and high shear stress gradient.^{27,28} Shear stress with a magnitude > 70 dyne/cm² in artery will also cause endothelial erosion and neointimal growth.^{20,29}

To our knowledge, there is, however, no relevant information about the physical properties of the portal vein. The branch area of L3 in our case was simulated to take a relatively high shear stress (0.8 Pa = 8 dyne/cm²), as compared with 6 dyne/cm², and high gradients postoperatively. A model developed by DePaola et al²⁸ for large shear stress gradients shows that endothelial cells migrate away from the area of large gradient while the remaining endothelial cells divide at a high rate. The L3 region of high shear stress gradient is, therefore, the predilection site for thrombosis.

The simulated blood flow to left portal vein branches was increased by an amount of 3- to 4-fold postoperatively in our study. Portal hyperperfusion has been considered to be responsible for the organ damage frequently observed after reperfusion of small-for-size liver grafts in liver transplantation.^{30,31} This can result in hepatocyte

ballooning with tremendous mitochondrial swelling, irregular large gaps between the sinusoidal lining cells, and collapse of the space of Disse.³² The so-called small-for-size-syndrome (SFSS) has been recognized to be the main factor that could lead to graft dysfunction and poor survival in adult living donor liver transplantation with extreme size mismatch.^{31,33} The mechanism of injury, including both enhanced injury and reduced metabolic and synthetic capacity of parenchymal cells,³⁴ has been postulated to be comparable to the one that could result in progressive necrosis of the liver remnant after 85% hepatectomy in the rat.³⁵ Postoperative focal portal hyperperfusion in our case, therefore, could possibly yield similar complications as SFSS.

The currently investigated etiology of intrahepatic portal vein aneurysm may be congenital in origin. This hypothesis was supported from findings of *in utero* portal vein aneurysm.³⁶ In the case of portal vein aneurysm present at the umbilical portion, it is commonly associated with portal vein anomalies such as the rightward deviation of the umbilical portion or right anterior segmental portal vein arising directly from the left portal vein.⁵ This case was not recommended to be an appropriate live liver donor based on our simulated hemodynamic results. A regular follow-up of the aneurysm is, however, recommended in asymptomatic patients.³⁷ Spontaneous rupture or thrombosis of the aneurysm, which is usually characterized by the presentation of abdominal pain,^{13,38} needs only medical treatment. In view of the size reduction of the aneurysm noticed after these complications, the aneurismal wall tension or pressure was found to be relieved and laminar flow was restored.^{13,37}

This study has some limitations. The proposed operation was not performed for safety reasons based on the simulated postoperative results. We, therefore, do not have the actual postoperative measurements for real-life validation. Only the preoperative measurement for portal vein velocity was available; the other hemodynamic characteristics were calculated. However, we provided a potential explanatory mechanism for those with

complicated portal vein aneurysm observed in clinical practice and hope we can avoid that. Narracott et al³⁹ had developed validated models of thrombosis in cerebral aneurysm formulated within CFX. The methodology can be applied further to illustrate the postoperative change in hepatic hemodynamics in hepatic resections or living-related liver transplantation.

In conclusion, the postoperative aneurismal pressure would have increased significantly in the potential live liver donor under the current investigation. The branch area of the aneurysm and the left segmental portal vein with the blood supply to liver segment 4 would have borne very high shear stress gradients postoperatively. It was demonstrated that the scientific computing and imaging reconstruction technologies can help surgeons in their decision-making for some difficult clinical situations.

References

1. Lopez-Machado E, Mallorquin-Jimenez F, Medina-Benitez A, et al. Aneurysms of the portal venous system: ultrasonography and CT findings. *Eur J Radiol* 1998;26:210–4.
2. Gallego C, Velasco M, Marcuello P, et al. Congenital and acquired anomalies of the portal venous system. *Radiographics* 2002;22:141–59.
3. Santana P, Jeffrey B Jr, Bastidas A. Acute thrombosis of a giant portal venous aneurysm: value of color Doppler sonography. *J Ultrasound Med* 2002;21:701–4.
4. Ozbek SS, Killi MR, Pourbagher MA, et al. Portal venous system aneurysms: report of five cases. *J Ultrasound Med* 1999;18:417–22.
5. Yang DM, Yoon MH, Kim HS, et al. Portal vein aneurysm of the umbilical portion: imaging features and the relationship with portal vein anomalies. *Abdom Imaging* 2003;28:62–7.
6. Laumonier H, Montaudon M, Corneloup O, et al. CT angiography of intrahepatic portal aneurysm. *Abdom Imaging* 2005;30:755–7.
7. Muggli FA, Eisele K, Casey MV, et al. Flow Analysis in a pump diffuser—part 2: validation and limitations of CFD for diffuser flows. *ASME J Fluids Eng* 1997;119:978–84.
8. Bardina JE, Huang PG, Coakley TJ. Turbulence modeling, validation, testing and development. *NASA Technical Memorandum 110446*, April 1997.
9. Yang DM, Yoon MH, Kim HS, et al. CT findings of portal vein aneurysm caused by gastric adenocarcinoma invading the portal vein. *Br J Radiol* 2001;74:654–6.

10. Brock PA, Jordan PH Jr, Barth MH, et al. Portal vein aneurysm: a rare but important vascular condition. *Surgery* 1997;121:105–8.
11. Mucenic M, Rocha MS, Laudanna AA, et al. Treatment by splenectomy of a portal vein aneurysm in hepatosplenic schistosomiasis. *Rev Inst Med Trop S Paulo* 2002;44:261–4.
12. Kaido T, Taii A, Nakajima T. A huge intrahepatic portal vein aneurysm. *Abdom Imaging* 2005;30:69–70.
13. Ferraz-Neto BH, Sakabe D, Buttros DAB, et al. Portal vein aneurysm as late complication of liver transplantation: a case report. *Transplantation Proceedings* 2004;36:970–1.
14. Kim J, Kim MJ, Song SY, et al. Acute thrombosis of a portal vein aneurysm and development. *Clin Radiol* 2004;59:631–3.
15. Ishida T, Takahashi M, Corson MA, et al. Fluid shear stress-mediated signal transduction: how do endothelial cells transduce mechanical force into biological transduction? *Ann N Y Acad Sci* 1997;811:12–23.
16. Traub O, Berk BC. Laminar shear stress: mechanisms by which endothelial cells transduce an atheroprotective force. *Arterioscler Thromb Vasc Biol* 1998;18:677–85.
17. Chen KD, Li YS, Kim M, et al. Mechanotransduction in response to shear stress. Roles of receptor tyrosine kinases, integrins, and Shc. *J Biol Chem* 1999;274:18393–400.
18. Resnick N, Yahav H, Shay-Salit A, et al. Fluid shear stress and the vascular endothelium: for better and for worse. *Prog Biophys Mol Biol* 2003;81:177–9.
19. Chen XL, Varner SE, Rao AS, et al. Laminar flow induction of antioxidant response element-mediated genes in endothelial cells—a novel anti-inflammatory mechanism. *J Biol Chem* 2003;278:703–11.
20. Esper RJ, Nordaby RA, Vilarino JO, et al. The endothelial dysfunction. *Cardiovasc Diabetol* 2006;5:4
21. Wagner CT, Durante W, Christodoulides N, et al. Hemodynamic forces induce the expression of heme oxygenase in cultured vascular smooth muscle cells. *J Clin Invest* 1997;100:589–96.
22. Chien S, Li S, Shyy YJ. Effects of mechanical forces on signal transduction and gene expression in endothelial cells. *Hypertension* 1998;31:162–9.
23. Yamawaki H, Pan S, Lee RT, et al. Fluid shear stress inhibits vascular inflammation by decreasing thioredoxin-interacting protein in endothelial cells. *J Clin Invest* 2005;115:733–8.
24. Harrison DG. The shear stress of keeping arteries clear. *Nature Medicine* 2005;11:375–6.
25. Butterfield AB, Miller CW, Lumb WV, et al. Inverse effect of chronically elevated blood flow on atherogenesis in miniature swine. *Atherosclerosis* 1977;26:215–24.
26. Brakemeier S, Kersten A, Eichler I, et al. Shear stress-induced up-regulation of the intermediate-conductance Ca(2+)-activated K(+) channel in human endothelium. *Cardiovasc Res* 2003;60:488–96.
27. Grabowski EF, Lam FP. Endothelial cell function, including tissue factor expression, under flow conditions. *Thromb Haemost* 1995;74:123–8.
28. DePaola N, Gimbrone MA, Davies PF, Dewey CF. Vascular endothelium responds to fluid shear stress gradients. *Arterioscler Thromb* 1992;12:1254–7.
29. Waniewski J, Kurowska W, Mizerski J K, et al. The effects of graft geometry on the patency of a systemic-to-pulmonary shunt: a computational fluid dynamics study. *Artif Organs* 2005;29:642–50.
30. Marcos A, Olzinski AT, Ham JM, et al. The interrelationship between portal and arterial blood flow after adult to adult living donor liver transplantation. *Transplantation* 2000;70:1697–703.
31. Troisi R, de Hemptinne B. Clinical relevance of adapting portal vein flow in living donor liver transplantation in adult patients. *Liver Transpl* 2003;9:536–41.
32. Man K, Fan ST, Lo CM, et al. Graft injury in relation to graft size in right lobe live donor liver transplantation: a study of hepatic sinusoidal injury in correlation with portal hemodynamics and intra-graft gene expression. *Ann Surg* 2003;237:256–64.
33. Goldstein MJ, Salame E, Kapur S, et al. Analysis of failure in living donor liver transplantation: differential outcomes in children and adults. *World J Surg* 2003;27:356–64.
34. Kiuchi T, Tanaka K, Ito T, et al. Small-for-size graft in living donor liver transplantation: how far should we go? *Liver Transpl* 2003;9:S29–35.
35. Panis Y, McMullan DM, Emond JC. Progressive necrosis after hepatectomy and the pathophysiology of liver failure after massive resection. *Surgery* 1997;121:142–9.
36. Gallagher DM, Leiman S, Hux CH. *In utero* diagnosis of a portal vein aneurysm. *J Clin Ultrasound* 1993;21:147–51.
37. Lau H, Chew DK, Belkin M. Extrahepatic portal vein aneurysm: a case report and review of the literature. *Cardiovasc Surg* 2002;10:58–61.
38. Barzilai R, Kleckner MS Jr. Hemocholecyt following ruptured aneurysm of portal vein: report of a case. *Arch Surg* 1956;72:725–7.
39. Narracott A, Smith S, Lawford P, et al. Development and validation of models for the investigation of blood clotting in idealized stenoses and cerebral aneurysms. *J Artif Organs* 2005;8:56–62.