View metadata, citation and similar papers at core.ac.uk

brought to you by CORE

provided by Elsevier - Publisher Connector

J Ped Surg Case Reports 2 (2014) 239–242

Contents lists available at ScienceDirect

Journal of Pediatric Surgery CASE REPORTS

journal homepage: www.jpscasereports.com

Managing concomitant congenital diaphragmatic hernia, esophageal atresia, and tracheoesophageal fistula: A case report of a premature infant that achieved survival☆

Eric J. Charles*, Joshua M. Judge, Brooke D. Vergales, Amelia H. Randall, Bartholomew J. Kane, Eugene D. McGahren, Sara K. Rasmussen

University of Virginia Health System, 1215 Lee St, Charlottesville, VA 22903, USA

ARTICLE INFO

Article history:
Received 27 February 2014
Accepted 17 April 2014
Available online 22 May 2014

Key words:
Congenital diaphragmatic hernia
Esophageal atresia
Tracheoesophageal fistula
Premature infant

ABSTRACT

Newborns with the constellation of congenital diaphragmatic hernia (CDH), esophageal atresia (EA), and tracheoesophageal fistula (TEF) present a unique clinical situation that requires well-coordinated multidisciplinary management as it is most commonly fatal. The authors describe successful management of a premature infant diagnosed with left CDH, EA, and TEF in the United States, the first such case to be reported in this country.

© 2014 The Authors. Published by Elsevier Inc. All rights reserved.

Few cases of coexisting congenital diaphragmatic hernia (CDH), esophageal atresia (EA), and tracheoesophageal fistula (TEF) are described in the literature, with most failing to survive the perinatal period. When associated with a congenital cardiac anomaly, the mortality is even greater. The rarity of this constellation of abnormalities is demonstrated by epidemiological studies based on the California Birth Defects Monitoring Program in 2004 demonstrating only 17 cases of patients with CDH, EA, and TEF, of which 16 were stillborn or died [1]. The following case report describes a premature infant who was successfully managed at the Children's Hospital of the University of Virginia Health System (Charlottesville, Virginia, USA) with left CDH, EA, TEF, and initially presumed coarctation of the aorta.

1. Case report

A premature male infant was born via precipitous spontaneous vaginal delivery at 34 weeks gestational age weighing 1.7 kg, with known left-sided CDH, diagnosed prenatally at 20 weeks gestation, and suspected congenital cardiac disease on prenatal echocardiography. Apgar scores were 3, 5, and 8 at 1, 5, and 10 min respectively. Immediately after birth the patient was intubated, started on high-frequency oscillatory ventilation, and admitted to the neonatal intensive care unit (NICU). An enteric tube was inserted by mouth but would not pass more than 11 cm, raising the suspicion for esophageal atresia. Chest x-ray (CXR) confirmed the presence of a large left congenital diaphragmatic hernia with multiple air-filled loops of bowel, as well as the enteric tube terminating in the mid-thoracic esophagus (Fig. 1). Esophageal atresia was confirmed on follow up x-ray with contrast injection (Fig. 2).

Further evaluation revealed normal appearing kidneys, no hydrocephalus or cerebral hemorrhage, but possible coarctation of the aorta with a large patent ductus arteriosus, bidirectional shunting, and a patent foramen ovale. The patient was administered prostaglandins. An attempt was made to prevent or minimize air passage through the TEF by advancing the endotracheal tube past the fistula. However, the stomach and intestines continued to distend, making ventilation increasingly difficult (Fig. 2). A decision was made to take the patient emergently to the operating room for surgical management. Via a transverse left upper quadrant laparotomy incision, the CDH was addressed first. The intestines were reduced out of the left chest. Similar to the approach described in the Journal of Pediatric Surgery in 1996 by Sapin E et al., the TEF was controlled with a Silastic (Dow Corning, Midland, MI) vessel loop as a Rommel tourniquet at the

☆ This is an open access article under the CC BY-NC-ND license (http://creativecommons.org/licenses/by-nc-nd/3.0/).

* Corresponding author. University of Virginia Health System, Department of Surgery, P.O. Box 800679, Charlottesville, VA 22908-0679, USA. Tel.: +1 434 924 9307; fax: +1 434 243 5791.

E-mail addresses: ec4wx@virginia.edu, echarlesmd@gmail.com (E.J. Charles).

2213-5766/$ – see front matter © 2014 The Authors. Published by Elsevier Inc. All rights reserved.
http://dx.doi.org/10.1016/j.epsc.2014.04.009

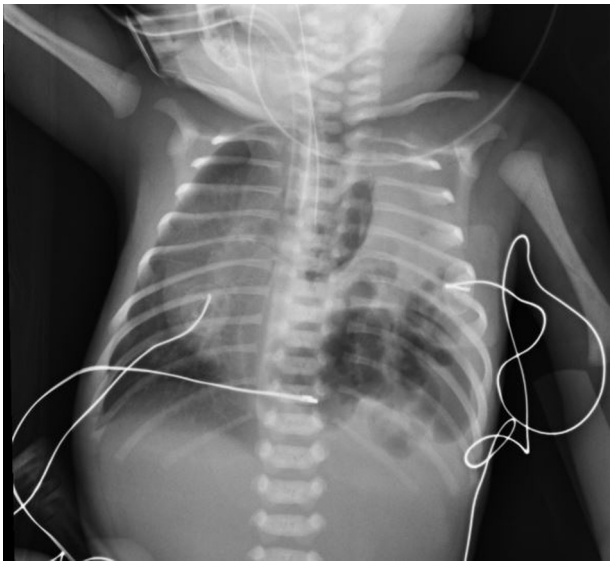

Fig. 1. Initial CXR showing herniated bowel contents in left hemithorax, as well as oral-gastric tube terminating in mid-esophagus.

gastroesophageal junction [2]. This was brought out of the right side of the abdomen through a stab incision. The posterolateral diaphragm defect was then closed with use of a Gore® Dualmesh (W.L. Gore & Associates, Inc, Newark, DE). A Stamm gastrostomy using a Malecot catheter was placed and brought out through a separate abdominal stab incision and connected to a one-way water seal valve. This allowed additional control of the tracheoesophageal fistula, as well as continued access to the stomach in case primary esophageal repair was not possible at the subsequent operation. Placement of the gastrostomy allowed for decompression of intra-luminal air from the distended intestine, which facilitated abdominal closure. The patient tolerated the procedure well and was maintained on mechanical ventilation in the NICU pending definitive TEF repair. Immediate post-operative CXR showed resolution of the left CDH with successful reduction of the herniated abdominal contents (Fig. 3).

Fig. 2. CXR with contrast injection via oral-gastric tube demonstrating blind-ending esophageal pouch and worsening gaseous distension of small bowel.

Fig. 3. Post-operative CXR showing repair of left-sided CDH.

After a trial of right-side up oscillatory ventilation, and a trial of conventional ventilation, that both demonstrated adequate left lung functionality, the patient was taken back to the operating room on day-of-life (DOL) 12. A left-sided chest tube was placed to drain a pleural effusion that had failed to resolve. Then, via a right thoracotomy, the tracheoesophageal fistula was ligated and a tension-free, primary end-to-end esophageal anastomosis was accomplished. A right-sided chest tube was placed and the patient returned to the NICU in stable, but critical condition.

He was transitioned to conventional mode ventilation on DOL 15. Trophic tube feeds were started via the gastrostomy tube on DOL 19. Prostaglandins were stopped and the left chest tube was removed on DOL 20. Cardiac echo on DOL 21 showed no aortic coarctation, a small PDA with left to right shunting, and a persistent left superior vena cava draining into a dilated coronary sinus. Upper GI contrast study showed no obstruction or leak at the esophageal anastomosis on DOL 24 (Fig. 4). The patient was extubated the same day. The right chest tube and NG tube were removed on DOL 25. Patient's respiratory status continued to improve and he was weaned to high-flow nasal cannula (HFNC) oxygen on DOL 28.

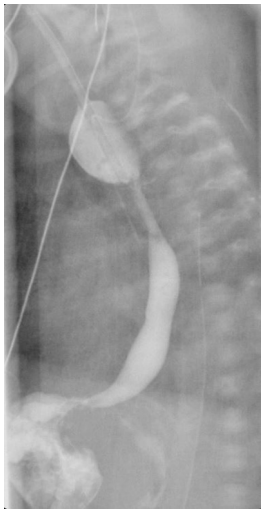

Fig. 4. Upper GI contrast study showing patent esophageal anastomosis without obstruction or leak.

Patient was started on oral feeding trials with speech pathology assistance on DOL 31 as he continued to show encouraging signs of improvement. Routine Virginia state newborn screening revealed no abnormalities, but cytogenetics and karyotyping showed mosaic duplication on the long arm of chromosome 10.

At the writing of this manuscript, the patient was maintaining appropriate oxygenation on room air, tolerating goal enteral tube feeds, and continuing to increase his daily oral intake. He was 6 weeks old and weighed 2.7 kg. He was discharged home to the care of his mother on DOL 48.

2. Discussion

The coexistence of CDH, EA, and TEF in a newborn presents a unique challenge to clinicians. As this is a rare constellation of congenital anomalies, there is no standard protocol for management. The resulting pathophysiology requires a well-coordinated effort that includes pediatric surgeons, neonatologists, anesthesiologists, intensive care nurses, and respiratory therapists. There are two database reports that each mention approximately 20 cases from different registries of the combination of CDH with EA/TEF, but do not investigate their surgical management [1,3]. As well, there are only 12 cases that have been reported in the literature as more detailed accounts [2,4–11]. Of those 12, there are only 2 case reports to date that describe successful management of an infant with left CDH, EA, and TEF [2,12].

The underlying cause of concurrent CDH and EA/TEF is unknown. Differentiation of the various structures of the respiratory tract and thoracic cavity begins during the 4th week of fetal development from foregut endoderm and associated mesoderm. Chromosomal abnormalities have been reported in patients with both CDH and EA/TEF. However, no genetic cause has been identified that links all three findings together [1]. Genetic work-up of our patient revealed mosaic duplication on the long arm of chromosome 10, but this finding has unknown significance at this time.

CDH is commonly diagnosed antenatally, but still carries mortality close to 40%, based on a study by The Congenital Diaphragmatic Hernia Study Group in 2001 that analyzed 1054 patients from 71 different institutions [13]. Since EA/TEF is usually diagnosed postnatally, surgical decisions for the progression of management must be made in a timely fashion. Complicated pathophysiology in these patients with all three findings includes pulmonary hypertension, lung hypoplasia, gastric acid reflux into the trachea and lungs, and gastrointestinal distension causing an inability to properly ventilate. Respiratory distress and failure is inevitable. Prematurity increases the short- and long-term risks of the required interventions to make survival possible.

The order of management, CDH repair first vs EA/TEF repair first, is the primary surgical decision, and was approached differently in the 3 successful cases thus far. The 1996 case report in the Journal of Pediatric Surgery describes successful management of a 1.9 kg premature infant born at 34 weeks gestation with four separate operations. The first operation, through a left subcostal incision, allowed primary repair of the CDH, placement of a gastrostomy tube, and temporary occlusion of the gastroesophageal junction with silicone rubber tubing. The second operation, with the patient on veno-venous ECMO, allowed ligation of the TEF via a right thoracotomy. The third operation allowed for primary closure of the abdominal cavity. The final operation allowed for transpleural repair of the esophageal atresia. The patient was discharged at 4 months of age and was developing well at $6^1/_2$ years of age [2].

Our approach was similar in that we first corrected the CDH with temporary occlusion of the TEF and gastrostomy tube placement. The infant was unstable during this first operation, and as a precaution we were prepared to place the intestines into a spring-loaded silo if unable to reduce and close the abdominal cavity. The routine management of CDH at our institution would have involved first stabilizing the infant and optimizing medical management of pulmonary hypertension that accompanies CDH. However, this was not an option in this patient due to increasing distention of the intestines in the thorax.

To prepare for the second operation, the infant was allowed to recover as fully as possible from the CDH repair, until DOL 12. During this time, the gastrostomy tube was kept to water seal and monitored for any leak. The infant was kept on antibiotics due to the Rommel tourniquet around the GE junction. The infant was kept on HFOV to avoid overpowering the tourniquet controlling the fistula. The infant made continuous improvement and was eventually able to tolerate several hours of ventilation on his left side, indicating he would be able to tolerate one-lung ventilation during the thoracotomy to address the TEF. Additionally, the infant was able to be weaned off of HFOV the day before the operation, indicating that should de-recruitment occur in the OR during thoracotomy, hand-bagging or other ventilator modes could be employed to assist in the management. There was a discussion about performing the TEF repair on conventional ventilation, but it was decided to proceed with repair using oscillatory ventilation.

We were able to complete definitive ligation of the TEF with primary esophageal anastomosis at the second operation. However, due to the necessity of performing the TEF ligation while dependent only on left lung ventilation, there was a pre-operative discussion and agreement between the anesthesia and surgery teams to approach the operation in two stages if necessary. The first priority was division of the TEF only. Primary repair was to be attempted only if the infant demonstrated the ability to re-recruit alveoli during any intra-operative desaturations, and if the infant was able to tolerate one lung ventilation on the left, hypoplastic lung only. As an additional safeguard, the operation was performed with ECMO on standby in the operating room, in case the infant experienced irreversible pulmonary compromise. The infant continued to improve after TEF ligation and EA repair, and fortunately has had no postoperative complications.

An alternative order of management was described in a 2013 case report in BMJ Case Reports, which details successful management by addressing the EA/TEF first, followed by delayed repair of the CDH. Via a right thoracotomy, the TEF was ligated and anastomosis of the esophagus was performed. A chest tube was placed at completion of that operation. One week later, via a left subcostal incision, the CDH was repaired with use of a Gore® Dualmesh. The patient was discharged home at 4 months of age and was developing well at 10 months of age [12].

Allowing for progressive gaseous distension of small bowel that has herniated into the thoracic cavity will quickly force a newborn into respiratory failure. The three successful case reports described all accomplished the same outcome on DOL 1: stop further bowel distension and ensure effective mechanical ventilation. If the hernia is large, and the fistula is widely patent, distention of the small bowel with subsequent mediastinal shift and inability to ventilate is likely. This was true in our patient, which is why it was deemed by our team that ligating the TEF first and not addressing the CDH would have been fatal.

3. Conclusion

This is the first case report of the successful management of a premature infant with left CDH and EA/TEF described in the US. All three case reports compared herein are unique in their management of a complicated constellation of findings, but with similarities that have allowed for positive outcomes. The coexistence of CDH, EA, and TEF in a newborn is unusual and rare. However, with a

well-prepared, multi-disciplinary approach, achieving survival is possible.

Conflict of interest statement

All authors declare that there are no conflicts of interest to disclose.

References

[1] Van Dooren M, Tibboel D, Torfs C. The co-occurrence of congenital diaphragmatic hernia, esophageal atresia/tracheoesophageal fistula, and lung hypoplasia. Birth Defects Res A Clin Mol Teratol 2005;73:53–7.
[2] Sapin E, Berg A, Raynaud P, Lapeyre G, Seringe R, Helardot PG. Coexisting left congenital diaphragmatic hernia and esophageal atresia with tracheoesophageal fistula: successful management in a premature neonate. J Pediatr Surg 1996;31:989–91.
[3] Ben-Ishay O, Johnson VM, Wilson JM, Buchmiller TL. Congenital diaphragmatic hernia associated with esophageal atresia: incidence, outcomes, and determinants of mortality. J Am Coll Surg 2013;216:90–5. e2.
[4] Cunát V, Stranák Z, Pýcha K, Tláskal T, Melichar J, Miletín J, et al. Congenital diaphragmatic hernia associated with esophageal atresia, tracheoesophageal fistula, and truncus arteriosus in a premature newborn. Pediatr Surg Int 2005;21:684–6.
[5] Takehara H, Komi N, Okada A, Nishi M, Masamune K. Left diaphragmatic hernia associated with lower esophageal atresia. Pediatr Surg Int 1993;8:339–40.
[6] Ahmed S. Right-sided Bochdalek hernia associated with esophageal atresia and trachea-esophageal fistula. J Pediatr Surg 1970;5:256.
[7] Rawlings JS, Shetler PL, Fill WL, Cathcart CF. Concurrent right diaphragmatic hernia and type C tracheoesophageal fistula. A case report. Clin Pediatr 1984;23:518–20.
[8] Udassin R, Zamir O, Peleg O, Lernau O. Coexisting left diaphragmatic hernia and esophageal atresia. Pediatr Surg Int 1987;2:301–3.
[9] Bowen A. The ventilatory dilemma of coexisting diaphragmatic hernia, esophageal atresia and tracheoesophageal fistula. Crit Care Med 1983;11:390–1.
[10] Gibon Y, Borde J, Mitrofanoff P, Lefort J. Association of left diaphragmatic hernia, lung agenesia and esophageal atresia (author's transl). Chir Pediatr 1978;19:261–7.
[11] Al-Salem AH, Alkhuwaher H. Coexisting congenital diaphragmatic hernia, esophageal atresia, and tracheoesophageal fistula: a case report and review of the literature. Int Surg 2008;93:141–4.
[12] Abdul Haium AA, Sim SW, Ong LY, Rajadurai VS. Congenital diaphragmatic hernia associated with oesophageal atresia and trachea-oesophageal fistula in a low birth weight infant. BMJ Case Rep 2013. http://dx.doi.org/10.1136/bcr-2013-200014.
[13] Congenital Diaphragmatic Hernia Study Group. Estimating disease severity of congenital diaphragmatic hernia in the first 5 minutes of life. J Pediatr Surg 2001;36:141–5.