

Available online at www.sciencedirect.com**ScienceDirect**

Journal of the Chinese Medical Association 76 (2013) 653–656

www.jcma-online.com

Case Report

Lymphangiomatous macroglossia associated with extensive cervicomedial cystic hygromas

Li-Hsiang Cheng^a, Jih-Chin Lee^a, Chuan-Hsiang Kao^a, Zheng-Ping Shi^a, Yaoh-Shiang Lin^{b,c,*}^a Department of Otorhinolaryngology-Head and Neck Surgery, Tri-Service General Hospital, National Defense Medical Center, Taipei, Taiwan, ROC^b Department of Otorhinolaryngology-Head and Neck Surgery, Kaohsiung Veterans General Hospital, Kaohsiung, Taiwan, ROC^c Department of Nutritional Science, Toko University, Chia-Yi, Taiwan, ROC

Received October 1, 2011; accepted May 21, 2013

Abstract

Children with lymphangiomatous macroglossia often have difficulty eating and talking, and their airways may be compromised because of bleeding and infection, especially when extensive cervicomedial cystic hygromas are present. We report a case of lymphangiomatous macroglossia associated with extensive cystic hygromas in the cervicomedial region. The 3-year-old girl was treated with anterior wedge reduction of the tongue, needle aspiration of the cervicomedial cystic hygromas, and systemic steroids and antibiotics. The extensive cystic cervicomedial hygromas spontaneously regressed, and further surgery was not needed until 4 years later. Surprisingly, subtotal or partial lymphatic malformation removal improved the complicated lymphatic malformation.

Copyright © 2013 Elsevier Taiwan LLC and the Chinese Medical Association. All rights reserved.

Keywords: cystic hygromas; lymphatic malformation; macroglossia

1. Introduction

Lymphatic malformations (lymphangioma and cystic hygroma) are uncommon congenital anomalies, and the precise embryonic origin of lymphatic malformations remains unknown.^{1–5} Lymphatic malformations are generally considered to be vascular malformations that result from sequestration of lymphatic tissue that fail to communicate normally with the lymphatic system. Notably, 80–90% of lymphatic malformation cases are diagnosed by age 2 years. Lymphatic malformations occur throughout the body, but are most common in the head and neck. The symptoms are related to the anatomical location of the lesions as well as the extent of involvement of the local anatomical structure. Although standard lymphatic malformation treatment is ablative, complete lymphatic malformation ablation is usually impossible in

the head and neck. The principal goal of lymphatic malformation management is the restoration or preservation of functional and aesthetic integrity.^{1–6} We present a case of massive enlargement of the tongue combined with a giant anterior lower neck cystic mass that extended directly into the superior mediastinum. Instead of a complete lymphatic malformation ablation, we performed anterior wedge reduction of the tongue with needle aspiration of the cervicomedial cystic hygromas. The outcome was successful, and to date the patient has been free of symptoms for more than 4 years.

2. Case report

A 3-year-old girl was referred to our institution for evaluation. She had a 6-month history of a persistent anterior lower neck mass and protrusion of her tongue from the mouth at rest. Antibiotics and steroids had been prescribed for 3 months prior to referral, with no improvement. There was no contributory prenatal or postnatal medical history. During the patient's hospitalization, she had to adopt a prone position to sleep because the tongue obstructed her airways in the supine

* Corresponding author. Dr. Yaoh-Shiang Lin, Department of Otorhinolaryngology-Head and Neck Surgery, Kaohsiung Veterans General Hospital, 386, Ta-Chung 1st Road, Kaohsiung 813, Taiwan, ROC.

E-mail address: yshuolin@ndmctsgh.edu.tw (Y.-S. Lin).

position. She had noisy breathing, slurred speech, and difficulty swallowing. The physical examination revealed a giant tongue that protruded 4 cm outside the oral cavity and had a dried, cracked, and necrotic surface on the lingual tip. We also observed prognathia that increased the angle between the body and the ramus of the jaw (Fig. 1) and a soft, nontender 3 cm × 4 cm mass in the anterior lower neck. A magnetic resonance imaging scan showed giant lobulated cystic masses (4.7 cm × 4.7 cm × 8.2 cm) in the anterior lower neck that extended to the superior mediastinum, causing partial displacement of the trachea to the right (Fig. 2). Accordingly, stage V of lymphatic malformation with lymphangiomatous macroglossia associated with extensive cervicomedial cystic hygromas was diagnosed. To reduce postoperative edema and secure the airway, the patient underwent a V-shaped wedge resection in which the whole thickness of the tip of the tongue is removed back to the free tumor invasion (Fig. 3) under general anesthesia with nasotracheal intubation so that the tongue was sufficiently reduced in size to fit back in the mouth. For the security of the child, needle aspiration of about 7 mL of the cervical cystic hygromas under echo guidance was performed to decompress the lesion. Intravenous antibiotics and a steroid were also prescribed concurrently. She stayed in the intensive care unit for postoperative observation. Staged surgical excision of the extensive cervicomedial cystic hygromas was planned for 3 months after the tongue reduction. Microscopic examination of the resected tongue revealed diffuse, variably sized thin-walled lymphovascular channels that dissected the skeletal muscular boundaries and led focally to the subepithelial area (Fig. 4). This appearance was consistent with a diagnosis of microcystic lymphangioma. After surgery, the patient could sleep in the supine position, her tongue fit completely inside her oral cavity, she showed significant improvement in swallowing and articulation, and her facial contours were improved. Follow-up was uneventful for 4 years. Surprisingly, the extensive cervicomedial cystic hygromas resolved spontaneously and dramatically without further management (Fig. 5).

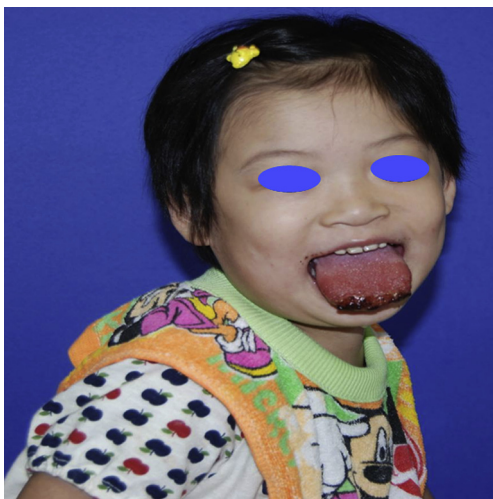

Fig. 1. Physical examination revealed a giant tongue with dried, cracked, and necrotic surface on the lingual tip protruding 4 cm outside the oral cavity, prognathia, increasing the angle between the body and ramus of the jaw.

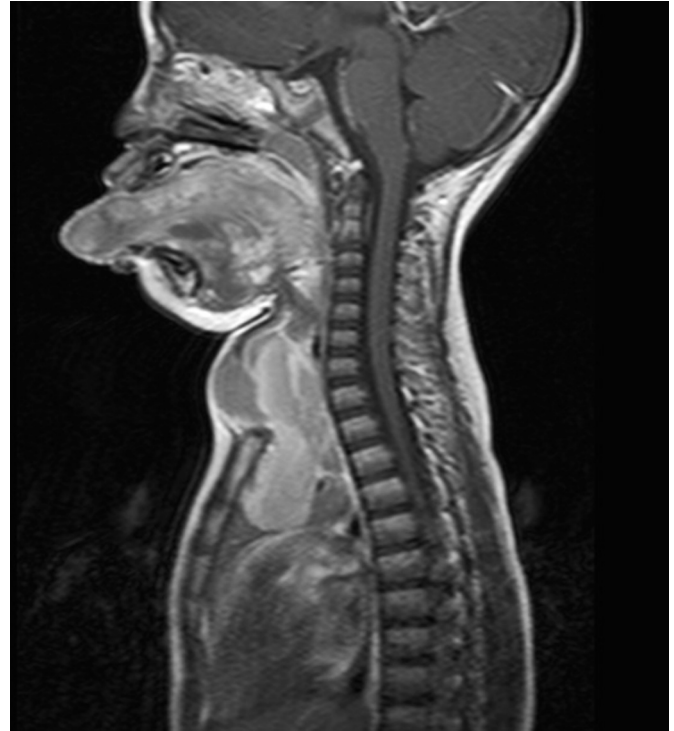


Fig. 2. Magnetic resonance imaging showed macroglossia and giant lobulated cystic masses (4.7 cm × 4.7 cm × 8.2 cm) in the anterior lower neck that extended to the superior mediastinum, causing partial displacement of the trachea.

3. Discussion

Head and neck lymphatic malformation assessment and treatment have changed and improved over the past 15 years

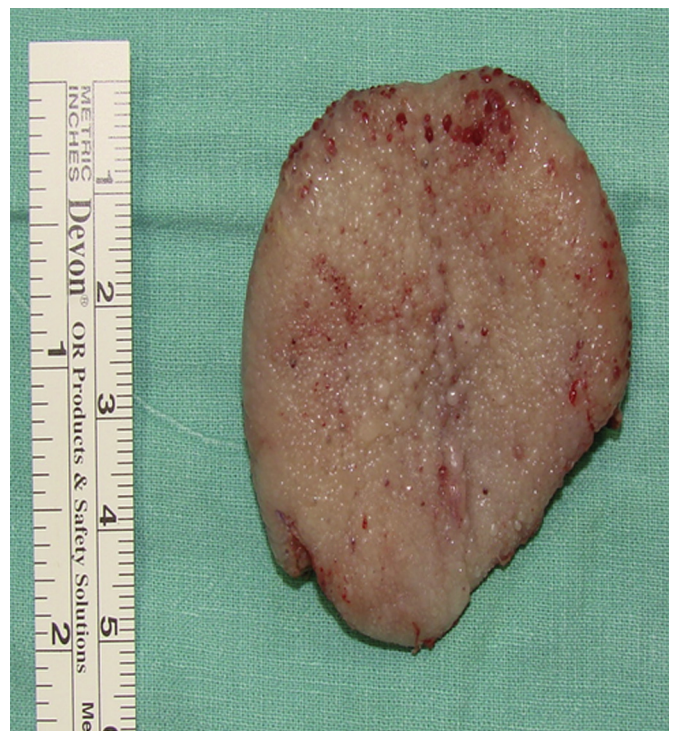


Fig. 3. Anterior wedge reduction of the tongue.

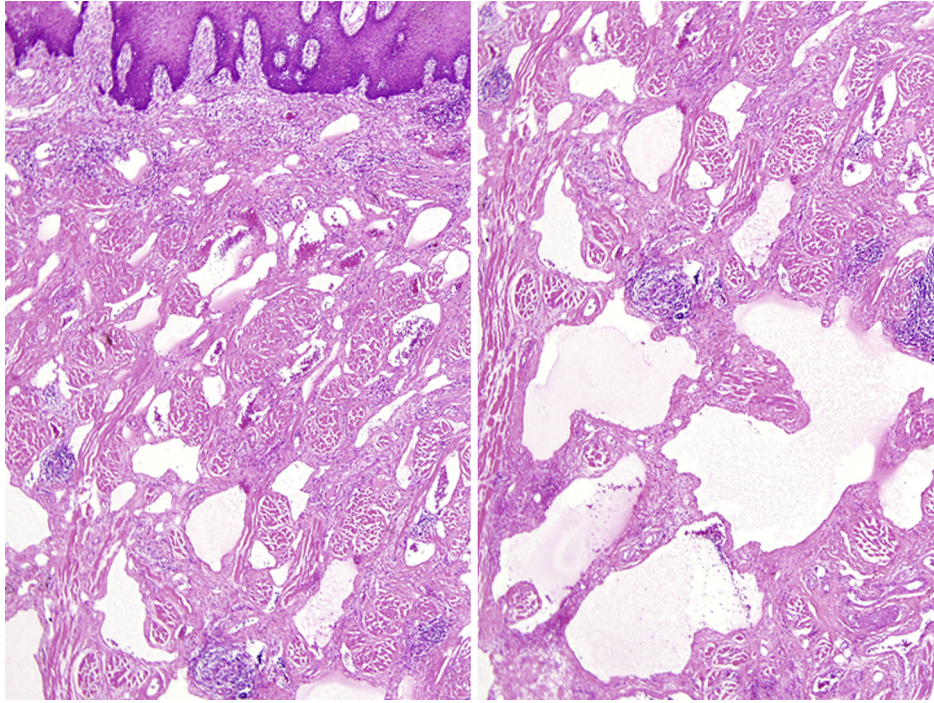


Fig. 4. Microscopic examination of the resected tongue revealed diffuse, variably sized thin-walled lymphovascular channels that dissected the skeletal muscular boundaries and led focally to the subepithelial area (hematoxylin–eosin stain, original magnification $\times 40$, left and $\times 80$, right)

based on systematic and standardized evaluation. Key factors for the improvement include: simplified lymphatic malformation nomenclature, a lymphatic malformation staging system, refined imaging that allows structural macrocystic and microcystic differentiation, and treatment innovations in both surgery and sclerotherapy. The mainstay of lymphatic malformation treatment has been surgical resection, which has been refined through lesion and radiographic characterization.^{1,2} For smaller lymphatic malformations (stages I and II), most surgeons recommend complete surgical excision. For larger lymphatic malformations (stages IV and V), an increasing number of physicians stage the procedure, use combination therapy, and, when possible, delay surgery until the child is older than 3 years because 80–90% of lymphatic malformations are diagnosed by age 2 years.⁶ An alternative to surgery, intralesional sclerotherapy in macrocystic lymphatic malformation, is effective and reduces the need for other forms of therapy for some cases.^{1–4}

Lymphangioma is the most common cause of pediatric macroglossia, and it usually has a very slow, chronic course until puberty, when it reaches a static stage. The typical clinical manifestations of macroglossia include: difficulty in chewing and swallowing, drooling, mandibular prognathism, slurred speech, dry or cracked tongue, and noisy breathing. Children with this serious condition often experience rapid enlargement of their tongue and upper respiratory tract infections, or ulceration of tongue with secondary infection and hemorrhage.^{3,4,6–8} Most lymphatic malformation patients are admitted for airway obstruction and are treated with steroids and antibiotics. The principles for treatment of lymphangiomatous macroglossia are: preservation of taste,

restoration of tongue size for articulation, correction of mandibular and dental deformities, and treatment of life-threatening respiratory problems.⁷ Surgical excision, radiofrequency ablation, superficial laser ablation, and sclerotherapy are commonly used to manage lymphangiomatous macroglossia. Sclerotherapy with OK-432 has not been effective in treating microcystic lesions. Radiofrequency^{8,9} or laser ablation^{10,11} (using carbon dioxide, yttrium–aluminum garnet, or potassium–titanylphosphate lasers) is minimally invasive and is much less painful than surgery. However, these are used mainly to treat vesicles of the mucous membranes and on the dorsal tongue without protrusion of the tongue.^{3,6,8} A protruding tongue can be treated by surgical reduction. The preferred methods of surgical tongue reduction are anterior wedge and midline keyhole reduction.^{3,7,10}

Cystic hygromas develop mainly in the cervicofacial region (75%) and axilla (20%). Approximately 10% of cervical cystic hygromas extend to the mediastinum.^{12–15} A patient with mediastinal cystic hygromas may be asymptomatic and thus be diagnosed only after an abnormal finding on the chest radiogram or computed tomogram. When symptoms are present, they are often nonspecific symptoms such as cough, hemoptysis, chest pain, dysphagia, and dyspnea. These symptoms may stem from compression or deviation of the airway and/or from the vascular structures of the cystic hygromas. Spontaneous regression of cystic hygroma is rare. Complete resection of mediastinal and cervicomediastinal cystic hygromas appears to give the best chance of cure when tongue enlargement or other symptoms are present. Thoracotomy with resection is the most common surgical intervention, and surgical complications include: chylothorax, hemothorax, phlebotaxis of the superior vena cava, and

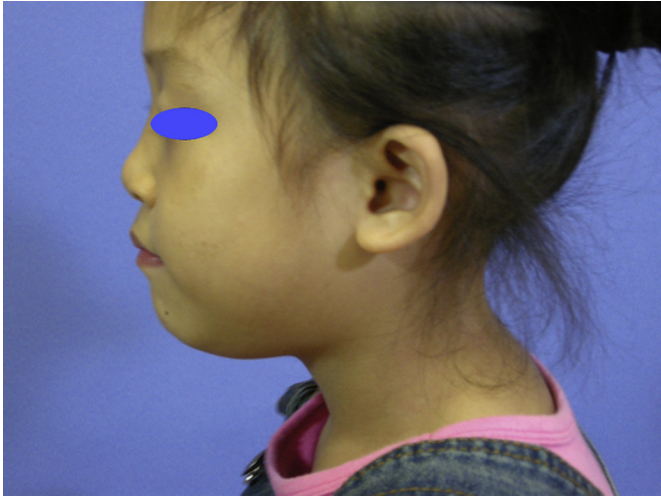

Fig. 5. The tongue was completely inside the oral cavity and the extensive cervicomedial cystic hygromas resolved spontaneously and dramatically without further management.

laryngeal nerve sacrifice. Severe postoperative edema is common. However, the higher the clinicoradiologic stage, the greater the potential risk of intraoperative and postoperative complications.^{1,2} Aspiration seems to be a reliable and safe management option with a low complication rate. It could be secondary to the opening of new lymphatic channels, which would eventually decompress the lesion. However, the lesions are usually multicystic, making cure difficult with aspiration.^{11–15}

Our patient's symptoms, that is, a persistent anterior lower neck mass and protrusion of the tongue from the mouth at rest, were present for 6 months. Antibiotics and steroids were prescribed for 3 months without significant improvement. Staged surgical excision was scheduled because of the large lymphatic malformations (stage V) and to reduce postoperative edema with aggravation of dyspnea. Surgical excision of the extensive cervicomedial cystic hygromas was scheduled for approximately 3 months after the tongue reduction. Surprisingly, the extensive cystic cervicomedial hygromas regressed spontaneously and has not required further staged surgical excision for 4 years. This could be attributable to the decreased inflammation after the tongue reduction. Because the possibilities of hemorrhage, infection, or trauma decreased after the reduction of the tongue, the load of inflammation could decrease. Although residual lymphatic malformation was left, incomplete excision does not necessarily lead to recurrence that requires additional therapeutic intervention.^{2,15}

Although staged surgical excision for complete lymphatic malformation excision is often necessary, subtotal or partial

lymphatic malformation removal may also “improve” a complicated lymphatic malformation, as in the case presented here. This prevents the patient from suffering the side effects of complete ablation, resulting in improved quality of life. We conclude that in the case of a tongue lymphangioma combined with a cervical hygroma, the treatment of the first entity will affect the management of the second, through its positive effect on inflammation. A conservative treatment of the cervical hygroma should be considered first rather than surgery in such situations.

References

- Perkins JA, Manning SC, Tempero RM, Cunningham MJ, Edmonds Jr JL, Hoffer FA, et al. Lymphatic malformation: current cellular and clinical investigations. *Otolaryngol Head Neck Surg* 2010;**142**:789–94.
- Perkins JA, Manning SC, Tempero RM, Cunningham MJ, Edmonds Jr JL, Hoffer FA. Lymphatic malformations: review of current treatment. *Otolaryngol Head Neck Surg* 2010;**142**:795–803.
- Rowley H, Perez-Atayde AR, Burrows PE, Rahbar R. Management of a giant lymphatic malformation of the tongue. *Arch Otolaryngol Head Neck Surg* 2002;**128**:190–4.
- Hartl DM, Roger G, Denoyelle F, Nicollas R, Triglia JM, Garabedian EN. Extensive lymphangioma presenting with upper airway obstruction. *Arch Otolaryngol Head Neck Surg* 2000;**126**:1378–82.
- Mulliken JB, Glowacki J. Hemangioma and vascular malformation in infants and children: a classification based on endothelial characteristics. *Plast Reconstr Surg* 1982;**69**:412–22.
- Bloom DC, Perkins JA, Manning SC. Management of lymphatic malformations. *Curr Opin Otolaryngol Head Neck Surg* 2004;**12**:500–4.
- Dinerman WS, Myers EN. Lymphangiomatous macroglossia. *Laryngoscope* 1976;**86**:2591–6.
- Achauer BM, Chang CJ, Vander Kam VM, Boyko A. Intralesional photocoagulation of periorbital hemangiomas. *Plast Reconstr Surg* 1999;**103**:11–6.
- Chang CJ, Fisher DM, Chen YR. Intralesional photocoagulation of vascular anomalies of the tongue. *Br J Plast Surg* 1999;**52**:178–81.
- Edwards PD, Rahbar R, Ferraro NF, Burrows PE, Mulliken JB. Lymphatic malformation of the lingual base and oral floor. *Plast Reconstr Surg* 2005;**115**:1906–15.
- Cable BB, Mair EA. Radiofrequency ablation of lymphangiomatous macroglossia. *Laryngoscope* 2001;**111**:1859–61.
- Shetty SC, Hasan S, Chary G, Balasubramanya AM, Das UC, Harshad D. Lymphangiomatous macroglossia causing upper airway obstruction and associated Plummer–Vinson syndrome. *Otolaryngol Head Neck Surg* 2001;**124**:477–8.
- Bloom DC, Perkins JA, Manning SC. Management of lymphatic malformations and macroglossia: results of a national treatment survey. *Int J Pediatr Otorhinolaryngol* 2009;**73**:1114–8.
- Park JG, Aubry MC, Godfrey JA, Midthun DE. Mediastinal lymphangioma: Mayo clinic experience of 25 cases. *Mayo Clin Proc* 2006;**81**:1197–203.
- Raveh E, de Jong AL, Taylor GP, Forte V. Prognostic factors in the treatment of lymphatic malformations. *Arch Otolaryngol Head Neck Surg* 1997;**123**:1061–5.