The Egyptian Journal of Radiology and Nuclear Medicine (2012) **43**, 631–636

Egyptian Society of Radiology and Nuclear Medicine

The Egyptian Journal of Radiology and Nuclear Medicine

www.elsevier.com/locate/ejrnm
www.sciencedirect.com

ORIGINAL ARTICLE

The role of MRI in the diagnosis of endometriosis

Noha Mohamed AbdelMaboud Ibrahim *, Haytham Haroon Elsaeed [1]

Department of Radiology, College of Medicine, Tanta University, Egypt

Received 14 December 2011; accepted 19 September 2012
Available online 7 November 2012

KEYWORDS

Endometriosis;
Adenomyosis;
MRI;
Ultrasound

Abstract *Aim:* The aim of this study is to evaluate the accuracy of the magnetic resonance imaging in diagnosis of endometriosis especially in non-apparent types as tubal and cul de sac endometriosis.
Patients and methods: MRI obtained between January 2007 and June 2009 for 34 premenopausal women complaining of dysmenorrhea, menorrhagia and infertility and the diagnosis of endometriosis were included in the differential diagnosis. T1 weighted fat saturated and T2 weighted images were done for every patient, we evaluated the MR images for the presence of T1 bright signal suggesting endometriosis. Transvaginal US was performed in two perpendicular planes for the detection of focal areas with ill defined borders or abnormal echo texture. Suspicious cases which become negative by laparoscopy were excluded from the study.
Results: MRI diagnosed endometriosis in the uterus in 18 patients, ovarian endometriosis in 13 patients, tubal in two patients, and cul de sac in one patient.
Conclusion: It is concluded that MRI is superior in the diagnosis of endometriosis than transvaginal ultrasound.

1. Introduction

Endometriosis is defined as the presence of endometrial epithelium and stroma in an ectopic site outside the uterine cavity (1). Endometriosis occurs in 10% of the female population and almost, exclusively, in women of reproductive age (2). The most common symptoms are dysmenorrhea, dyspareunia, pelvic pain, and infertility although endometriosis may be asymptomatic (3). Adenomyosis is the presence of endometrial glands and stroma within the myometrium and it is the cause of uterine enlargement, menorrhagia, and dysmenorrhea (4–6). The most common sites for endometrial implantation within the pelvis are the ovaries, broad and round ligaments, fallopian tubes, and cervix (7). Endometriosis can affect the woman in the reproductive age; however, it cannot be accurately diagnosed by clinical criteria alone. In addition, the transabdominal and transvaginal US are not as accurate as MRI (8,9).

* Corresponding author. Address: Tanta University Hospital, Elgesh Street, Tanta, Gharbeya, Egypt. Tel.: +20 168643995.
E-mail addresses: ahmed_osama99@hotmail.com (N.M. AbdelMaboud Ibrahim), hythamharoon@yahoo.com (H.H. Elsaeed).
[1] Address: Tanta University Hospital, Elgesh Street, Tanta, Gharbeya, Egypt. Tel.: +20 123658711.
Peer review under responsibility of Egyptian Society of Radiology and Nuclear Medicine.

ELSEVIER Production and hosting by Elsevier

0378-603X http://dx.doi.org/10.1016/j.ejrnm.2012.09.005

Table 1 The number and types of endometriosis.

	Adenomyosis	Ovarian endometriosis	Tubal endometriosis	Cul de sac endometriosis
Number	18	13	2	1
%	52.9	38.2	5.8	2.9

Table 2 Types of adenomyosis.

	Focal adenomyosis	Diffuse adenomyosis	Total
Number of patients	13	5	18
%	72.2	27.7	100

Table 3 Adenomyosis diagnosed by transvaginal US.

Total number of adenomyosis	Adenomyosis diagnosed by transvaginal us	%
18	13	72.2

Table 4 Diagnostic criteria of adenomyosis at transvaginal US.

US criteria	Number of patients	%
Myometrial cyst	6	46.1
Focal heterogeneous myometrial area	3	23.07
Asymmetric myometrium + enlarged uterus	4	30.7
Total	13	100

Table 5 The number of cases of adenomyosis diagnosed by MRI.

Total number of adenomyosis	Adenomyosis diagnosed by MRI	%
18	18	100

Table 6 MRI criteria of adenomyosis.

Criteria	Number of patients	%
Low SI in the myometrium	6	33.3
JZ > 12 mm	5	27.7
High T2 SI myometrial spots	2	11.1
The above three features	4	22.2
JZ > 15 mm (diffuse adenomyosis)	4	22.2

Table 7 Accuracy of transvaginal US and MRI in diagnosis of adenomyosis.

	US	MRI	Total
Number of patients	13	18	18
%	72.2	100	100

Table 8 Accuracy of transvaginal US and MRI in the diagnosis of endometriosis.

	Ovarian		Tubal		Cul de sac	
	TVUS	MRI	TVS	MRI	TVS	MRI
Number of patients	7	12	0	1	0	1
%	53.8	92.3	0	50	0	100
Total	13		2		1	

2. Patients and methods

This study was conducted according to the guidelines of the ethics committee of Tanta University and was approved by our institutional review board; all patients gave us written informed consent to be included in our study.

Prospective studies of 34 females in the reproductive age have been examined. Ten patients are with symptoms of dysmenorrhea, nine patients with menorrhagia, 14 patients with pelvic pain, and five patients with infertility; all of them had suffered from the clinical suspicion of endometriosis. We studied them by transabdominal, transvaginal ultrasound, and MRI with and without contrast.

2.1. Ultrasound examination

Sonographic examinations took place on two perpendicular planes using PHILIPS HD11 instrument. Pelvic transabdominal US was performed by using a 3.5-MHz transducer and transvaginal US examination with 8-MHz transducer. During each Sonographic examination, the uterine borders, whether regular or irregular, uterine size, myometrial echotexture and the presence of focal areas with ill-defined borders or abnormal echotexture were described. When these areas were present, the following criteria of adenomyosis were evaluated: presence of heterogeneity, increased or decreased areas of echogenicity, or presence of myometrial cysts. Another type of ultrasound that we used in our study is trans-rectal ultrasound which is necessary in the evaluation of deep infiltrating endometriosis involving recto-vaginal and utero-sacral ligaments but unfortunately we have no cases that have the deep infiltration of these regions.

2.2. MRI protocols

MRI performed on a 1.5 T MR unit (General Electric Medical Systems) using T2 weighted images required 4 mm slices in the sagittal, coronal, and axial planes related to the orientation of the uterine cavity that used fast spin echo sequences in all the three planes. T1 weighted spin echo and gradient echo images were obtained both with and without fat saturation for all patients. High-resolution body coils were used for data

acquisition, and exams were completed in 30–45 min. T1 weighted fat saturated and T2 weighted images in these patients were reviewed for four major criteria:

1. Borders, size and uterine symmetry.
2. Maximal junctional zone (JZ max) thickness and/or the presence of an ill-defined, relatively homogenous, low signal intensity, myometrial area.
3. Maximal (JZ max) to myometrial thickness ratio using the maximal thickness of JZ and the corresponding thickness of the entire myometrium obtained at the same level.
4. High intensity spots within the myometrium, the presence of T1 bright/T2 dark signals, suggesting the existence of endometriosis in any of the anatomical locations.

Diffuse adenomyosis was thought to be present at JZ max > 15 mm. For a JZ thickness of 12–15 mm, adenomyosis was considered present in case one of the previous criteria was present. An endometrial implant has a varied appearance depending on the age of the associated blood products. The diagnosis of implants was made when hyperintense lesions were found in T2 weighted imaging. The diagnosis was made after ruling out artifacts of motion, incomplete fat saturation, and bowel contents; the lesion must be less than 10 mm. Lesions that were larger than 10 mm were considered being endometriomas; lesions that were less than 10 mm. were classified as implants. The sites were evaluated included uterine serosa, both ovaries and fallopian tubes, and cul de sac.

Both ovaries were evaluated for cystic lesions, and internal echogenicity and wall thickness were fully considered. Ovarian endometriomas were diagnosed when cystic lesion with internal echoes is found (hemorrhage). Internal septation or multilocular cysts may be present also as a fluid. Fluid level can be present due to separation of blood products into layers.

Diagnosis of ovarian endometriomas by MRI is made when there is cystic mass of high signal intensity in T1 fat saturated image and low signal intensity in T2 "shading". The loss of signal intensity in T2 weighted image, is due to cyclic bleeding within the endometriomas and is called shading sign and occasionally occurs in a graded form with higher to lower signal intensity patterns as a result of high protein and iron concentration from recurrent hemorrhage in the endometriomas, all

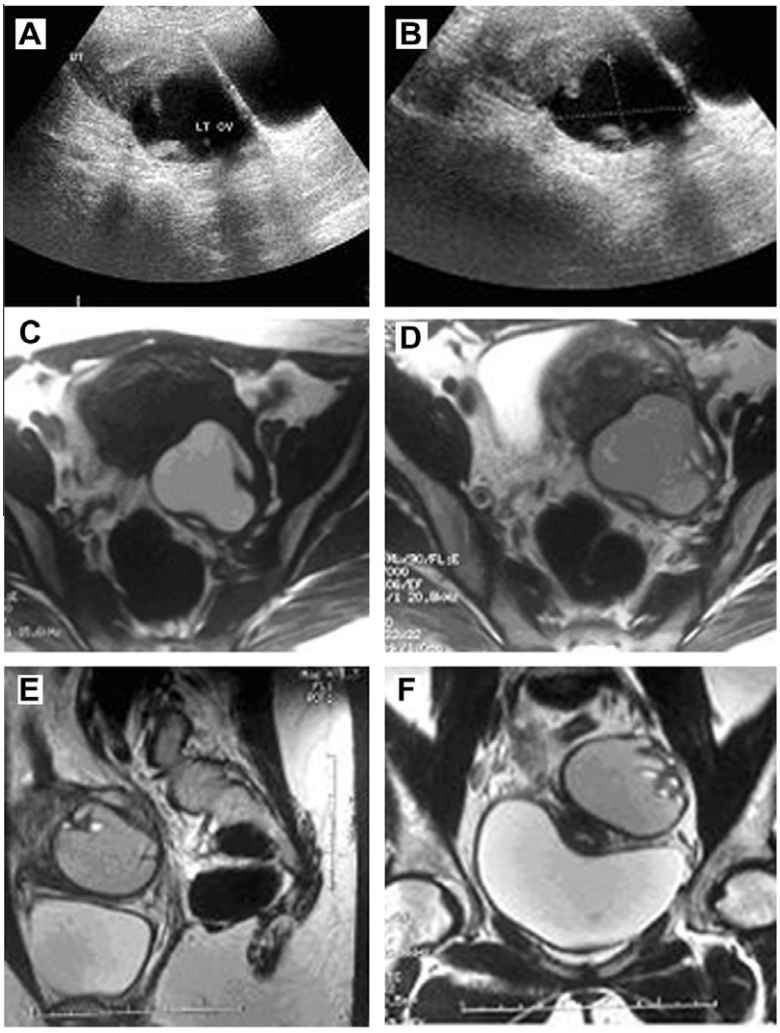

Fig. 1 A, B: Ultrasound of the pelvis showed left ovarian cystic lesion with internal echoes and two hyperechogenic areas inside corresponding to hemorrhagic content of the cyst. C: Axial fat sat MRI showed hyperintense lesion at left ovary. D: The lesion showed drop of SI at T2WI MRI which is pathgnomonic of endometrioma. E, F: Sagittal and coronal T2WI MRI showed low SI of the lesion which is pathologically proved endometrioma by laparoscopic examination and biopsy.

of these components can shorten T2 and may contribute to loss of signal intensity described as shading sign (13).

MRI can diagnose endometriosis of the fallopian tubes when there are dilated tubes with high signal intensity in T1 weighted images. Obliteration of cul-de-sac in MRI by hyperintense T1 weighted image lesion is considered as endometrial implants in cul de sac.

3. Results

We examined 34 patients presented by multiple types of abnormal uterine bleeding. Among those patients, there were 18 patients proved to be with adenomyosis, 13 patients with ovarian endometriosis, two patients with tubal endometriosis and one patient with cul de sac endometriosis proved by laparoscopy (Table 1).

The 18 cases of adenomyosis were subdivided into two subtypes: 13 cases with focal adenomyosis and five cases with diffuse adenomyosis (proved by laparoscopy) (Table 2).

Transvaginal US diagnosed adenomyosis in 13 cases out of 18 cases of adenomyosis (Table 3).

The criteria of adenomyosis in transvaginal US are summarized in Table 4.

MRI diagnosed adenomyosis in 18 cases, as shown in Table 5.

The criteria of adenomyosis in MRI are summarized in Table 6.

Transvaginal US diagnosed 13 of 18 cases of adenomyosis; however MRI diagnosed the 18 cases of adenomyosis (Table 7).

Transvaginal US diagnosed ovarian cysts. We paid attention to internal echogenicity, wall thickness, and the influence on the surrounding organs. Ovarian cysts were diagnosed in seven cases with variable echogenicity according to the age of hemorrhage, thick wall, and chocolate interior of the cyst which is necessary.

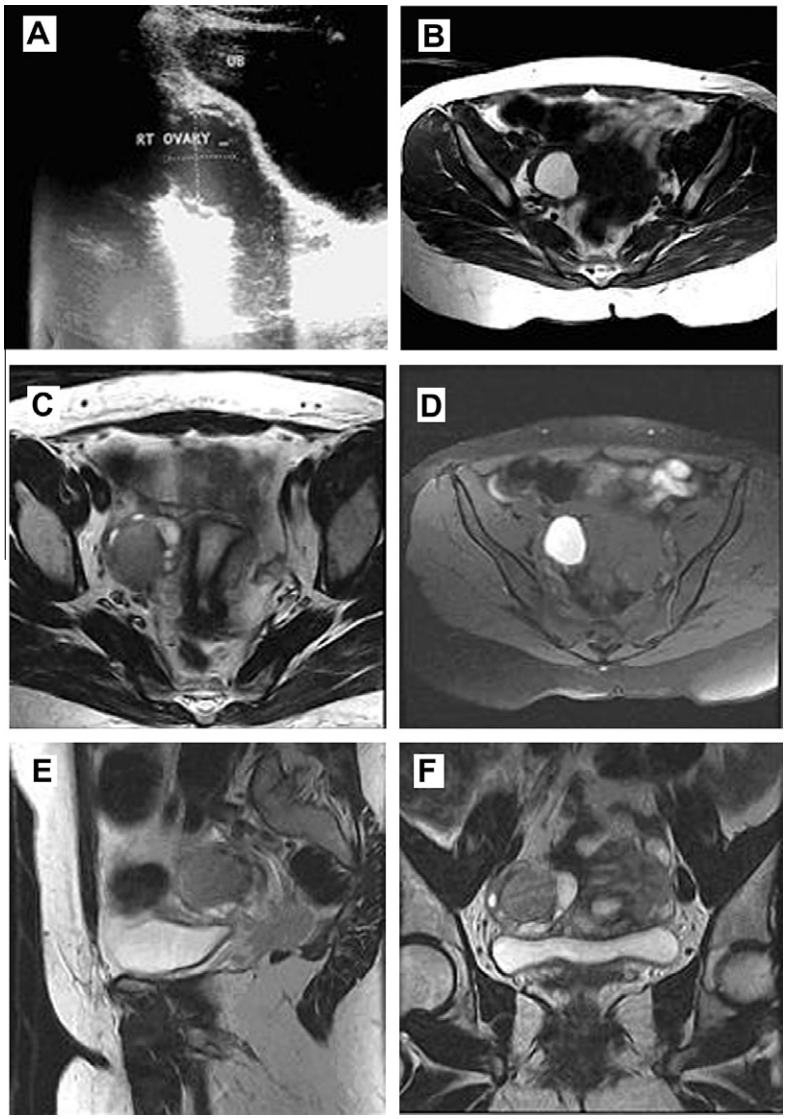

Fig. 2 A: Relatively hyperechoic SOL at right ovary. B: MRI (axial T1WI) shows hyperintense content of the right ovary. C: Axial T2WI shows low SI of the cyst of the right ovary (shading sign). D: Axial T1WI with fatsat showes hyperintense cystic right ovarian lesion (haemorrhage). E, F: MRI (sagittal and cronal T2WI) revealed low SI of right ovarian lesion.

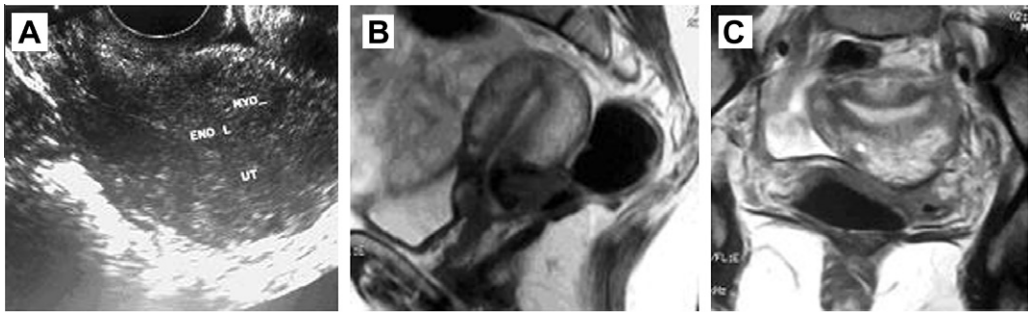

Fig. 3 A: Transvaginal US revealed abnormal increase in thickness of myometrium in a retroverted uterus. B: MRI (sagittal T2WI) shows retroverted uterus with abnormal increase thickness in juctional zone (10 mm) and diffuse abnormal high T2 SI of myometrium abnormal stromal glands. C: MRI (coronal T2WI) shows the same findings as image B. Examination.

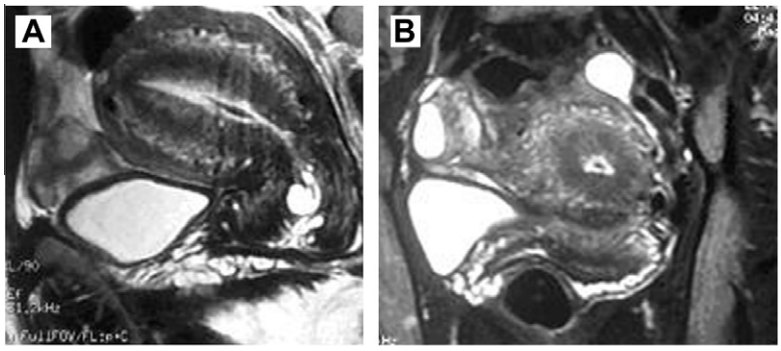

Fig. 4 A: MRI (sagittal T2WI) shows abnormal increase in thickness of junctional zone (12 mm) and abnormal high T2 SI of the myometrium represents abnormal stromal glands inside the myometrium. B: MRI (coronal T2WI) shows the same findings as figure A) as well as bilateral ovarian simple cysts.

MRI diagnosed ovarian endometriomas in 12 cases. We found cystic ovarian mass with high signal intensity contents in T1 weighted images and low signal intensity in T2 weighted images, the "shading sign". This finding is a result of recurrent hemorrhage in the endometriomas that is also proven by laparoscopy to be a chocolate cyst.

In one case, endometriomas of the fallopian tube was detected by MRI to be dilated fallopian tubes with high T1 signal intensity and was proved by laparoscopy to be endometriomas in fallopian tubes. In another case, MRI showed a fluid–fluid level with high T1 signal intensity that was diagnosed after laparoscopy to be endometriomas in the fallopian tubes.

By MRI, there was obliteration of posterior cul de sac by a cystic lesion that displayed high signal intensity in T1 weighted image and low signal intensity in T2 weighted image denoting endometrial implant and was proved by laparoscopy.

Comparison between US and MRI resulted in different types of endometriomas as shown in Table 8.

Case I

- Female patient, aged 35, presented with severe pain on the left side of pelvic region during menstruation.
- Pathologically proved endometrioma by laparoscopic examination and biopsy (Fig. 1).

Case II

- A female patient, aged 27, complains of pelvic pain increasing during menstruation.

Final diagnosis: Right ovarian endometrioma confirmed by laparoscopic examination and biopsy (Fig. 2).

Case III

- A female patient, aged 42, complains of severe lower abdominal pain.

Final diagnosis: Diffuse adenomyosis is confirmed by histopathological by US (Fig. 3).

Case IV

- A female patient, aged 46, complains of severe pelvic pain.

Final diagnosis: Histopathological examination after hysterectomy has revealed diffuse adenomyosis (Fig. 4).

4. Discussion

Endometriosis is defined as the presence of endometrial epithelium and stroma in an ectopic site outside the uterine cavity (1). In our study there are 34 patients of endometriosis that are proved by laparoscopy as endometriosis.

Transvaginal US allows the diagnosis of adenomyosis with high accuracy in 13 patients out of 18 cases in accordance with a previous report, by Hricak (10). Among the sonographic criteria, myometrial cyst was the most sensitive and specific one and was present in six cases; three cases with focal heterogeneous myometrial areas with decreased or increased echogenic-

ity, and four cases with asymmetric enlarged uterus and asymmetric myometrium. This attitude agreed with Fedele et al. (11) because he was the first person to report the diagnostic value of myometrial anechoic lakes for adenomyosis. In our study, regular homogenous uterine enlargement is unreliable as a MRI criterion for adenomyosis, a JZ of at least 12 mm in five cases and low signal intensity in the myometrium in six cases. A high T2 SI myometrial spot is in two cases only.

The above three features were present in three cases and diffuse adenomyosis was diagnosed when JZ > 15 mm in four cases.

Foci of high signal intensity correlated with non-bleeding endometrial tissue. However, in our study and that of Reinhold et al. (12), this MRI feature had low sensitivity. Our results suggest the possibility of using these imaging modalities to evaluate the incidence of adenomyosis in symptomatic and non-symptomatic women. In our study, MRI was superior to transvaginal US for the diagnosis of adenomyosis, especially in JZ measurements.

Glastonburg (13) diagnosed ovarian endometriomas by transvaginal US when there was cystic lesion with internal echoes and thick internal septation. This case was similar to our study when chocolate cyst was diagnosed in seven cases of 13, and in the other six cases there was ovarian cyst with clear contents and no hypo echoic internal echoes could be identified. So, we were not sure that it was ovarian endometriomas except after MRI study. After the study, the shading sign as described by Glastonburg (13) was present in 12 cases. In the other case, the cyst displayed high signal intensity in both T1&T2 weighted images (according to the grade of hemorrhage), the thing that raised the suspicion of endometriomas and was proved after laparoscopy.

In two cases of tubal endometriosis transvaginal US cannot elucidate any (+ve signs) that can suggest tubal endometriosis. In the only case of cul-de-sac endometriomas, there was only obliteration of cul de sac Bazat et al. (14). Atri et al. (15) diagnosed endometriomas of the fallopian tubes by MRI when there was dilated tube that was of high signal intensity in T1 weighted image. MRI diagnosed one case, but the other case could not be diagnosed because the tube showed high signal intensity in T1&T2 weighted images. In addition, in the case of endometriomas of cul de sac, we diagnosed cystic lesion in the cul de sac, hyperintense in T1 but in transvaginal US. There is an obliteration of cul de sac which was the only thing that could be visualized, this point was proved by Bazat et al. (14) in his study.

From the above, MRI diagnosed 13 cases of adenomyosis accurately as compared with laparoscopy, while transvaginal US diagnosed only eight cases. MRI diagnosed all eight cases of ovarian endometriomas, while transvaginal US diagnosed six cases only. MRI diagnosed only one case from the two cases of tubal endometriomas, while transvaginal US had no rule in diagnosis of tubal endometrioma. MRI can diagnose the only one case of cul de sac endometriomas, while transvaginal US did not show any +ve sign that could help in diagnosis of cul de sac endometriomas.

5. Conclusion

In conclusion, MRI is more sensitive than transvaginal US in the diagnosis of endometriosis.

References

(1) Dueholm M, Lundorh E, Hansen ES, et al.. Magnetic resonance imaging and trans-vaginal ultrasonography for the diagnosis of adenomyosis. Br J Radiol 2006;79:303–7.
(2) Bazot M, Cortez A, Darai E, et al.. Ultrasonography compared with magnetic resonance imaging for the diagnosis of adenomyosis; correlation with histopathology. Hum Reprod 2001;16(11):2427–33.
(3) Zacharia TT, Oneill M. Prevalence and distribution of adnexal findings suggesting endometriosis in patients with MR diagnosis of adenomyosis. Br J Radiol 2006;76:303–7.
(4) Kataoka ML, Togashi K, Yamaoka T, et al.. Posterior cull-de-sac obliteration associated with endometriosis: MR imaging evaluation. Radiology 2005;234:815–23.
(5) Dumontier I, Roseau G, Vincent B, et al.. Comparison of endoscopic ultrasound and magnetic resonance imaging in severe pelvic endometriosis. Gastroenterol Clin Biol 2000;24:1197–204.
(6) Stratton P, Winkel C, Premkumar A, et al.. Diagnostic accuracy of laparoscopy, magnetic resonance imaging, and histopathologic examination for the detection of endometriosis. Fertil Steril 2003;79:1078–85.
(7) Vercellini P, Parazzini F, Oldani S, et al.. Adenomyosis at hysterectomy: a study on frequency distribution and patients characteristics. Hum Reprod 1995;10:1160–3.
(8) Verma SK, Lev-Toaff AS, Baltrarowich OH, et al.. Adenomyosis: sonohysterography with MRI correlation. Am J Roentgenol 2009;192(4):112–6.
(9) Rotondi M, Labriola D, Rotondi M, Ammaturo FP, Amato G, Carella C. Depot leuprorelin acetate versus danazol in the treatment of infertile women with symptomatic endometriosis. Eur J Gynaecol Oncol 2002;23:523–6.
(10) Hricak H. Advances in women imaging. Radiographics 1998;18:891–3.
(11) Fedele L, Bianchi S, Dorta M. Transvaginal ultrasonography in the diagnosis of diffuse adenomyosis. Fertil Steril 1992;58:94–7.
(12) Reinhold C, Tahazoli F, Kanag L. Imagining features of adenomyosis. Hum Reprod Update 1998;4:337–49.
(13) Glastonburg CM. The shading sign. Radiology 2002;224:199–201.
(14) Bazat M, Bornier C, Dubernard G, Roseau G, et al.. Accuracy of magnetic resonance imaging and rectal endoscopic sonography for the prediction and location of the deep pelvic endometriosis. Hum Reprod 2007;22(5):1457–63.
(15) Atri M, Reinhold C, Mehio AR. Adenomyosis: US features with histologic correlation in an in vitro study. Radiology 2000;215:783–90.