



Original article

Obstetric paralysis: anterior arthroscopic release of the shoulder and transfer of the latissimus dorsi using a homologous graft[☆]



Alberto Naoki Miyazaki, Caio Santos Checchia*, Sergio Luiz Checchia, Marcelo Fregoneze, Pedro Doneux Santos, Guilherme do Val Sella

Faculdade de Ciências Médicas da Santa Casa de São Paulo, São Paulo, SP, Brazil

ARTICLE INFO

Article history:

Received 19 May 2015

Accepted 18 August 2015

Available online 3 May 2016

Keywords:

Paralysis, obstetric

Brachial plexus neuropathy

Tendon transfer

Transplantation

Homologous

Shoulder

Arthroscopy

ABSTRACT

Objective: Description of a new surgical technique for treating the shoulders of patients with sequelae of obstetric paralysis. Preliminary analysis on the results obtained from this technique.

Methods: Five consecutive patients underwent the proposed surgical procedure, consisting of arthroscopic anterior joint release followed by transfer of the latissimus dorsi tendon (elongated and reinforced with a homologous tendon graft) to the posterosuperior portion of the greater tubercle, using a single deltopectoral approach. All the patients were reevaluated after a minimum postoperative period of twelve months. The functional assessment was based on the range of motion and the modified Mallet classification system. Statistical analyses were not possible because of the small sample.

Results: Overall, passive and active lateral rotations increased, while medial rotation decreased. The other movements (elevation, capacity to place a hand in the mouth and capacity to place a hand behind the neck) had less consistent evolution. The mean modified Mallet score improved by 4.2 points (from 11.4 to 15.6).

Conclusion: The latissimus dorsi tendon can be transferred to the posterosuperior portion of the greater tubercle through a single deltopectoral approach when elongated and reinforced with a homologous tendinous graft.

© 2015 Sociedade Brasileira de Ortopedia e Traumatologia. Published by Elsevier Editora Ltda. All rights reserved.

[☆] Study conducted at the Department of Orthopedy and Traumatology, Faculdade de Ciências Médicas da Santa Casa de São Paulo (DOT-FCMSCSP), São Paulo, SP, Brazil.

* Corresponding author.

E-mail: caio checchia@gmail.com (C.S. Checchia).

<http://dx.doi.org/10.1016/j.rboe.2016.04.004>

2255-4971/© 2015 Sociedade Brasileira de Ortopedia e Traumatologia. Published by Elsevier Editora Ltda. All rights reserved.

Paralisia obstétrica: liberação artroscópica anterior do ombro e transferência do grande dorsal com enxerto homólogo

R E S U M O

Palavras-chave:

Paralisia obstétrica
Neuropatias do plexo braquial
Transferência tendinosa
Transplante
Homólogo
Ombro
Artroscopia

Objetivos: Descrição de uma nova técnica cirúrgica para o tratamento de ombro de pacientes com seqüela de paralisia obstétrica. Análise preliminar dos resultados obtidos com essa técnica.

Métodos: Cinco pacientes consecutivos foram submetidos ao tratamento cirúrgico proposto, que envolve a liberação artroscópica anterior por via artroscópica, seguida da transferência do tendão do músculo grande dorsal (alongado e reforçado com enxerto tendíneo homólogo) para a porção pósterio-superior do tubérculo maior, com o uso de uma única via delto-peitoral. Todos foram reavaliados após um período pós-operatório mínimo de 12 meses. A avaliação da função baseou-se na amplitude de movimento e na classificação modificada de Mallet. A pequena casuística não permitiu análises estatísticas.

Resultados: De forma geral, as rotações laterais passiva e ativa melhoraram, enquanto a rotação medial piorou. Os outros movimentos (elevação, capacidade de colocação da mão na boca e capacidade de colocação da mão na nuca) tiveram evolução menos consistente. A média do escore de Mallet modificado melhorou 4,2 pontos (de 11,4 para 15,6).

Conclusão: O tendão do músculo grande dorsal pode ser transferido para a porção pósterio-superior do tubérculo maior por meio de uma única via delto-peitoral, quando alongado e reforçado com enxerto tendíneo homólogo.

© 2015 Sociedade Brasileira de Ortopedia e Traumatologia. Publicado por Elsevier Editora Ltda. Todos os direitos reservados.

Introduction

Most patients with obstetrical brachial plexus palsy (OBPP) sequelae develop spontaneous, complete or nearly complete improvement of shoulder function.¹⁻⁵ However, in those with incomplete recovery, medial rotation shoulder contracture is one of the most common sequelae,^{4,6-9} due to muscle imbalance secondary to plexus injury (with a predominance of medial rotators over lateral rotators). This sequela occurs early and can be found in advanced stages in patients as young as 2 years.^{1,3-6,8-13} If left untreated, it can lead to a very debilitating joint deformity to the shoulder function.^{6,11}

In 1918, Sever¹⁴ proposed and described the release of the pectoralis major and subscapularis. L'Episcopo, in 1934 and again in 1939,^{15,16} observing the tendency of recurrence of medial rotation contracture after Sever procedure, associated this surgery to the transfer of the insertions of the latissimus dorsi and teres major muscles from the anterior medial portion to the posterolateral humerus. Currently, surgical procedures can be divided into three groups: (1) tendon transfers without anterior shoulder release; (2) anterior release of the shoulder, usually accompanied by tendon transfer; and (3) rescue procedures, such as humeral osteotomy or shoulder arthrodesis, typically for patients with severe joint deformity.^{12,17}

The second group of procedures is currently recommended by most authors for the treatment patients that present with pre-existing medial rotation shoulder contracture, but still have a congruent joint.^{2-9,11,18-20} The anterior shoulder release may be achieved by open^{3,5-7,20-26} or arthroscopic surgical techniques.^{3,4,8-10} The tendon transfer most cited in the

literature is that of the latissimus dorsi (whether or not accompanied by the teres major), so that it will act as a lateral shoulder rotator.^{2-5,7-9,12,18,19,27} The attachment point of the transferred tendon was initially described as the lateral cortex of the humerus, just below the greater tuberosity, using the deltopectoral approach.^{15,16} Later, in order to promote abduction improvement, the transfer was modified to the posterosuperior portion of the greater tuberosity.¹⁸ However, to achieve this, it was necessary to use a posterior approach or multiple access routes. No studies using only an anterior approach to this new topography were retrieved in the literature.

This study aimed to describe and discuss the surgical technique developed and used by our group in five patients with OBPP, which involves: (1) arthroscopic release of the shoulder to gain passive lateral rotation and (2) the transfer of the latissimus dorsi, where its tendon insertion is lengthened and reinforced with a tendon allograft so that it can be transferred to the posterosuperior portion of the greater tuberosity through a single anterior surgical approach.

Materials and methods

From May 2011 to July 2013, five patients with medial rotation shoulder contracture underwent arthroscopic release and latissimus dorsi tendon transfer performed by the Shoulder and Elbow Surgical Group of our institution. The research project was approved by the Human Research Ethics Committee of the same institution.

The inclusion criteria were: patients with OBPP sequela who presented functional deficit of shoulder lateral rotation, with congruent joint and without humeral head or glenoid

Table 1 – Patient clinical data.

Case	Age (years)	Gender	Side	Narakas classification	Previous brachial plexus surgeries
1	18	F	R	High (Erb)	–
2	5	F	R	High (Erb)	Neurolysis at 8 months of age
3	14	F	L	High (Erb)	–
4	4	F	L	Total	Neurotization at 5 months of age
5	7	M	R	High (Erb)	–

Source: Service records (same).

deformities (i.e., classified as maximum of grade 3, according to the Waters¹ classification).

Of the five patients, four were female and one (case 5) male. The mean age at surgery was 9 years (4–18). According to the Waters¹ classification, the shoulders of all patients were classified as grade 1 (no joint deformity). As for the modified Narakas classification, *apud* Sawyer,¹² four patients had upper brachial plexus injury (type I, involving C5–C6) and only case 4 had total plexus injury (type III). Cases 2 and 4 had already undergone prior brachial plexus surgery. Case 2 underwent a neurolysis at eight months of life; case 4, at five months, underwent C5 root neurotization to the posterior cord, C6 neurotization to the anterior division of the lateral cord, accessory nerve neurotization to the suprascapular nerve, and C7 root neurotization to the middle stem (Table 1).

For the functional assessment, active and passive range of motion (ROM) measurements were made by physicians, with the use of a goniometer. Shoulder ROMs included passive lateral rotation (with the shoulder adducted) and the following active movements: elevation in the scapular plane, lateral and medial rotation (with the shoulder adducted), hand-to-mouth, and hand-to-neck. Patients were assessed and classified according to the modified Mallet scale, *apud* Bae et al.,²⁸ for global shoulder function in patients with OBPP (Fig. 1).

All patients underwent pre- and post-operative radiographic assessment in the true AP, axillary, and scapular Y views. In two cases (2 and 3), computed tomographies were performed.

The mean postoperative outpatient follow-up time was 23 months and 15 days (range: 12–49 months). Functional re-evaluation of the operated shoulder was conducted in the same manner as the pre-operative evaluation (Table 2).

Due to the small number of cases operated so far with this technique, the results were not statistically analyzed.

Surgical technique

The first step of the surgery, which aims to gain passive lateral rotation (Fig. 2), is the arthroscopic release, performed with the patient under general anesthesia and in the beach-chair position. With the arthroscope (4-mm diameter, 30-degree angle) positioned in the posterior portal and an arthroscopic scissor in the anterior, an anterior capsulotomy until the five o'clock position is performed, as well as a tenotomy of the proximal portion of the subscapularis tendon, when necessary (Fig. 3).

Then, the open muscle transfer is made. Through a deltopectoral approach, the proximal third of the pectoralis major tendon is detached and the latissimus dorsi and teres

major tendons insertions are identified (Fig. 4). The tendon of the latissimus dorsi is repaired, totally detached from the humerus, and its muscle belly is partially dissected. It is then stretched and reinforced with a homologous tendon from a tissue bank (Fig. 5), which is trimmed to have the same width as the patient's tendon and sufficient length to reach the posterosuperior portion of the greater tuberosity. In cases 1, 2, and 3, Achilles tendons were used. In cases 4 and 5, patellar tendons.

The tendon (already stretched) is passed inferiorly to the teres minor and the lateral head of the triceps to the posterior portion of the humerus. This is done with the aid of a long curved clamp, which is passed between the deltoid and humeral head in order to reach the tendon (Fig. 5). Finally, with the shoulder placed at 15° of abduction and 60° of rotation, the transfer is sutured (with nonabsorbable No. 5 wire) to the posterosuperior portion of the greater tuberosity (Fig. 6).

At the end of surgery, the patient is immobilized in neutral rotation with an abduction sling, which is kept full-time for six to eight weeks. In this period, the sling is removed only for bathing and for daily physical therapy, which involves only passive lateral rotation shoulder exercises. After this period, shoulder ROM gain and maintenance are initiated, but still without strengthening. The latter is started only four months after surgery.

Results

The results are shown in Table 2 in detail, which compares the pre- and postoperative ROMs (and their scores in the modified Mallet²⁸ classification) of each evaluated motion, separated by patient. This allows for a clear picture of the functional evolution of each operated shoulder (Table 2).

In general, passive and active lateral rotations improved, while medial rotation got worse. Other movements (elevation, hand-to-mouth, and hand-to-neck) presented less consistent evolution. The mean modified Mallet score²⁸ improved by 4.2 points (11.4–15.6; Table 2).

Discussion

As mentioned in the inclusion criteria of this study, candidates for the surgical technique described are those with functional deficit of lateral rotation of the shoulder and glenohumeral changes less than or equal to grade 3 according to the Waters et al.¹ classification (with congruent joint and without humeral head or glenoid deformities).²⁶ Patients without the limitation of the lateral rotation have reduced risk of

Table 2 – Comparison of preoperative vs. postoperative function, stratified by patient and motion.

Case	Follow-up (months)	Passive lateral rotation		Active lateral rotation		Elevation		Medial rotation		Hand to mouth		Hand to neck		MALLET SCORE	
		Pre-op	Post-op	Pre-op	Post-op	Pre-op	Post-op	Pre-op	Post-op	Pre-op	Post-op	Pre-op	Post-op	Pre-op	Post-op
1	49	30°	45°	-10° (2)	-10° (2)	75° (3)	80° (3)	Sacrum (3)	Sacrum (3)	Marked trumpet sign (2)	Partial trumpet sign (3)	Not possible (2)	Not possible (2)	13	13
2	26	20°	70°	-45° (1)	0° (2)	90° (3)	130° (4)	T12 (4)	Not possible (2)	Marked trumpet sign (2)	<40° abd (4)	Not possible (2)	Easy (4)	9	16
3	20	10°	80	-5° (2)	30° (4)	150° (4)	140° (4)	T7 (5)	T7 (5)	Marked trumpet sign (2)	Partial trumpet sign (3)	Hard (3)	Easy (4)	12	20
4	14	45°	90	0° (2)	70° (4)	90° (3)	80° (3)	Trochanter (2)	Not possible (2)	Marked trumpet sign (2)	Partial trumpet sign (3)	Not possible (2)	Not possible (2)	8	14
5	12	45°	80°	10° (3)	15° (4)	80° (3)	80° (3)	T12 (4)	Gluteus (2)	Partial trumpet sign (3)	Partial trumpet sign (3)	Not possible (2)	Hard (3)	15	15
MEAN	24	30°	73°	-10° (2)	21° (3.2)	97° (3.2)	102° (3.4)	(3.6)	(2.8)	(2.2)	(3.2)	(2.2)	(3)	11.4	15.6

Source: Service records (same).

Values between parenthesis = modified Mallet score results. Follow-up = postoperative outpatient follow-up time.

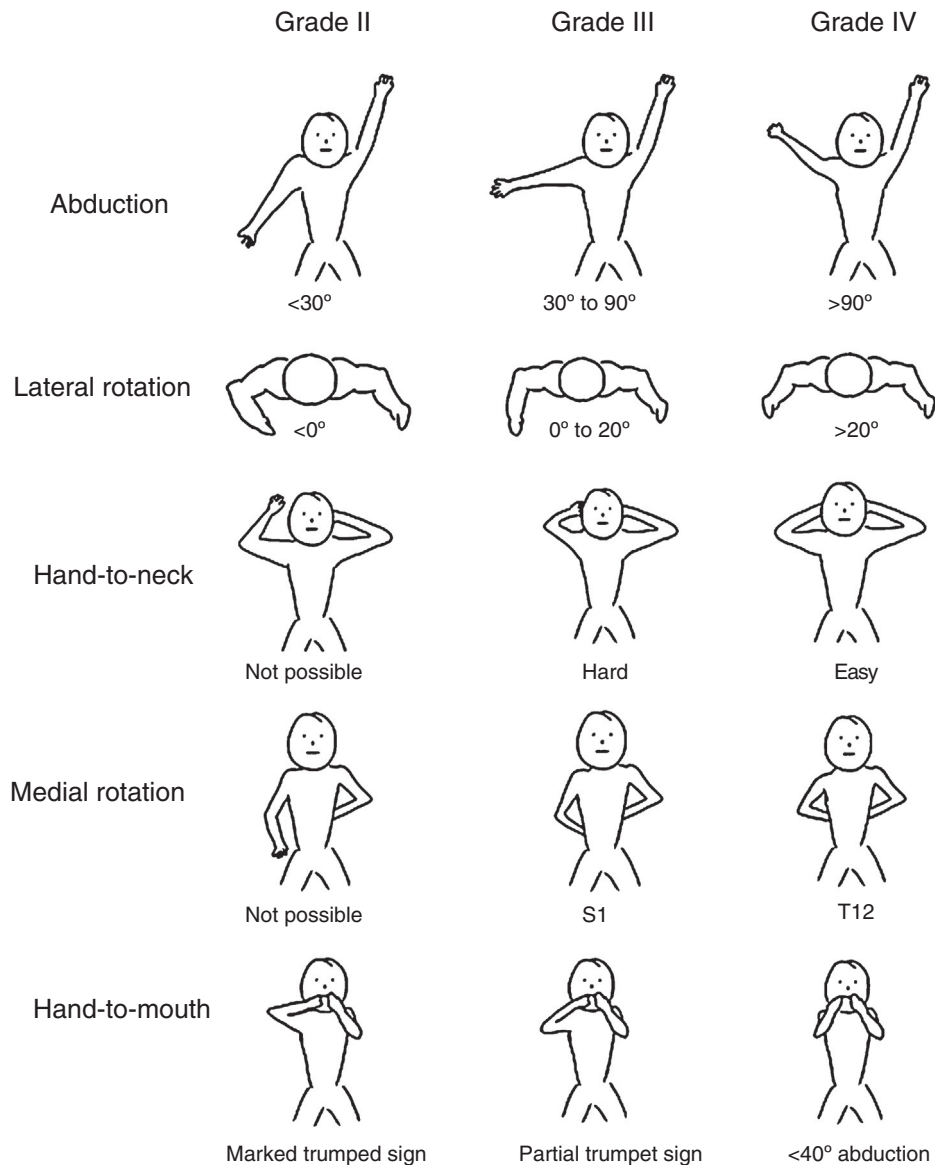


Fig. 1 – Schematic representation of the modified Mallet classification²⁸ to assess shoulder function in patients with OBPP. Grade I, no function; grade V, function equal to the contralateral shoulder. Grades II, III, and IV are represented for each motion. S1, first sacral vertebra; T12, 12th thoracic vertebra.

developing joint deformity and therefore would not benefit from this procedure.¹⁹

In order to provide the most appropriate therapeutic indication in each case, radiological assessment is necessary. In addition to assessing joint congruity and deformities of the glenoid and humeral head, rated according to Waters classification,¹ X-rays and computed tomography allow for the assessment and measurement of the shape and version of the glenoid joint surface and the amount of posterior subluxation of the humeral head.^{1,4,9,22} Pedowitz et al.⁴ and Kozin et al.⁹ demonstrated that magnetic resonance imaging can also be used for this purpose, and is indicated in cases where the humeral epiphysis and glenoid are still cartilaginous.

Regarding the surgical technique, the arthroscopic release used in the present study is not unusual; it was first described by Pearl¹⁰ in 2003. The use of the arthroscopic approach (rather

than open) is justified by the fact that subscapularis tenotomy is not always necessary to obtain the desired passive lateral rotation. By not performing a tenotomy, in theory, the risk of iatrogenic lateral rotation contracture is reduced; it can occur with other open subscapularis stretching techniques.¹⁰ As advocated by Pearl et al.,^{8,10} Pedowitz et al.,⁴ and Kozin et al.,⁹ it is noteworthy that the release is considered incomplete when the passive external rotation achieved with the shoulder abducted at 90° is lower than 45° (Fig. 2). If that is the case, total release of the inferior glenohumeral ligament to a slightly posterior point in the middle portion of the axillary recess should be performed^{4,8-10} (the meticulous dissection of the axillary recess before its release is of paramount importance to avoid iatrogenic injury to the axillary nerve), as well as subscapularis tenotomy in its proximal portion, which is precisely the most contracted portion.⁷

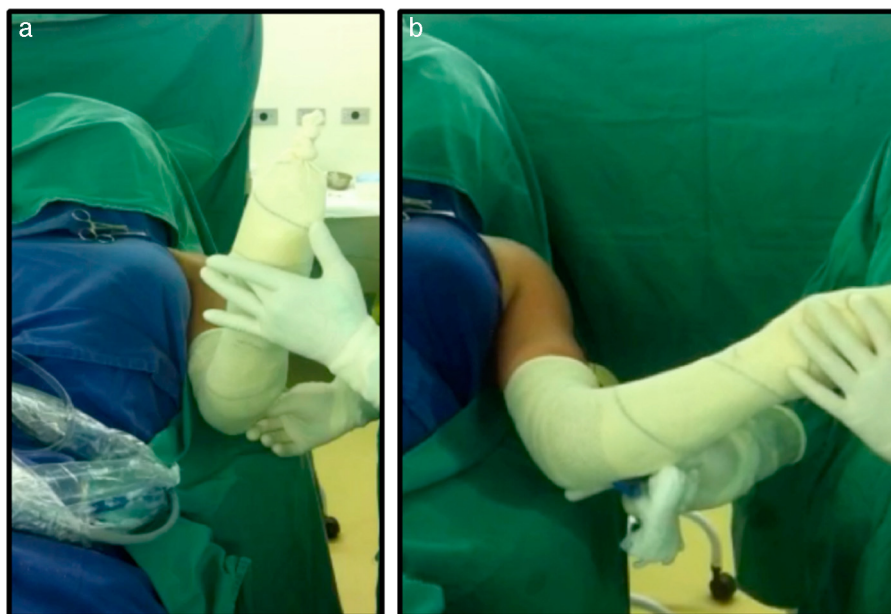


Fig. 2 – Case 3. Passive lateral rotation of the left shoulder before (a) and after (b) the arthroscopic procedure.

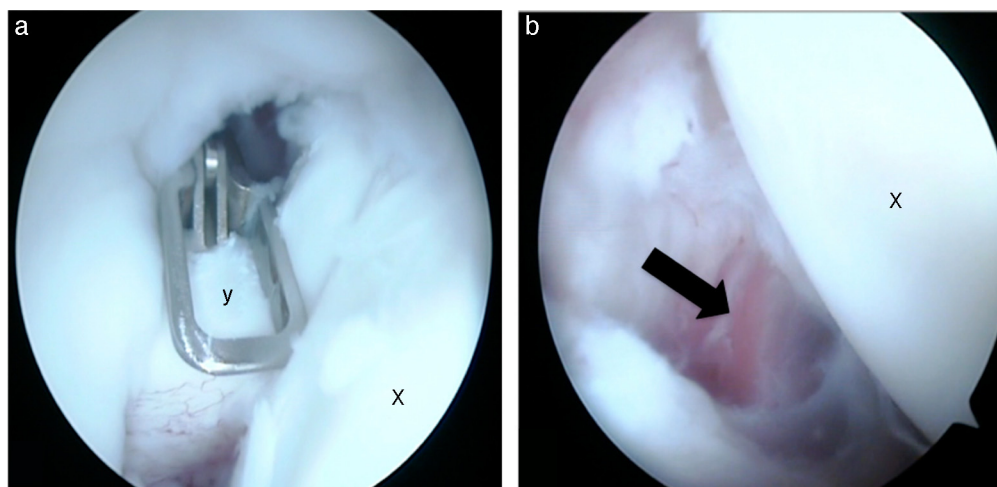


Fig. 3 – Case 2. View of the intra-articular space of the right shoulder, with the arthroscope in the posterior portal. x = humeral head; y = subscapularis tendon. (A) Tenotomy of the proximal portion of the subscapularis muscle with a punch. (B) After subscapularis tenotomy and anterior capsulotomy (arrow).

Regarding the tendon transfer, the first aspect considered in its development was related to the surgical approach. To make a tendon transfer specifically to the posterior superior portion of the greater tuberosity, some surgeons use a single posterior approach,^{2,3,9,18} a single axillary approach,²⁰ an anterior approach (deltopectoral) associated with a posterior approach,²⁶ or a saber-cut approach associated to a posterior approach.^{29,30} No articles describing the tendon transfer to the described site using the technique described in the present study (a single anterior access route) were retrieved in the literature.

The deltopectoral approach was chosen for its advantages when compared to other approaches, which are: orthopedic surgeons familiarity; no violation of the deltoid muscle; allows, when necessary, the osteotomy of the dysplastic

coracoid process^{12,20} and elongation of the tendons of the pectoralis major, short head of the biceps, and coracobrachialis⁷; and allows the detachment of the tendons of the latissimus dorsi and teres major under good viewing,³¹ which, in the authors' opinion, reduces the risk of iatrogenic injury to the axillary nerve. However, the anterior approach has the following disadvantages: in the authors' opinion, greater risk of iatrogenic injury to the radial nerve (it cannot be easily identified, despite being very near the surgical site [Fig. 4]); and the impossibility of a wide dissection of the latissimus dorsi and teres major muscles, which does not allow for their traction to the posterosuperior portion of the greater tuberosity.

In order to benefit from the deltopectoral approach, and to counterbalance these two disadvantages, two important steps

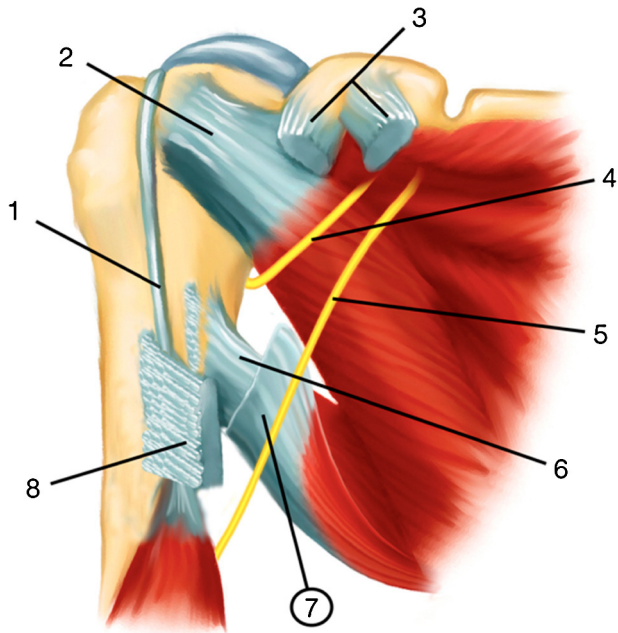


Fig. 4 – Schematic representation of the right shoulder. Anterior view. The deltoid muscle is not shown. (1) Long head of the biceps; (2) subscapularis tendon; (3) insertion of the conjoint tendon and the pectoralis minor tendon into the coracoid process (muscles are not shown); (4) axillary nerve; (5) radial nerve; (6) teres major tendon; (7) latissimus dorsi tendon (sectioned); and (8) humeral insertion of the pectoralis major muscle (muscle is not shown).

were added to the technique: (1) arthroscopical joint release (which has already been described and discussed); and (2) tendon lengthening and strengthening with a graft, to allow the fixation of the latissimus dorsi to the posterior superior

aspect of the greater tuberosity, which in theory would be biomechanically more favorable. In the present cases, allografts of calcaneal or patellar tendons were used, as they were considered to be sufficiently strong and wide. Allografts could also be used in order to strengthen tendon transfer. Thus, the authors believe that it is possible to maintain the patient with only a functional sling and without rigid thoracobrachial immobilization (plaster or orthosis).

Another important aspect taken into consideration in the development of the technique was what would be the biomechanically best anatomical site for the tendon transfer attachment. Reviewing the literature, two trends were identified: (1) some authors^{5-8,19} use the lateral cortex of the humerus, just below the greater tuberosity, the same place suggested by the L'Episcopo technique¹⁶; (2) others^{2-4,9,18,20,26} use the posterosuperior portion of the greater tuberosity (or on the rotator cuff itself), according to the technique described by Hoffer et al.¹⁸ The difference in the principle behind the two techniques lies in the vectors of the forces generated by the transferred musculotendinous units. In the first group, the transfer acts only as a lateral rotator of the shoulder, while in the second group, in addition to acting as a lateral rotator, it theoretically allows for gains in shoulder abduction, which is one of the compromised movements in patients with OBPP sequelae. According to Hoffer et al.,¹⁸ this is because a transfer made to the posterosuperior portion of the greater tuberosity increases the stabilizing effect of the rotator cuff and thus enables the deltoid to be more effective as a shoulder abductor. However, it is worth discussing whether this theoretical difference is able to promote a change in clinical outcomes.

In the analysis of results obtained in the literature, it was observed that several studies (regardless of location of tendon transfer) reported improved lateral shoulder rotation for most patients.^{2,3,5,6,8,9,18-20,26} However, the same could not be said for abduction gains. Of the studies that used transfer to the

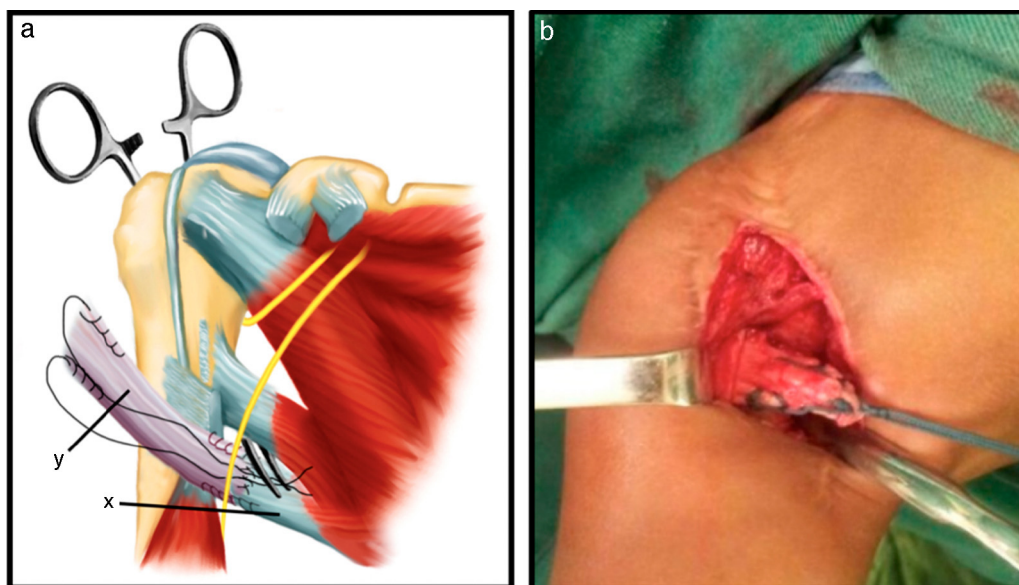


Fig. 5 – (a) Schematic representation of the right shoulder. Anterior view: the deltoid muscle is not shown. The latissimus dorsi tendon (x) is reinforced and lengthened with tendon allograft (y). Then, a long curved clamp is passed between the deltoid and the humeral head in order to reach it and pass it to the posterior portion of the shoulder. (b) Right shoulder: intraoperative photograph (case 4). Arrow: the tendon (already extended) has been passed around the humeral head.

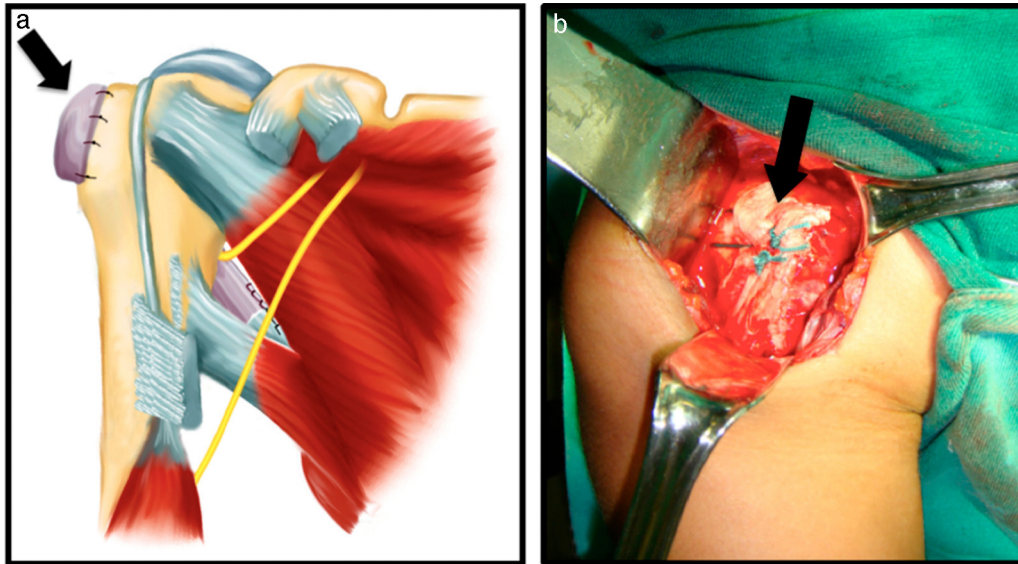


Fig. 6 – Schematic representation (a) and intraoperative photograph (case 1) (b) right shoulder. Anterior view. Arrows: site of transfer suture at the posterior superior aspect of the greater tuberosity.

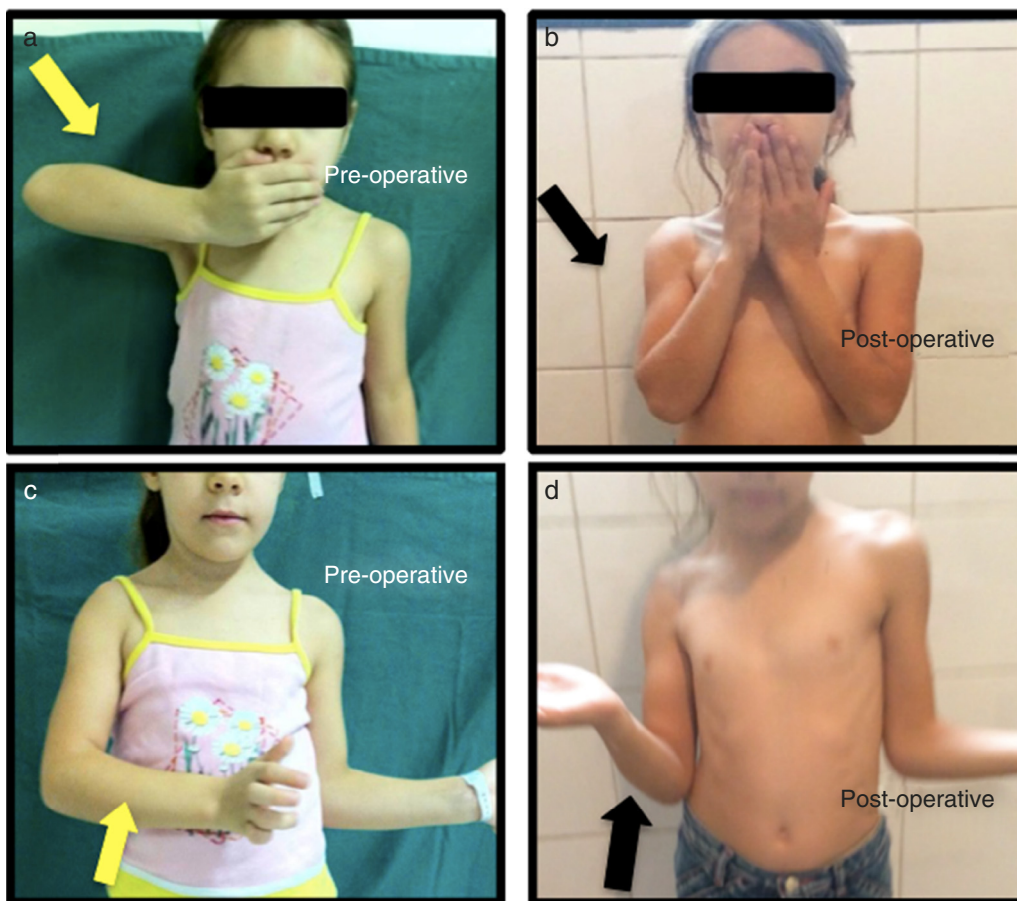

Fig. 7 – Case 2. Pre- (a) and post-operative (b) photographs demonstrating patient's hand-to-mouth motion. Note the "trumpet sign" (arrow in the figure "a"), which is the need for shoulder abduction to bring the hand close to the face due to loss of active lateral rotation of the shoulder. Pre- (a) and post-operative (b) photographs of the active lateral rotation of the affected shoulder.

lateral cortex of the humerus, improved amplitude of such motion for most patients was only observed in the studies by Covey et al.¹⁹ and by Wickstrom et al.⁶ However, abduction improved in all studies in which the transfer was made to the posterosuperior portion of the greater tuberosity.^{2,3,9,18,20,26}

Specifically in relation to the improvement of shoulder elevation in the scapular plane, presented results are lesser than expected (Table 2). Although both tendon transfer and the use of a graft decrease the strength of the transferred muscle group, the authors believe that the increase in effectiveness of the deltoid as an abductor after the transfer of the latissimus dorsi to the posterosuperior portion of the greater tuberosity¹⁸ occurs more due to the tenodesis effect of the transfer than to active muscle contraction, as proposed Gerber et al.^{29,30} and by Nové-Josserand et al.³² Therefore, the addition of a tendon graft would not affect the functional outcome. However, only case 2 presented improvements of such motion (Table 2), while in the other four it was virtually unchanged (Table 2). Considering this fact, the authors believe that the lifting motion can be further improved in future cases if the suture of the bone transfer is made with the shoulder at a greater degree of abduction, which would provide higher tension to the transfer.

Improvement in lateral rotation was expected, as the findings were similar to those found in other series.⁵ This was observed with the improvement in active and passive lateral rotation, which was achieved in four out of five patients (Table 2). Other findings that corroborate this theory were the improvement (also in almost every case) of hand-to-mouth and hand-to-neck movements (Table 2), because the movement of bringing the hand to the face without the need of shoulder abduction requires active lateral rotation of the shoulder.^{11,33} In clinical practice, a less pronounced trumpet sign translates into an improvement of the active lateral rotation ability (Fig. 7).

Full open subscapularis tenotomy, in theory, leads to reduction in active medial rotation ability. The proximal portion of the subscapularis tendon can be accessed and undergo intra-articular tenotomy through arthroscopy.^{4,8-10} This tendon portion is precisely the one that Zancolli and Zancolli⁷ believe to be the most shortened. Therefore, arthroscopic surgery theoretically provides a lateral rotation gain (through the release of the shortened portion of the tendon) without causing the loss of active medial rotation, as it would maintain the distal portion of the subscapularis intact. The study by Kozin et al.⁹ reinforces this thesis by reporting no changes in medial rotation ability after arthroscopic partial subscapularis release. However, Pearl et al.,⁸ in a study published in 2006, demonstrated that their patients had significant loss of this motion after undergoing the same arthroscopic surgical technique. Our experience yielded mixed results. In two cases, the medial rotation was unchanged. In three, it got worse.

Despite the small number of patients in the present studies, and in light of the results, the authors believe that it is possible to improve upper limb function in this group of patients using the surgical technique described. It is important to mention that the limb function in these patients is extremely precarious, and any percentage of improvement can greatly benefit their daily activities.

Conclusion

The latissimus dorsi muscle tendon can be transferred to the posterosuperior portion of the greater tuberosity through a single deltopectoral access when lengthened with a tendon allograft.

Conflicts of interest

The authors declare no conflicts of interest.

REFERENCES

1. Waters PM, Smith GR, Jaramillo D. Glenohumeral deformity secondary to brachial plexus birth palsy. *J Bone Joint Surg Am.* 1998;80(5):668-77.
2. Pagnotta A, Haerle M, Gilbert A. Long-term results on abduction and external rotation of the shoulder after latissimus dorsi transfer for sequelae of obstetric palsy. *Clin Orthop Relat Res.* 2004;426:199-205.
3. Waters PM, Bae DS. Effect of tendon transfers and extra-articular soft-tissue balancing on glenohumeral development in brachial plexus birth palsy. *J Bone Joint Surg Am.* 2005;87(2):320-5.
4. Pedowitz DI, Gibson B, Williams GR, Kozin SH. Arthroscopic treatment of posterior glenohumeral joint subluxation resulting from brachial plexus birth palsy. *J Shoulder Elbow Surg.* 2007;16(1):6-13.
5. Cabral JRD, Crepaldi BE, Sambuy MTC, Costa ACD, Abdouni YA, Chakkour I. Avaliação da função do membro superior nos pacientes com paralisia obstétrica após cirurgia de Sever-L'piscopo modificada. *Rev Bras Ortop.* 2012;47(4):451-4.
6. Wickstrom J, Haslam Et Hutchinson RH. The surgical management of residual deformities of the shoulder following birth injuries of the brachial plexus. *J Bone Joint Surg Am.* 1955;37(1):27-36.
7. Zancolli EA, Zancolli ER Jr. Palliative surgical procedures in sequelae of obstetric palsy. *Hand Clin.* 1988;4(4):643-69.
8. Pearl ML, Edgerton BW, Kazimiroff PA, Burchette RJ, Wong K. Arthroscopic release and latissimus dorsi transfer for shoulder internal rotation contractures and glenohumeral deformity secondary to brachial plexus birth palsy. *J Bone Joint Surg Am.* 2006;88(3):564-74.
9. Kozin SH, Boardman MJ, Chafetz RS, Williams GR, Hanlon A. Arthroscopic treatment of internal rotation contracture and glenohumeral dysplasia in children with brachial plexus birth palsy. *J Shoulder Elbow Surg.* 2010;19(1):102-10.
10. Pearl ML. Arthroscopic release of shoulder contracture secondary to birth palsy: an early report on findings and surgical technique. *Arthroscopy.* 2003;19(6):577-82.
11. Waters PM. Update on management of pediatric brachial plexus palsy. *J Pediatr Orthop B.* 2005;14(4):233-44.
12. Sawyer JR. Paralytic. In: Canale ST, Beaty JH, editors. *Campbell's operative orthopaedics.* 12 ed. Philadelphia: Mosby Elsevier; 2013. p. 1255-333.
13. Vieira LAG, Poderoso MA, Gonçalves MCK, Hissadomi MI, Benegas E, Ferreira Neto AA, et al. A osteotomia de centralização da cabeça umeral, na luxação posterior do ombro, seqüela de paralisia obstétrica. *Rev Bras Ortop.* 2004;39(11/12):661-9.
14. Sever JW. The results of a new operation for obstetrical paralysis. *Am J Orthop Surg.* 1918;16:248-57.
15. L'piscopo JB. Tendon transplantation in obstetrical paralysis. *Am J Surg.* 1934;25:122-5.

16. L'Episcopo JB. Restoration of muscle balance in the treatment of obstetrical paralysis. *N Y State J Med.* 1939;39:357.
17. Lopes EI, Chakkour I, Gomes MD, Cauchioli CA, Ramirez JFG, Lopes Filho JD. Osteotomia de rotação externa do úmero no tratamento das deformidades em rotação interna do ombro nas seqüelas de paralisia obstétrica. *Rev Bras Ortop.* 1996;31(4):322-6.
18. Hoffer MM, Wickenden R, Roper B. Brachial plexus birth palsies: results of tendon transfers to the rotator cuff. *J Bone Joint Surg Am.* 1978;60(5):691-5.
19. Covey DC, Riordan DC, Milstead ME, Albright JA. Modification of the L'Episcopo procedure for brachial plexus birth palsies. *J Bone Joint Surg Br.* 1992;74(6):897-901.
20. Phipps GJ, Hoffer MM. Latissimus dorsi and teres major transfer to rotator cuff for Erb' palsy. *J Shoulder Elbow Surg.* 1995;4(2):124-9.
21. Gilbert A, Brockman R, Carlouz H. Surgical treatment of brachial plexus birth palsy. *Clin Orthop Relat Res.* 1991;264:39-47.
22. Pearl ML, Edgerton BW. Glenoid deformity secondary to brachial plexus birth palsy. *J Bone Joint Surg Am.* 1998;80(5):659-67.
23. Giostrì GS, Machezini EJ, Pasin AP. Rotação interna na paralisia obstétrica: comparação dos resultados dos procedimentos de Sever-L'Episcopo e osteotomia derrotadora do úmero. *Rev Bras Ortop.* 1996;31(1):33-5.
24. Chuang DC, Ma HS, Wei FC. A new strategy of muscle transposition for treatment of shoulder deformity caused by obstetric brachial plexus palsy. *Plast Reconstr Surg.* 1998;101(3):686-94.
25. Waters PM, Peljovich AE. Shoulder reconstruction in patients with chronic brachial plexus birth palsy: a case-control study. *Clin Orthop Relat Res.* 1999;(364):144-52.
26. Ozben H, Atalar AC, Bilsel K, Demirhan M. Transfer of latissimus dorsi and teres major tendons without subscapularis release for the treatment of obstetrical brachial plexus palsy sequela. *J Shoulder Elbow Surg.* 2011;20(8):1265-74.
27. Santos C, Pereira A, Pinto RR, Trigueiros M, Lemos R, Silva C. Cirurgia paliativa do ombro em paralisia obstétrica do plexo braquial. *Rev Iberam Cir Mano.* 2010;38(1):25-30.
28. Bae DS, Waters PM, Zurakowski D. Reliability of three classification systems measuring active motion in brachial plexus birth palsy. *J Bone Joint Surg Am.* 2003;85A(9):1733-8.
29. Gerber C, Vinh TS, Hertel R, Hess CW. Latissimus dorsi transfer for the treatment of massive tears of the rotator cuff: a preliminary report. *Clin Orthop Relat Res.* 1988;(232):51-61.
30. Gerber C. Latissimus dorsi transfer for the treatment of irreparable tears of the rotator cuff. *Clin Orthop Relat Res.* 1992;(275):152-60.
31. Boileau P, Chuinard C, Roussanne Y, Neyton L, Trojani C. Modified latissimus dorsi and teres major transfer through a single delto-pectoral approach for external rotation deficit of the shoulder: as an isolated procedure or with a reverse arthroplasty. *J Shoulder Elbow Surg.* 2007;16(6):671-82.
32. Nové-Josserand L, Costa P, Liotard JP, Safar JF, Walch G, Zilber S. Results of latissimus dorsi tendon transfer for irreparable cuff tears. *Orthop Traumatol Surg Res.* 2009;95(2):108-13.
33. Sobania LC, Kimura LK. Paralisia braquial obstétrica. In: Pardini Júnior AJ, Freitas AF, editors. *Cirurgia da mão, lesões não traumáticas.* 2 ed. Rio de Janeiro: Medbook; 2008. p. 299-310.