

Anti-Allergic Effects of *Vernonia amygdalina* Leaf Extracts in Hapten-Induced Atopic Dermatitis-Like Disease in Mice

Nlandu Roger Ngatu¹, Maiko K Okajima², Maki Yokogawa³, Ryoji Hirota¹, Mikiro Takaishi³, Masamitsu Eitoku¹, Basilua Andre Muzembo¹, Asif Bhati Sabah¹, Takao Saruta⁴, Mitsuhiro Miyamura⁵, Tatsuo Kaneko², Shigetoshi Sano³ and Narufumi Suganuma¹

ABSTRACT

Background: Atopic dermatitis (AD) is a chronic inflammatory skin disease characterized by pruritic and eczematous skin lesions. In this study, AD-like disease was induced in NC/Nga mice so as to evaluate the anti-allergic effects of *Vernonia amygdalina* leaf extracts (VAM).

Methods: Forty NC/Nga mice were purchased for each of the two protocols (prophylactic and curative) of the study. Mice were randomly divided in groups of five or six after sensitization with 5% trinitrochlorobenzene (TNCB): aqueous extracts (VAM1), methanolic extracts (VAM2), hydrocortisone (HCT), buffer for the control (TNCB) and the normal mice (NORM) groups.

Results: As for HCT, VAM1 and VAM2-pretreated mice showed significantly lower number of scratching behavior episodes ($p < 0.01$; vs. TNCB) following TNCB challenge. In addition, VAM1, VAM2 exerted a significant inhibitory effect on the development of AD skin symptoms (vs. TNCB group; $p < 0.001$), the production of IgE, TNF-alpha ($p < 0.05$), IL-5 and IFN-gamma ($p < 0.01$) (vs. TNCB group) and on the increase in ear thickness ($p < 0.05$) in prophylactic protocol.

In the AD curative protocol, topical VAM1, VAM2 markedly improved skin lesions such as erythema/hemorrhage ($p < 0.05$), scaling/dryness, erosion/excoriation ($p < 0.01$) (vs. TNCB mice). Furthermore, a significant decrease in ear thickness was noted in VAM1, VAM2, HCT groups (vs. TNCB group; $p < 0.05$) as well as the serum total IgE, MCP-1 ($p < 0.01$) and eotaxin ($p < 0.05$). VAM2 also improved chronic eczema dermatitis skin symptoms in a patient.

Conclusions: Results from this report suggest that VAM extracts, known as ERK pathway inhibitor, prevent and improve atopic/eczema dermatitis syndrome.

KEY WORDS

atopic dermatitis, eosinophilia, scratch, *Vernonia amygdalina*

INTRODUCTION

Environmental factors and stress have been reported to play a role in the development and aggravation of dermatitis. The prevalence of atopic dermatitis (AD) is increasing, especially in industrialized countries,

and 10-20% of children worldwide are affected by AD. It is an illness characterized by pruriginous eczema as its main morbid process in which aggravation and abatement are repeated, and most AD patients present an atopic disposition. The control of inflammation, the reduction of pruritus and skin care is essen-

¹Department of Environmental Medicine, ²Department of Dermatology, ³Department of Pharmacy, Kochi University Medical School, ⁴Saruta Clinic of Dermatology, Kochi and ⁵Department of Materials Science, Japan Advanced Institute of Science and Technology, Ishikawa, Japan.

Conflict of interest: No potential conflict of interest was disclosed.
Correspondence: Narufumi Suganuma, Department of Environ-

mental Medicine, Kochi University Medical School, Kohasu, Okochi, Nankoku-city, Kochi 783-8505, Japan.

Email: nsuganuma@kochi-u.ac.jp

Received 3 November 2011. Accepted for publication 13 April 2012.

©2012 Japanese Society of Allergology

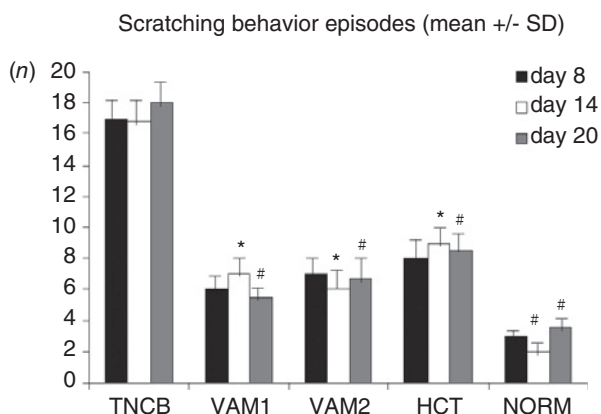


Fig. 1 Distribution of total number of scratching behaviors following mice exposure to the chemical allergen (prophylactic protocol; $n = 25$). * p -value less than 0.05; # p -value less than 0.01 (vs. TNCB mice). TNCB, 2,4,6-trinitrochlorobenzene (buffer-treated control group); VAM1, aqueous extracts of *Vernonia amygdalina* leaf treated group; VAM2, alcoholic extracts of *Vernonia amygdalina* leaf treated group; HCT, hydrocortisone-treated mice; NORM, buffer-treated normal mice. The figure shows significantly lower number of scratching behavior episodes in VAM1, VAM2 and HCT mice on days 14 and 20 ($p < 0.05$ and $p < 0.01$, respectively) as compared with TNCB group. Normal control mice that were not exposed to the hapten had markedly lower scratching episodes on days 14 and 20 ($p < 0.01$, vs. TNCB group).

tial in the treatment of AD.¹⁻⁴ T cells and eosinophils are also thought to play a major role in the pathogenesis of the disease. In human, skin lesion in AD reveals a mononuclear cells infiltrate consisting of activated CD4⁺ T cells and most AD patients have increased serum levels of IgE antibodies against many kinds of allergens.^{5,6}

Although evidence suggests that the development and pathogenesis of AD are associated with immunologic reaction such as type I allergic reaction,^{7,8} a significant increase in number of cells expressing the Th1 cytokines, IFN- γ can be observed in some chronic AD conditions.^{4,7-11}

Vernonia amygdalina (VAM) is an edible African plant whose leaves are used in traditional medicine by some Congolese villagers to relieve cough and hemorrhoids. It has been reported that the plant extracts have an antioxidant, anti-inflammatory and anti-tumor activities.¹¹⁻¹³ Up to now, there have been no published researches on the beneficial effects of VAM extracts on skin allergy.

NC/Nga (NC) mice are a species that spontaneously develop eczematous AD-like skin lesions when kept under conventional care and have been used in several studies related to AD induction in mice.⁶ In this experiment, NC/Nga mice were used to evaluate the prophylactic and curative effects of VAM extracts

in a murine model of atopic dermatitis-like disease.

METHODS

NC/Nga MICE

In total, eighty inbred male NC/Nga mice (6 weeks of age) were purchased from Japan SLC (Hamamatsu, Shizuoka, Japan) for this study. Two separate experiments were conducted in 2010 and 2011, the prophylactic and curative protocols for atopic dermatitis-like disease. Forty animals were used for each protocol. Mice were always housed under conventional conditions at the animal facility of Kochi University Medical School in filter-topped macrolon cages, with a bedding of wood chips (temperature: 23°C; 50-60% of relative humidity; 12-h light/dark cycle). A standard lab chow was provided with acidified tap water that was taken *ad libitum* by the animals. The research adhered to the animal facility guidelines of Kochi Medical School (C000144). Mice were maintained until they were 7 weeks old (-20-24 g body wt) before their use in the study.

VERNONIA AMYGDALINA EXTRACTS PREPARATION

Vernonia amygdalina species are believed to differ according to their origins. The plant is cultivated in west Africa region where its leaves are used in ethnomedicine and also as vegetable and drink; however, in the Democratic Republic of Congo, it often grows as a wild plant.

Our preliminary study with the plant, realized at Japan Advanced Institute of Science and Technology (JAIST), consisted in high performance liquid chromatography (HPLC) and gass chromatography mass spectrometry (GC-MS) analyses of the leaf extracts which showed that the alcoholic extracts' main compounds are terpenoids (sesquiterpenes) and lipids, whereas the water extracts are mainly composed of polyphenols (flavonoids), saponins and also lipids. The most active terpene and flavonoid in the extracts have been reported to be *vernodalin* and *dicafeoyl quinic acid* and its derivatives, respectively.^{11,12}

For this study, fresh leaves of *Vernonia amygdalina* leaves were harvested in a garden in Kinshasa, Democratic Republic of Congo, by one of the authors of this report; they were rinsed with distilled water and sorted to remove dead leaves and debris. Leaves were sun-dried, milled so as to get a course powder (1.2 Kg in total). For the preventive and curative protocols of the experiment, two separate samples of VAM powder (100 g each) were separately mixed and homogenized with hot distilled water for VAM1 group (water extraction), and methanol for VAM2 group (alcoholic extraction). The mixtures were allowed to stand on the mixer for 24 hours after which they were filtered. The filtrates were then placed in a rotary evaporator, yielding 35.1 g and 33.2 g (nearly 35% and 33% yields of crude extracts) for the alcoholic

Table 1 Mean severity score for ear skin symptoms on day 8-14-20 of AD prophylactic protocol according to mice group (n = 25; mean +/- SD)

Symptom	Day	VAM1	VAM2	HCT	TNCB	NORM
Scaling/dryness	8	0.00	0.00	0.00	0.00	0.00
	14	0.25	0.00	0.25	1.50	0.00
	20	1.00	0.50	1.00	2.50	0.00
		<i>p</i> < 0.001	<i>p</i> < 0.001	<i>p</i> < 0.001	—	—
Erythema/hemorrhage	8	0.00	0.00	0.00	0.00	0.00
	14	0.25	0.00	0.00	1.50	0.00
	20	0.75	0.25	0.50	2.75	0.00
		<i>p</i> = 0.059	<i>p</i> < 0.001	<i>p</i> < 0.001	—	—
Excoriation/erosion	8	0.00	0.00	0.00	0.00	0.00
	14	0.50	0.00	0.00	2.00	0.00
	20	0.50	0.00	0.25	2.50	0.00
		<i>p</i> = 0.001	<i>p</i> < 0.001	<i>p</i> < 0.001	—	—

p, *p*-value; VAM1, aqueous extract of *Vernonia amygdalina* group; VAM2, alcoholic extract of *Vernonia amygdalina* group; TNCB, negative control group; NORM, normal control group.

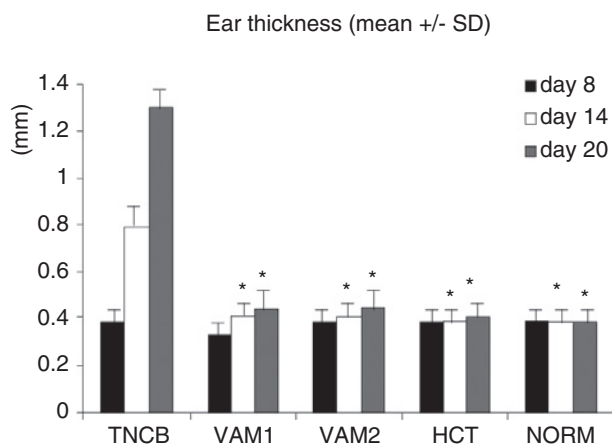


Fig. 2 Pretreatment with *Vernonia amygdalina* extracts inhibits the increase in ear thickening following challenge to the hapten. **p*-value less than 0.05 (vs. TNCB). TNCB, trinitrochlorobenzene; VAM1, aqueous extracts of *Vernonia amygdalina* leaf; VAM2, alcoholic extracts of *Vernonia amygdalina* leaf; HCT, hydrocortisone; NORM, normal control. The figure shows that, despite repeated challenges to the chemical allergen, both VAM1 and VAM2, as well as HCT, significantly prevented the increase in ear thickness as compared with TNCB mice (*p* < 0.05). In addition, no statistically significant difference was observed between VAM1 and VAM2 groups (*p* > 0.05).

and aqueous extracts, respectively. The solid residues were mixed with distilled water for the experiment and kept in the refrigerator at 4°C. The solution used in the experiments was 7 mg/ml for both aqueous (VAM1) and alcoholic extracts (VAM2).

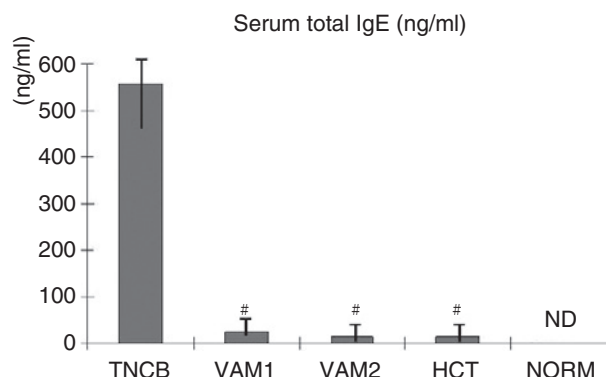


Fig. 3 Serum level of total IgE (prophylactic protocol; n = 25; mean +/- SD). #*p*-value less than 0.01. ND, not detected; TNCB, buffer-treated control group; VAM1, aqueous extract of *V. amygdalina* treated group; VAM2, methanolic extract of *V. amygdalina* treated group; HCT, hydrocortisone-treated group; NORM, buffer-treated normal control group. The figure shows that serum level of total IgE was significantly lower in VAM1, VAM2, and HCT-pretreated groups as compared with TNCB group (*p* < 0.01). The serum IgE level was not detectable in normal mice.

MICE SENSITIZATION, AD INDUCTION AND TREATMENT

For each of the experimental protocols, NC/Nga mice were randomly divided into groups of five or six (for the prophylactic and curative protocols, respectively) a week after sensitization with 5% trinitrochlorobenzene. In this report, five mice groups are considered, including VAM1, VAM2, hydrocortisone (HCT), and buffer-treated trinitrochlorobenzene (TNCB) and normal control (NORM) for a total of 25 mice for the prophylactic protocol and 30 mice for the curative protocol. Data related to another plant mate-

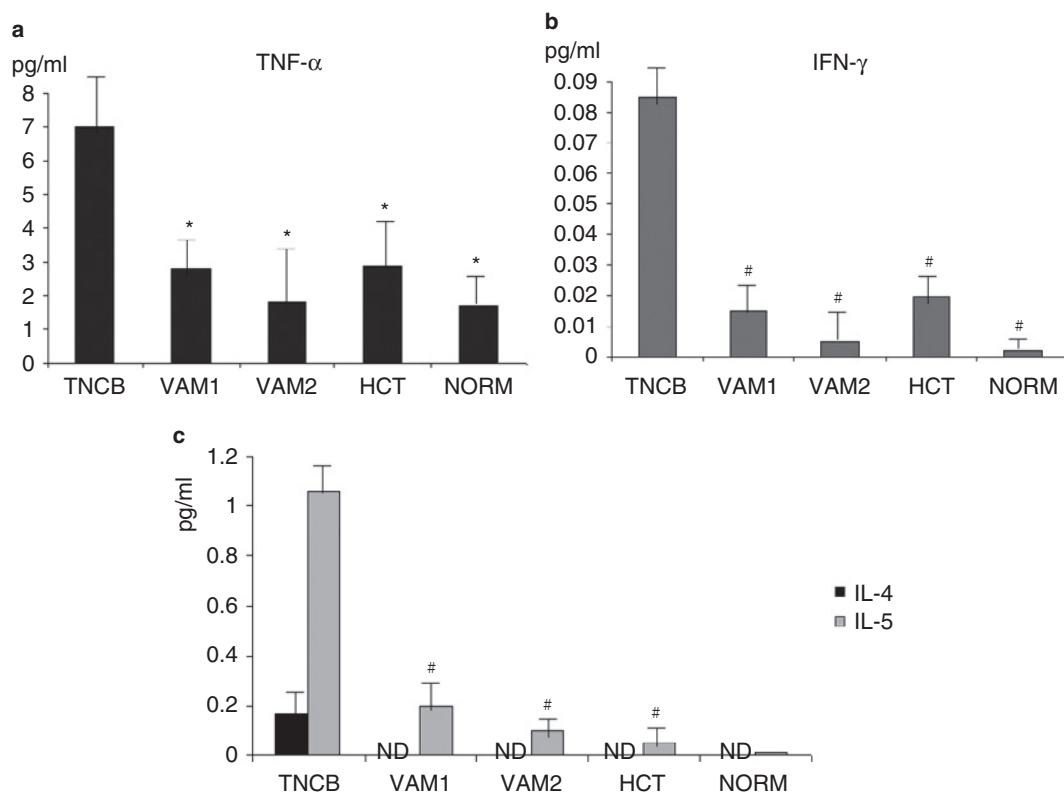


Fig. 4 Serum cytokine levels (preventive protocol; $n = 25$; mean \pm SD). # p -value less than 0.01; * p -value less than 0.05. ND, not detected; VAM1, aqueous extract of *Vernonia amygdalina* leaf treated mice; VAM2, methanolic extract of *Vernonia amygdalina* leaf treated mice; HCT, hydrocortisone-treated mice; TNCB, 2,4,6-trinitrochlorobenzene (buffer-treated control group); NORM, buffer-treated normal control mice. The figure shows significantly lower levels of serum TNF- α in VAM1, VAM2 and hydrocortisone-pretreated mice groups ($p < 0.05$; vs. TNCB group) (a). Similarly, markedly lower levels of IFN- γ (b) and IL-5 were found in VAM1, VAM2 and HCT groups ($p < 0.01$; vs. TNCB group). The serum levels of IL-4 were too low and not detectable in VAM1, VAM2, Hydrocortisone-pretreated groups and also the normal mice group (c).

rial used in this study are reported elsewhere.

The chemical allergen used in this study to induce atopic dermatitis-like skin lesions in NC/Nga mice was 2,4,6-trinitrochlorobenzene (Nacalai Tesque, Kyoto, Japan); it was used after recrystallization with ethanol. To sensitize mice, 150 μ l of 5% TNCB was applied epicutaneously on mice abdomens at 7 weeks of age as previously described.⁶ A week later (on day 8) after initial sensitization, the external areas of both right and left ears were applied once with 15 μ l of 1% TNCB solution, dissolved in acetone and olive oil mixture (4 : 1), then repeatedly once every three days from the following week to induce atopic dermatitis-like skin lesions as described in the experimental protocol (Supplementary Fig. 1 available at the online journal site). During TNCB challenge period, mice were usually anesthetized with diethyl ether by inhalation.

In the AD prophylactic protocol, just after being anesthetized, mice were then pretreated with respec-

tive treatments: VAM1, VAM2, hydrocortisone or buffer for TNCB and NORM groups. Thirty minutes later, 15 μ l of 1% TNCB was applied on mice ears so as to induce itch and AD-like skin lesions; whereas in the AD curative protocol all mice were first challenged to 15 μ l of 1% TNCB until they develop atopic dermatitis-like skin lesions (day 8 to day 20); thereafter, they were treated, from day 21 to 29, with VAM1, VAM2, hydrocortisone or buffer according to mice groups. For both the preventive and curative protocols, 20 μ l of each treatment (VAM1, VAM2, hydrocortisone, buffer) was applied epicutaneously on mice ears. Animals were always kept in separated cages throughout the experiment.

EAR THICKNESS MEASUREMENT AND SCRATCHING BEHAVIOR EPISODES COUNT

Ear thickness, which expresses the severity of inflammatory process and edema in mouse ear, was measured with the use of a digimatic (electronic) caliper

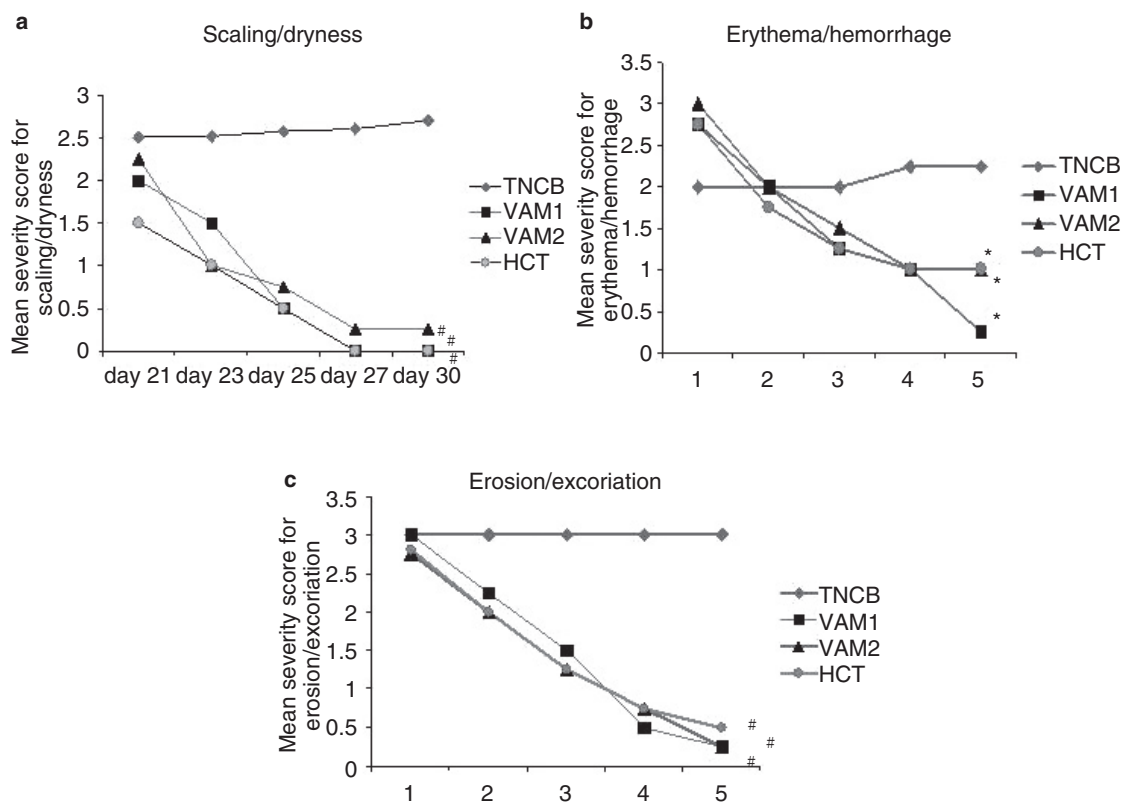


Fig. 5 Mean severity score for AD skin lesions in treated mice (AD curative protocol; $n = 30$; mean \pm SD). * p -value less than 0.05; # p -value less than 0.01 (vs. TNCB). VAM1, aqueous extract of *Vernonia amygdalina* leaf treated mice; VAM2, methanolic extract of *Vernonia amygdalina* leaf treated mice; HCT, hydrocortisone-treated mice; TNCB, 2,4,6-trinitrochlorobenzene (buffer-treated control group); NORM, buffer-treated normal control mice. The figure shows a significant reduction of the mean severity score for scaling/dryness ($p < 0.01$) (a), erythema/hemorrhage ($p < 0.05$) (b) and erosion/excoriation ($p < 0.01$) (c) in VAM1 and VAM2 mice groups after 10 days (5 applications) of treatment as compared to buffer-treated negative control (TNCB) mice. Similar trend was observed in hydrocortisone mice.

IP66 (Mitutoyo, Kawasaki, Japan). Scratching behavior were recorded using playback of videotaped images, taken with the use of digital video camera GR-DVL7 (Victor, Yokohama, Japan) and the number of scratching episodes that occurred within the first thirty minutes, following 1%TNCB challenge, was counted on days 8, 14 and 20 for each mouse in the prophylactic protocol, and on days 21, 23, 25, 27 and 29 in the curative protocol. They are expressed as mean \pm SD in the results section. Normal mice were exposed to buffer instead of TNCB.

HEMATOXYLIN AND EOSIN STAINING (HE STAIN) AND BIOLOGICAL MARKERS MEASUREMENT

On day 20 of the prophylactic protocol, skin biopsy specimen from left ears of mice (7 mm of longest dimension) were taken and samples were fixed in 10% formalin, embedded in paraffin, sectioned at 10 μ m and stained with hematoxylin and eosin (HE). To examine the specimens, light microscope BX60 from

Nikon, Tokyo, Japan, was used at $\times 100$ magnification. Blood samples were drawn after sacrificing mice with the use of diethyl ether by inhalation, for the measurement of serum levels of immunoglobulin E (IgE), Th-1 cytokines (TNF- α , IFN- γ) and Th-2 cytokines (IL-4, IL-5). In the curative protocol, serum levels of total IgE and CC-chemokines such as MIP-1 and eotaxin were measured. All those markers were assayed with the use of respective ELISA kits for mice and in accordance with the makers' instructions.

EVALUATION OF CLINICAL SEVERITY OF DERMATITIS

The severity of skin lesions was evaluated macroscopically using the following scoring procedure as previously described⁷ (0, no symptoms; 1, mild; 2, moderate; 3, severe) for each of the following symptoms and signs: dryness/scaling, erythema/hemorrhage, excoriation/erosion. Symptoms were recorded three times, using purposely prepared excel forms, on days 8, 14 and 20 in the prophylactic protocol, and

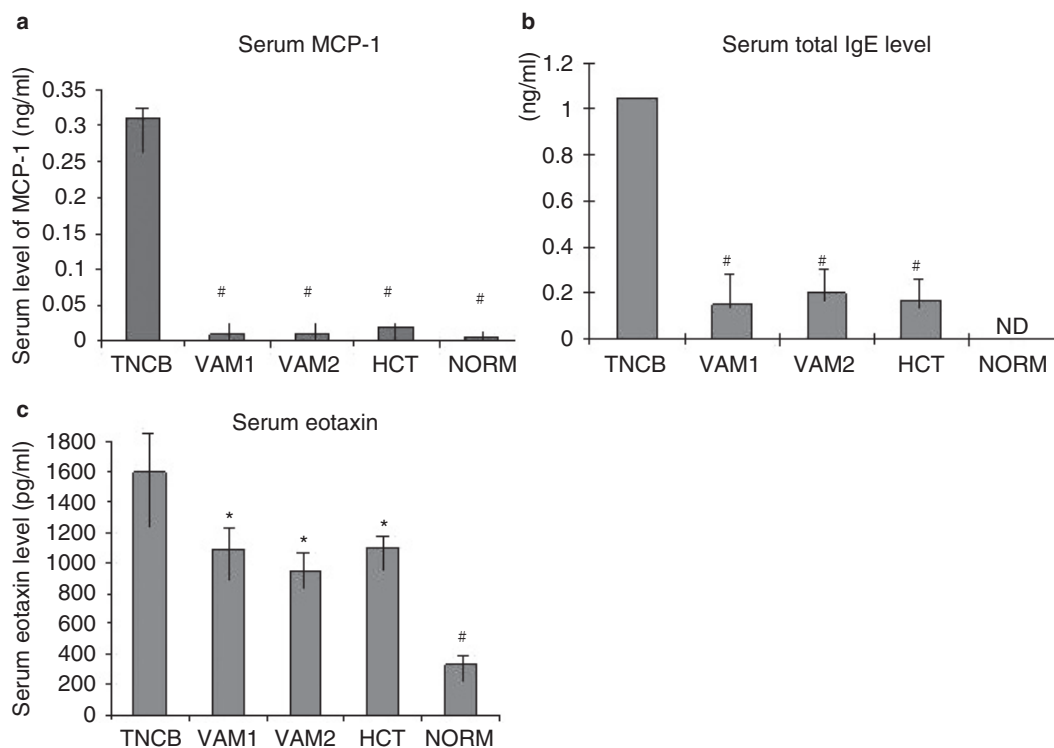


Fig. 6 Serum levels of total MCP-1 (a), eotaxin (b) and total IgE (c) in treatment and control mice (AD curative protocol; $n = 30$; mean \pm SD). * p -value less than 0.05; # p -value less than 0.01. ND, not detected; VAM1, aqueous extract of *Vernonia amygdalina* leaf treated group; VAM2, methanolic extract of *Vernonia amygdalina* leaf treated group; HCT, *hydrocortisone*; TNCB, 2,4,6-trinitrochlorobenzene (buffer-treated control group); NORM, buffer-treated normal mice. The figure shows significantly reduced levels of serum MCP-1 ($p < 0.001$), total IgE ($p < 0.001$) and eotaxin ($p < 0.05$) in VAM1, VAM2 and *hydrocortisone*-treated mice groups. The serum level of total IgE was too low and not detected in the normal mice.

on days 21, 24, 25, 27 and 29 in the curative protocol.

CASE OF ATOPIC/ECZEMA DERMATITIS IN A 17 YEARS OLD STUDENT TREATED WITH VAM

A 17-year-old albino boy with a chronic atopic/eczema dermatitis was consulted by our medical team during a dermatological screening and care project in the western province of Bas-Congo, Democratic Republic of Congo. He was one of the 523 school children and staffs presenting with skin disorders. In this report, we include a brief description of the patient skin condition and the outcome of VAM therapy.

STATISTICAL ANALYSIS

All data from different mice groups were expressed as mean \pm SD. Statistical differences in scratching behavior episodes, the severity of symptoms, serum levels of cytokines, chemokines and IgE were assessed by Dunnett test following one way analysis of variance. On the other hand, differences in ear thickness between mice groups [comparing values obtained after starting treatment to baseline values (day 8 for prophylactic protocol and day 21 for curative protocol)] using Fisher's exact test. P -values less than 0.05

were considered statistically significant. All analyses were performed using Stata software version 10 (StataCorp, Texas, USA).

RESULTS

VAM EXTRACTS PREVENT THE DEVELOPMENT OF ATOPIC DERMATITIS-LIKE DISEASE IN MICE Effect of Topical Administration of VAM Extracts on Scratching Behavior

The total number of videotaped scratching behavior episodes for each group was counted on day8, day14 and day20. Mice pretreated with VAM1, VAM2 and *hydrocortisone* showed significantly lower numbers of scratching behavior episodes on day 14 ($p < 0.05$) and day 20 ($p < 0.01$) of the prophylactic protocol as compared with TNCB group. Normal control mice that were not exposed to the hapten had markedly lower scratching episodes on days 14 and 20 ($p < 0.01$). In addition, VAM1 and VAM2 groups had lower numbers of scratching episodes as compared with *hydrocortisone*-pretreated mice, but not significantly ($p > 0.05$) (Fig. 1). Furthermore, no statistically significant difference was observed between VAM1, VAM2-pretreated mice groups ($p > 0.05$).

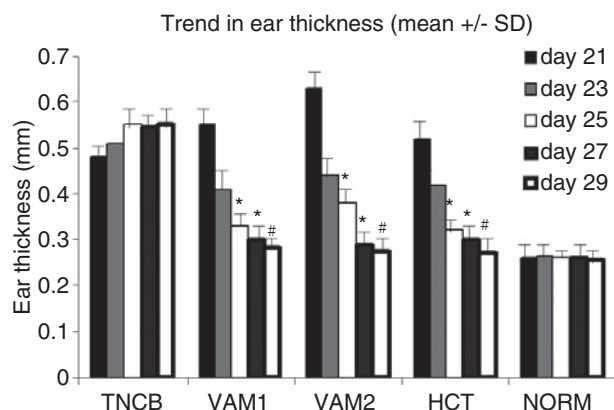


Fig. 7 Trend in ear thickness changes in treated mice from day 21 to day 29 of the experiment ($n = 30$; mean \pm SD). * p -value less than 0.05; # p -value less than 0.01. VAM1, aqueous extract of *Vernonia amygdalina* leaf treated mice; VAM2, alcoholic extract of *Vernonia amygdalina* leaf treated mice; HCT, hydrocortisone-treated mice; TNCB, 2,4,6-trinitrochlorobenzene (buffer-treated control group); NORM, buffer-treated normal control mice. The figure shows an inhibiting effect of hydrocortisone, the alcoholic and aqueous extracts of *Vernonia amygdalina* leaf on the increase in ear thickness that could result from repeated exposure to TNCB. A significantly reduced ear thickness was observed in VAM2, VAM1 and HCT-treated mice on day 25, day 27 ($p < 0.05$) and day 29 ($p < 0.01$) of treatment as compared with buffer-treated TNCB group. No significant difference was observed between treatment groups [VAM1, VAM2, HCT; ($p > 0.05$)].

Topical Application of VAM Extracts Inhibits the Development of AD Skin Lesions and Prevents the Increase in Ear Thickness in Mice Following Repeated Challenges to the Hapten

NC/Nga strain of mice has also been reported to develop atopic dermatitis-like skin lesions following repeated application of TNCB. In the preventive protocol of the study, TNCB-challenged mice developed AD-like lesions within the second week after initial sensitization, showing hypertrophy and hyperkeratosis of the epidermis. The severity of skin symptoms increased gradually during the experiment period in TNCB (control) mice. Conversely, no macroscopically visible skin lesions were observed in VAM1 and VAM2-pretreated mice during the second week post initial sensitization (vs. TNCB group; $p < 0.001$) (Table 1) and no significant difference was observed between VAM2-pretreated mice and the normal mice group ($p > 0.05$). VAM2 and HCT groups showed markedly lower severity score for all skin lesions throughout the experiment (prophylactic protocol); however, in regard to the severity of erythema/hemorrhage, the difference between VAM1 and TNCB groups was no statistically different ($p = 0.059$) at the

end of experiment.

Regarding the trend in ear thickness, after repeated challenge to the chemical allergen, VAM1, VAM2 and HCT significantly prevented the increase in ear thickness as compared with TNCB mice ($p < 0.05$), and no statistically significant difference was observed between VAM1 and VAM2 groups ($p > 0.05$) (Fig. 2).

Effect of Topical Administration of *V. amygdalina* Extracts on Serum Levels of Total IgE, TNF- α , IFN- γ , IL-4 and IL-5 in Mice

The serum titers of immunoglobulin E (IgE) were significantly lower in VAM1, VAM2, and hydrocortisone-pretreated groups as compared with TNCB group ($p < 0.01$) and no statistical difference was observed between VAM1, VAM2 and hydrocortisone-pretreated groups ($p > 0.05$) (Fig. 3).

On the other hand, the serum level of TNF- α was significantly lower in VAM1, VAM2 and HCT ($p < 0.05$) groups as compared with TNCB mice (Fig. 4a). In addition, the levels of IFN- γ and IL-5 were also markedly lower in VAM1, VAM2 and HCT groups ($p < 0.01$; vs. TNCB group) (Fig. 4b, c). However, the serum levels of IL-4 were too low and undetectable in VAM1, VAM2 and Hydrocortisone-pretreated groups

VAM EXTRACTS AMELIORATES ATOPIC DERMATITIS-LIKE DISEASE IN MICE VAM Extracts Improve Skin Lesions

After inducing AD-like skin lesions in all mice (curative protocol), they were treated the other day with VAM1, VAM2, hydrocortisone or buffer, according to treatment groups for a total five applications (10 days). Both VAM1 and VAM2, as well as hydrocortisone, markedly improved erythema/hemorrhage ($p < 0.05$), scaling/dryness and erosion/excoriation ($p < 0.01$) as compared with TNCB group (Fig. 5a, b, c). In addition, though VAM2 mice seemed to show a good and quick improvement, no statistically significant difference was observed when compared with hydrocortisone group, and also between VAM2 and VAM1 groups ($p > 0.05$).

VAM Extracts Reduce the Serum Levels of CC-Chemokines Eotaxin and MCP-1 and Total IgE

MCP-1 and eotaxin are CC-chemokines that play a role in the migration of monocytes and eosinophils to the inflammation site. In this study, treatment with VAM1, VAM2, as well as hydrocortisone, significantly reduced the serum levels of MCP-1 ($p < 0.01$), eotaxin ($p < 0.05$) and IgE ($p < 0.01$) (Fig. 6a, b, c). No statistically significant difference was noted in terms of serum levels of MCP-1, eotaxin and IgE between both VAM extracts, and also between VAM extracts and hydrocortisone-treated atopic mice ($p > 0.05$).

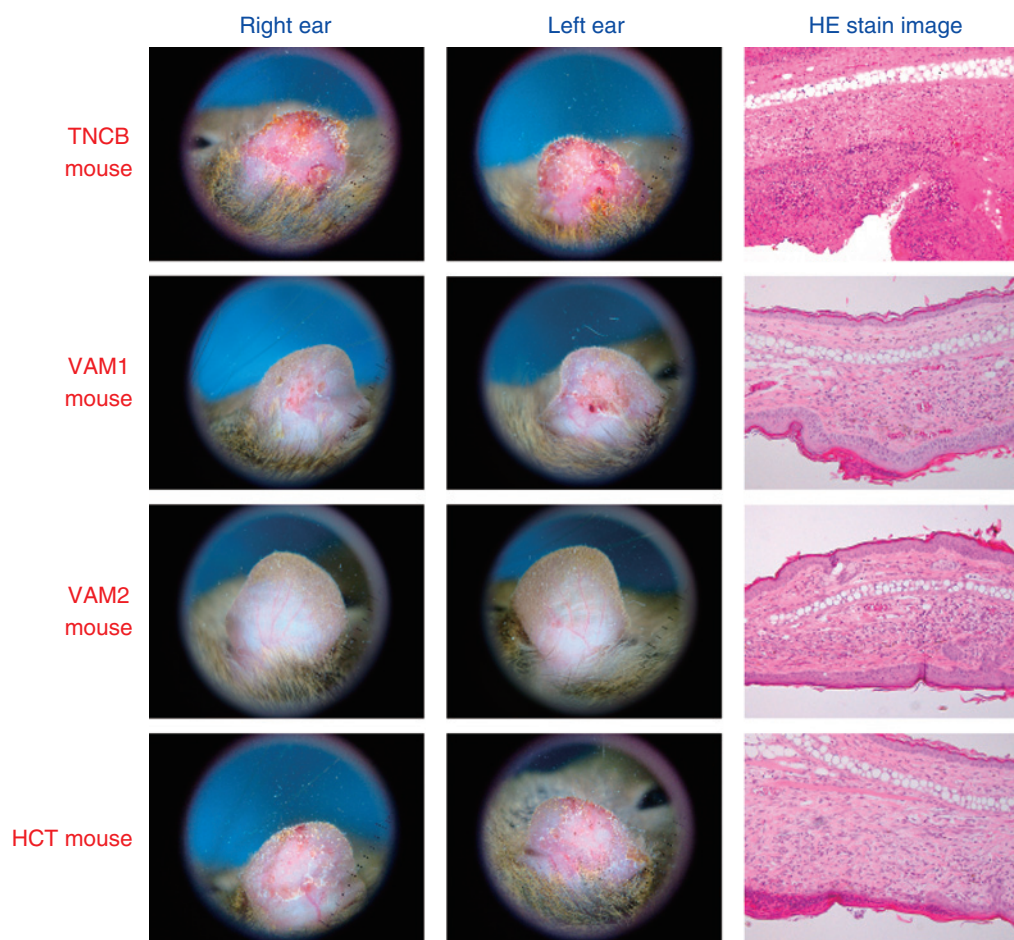


Fig. 8 Macroscopic ear skin lesions and histological features (HE stain) of auricular skin specimen ($\times 100$ magnification) of representative mice after 10 days of treatment (curative protocol; $n = 30$). HCT, hydrocortisone-treated group; VAM1, aqueous extracts of *Vernonia amygdalina* treated mice; VAM2, alcoholic extracts of *Vernonia amygdalina* treated mice; TNCB, buffer-treated control mice; NORM, buffer-treated normal mice. Noticeable severe skin lesions with hyperkeratosis and an intense inflammatory cells infiltration in ear skin specimens were observed in buffer-treated TNCB mouse, while those processes were markedly inhibited by VAM1, VAM2 and hydrocortisone treatment. In addition, a re-epithelization of the skin was obviously observable in VAM-treated mice ear specimen.

Trend in Ear Thickness Changes in Treated Mice from Day 21 to Day 29 of Experiment (Curative Protocol)

Exposure to the hapten (TNCB) induces the increase in the ear thickness in mice. We measured the ear thickness in mice from day 21 to day 29 of treatment. A marked decrease in ear thickness was observed in VAM2, VAM1 and HCT-treated mice on day 25, day 27 ($p < 0.05$) and day 29 ($p < 0.01$) of the experiment as compared with TNCB group. On the other hand, no significant difference was observed between VAM1, VAM2 and HCT groups ($p > 0.05$) (Fig. 7).

VAM Extracts Reduce Inflammatory Cells Infiltration to Mice Ears

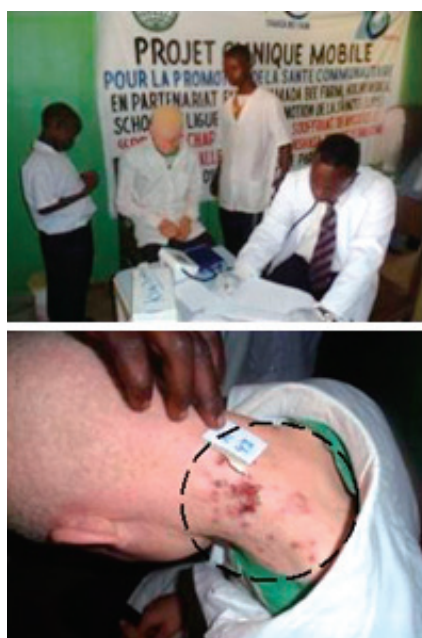The 10-day period of VAM and hydrocortisone treat-

ment markedly reduced inflammatory cells infiltration compared to buffer-treated TNCB mice (Fig. 8). While noticeable collagen deposition in the extracellular matrix, hemorrhagic zones and disruption of ear skin barrier were still present in buffer-treated TNCB mice at the end of the experiment, a marked improvement of these processes was observed in VAM1, VAM2 and hydrocortisone-treated mice.

Taken together, these changes suggest that VAM1, VAM2 and HCT treatments improved the hapten-induced ear skin allergic inflammation in mice.

Eczema dermatitis in a 17-year-old albino boy

Day 1



VAM 2



3 weeks later

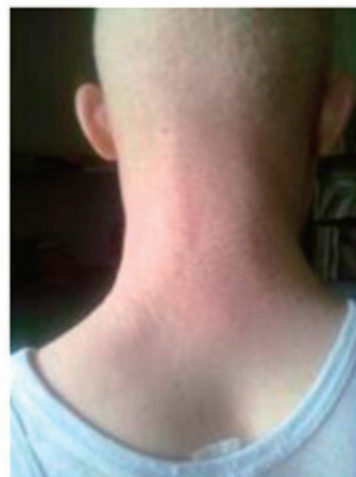

Fig. 9 Case of eczema dermatitis in a 17-year-old boy. EASI, eczema area and severity index. The figure shows marked improvement of scaling, edema, incrustation and erythematous lesions on day 21 of VAM treatment.

THE ALCOHOLIC EXTRACTS OF *VERNONIA AMYGDALINA* LEAF IMPROVE ECZEMA DERMATITIS SYNDROME IN A 17 YEARS OLD BOY

The patient has been suffering from eczema dermatitis for several months and taken care at a local medical center. He presented with itchy erythematous skin lesions and was treated with the use of topical zinc oxide ointment and some topical steroid preparations such as betamethasone dipropionate cream which was available at the medical center; however, his skin condition did not improve. In December 2010, the patient consulted our medical team and presented with severe itchy and erythematous skin with incrustation, edema, lichenification and scaling on neck and shoulder areas for an estimated eczema area and severity index (EASI) of 7.8 on day 1; scratch markings and lichenification were also noticeable. A written informed consent was obtained from the patient's mother, as for other patients taken care during a dermatological screening conducted in schools of the province of Bas-Congo, Democratic republic of Congo.

The treatment with VAM relieved itch completely within the second week and improved the severity of the disease (EASI = 0.7) on day 21, as shown on Figure 9. For more about a year since this treatment, the patient did not develop similar skin condition.

DISCUSSION

AD-like skin lesions in NC/Nga mice are similar to those of human atopic dermatitis, showing various grades of signs and symptoms such as erythema and hemorrhage, followed by edema, superficial erosion, deep excoriation and skin dryness. Although it occurs primarily in childhood, AD can persist or start in adulthood.¹⁴

In the prophylactic protocol of our study, after sensitization with 5% TNCB, AD-like disease was induced in mice using a repeated exposure to 1% TNCB on dorsal region of both left and right ears. Despite the repeated application the chemical allergen, VAM1 and VAM2 inhibited the development of AD skin lesions and on the increase of ear thickness. Both the aqueous and alcoholic extracts showed a relatively better effect regarding inhibition of itch than did hydrocortisone, as animals pretreated with those extracts showed significantly lower number of scratching behavior episodes than hydrocortisone-pretreated mice.

The serum level of total IgE, one of the markers of allergic inflammation, was significantly lower in *V. amygdalina* extracts pretreated mice. As for HCT, both VAM1 and VAM2 significantly inhibited the production of inflammatory markers such as Th2 cytokines, IL-4 and IL-5; and Th1 cytokines, IFN- γ and TNF- α in the prophylactic protocol of the study.

In the curative protocol, VAM1 and VAM2 markedly reduced the severity of skin lesions (scaling/dryness, erythema/hemorrhage, erosion/excoriation) in atopic mice. In addition, as for HCT, VAM1 and VAM2 also significantly decreased the serum levels of IL-4, IL-5 and CC-chemokines such as eotaxin and MIP-1, which seemed to reflect the histopathological features (reduction of inflammatory cells infiltration, skin barrier disruption) observed in VAM-treated mice.

Th2 cytokine IL-5 is believed to activate eotaxin, and this chemokine induces eosinophilic infiltration in allergic inflammation; on the other hand, eosinophilia is often accompanied by IgE overproduction.^{15,16} The inhibition of the release of eotaxin thanks to inhibition or reduction of IL-5 production on one side, and the inhibition and reduction of IgE production by VAM therapy that were observed in this study may explain the anti-inflammatory effects displayed by the extracts in VAM-treated mice. It has been previously reported that VAM extracts possess ERK pathway inhibitory activity^{12,13}; and that could justify the anti-allergic effect demonstrated in these animal experiments. This anti-allergic effect is mainly attributable to vernodalin, the most potent anti-inflammatory and antitumor terpenoid compound found in *vernonia amygdalina* leaf extract.¹⁷ Furthermore, the improvement of eczema dermatitis skin signs and symptoms observed in the case described in the results section of this manuscript, after VAM treatment, reflects that of the animal experiment.

In recent years, considerable attention has been focused on dietary and medicinal phytochemicals that inhibit, reverse or retard diseases caused by oxidative and inflammatory processes, anti-allergic foods ingredients have been attracting attention such as lactic bacteria and plant polyphenols.¹⁸⁻²² *Vernonia amygdalina* is grown in Africa and it has been reported its leaf extracts exert hepatoprotective and antioxidant activities in animals. The plant is used as a vegetable or drink mostly in western African countries and its leaf is rich in flavonoids and sesquiterpene lactones. Flavonoids and sesquiterpene lactones in the plant's leaf are believed to be responsible of the anti-inflammatory activity.^{23,24} Our very recent study in allergic patients has proven the safety of VAM extracts.²⁵ Further investigations to identify its major active components that display anti-allergic activity are being finalized. In our experiments, though the alcoholic extracts showed relatively better effects for a number of parameters evaluated, the difference between both extracts was in general not statistically different.

In conclusion, the present study is the very first that shows the beneficial effects of *Vernonia amygdalina* leaf extracts on skin disorders; it demonstrates both the prophylactic and curative effects of *Vernonia amygdalina* leaf extracts on atopic

dermatitis-like disease in mice. Our results suggest that VAM extracts, known as ERK pathway inhibitor, exert prophylactic and curative effects on AD possibly through this pathway inhibition and down regulation of IgE production.

ACKNOWLEDGEMENTS

The authors thank Dr. Dumavibhat Narongpon, Miss Takako Kusunose and Mrs. Mansongi Biyela Carine from the Department of Environmental Medicine, Kochi Medical School, for all their support during this study. This study was solely supported by the Department of Environmental Medicine, Kochi University Medical School.

SUPPLEMENTARY MATERIALS

Supplementary Figure 1 is available online.

REFERENCES

1. Kawakami Y, Yumoto K, Kawakami T. An improved mouse model of atopic dermatitis and suppression of skin lesions by an inhibitor of Tec family kinases. *Allergol Int* 2007;**56**:403-9.
2. Lee HS, Kim SK, Han JB *et al*. Inhibitory effects of *Rumex japonicus* Houtt on the development of atopic dermatitis-like skin lesions in NC/Nga mice. *Br J Dermatol* 2006; **155**:33-8.
3. Leung DY. Atopic dermatitis: new insights and opportunities for therapeutic intervention. *J Allergy Clin Immunol* 2000;**105**:860-76.
4. Werfel T, Morita A, Grewe M *et al*. Allergen specificity of skin-infiltrating T cells is not restricted to a type-2 cytokine pattern in chronic skin lesions of atopic dermatitis. *J Invest Dermatol* 1996;**107**:871-6.
5. Hokazono H, Omori T, Ono K. Effects of single and combined administration of fermented barley extract and gamma-aminobutyric acid on the development of atopic dermatitis in NC/Nga Mice. *Biosci Biotechnol Biochem* 2010;**74**:135-9.
6. Ohmura T, Tsunenari I, Hayashi T *et al*. Role of substance P in an NC/Nga mouse model of atopic dermatitis-like disease. *Int Arch Allergy Immunol* 2004;**133**:389-97.
7. Taniguchi Y, Kohno K, Inoue S *et al*. Oral administration of royal jelly inhibits the development of atopic dermatitis-like skin lesions in NC/Nga mouse. *Int Immunopharmacol* 2003;**3**:1313-24.
8. Akdis CA, Akdis M, Trautmann A, Blaser K. Immune regulation in atopic dermatitis. *Curr Opin Immunol* 2000; **12**:641.
9. Akdis M, Simon HU, Weigl L, Kreyden O, Blaser K, Akdis CA. Skin homing (cutaneous lymphocytes-associated antigen-positive) CD8+ T cells respond to superantigen and contribute to eosinophilia and IgE production in atopic dermatitis. *J Immunol* 1999;**163**:466-75.
10. Halbert AR, Weston WL, Morelli JG. Atopic dermatitis: is it an allergic disease? *J Am Acad Dermatol* 1995;**33**:1008-18.
11. Erasto P, Grierson DS, Afolayan AJ. Evaluation of antioxidant activity and the fatty acid profile of the leaves of *Vernonia amygdalina* growing in South Africa. *Food Chem* 2007;**104**:636-42.
12. Howard CB, Stevens J, Izevbigie EB, Walker A, McDaniel O. Time and dose dependent modulation of phase 1 and

- phase 2 gene expression in response to treatment of MCF-7 cells with a natural anti-cancer agent. *Cell Mol Biol* 2003;**49**:1057-65.
13. Oyugi DA, Luo X, Lee KS, Hill B, Izevbigie EB. Activity markers of the anti-breast carcinoma cell growth fractions of vernonia amygdalina extracts. *Exp Biol Med (Maywood)* 2009;**234**:410-7.
 14. Matsukura S, Aihara M, Hirasawa T, Ikezawa Z. Effects of TNCB sensitization in DS-Nh mice, Serving as a model of atopic dermatitis, in comparison with NC/Nga mice. *Int Arch Allergy Immunol* 2005;**136**:173-80.
 15. Yamamoto M, Haruna T, Yasui K *et al.* A novel atopic dermatitis model induced by topical application with dermatophagoides farinae extract in NC/Nga mice. *Allergol Int* 2007;**56**:139-48.
 16. Hamid Q, Boguniewicz M, Lueng DY. Differential in situ cytokine gene expression in acute versus chronic atopic dermatitis. *J Clin Invest* 1994;**94**:870-6.
 17. Kupchan SM. Recent advances in the chemistry of terpenoid tumor inhibitors. *Pure Appl Chem* 1970;**21**:227-46.
 18. Kalliomaki M, Salminen S, Arvilommi H, Kero P, Koskinen P, Isolauri E. Probiotics in primary prevention of atopic disease: a randomised placebo-controlled trial. *Lancet* 2001;**357**:1076-9.
 19. Leung DY, Bieber T. Atopic dermatitis. *Lancet* 2003;**361**:151-60.
 20. Rosenfeldt V, Benfeldt E, Nielsen SD *et al.* Effect of probiotic Lactobacillus strains in children with atopic dermatitis. *J Allergy Clin Immunol* 2003;**111**:389-95.
 21. Farombi EO, Owoeye O. Antioxidative and chemopreventive properties of Vernonia amygdalina and Garcinia biflavonoid. *Int J Environ Res Public Health* 2011;**8**:2533-55.
 22. Akazome Y. Characteristics and physiological functions of polyphenols from apples. *Biofactors* 2004;**22**:311-4.
 23. Adesanove OA, Farombi EO. Hepatoprotective effects of Vernonia amygdalina (asteraceae) in rats treated with carbon tetrachloride. *Exp Toxicol Pathol* 2010;**62**:197-206.
 24. Ijeh II, Ejike CECC. Current perspective on the medicinal potentials of Vernonia amygdalina Del. *Journal of Medicinal Plants Research* 2011;**5**:1051-61.
 25. Occupational Safety and Health Research Institute (OSHRI/Korea). *Proceedings of the International Symposium on Safety and Health at Work*. 2011;39.