

Available online at www.sciencedirect.com

ScienceDirect

journal homepage: www.jfma-online.com

CORRESPONDENCE

Treatment of bisphosphonate-related osteonecrosis of the jaw with platelet-rich fibrin

Lo-Lin Tsai ^a, Yu-Feng Huang ^{a,b}, Yu-Chao Chang ^{a,b,*}^a School of Dentistry, Chung Shan Medical University, Taichung, Taiwan^b Department of Dentistry, Chung Shan Medical University Hospital, Taichung, Taiwan

Received 15 September 2015; received in revised form 15 October 2015; accepted 16 October 2015

Bisphosphonate-related osteonecrosis of the jaw (BRONJ) is a well-known potential complication of bisphosphonate treatment. The clinical findings of BRONJ may vary in patients, including exposed necrotic bone, which can be accompanied by pain, swelling, paresthesia, pus discharge, and soft tissue ulceration. Currently, the management of BRONJ remains controversial, and there is no definitive treatment other than the standard protocol. Choukroun's platelet-rich fibrin (PRF) represents a relatively new biotechnology for the stimulation and acceleration of tissue healing and bone regeneration.¹ In this study, we report a BRONJ patient who was treated with surgical debridement, sequestrectomy, and simultaneous reconstruction using PRF as the sole grafting material.

A 79-year-old woman was referred in July 2011 by a local dental clinic for a painful jaw bone lesion. Her medical history included osteoporosis since 1996, which was treated weekly with alendronate (Fosamax, 70 mg, per os; Merck, Whitehouse Station, NJ, USA) for 10 more years, and intravenous zoledronic acid (Aclasta; Novartis Pharmaceuticals, Frimley, Camberley, UK) infusions annually, at a dose of 5 mg, from 2010 to 2011. The intraoral examination revealed a diffuse, tender, erythematous swelling over the edentulous area at the right posterior mandible with a purulent discharge

(Figure 1A). Panoramic tomography showed a sequestrum in the right posterior mandible (Figure 1B). According to the patient's clinical and radiological findings, the diagnosis was BRONJ stage 3. Medical therapy with ciprofloxacin (750 mg/d) and chlorhexidine mouthwashes were prescribed for 3 months. Then, the patient received surgical sequestrectomy and saucerization (Figure 1C) under general anesthesia with simultaneous reconstruction with PRF. PRF clots and membranes were prepared according to the Choukroun procedure.¹ PRF was packed into the surgical defect (Figure 1D). The overlying mucosa was sutured tension free with PRF membranes. After 10 days, postoperative healing was uneventful with no signs of infection or wound dehiscence (Figure 1E). Panoramic tomography showed new bone regeneration and no sign of necrotic bone after 10 months of follow-up (Figure 1E). The patient was still regularly followed up in our clinic. No new oral lesion was observed.

Recently, we reported that the use of PRF as sole filling material applied in simultaneous sinus lift and implantation demonstrated a new bone formation in the augmented areas.² In this case, the application of PRF for BRONJ also revealed total bone closure and new bone regeneration. The mechanism responsible for the osteoblasts by PRF may be explained as follows. Previously, PRF was found to be capable of increasing osteoblast attachment, growth, proliferation, and simultaneously upregulating osteoprotegerin and collagen-related protein production.^{3–5} These actions in combination may effectively promote bone regeneration. Taken together, PRF could be an easily prepared and effective material for the closure of BRONJ. The

Conflicts of interest: The authors have no conflicts of interest relevant to this article.

* Corresponding author. School of Dentistry, Chung Shan Medical University, 110, Section 1, Chien-Kuo N. Road, Taichung, Taiwan.

E-mail address: cyc@csmu.edu.tw (Y.-C. Chang).

<http://dx.doi.org/10.1016/j.jfma.2015.10.005>

0929-6646/Copyright © 2015, Formosan Medical Association. Published by Elsevier Taiwan LLC. This is an open access article under the CC BY-NC-ND license (<http://creativecommons.org/licenses/by-nc-nd/4.0/>).

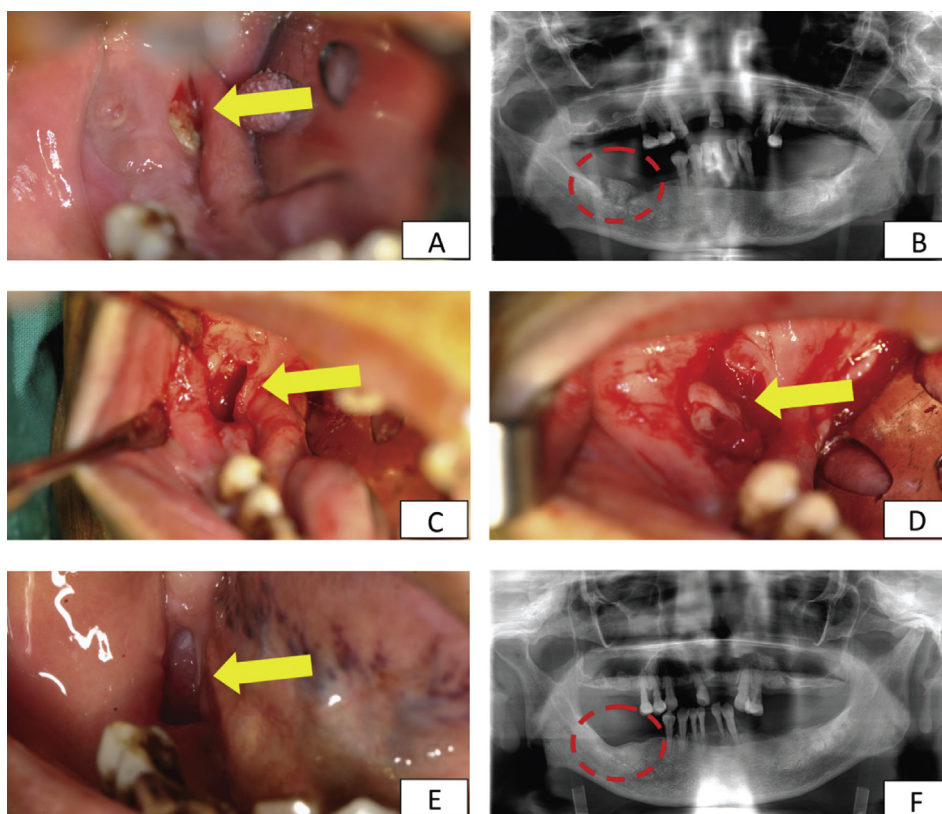


Figure 1 Clinical and radiographic photographs of the affected area. (A) Initial intraoral view showing the exposed necrotic bone and pronounced mucosal ulceration over the right posterior mandibular edentulous area caused by BRONJ. (B) Sequestration was obvious in the right posterior mandibular edentulous area shown on an initial panoramic tomographic scan. (C) The sequestrum was removed by surgical sequestrectomy and saucerization. (D) Clinical application of PRF as the sole grafting material in bony lesion. (E) Clinical photograph of the lesion with PRF coverage after 10 days. (F) Postoperative panoramic radiograph revealed dense bonelike tissues over the right posterior mandibular edentulous area 10 months after the surgery. BRONJ = bisphosphonate-related osteonecrosis of the jaw; PRF = platelet-rich fibrin.

application of PRF may be an alternative method to enhance bone healing for the treatment of BRONJ.

References

1. Choukroun J, Adda F, Schoeffler C, Vervelle A. PRF: an opportunity in perio-implantology (in French). *Implantodontie* 2000; 42:55–62.
2. Zhao JH, Tsai CH, Chang YC. Clinical application of platelet-rich fibrin as the sole grafting material in maxillary sinus augmentation. *J Formos Med Assoc* 2015;114:779–80.
3. Tsai CH, Shen SY, Zhao JH, Chang YC. Platelet-rich fibrin modulates cell proliferation of human periodontally related cells in vitro. *J Dent Sci* 2009;4:130–5.
4. Chang IC, Tsai CH, Chang YC. Platelet-rich fibrin modulates the expression of extracellular signal-regulated protein kinase and osteoprotegerin in human osteoblasts. *J Biomed Mater Res Part A* 2010;95:327–32.
5. Wu CL, Lee SS, Tsai CH, Lu KH, Zhao JH, Chang YC. Platelet-rich fibrin increases cell attachment, proliferation, and collagen-related proteins expression of human osteoblasts. *Aust Dent J* 2012;57:207–12.