




Available online at  
 ScienceDirect  
www.sciencedirect.com

Elsevier Masson France  
 EM|consulte  
www.em-consulte.com



ORIGINAL ARTICLE

# Four-strand hamstring tendon autograft for ACL reconstruction in patients aged 50 years or older

C. Trojani\*, J.-C. Sané, J.-S. Coste, P. Boileau

Department of orthopaedics and sports traumatology, L'Archet 2 University, Hospital of Nice, University of Nice-Sophia Antipolis, 151, route saint Antoine-de-Ginestière, 06200 Nice, France

Accepted: 20 May 2008

## KEYWORDS

ACL reconstruction;  
Hamstring tendon  
graft;  
Age

## Summary

**Introduction.** – Reconstruction of the anterior cruciate ligament using a four-strand hamstring tendon autograft in symptomatic patients aged 50 years or older is an accepted treatment option.

**Hypotesis.** – Four-strand hamstring tendon autograft although not universally utilized in patients who are at least 50 years old is an efficient procedure to control knee instability.

**Material and methods.** – In this retrospective, we analyzed the clinical outcomes of 18 patients treated from September 1998 to September 2003. Criteria for inclusion were the following: age above 50 years at surgery, chronic anterior laxity associated or not with meniscal damage; one or more episodes of knee instability and no prior ligament surgery on the involved knee. A same operative technique (arthroscopic single-bundle four-strand hamstring reconstruction, blind femoral tunnel, through anteromedial portals), a same fixation type (absorbable interference screws in femur and tibia) and a same rehabilitation protocol were used for all these knees. The IKDC 93 scores were determined pre- and postoperatively combined with anteroposterior and lateral views, single leg stance, 30° flexion stance, and passive Lachman test (Telos) postoperatively.

**Results.** – At mean 30 month-follow-up (range 12–59 months), there were no graft failure and no loss of extension for any of these knees. Three patients complained of hypoesthesia in the medial saphenous nerve territory and one patient experienced posterior knee pain. All patients graded their knee as normal or nearly normal, all were satisfied or very satisfied with their operation. None of the patients reported instability. The Lachman-Trillat test was noted “firm end point” in 14 knees and “delayed firm end point” in four. The pivot-shift test was negative in 16 knees and mild positive in two. The mean residual differential laxity was 3.1 mm (0 to +6 mm) for the passive Lachman test. At last follow-up, the overall IKDC score was 7 A, 7 B, 3 C, and 1 D. Patients with preserved meniscus (nine patients) reported a lesser degree of pain and a better residual laxity control compared with patients who had undergone a meniscectomy.

\* Corresponding author.

E-mail address: [chir-orthopedique@chu-nice.fr](mailto:chir-orthopedique@chu-nice.fr) (C. Trojani).

*Conclusion.* – Age over 50 years is not a contraindication to select a hamstring tendon autograft for ACL reconstruction. This surgery can restore knee stability but does not modify the pain pattern in patients, who had a medial meniscectomy prior to the ACL reconstruction.

Level of evidence: level IV, therapeutic study.

© 2009 Published by Elsevier Masson SAS.

## Introduction

Until the 1980s, anterior cruciate ligament (ACL) reconstructions aimed more specifically at young athletic patients [1]. However, in the face of the good results reported during the 1990s by various authors [2–4] after bone-patellar tendon-bone grafts (KJ) in patients over 40 years of age, such dogma has now become obsolete from the debate. To date, only one study has been published on autograft ACL reconstruction in patients aged over 50 years [5].

The use of gracilis tendon for ACL reconstruction was first described in 1939 [6] using a single-bundle graft and in 1983 with a double-bundle graft [7]. Combined semitendinosus and gracilis grafts (STG) in a single-bundle technique were first reported in 1986 [8] whereas double-bundle or single-bundle quadrupled graft reconstruction was described in 1988 [9].

The hypothesis of the present study is that the use of a single-bundle quadrupled hamstring tendon autograft in ACL reconstruction allows good control of knee instability in patients over 50 years of age. The purposes of the present study were [1] to evaluate the feasibility of hamstring tendon graft for ACL reconstruction in this specific age group [2] to perform measurements of millimetric residual knee laxity using the radiological passive comparative Lachman test and [3] to evaluate the role of the meniscus by comparing patients with prior meniscectomy to those having a preserved meniscus.

## Material and methods

### Patients

From September 1998 to September 2003, 18 patients aged over 50 years who presented a ruptured ACL, underwent ACL reconstruction with use of a single-bundle quadrupled STG tendon autograft in the orthopaedic surgery department of Nice University Hospital and were included in this retrospective study. Inclusion criteria were chronic anterior laxity associated or not with meniscal lesion and dating back more than six weeks, age at surgery over 50 years, no bone or ligament procedures associated with ACL reconstruction and no previous history of intra- or extra-articular ligament surgery in the involved knee. During the same period, 205 ACL reconstructions were performed in the same department. Prior to surgery, IKDC 93 functional scores were recorded [10] and anteroposterior and lateral single-leg-stance radiographs were analyzed. All patients, 12 females and six males, of average age 57 years (range 51–66) reported at least one prior episode of knee instability, either during sports (eight cases) or daily activities (10 cases). The ACL tear

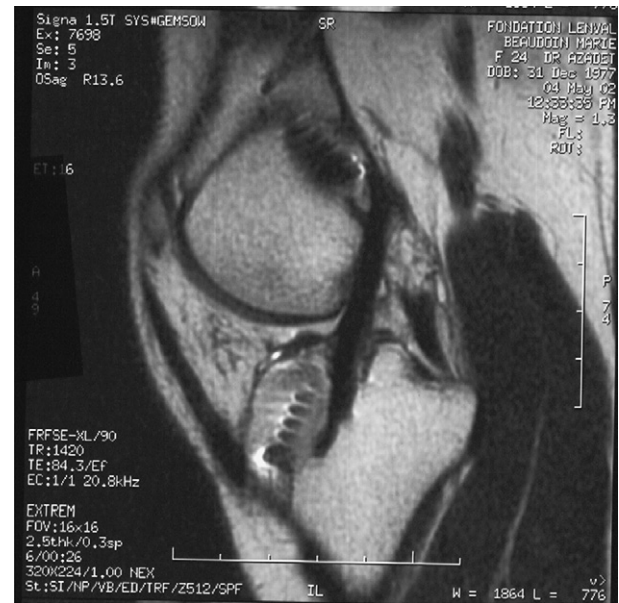was ski-related in nine cases and work-related in one. The mean time between injury and reconstruction was 11 months (range three months to six years). Four patients had previous history of medial meniscectomy performed three years, two years, 18 months and nine months before ACL reconstruction and complained of medial tibiofemoral pain preoperatively. The Lachman-Trillat testing revealed a “soft end point” and Pivot shift test was positive in all cases. No loss of flexion was observed whereas three patients experienced a loss of extension: a 5° loss in two of these and a 10° loss in the third one. Radiographic findings showed no evidence of tibiofemoral arthritis in 12 cases, a remodelling in four cases and a medial tibiofemoral pre-arthritis related to a partial medial tibiofemoral joint space narrowing in two cases. Two cases of remodelling and two cases of medial tibiofemoral pre-arthritis were found in patients who had undergone meniscectomy prior to ACL reconstruction. Preoperatively, the overall IKDC score was C in six patients and D in 12. Detailed IKDC outcome is shown in Table 1.

### Operative technique

All ligamentoplasties were performed arthroscopically using a blind femoral tunnel, positioning of the femoral tunnel being arthroscopically achieved through the antero-medial portal. Both the gracilis and semi-tendinosus tendons were harvested with an open tendon stripper via a 3–4 cm longitudinal incision placed 2 cm medial to the anterior tibial tubercle and 4–5 cm below the joint line. Each tendon was approximately 20–25 cm long. Both tendons were identified and harvested through their entire length in all cases. The semitendinosus and gracilis tendons were then folded over as to acquire a four-strand 10 cm graft. No tensioner was required. The four strands were then tied together in a single bundle graft with a 3 cm continuous running suture at both ends. The graft was next calibrated. A femoral and a tibial guide (Acufex Microsurgical Inc) were used for accurate tunnel placement. Tibial and femoral tunnels were drilled to the precise diameter of the graft. The femoral tunnel was drilled first and placed at the 10 o'clock position in the right knee and 2 o'clock position in the left knee, positioned 5 mm anteriorly using the femoral guide. The tibial tunnel was positioned at the bottom of the posterior cruciate ligament slightly shift towards the medial femoral condyle, tilted 50° using the tibial guide, and oriented from inside to outside at approximately 20°. The graft was pulled through the tibial and femoral bone tunnels with a suture thread. Femoral and tibial graft fixations were performed with Physis (Tornier Inc) bioabsorbable interference screws in all cases (Fig. 1). The graft was fixed to the femur with the knee in full flexion and to the tibia at 20° of knee flexion after optimum manual tensioning was applied

**Table 1** Pre- and postoperative IKDC scores in 18 patients of the series.

Preoperative IKDC	Mobility		Laxity		Radiography		Global	
	Preoperative	Postoperative	Preoperative	Postoperative	Preoperative	Postoperative	Preoperative	Postoperative
A	15	15	0	14	12	10	0	7
B	2	3	2	4	4	4	0	7
C	1	0	4	0	2	3	6	3
D	0	0	12	0	0	1	12	1
Number of patients	18	18	18	18	18	18	18	18



**Figure 1** Oblique sagittal MRI. ACL reconstruction with hamstring tendon graft using interference screws for femoral and tibial fixation.

without cycling loading strength tests. No notch plasty was needed.

The mean graft diameter was 7.1 (range 6.5 to 8.5) in the femur and 7.5 (range 7–8.5) in the tibia. Both tunnel diameters were identically sized. On the femoral side, interference screw diameter was 9 mm in 15 patients, 8 mm in two and 7 mm in one. Tibial fixation was achieved with a 9 mm interference screw in 17 patients and a 7 mm screw in one patient. Three medial and two lateral meniscectomies were performed during ACL reconstruction. No preoperative “cyclops syndrome” was observed during ligamentoplasty [11].

### Rehabilitation protocol

An accelerated rehabilitation protocol was implemented in all patients [12] and included full passive ROM restoration (including recurvatum) within the first six postoperative weeks, full early weight bearing without splint and closed kinetic chain exercises involving quadriceps and hamstring co-contraction exercises. At eight weeks, patients could return to specific sport activities such as running on level ground, swimming with leg movements and biking. Leisure or competitive pivot/contact sports were allowed at six months postoperatively.

### Evaluation method

The IKDC 93 form was postoperatively used for assessment of knee function, symptoms, mobility and for ligament clinical and radiographic evaluation. Residual ligament laxity was radiographically measured with comparative lateral views, using the passive Lachman test with the Telos measurement device at 150 Newtons (N). Morbidity of the transplant was assessed for potential knee hypoesthesia, anterior and posterior knee pain, pain in the kneeling position or inability

**Table 2** Last follow-up data from 18 patients over 50 years of age who underwent ACL reconstruction using a single-bundle quadruple-hamstring tendon graft.

Patient	Age (year)	Gender	Meniscus	Follow-up (month)	IKDC	Lachman	Pivot shift	Telos (mm)
1	59	F		59	A	FEP	Negative	0
2	52	F		48	B	FEP	Negative	5
3	58	F	MM per op	44	B	FEP	Negative	2
4	55	F		40	A	FEP	Negative	2
5	51	F	MM pre-op	38	C	FEP	Negative	4
6	51	F		35	B	FEP	Negative	1
7	55	F	MM pre-op	30	D	FEP	Mild positive	6
8	53	F		30	B	DF	Negative	4
9	64	M	MM per-op	28	A	FEP	Negative	4
10	66	M	ML per-op	28	A	FEP	Negative	3
11	61	M	MM pre-op	25	C	DF	Mild positive	5
12	51	F		24	A	FEP	Negative	3
13	53	F		21	B	FEP	Negative	0
14	52	F	MM per-op	20	A	FEP	Negative	3
15	64	M	MM pre-op	20	C	DF	Negative	5
16	61	M		18	A	FEP	Negative	2
17	58	F	ML per-op	18	B	FEP	Negative	4
18	65	M		12	B	FEP	Negative	3

ACL graft; FEP: firm end point; DF: delayed firm end point; MM pre-op: medial meniscectomy prior to ACL graft; MM or ML per-op: meniscectomy during; F: female; M: male.

to kneel. AP and lateral single-leg-stance radiographs combined with 30° flexion views in two-leg-stance were used for detection of tibiofemoral arthritis.

## Results

All patients were reviewed at a median 31 month-follow-up (range 12–59). The results of the series are available in [Table 2](#).

## Failures – Complications

No recurrent instability was reported, no graft failure was diagnosed. No patient was either reoperated on the ipsilateral knee or developed infection or postoperative “cyclope syndrome”.

## Morbidity

At last follow-up, hypoesthesia of the medial saphenous nerve territory was experienced in three patients while one patient complained of posterior knee pain. None of the patients reported either anterior knee pain or pain in the kneeling position. All patients were able to kneel down on the operated knee.

## IKDC evaluation

All patients were satisfied or very satisfied following surgery. None of them experienced instability. The IKDC functional scores at last follow-up are shown in [Table 1](#). The overall IKDC score was A in seven patients, B in seven, C in three

and D in one. All patients rated their knee as normal or nearly normal. The Lachman-Trillat test revealed a “firm end point” in 14 cases (78%) and a “delayed firm end” point in four cases. The pivot-shift test was negative in 16 cases (88%) and mild positive in two. Ten of the patients were free of pain. Full symmetrical knee movement was achieved in 15 cases whereas a 5° flexion deficit in comparison with the contralateral side was found in three patients. However, none of the patients experienced loss of extension. The three patients with IKDC C and the one with IKDC D had undergone preoperative meniscectomy and had reported painful tibiofemoral joint. ACL injury was work-related in one of them.

## Radiographic laximetry

Lateral comparative passive Lachman radiographs were performed in all patients. Radiographically, mean postoperative differential laxity was 3.1 mm (range 0 to +6). The nine meniscectomized patients reported a higher residual differential laxity than those with preserved meniscus ([Table 1](#)). However, no statistical analysis was conducted due to the small size of the sample.

## Tibio-femoral pain

At last follow-up, the four patients with preoperative medial meniscectomy still experienced tibio-femoral pain whereas the five patients in whom partial, medial or lateral meniscectomy had been carried out at the time of the ACL reconstruction, did not complain of joint line pain. None of the patients with preserved meniscus reported tibiofemoral joint line pain ([Table 3](#)).

**Table 3** The role of the meniscus in laxity, stability and pain control.

	Meniscectomy (n = 9)	Preserved meniscus (n = 9)
Residual differential (mm)	4	2.5
Laxity (Telos 150 N)		
Pivot-shift test +	2 out of 9	0 out of 9
Pain	4	0

## Radiographic findings

Postoperative evaluation of AP and lateral single-leg-stance radiographs combined with 30° of knee flexion views demonstrated 10 knees free of medial tibiofemoral arthritis, four remodellings, three medial tibiofemoral pre-arthritis and one tibiofemoral arthritis. This radiographic assessment brought out an arthritic evolution.

## Radiographic and meniscal outcome

Among the four meniscectomized patients prior to ACL reconstruction, two cases of remodelling and two cases of medial tibiofemoral pre-arthritis were found. None of the five meniscectomized patients during ACL surgery did report either remodelling or medial tibiofemoral pre-arthritis at the last follow-up.

## Discussion

There is, as far as we know, no similar study reporting the results of a hamstring autograft ACL reconstruction in patients over 50 years. The present study is monocenter and was performed in a homogeneous patient population as regards the age of patients, the choice of graft and two other parameters: the graft fixation system and patients' rehabilitation protocol. Other studies involving that age group were published but did concern on the one hand 31 patients with torn ACL, reconstructed with bone-tendon-bone (BTB) graft in 26 and STG graft in five [5] and 29 BTB grafts and four STG grafts on the other hand [13]. Our results are somewhat surprisingly good, however, they appear to clearly corroborate the literature data. They confirm those previously reported for BTB grafts in patients over 40 years [2–4] and over 50 years in a series of combined grafts (STG and BTB) [5]. Typically, older people are less active and put less strain on their knees than do younger people, which might explain our good results. Therefore, this bears out the fact that results of ACL grafting are not age-dependent [14,15]. In patients over 50 years, indication for ACL reconstruction was motivated by a soft end point Lachman-Trillat test combined with a positive pivot-shift test and one or more episodes of instability. The same surgical technique was used for all patients. Both gracilis and semi-tendinosus tendons were entirely harvested, greater or equal to 20 cm in all cases and tied together in a single-bundle quadrupled graft of mean diameter 7.1 mm in the femur and 7.5 mm in the tibia. Neither pre-tensioning nor cyclic preconditioning were performed prior to graft suture in order to achieve the same tear resistance pattern as patellar tendon [16,17]. Our chosen femoral and tibial graft fixation technique was bioab-

sorbable interference screws. The type of graft fixation seems to have significant effect on knee stability after ACL reconstruction [18]. Extra-anatomic models demonstrate a higher mechanical strength [19–21], however bioabsorbable interference screws are sufficiently resistant and should be preferred to metal interference screws in hamstring grafts [22,23]. This fixation technique is in line with the overall coherence of tunnel-tendon-screw. Graft and tunnel diameter are identical, both on the femoral and tibial side, however, the interference screw diameter is larger than the graft and tunnel diameter. Neither femoral nor tibial double fixation was used and we advocate the use of larger diameter interference screws to help compensate for osteopenic bones. Our patients were also suggested an accelerated rehabilitation protocol [12] which was respected throughout the series and did not prove deleterious as neither graft failure nor revision was observed. Whatever the fixation system, graft healing in bone tunnels takes a longer time when using hamstring tendons [24–27] but this does not contraindicate an accelerated rehabilitation protocol [28]. Pre- and postoperative mobilities were similar. No *genu flexum* was observed in our series at last follow-up. Accelerated rehabilitation provides good preservation of knee ROM [29] and undermines the suggestion that ACL reconstruction in elderly patients could induce stiffness of the knee joint. In the face of these results, single-bundle ACL reconstruction using quadrupled STG graft, combined with bioabsorbable interference screw fixation and accelerated rehabilitation protocol is a suitable method in patients over 50 years of age. What about knee laxity and instability control?

In our series, mean residual differential laxity was 3.1 mm. None of the patients experienced knee instability whatever their activities, pivot-shift test was negative in 16 patients (88%) and mild positive in two. Such results are similar to those previously reported for BTB grafts in this age group [5,13] and in patients aged over 40 years [2–4]. Our overall results, with regard to laxity and instability control, corroborate those reported in the literature and confirm the hypothesis that hamstring ACL reconstruction is suitable technique in people over 50 years of age. However, analysis and interpretation should be conducted cautiously due to the rather small size of the sample.

Finally, patients with previous meniscectomy report less encouraging results, in particular two of them having a positive pivot-shift test (mild positive) and four of them experiencing medial tibiofemoral pain. Preoperative pain does not decrease after surgery. Moreover, patients in whom meniscectomy was performed prior to ACL reconstruction, show an arthritic evolution. Here again, such results should be considered cautiously due to the methodological weaknesses of our study. It is a level 4 study, with small sample size and limited duration of follow-up.

To conclude, our series clearly demonstrate that people over 50 years of age do not constitute a contraindication for ACL reconstruction when using the semitendinosus and gracilis tendons. All our patients had preoperative knee instability with a "soft end point" Lachman-Trillat test and a positive pivot-shift test. Within the framework of this specific study, control of laxity revealed satisfactory with a mean 3.1 mm residual differential laxity. This surgery thus guarantees full restoration of knee stability although it does not modify the pain pattern in patients who had medial meniscectomy prior to ACL plasty.

## References

- [1] Dejour H, Walch G, Neyret P, Adeleine P. Résultats des laxités antérieures chroniques opérées : à propos de 251 cas revus avec un minimum de trois ans de recul. *Rev Chir Orthop* 1988;74:622–36.
- [2] Dejour D, Greco M, Neyret P, Dejour H. La greffe du LCA chez les patients âgés de plus de 40 ans. *J Traum Sports* 1997;14:223–6.
- [3] Plancher KD, Steadman JR, Briggs KK, Hutton KS. Reconstruction of the anterior cruciate ligament in patients who are at least 40 years old. *J Bone Joint Surg* 1998;80A:184–97.
- [4] Texier A, Hulet C, Acquitter Y, Tallier E, Jambou S, Locker B, Vielpeau C. Reconstruction du LCA après 40 ans. *Rev Chir Orthop* 2002;88:149–56.
- [5] Blyth MJ, Gosal HS, Peak WM, Bartlett RJ. Anterior cruciate ligament reconstruction in patients over the age of 50: 2 to 8 years follow-up. *Knee Surg Sports Traumatol Arthrosc* 2003;11:204–11.
- [6] Macey HB. A new operative procedure for repair of a ruptured cruciate ligaments of the knee joint. *Surg Gynecol Obstet* 1939;69:108–9.
- [7] Mott HW. Semitendinosus anatomic reconstruction for cruciate ligaments insufficiency. *Clin Orthop* 1983;172:90–2.
- [8] Moyer RA, Belz RR, Marchello PA. Arthroscopic anterior cruciate reconstruction using the semitendinosus and gracilis tendons: a preliminary report. *Contemp Orthop* 1986;12:17–23.
- [9] Friedman MJ. Arthroscopic semitendinosus (gracilis) reconstruction for anterior cruciate ligament deficiency. *Tech Orthop* 1988;2:74–80.
- [10] Hefti F, Muller W, Jakob RP, Staubli HU. Evaluation of the knees ligament injuries with the IKDC form. *Knee Surg Sports Traumatol Arthrosc* 1993;1:226–34.
- [11] Trojani Ch, Coste JS, Michiels JF, Boileau P. Le cyclope : un problème pré-existant à la greffe du LCA? *J Traumatol Sport* 2003;20:76–82.
- [12] Boileau P, Rémi M, Lemaire M, Rousseau P, Desnuelle C, Argenson C. Plaidoyer pour une rééducation accélérée après ligamentoplastie du genou par un transplant os-tendon rotulien-os. *Rev Chir Orthop* 1999;85:475–90.
- [13] Jarry A., Burdin G., Galaud B., Hulet C., Locker B., Vielpeau C. Reconstruction du ligament croisé antérieur après 50 ans : à propos de 33 cas. *Locker. Rev Chir Orthop* 2004;90:3594.
- [14] Barber FA, Elrod BF, Mc Guire DA, Paulos LE. Is an anterior cruciate ligament reconstruction outcome age dependent? *Arthroscopy* 1996;12:720–5.
- [15] Brandsson S, Kartus J, Larsson, Eriksson BI, Kaarlsson J. A comparison of results in middle aged and young patients after anterior cruciate ligament reconstruction. *Arthroscopy* 2000;16:178–82.
- [16] Schatzmann L, Brunner P, Staubli HU. Effect of cyclic preconditioning on the tensile properties of human quadriceps tendons and patellar ligament. *Knee Surg Sports Traumatol* 1998;6:556–61.
- [17] Wilson TW, Zafuta MP, Zobitz M. A biomechanical analysis of matched bone-patellar tendon-bone and double-looped semitendinosus and gracilis tendon grafts. *Am J Sports Med* 1999;27:202–7.
- [18] Ishibashi Y, Rudy T, Livesay G, Stone J, Fu F, Woo S. The effect of anterior cruciate graft fixation site on the knee stability. *Arthroscopy* 1997;13:177–83.
- [19] Howell SM. Autogenous graft choices in ACL reconstruction. *Curr Opin Orthop* 2001;12:149–55.
- [20] Kousa P, Järvinen T, Vihavainen M, Kannus P, Järvinen N. The fixation strength of six hamstring tendon graft fixation devices in anterior cruciate ligament reconstruction. Part 1: femoral site. *Am J Sports Med* 2003;31:174–81.
- [21] Kousa P, Järvinen T, Vihavainen M, Kannus P, Järvinen N. The fixation strength of six hamstring tendon graft fixation devices in anterior cruciate ligament reconstruction. Part 2: tibial site. *Am J Sports Med* 2003;31:182–8.
- [22] Aune AK, Cawley Ekelan A. Interference screw fixation of hamstring versus patellar tendon grafts for anterior cruciate ligament reconstruction. *Knee Surg Sports Traumatol Arthrosc* 1998;6:99–102.
- [23] Caborn DN, Coen M, Neef R, Hamilton D, Nyland J, Johnson DL. Quadrupled semitendinosus-gracilis autograft fixation in the femoral tunnel: a comparison between metal and bioabsorbable interference screw. *Arthroscopy* 1998;14:241–5.
- [24] Jansson K, Harilainen A, Sandelin J, Karjalainen PT, Aaronen HJ, Tallroth K. Bone tunnel enlargement after anterior cruciate reconstruction with the hamstring autograft and endobutton fixation technique. *Knee Surg Sports Traumatol Arthrosc* 1999;7:290–5.
- [25] Peyrache MD, Djian P, Christel P, Witvoet J. Tibial tunnel enlargement after anterior cruciate reconstruction by autogenous bone-patellar tendon-bone. *Knee Surg Sports Traumatol Arthrosc* 1996;4:2–8.
- [26] Pinczewski LA, Clingefeller AJ, Otto DD, Bonar SF, Corry IS. Integration of hamstring tendon with bone in reconstruction of the anterior cruciate ligament. *Arthroscopy* 1997;13:641–3.
- [27] Robert H, Es-Sayeh J. Étude histologique de l'ancrage des tendons ischio-jambiers dans les tunnels osseux des plasties du LCA. *Ann Orthop Ouest* 2001;33:57–62.
- [28] Howell SM, Taylor MA. Brace-free rehabilitation, with early return to activity, for knees reconstructed with a double-looped semitendinosus and gracilis graft. *J Bone Joint Surg* 1996;78A:814–25.
- [29] Shelbourne KD, Nitz P. Accelerated rehabilitation after anterior cruciate ligament reconstruction. *Am J Sports Med* 1990;18:292–9.