

Flecainide-induced incessant orthodromic atrioventricular reentrant tachycardia in Wolff-Parkinson-White syndrome: Uneven depression of accessory pathway conduction

Oscar A. Pellizzón, MD, PhD,* Manlio F. Márquez, MD,[†] Mario D. González, MD,[‡] Sebastián Nannini, MD,* Rodolfo Leiva, MD,* Antonia Catalano, MD,* Pedro Iturralde, MD[†]

From the *Centro de Arritmias Cardíacas, Hospital Universitario del Centenario, Rosario, Argentina, [†]Instituto Nacional de Cardiología Ignacio Chávez, Mexico City, Mexico, and [‡]Clinical Electrophysiology, Penn State Heart and Vascular Institute, Milton S. Hershey Medical Center, Penn State University, Hershey, Pennsylvania.

Introduction

During orthodromic atrioventricular reentrant tachycardia (AVRT), ventricles are activated anterogradely through the atrioventricular node and retrogradely through an accessory pathway (AP). Antiarrhythmic drugs are initially used to prevent recurrences^{1,2} of AVRT, whereas catheter ablation is frequently performed as a definitive treatment.³ Occasionally, catheter ablation can be “proarrhythmic” if the AP is partially damaged but not completely eliminated.⁴ A similar proarrhythmic effect has not been described with antiarrhythmic drugs in patients with an AP. In fact, the literature only describes the proarrhythmic effect of flecainide causing atrial flutter or ventricular tachycardia,^{5,6} but not the development of incessant supraventricular tachycardia in subjects with an AP. In the present report we describe a patient with Wolff-Parkinson-White syndrome due to a right paraseptal AP in whom the administration of flecainide resulted in an incessant form of AVRT resembling the permanent form of junctional reciprocating tachycardia.

Case report

A 16-year-old male subject with a structurally normal heart and a manifest right-sided AP consistent with a paraseptal location⁵ (Figure 1A) presented with recurrent palpitations. A supraventricular tachycardia was documented with a cycle length of 220 msec (Figure 2A). Initial treatment with beta blocker was ineffective in preventing recurrence of the

tachycardia. He was then started on flecainide (50 mg every 12 hours). One week later, he had no recurrence of tachycardia and the electrocardiogram showed disappearance of ventricular preexcitation (Figure 1B). By performing carotid sinus massage and asking the patient to exercise, long and short sinus cycle lengths were obtained and confirmed that antegrade block over the AP was present over a wide range of sinus cycle lengths. Unexpectedly, 1 month after initiation of flecainide, he developed an incessant supraventricular tachycardia. When compared with the tachycardia observed before flecainide administration, under the drug the cycle length had now increased, from 220 to 320 msec, and the RP interval had increased from 80 to 120 msec (Figure 2B). Clear retrograde P waves were observed in inferior leads. Administration of repeated doses of adenosine (6–12–24 mg) only terminated the tachycardia transiently, with rapid reinitiation of the arrhythmia in the absence of atrial or ventricular premature beats (Figure 2C). In fact, a slight shortening of the PP interval was enough to reinitiate that tachycardia without a premature atrial or ventricular beat, resembling the permanent form of junctional reciprocating tachycardia. The supraventricular tachycardia was eventually terminated with intravenous amiodarone administration. The patient subsequently underwent an electrophysiology study after all antiarrhythmic drugs had been discontinued (Figure 3), which confirmed the presence of a single AP with earliest ventricular activation recorded close to the anterior edge of the coronary sinus ostium. Orthodromic AVRT utilizing the AP as the retrograde limb was induced. Delivery of radiofrequency energy at this site eliminated AP conduction and the tachycardia could not be reinduced.

KEYWORDS Supraventricular tachycardia; Wolff-Parkinson-White syndrome; Flecainide; Incessant orthodromic AV reentrant tachycardia; Proarrhythmia (Heart Rhythm Case Reports 2016;2:506–510)

Address reprint requests and correspondence: Dr Oscar A. Pellizzón, Centro de Arritmias Cardíacas, Hospital Universitario del Centenario, Pasco 1315 2° A. Rosario (2000), Santa Fe, Argentina. E-mail address: opeli@fibertel.com.ar.

Discussion

In the present case, adenosine was initially successful in interrupting AVRT. However, once the electrophysiological

KEY TEACHING POINTS

- Flecainide administration in a patient with Wolff-Parkinson-White syndrome and atrioventricular reentrant tachycardia resulted in suppression of antegrade conduction over the accessory pathway with slowing of retrograde conduction, creating the conditions for an incessant orthodromic atrioventricular reentrant tachycardia.
- The present case illustrates the differential suppressive effect of antiarrhythmic agents over antegrade vs retrograde conduction of accessory pathways.
- This was a proarrhythmic effect of flecainide associated with development of incessant supraventricular tachycardia.

properties of the AP were modified by flecainide, the patient developed an incessant tachycardia resembling the permanent form of junctional reentrant tachycardia,⁷ which is secondary to an AP that only conducts retrogradely with slow conduction, providing the conditions of a stable reentry. One unique characteristic of the permanent form of junctional reentrant tachycardia is that upon occasional termination, the arrhythmia is rapidly reinitiated after a slight shortening of the sinus cycle length, in the absence of atrial or premature beats. This distinctive behavior was observed in

the present case during flecainide administration, once the drug had eliminated antegrade conduction over the accessory A-V pathway and slowed, without abolishing, retrograde AP conduction, creating the conditions for an incessant tachycardia.

Our findings of preferential loss of antegrade conduction over the AP, with prolongation of the V-A interval during tachycardia, are consistent with the findings of Neuss et al.⁸ These investigators showed that flecainide abolished antegrade conduction over the AP in 7 out of 12 patients. In contrast, retrograde conduction was eliminated in only 1 patient. In the present case, flecainide abolished antegrade conduction over the AP. The longer RP during tachycardia suggests that this drug slowed retrograde conduction, resulting in an incessant AVRT. However, because the electrophysiology study was performed after all antiarrhythmic drugs were discontinued, we cannot entirely rule out an alternative mechanism. Although previous cases of incessant AVRT had been reported in the literature, they are not related to flecainide or other class Ic antiarrhythmic agents as in the case herein presented. Littmann and Saxonhouse reported a case of incessant AVRT induced by the administration of metoprolol and diltiazem in a patient with a concealed left-sided AP.⁹ In that case, these drugs slowed antegrade conduction over the AV node, facilitating retrograde conduction over the AP. In contrast, in the case now presented, flecainide blocked antegrade conduction while only slowing retrograde conduction over the AP, creating the conditions for an incessant tachycardia.

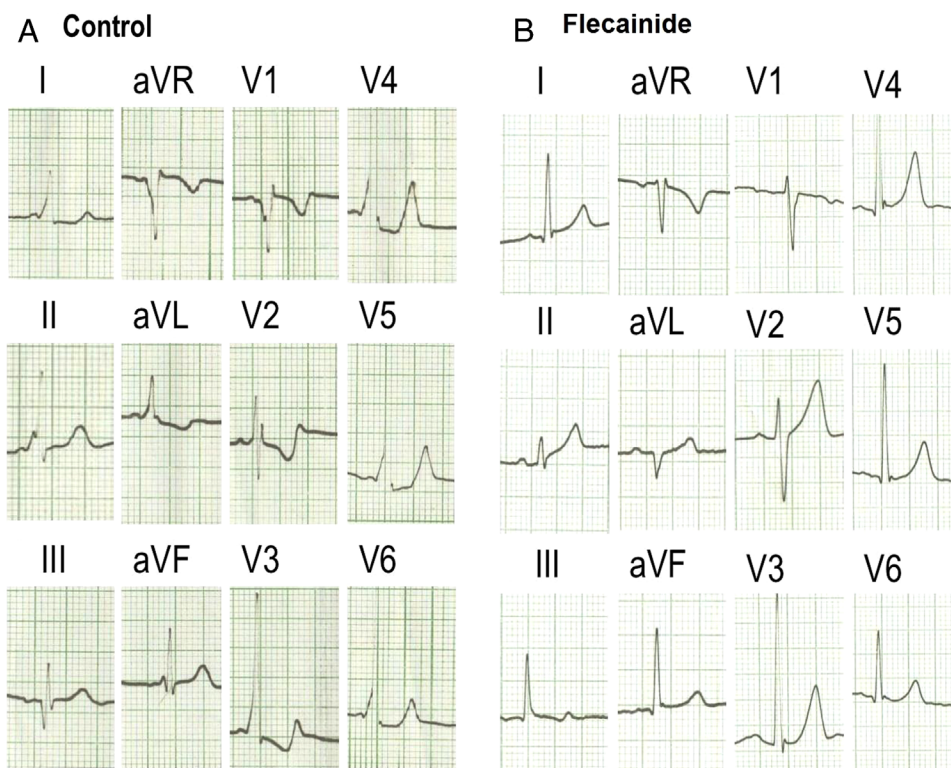


Figure 1 A: The 12-lead surface electrocardiogram before flecainide. B: Disappearance of antegrade conduction through the accessory pathway after the onset of flecainide.

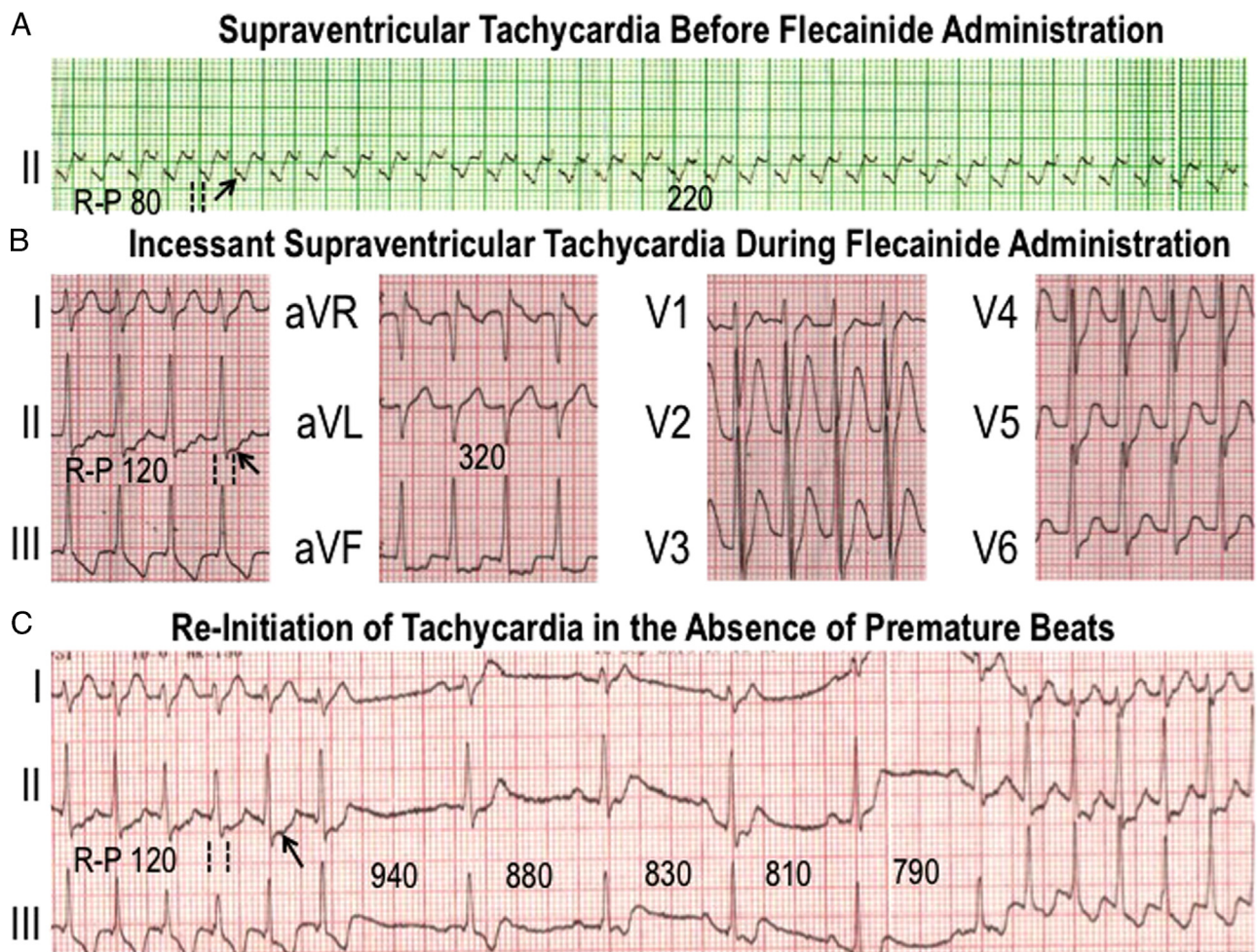


Figure 2 **A:** Supraventricular tachycardia before administration of flecainide with cycle length of 220 msec and interval RP of 80 msec. **B:** Incessant supraventricular tachycardia developed during flecainide administration. The RP interval has now increased to 120 msec. **C:** Following administration of intravenous adenosine there was transient termination of the tachycardia with rapid reinitiation in the absence of atrial or ventricular premature beats. Shortening of the sinus cycle length from 940 to 790 msec was enough to restart the tachycardia in the absence of premature beats. Arrows point to the retrograde P waves. Dotted lines indicate the R-P intervals.

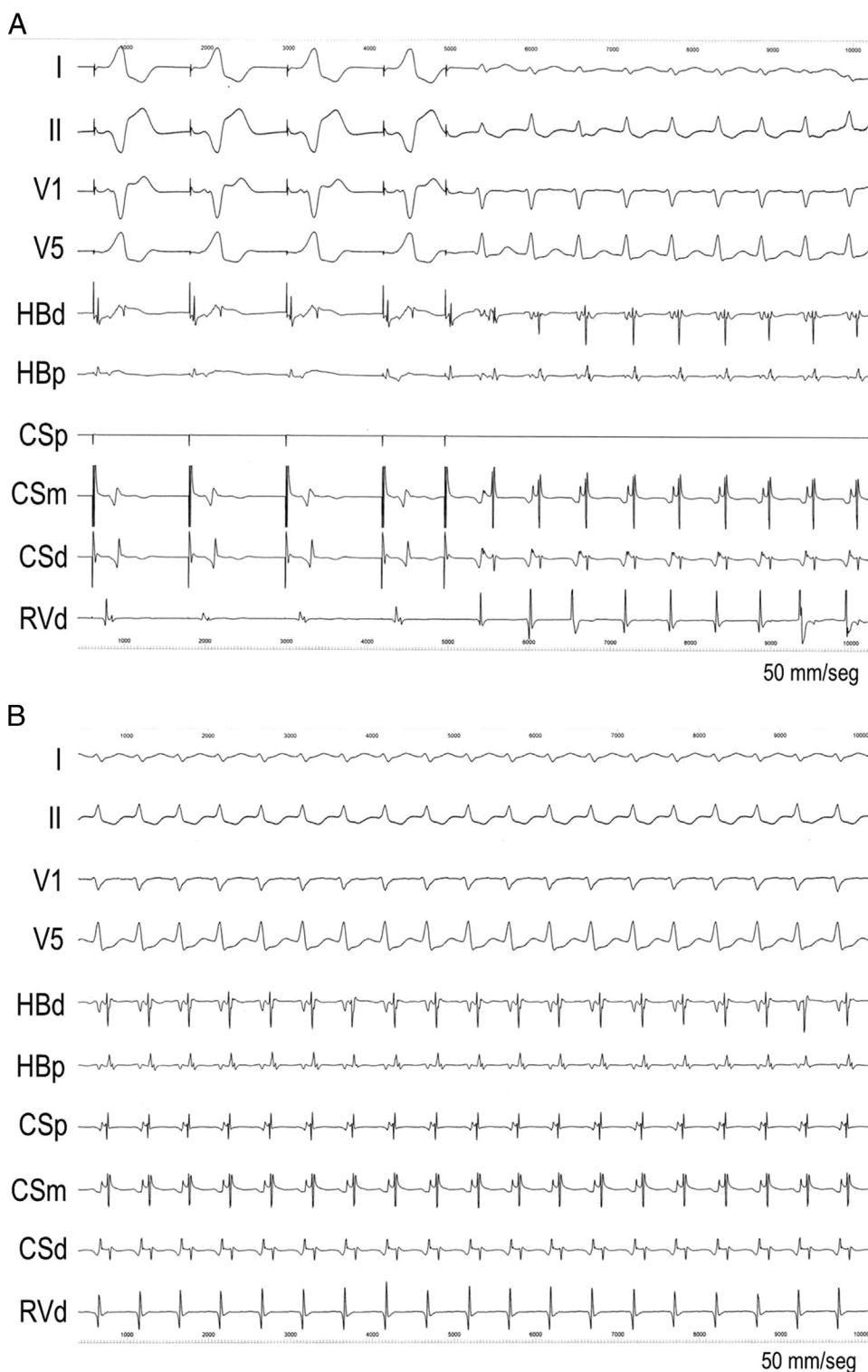


Figure 3 **A:** Electrocardiographic leads I, II, V₁, and V₅ are displayed along with electrograms recorded from the His bundle (HB), coronary sinus (CS), and right ventricle (RV) at a paper speed of 50 mm/sec. Pacing from proximal CS at a cycle length of 600 msec results in full preexcitation with negative delta wave in V₁ and II consistent with a right inferior paraseptal accessory A-V pathway. After introducing a single extrastimulus with a coupling interval of 400 msec, antegrade block over the accessory A-V pathway allows exclusive antegrade conduction over the atrioventricular (AV) node and induction of an orthodromic AV reentrant tachycardia with a cycle length of 280 msec. **B:** Same recording as panel A (50 mm/sec) with fewer signals for clarity (leads V₁ and V₅, HB, and CS recordings). Earliest retrograde atrial activation was recorded from the proximal coronary sinus (CSp) owing to retrograde activation through the accessory A-V pathway.

Conclusion

We describe a patient with a manifest AP in whom the administration of flecainide resulted in an incessant form of AVRT owing to a differential suppressive effect on antegrade and retrograde conduction over the AP. Such proarrhythmic effect of a class Ic drug has not been previously described.

References

1. Núñez F, Ruiz-Granell R, Martínez-Costa C, Morell S, Brines J. Safety and efficacy of flecainide in the treatment of symptomatic children with Wolff-Parkinson-White syndrome. *Pediatr Cardiol* 2010;31:1162–1165.
2. Langberg JJ, Calkins H, Kim YN, Sousa J, el-Atassi R, Leon A, Borganeli M, Kalbfleisch SJ, Morady F. Recurrence of conduction in accessory atrioventricular connections after initially successful radiofrequency catheter ablation. *J Am Coll Cardiol* 1992;19:1588–1592.
3. Iturralde P, Araya-Gomez V, Colin L, Kershenovich S, de Micheli A, Gonzalez-Hermosillo JA. A new ECG algorithm for the localization of accessory pathways using only the polarity of the QRS complex. *J Electrocardiol* 1996;29:289–299.
4. Huang YC, Lo W, Lin YJ, Chen SA. Incessant tachycardia after radiofrequency ablation of accessory pathway. *J Cardiovasc Electrophysiol* 2013;24:1306–1307.
5. Almroth H, Andersson T, Fengsrud E, Friberg L, Linde P, Rosenqvist M, Englund A. The safety of flecainide treatment of atrial fibrillation: long-term incidence of sudden cardiac death and proarrhythmic events. *J Intern Med* 2011;270:281–290.
6. Feld GK, Chen PS, Nicod P, Fleck RP, Meyer D. Possible atrial proarrhythmic effect of class 1C antiarrhythmic agents. *Am J Cardiol* 1990;66:378–383.
7. Coumel P. Junctional reciprocating tachycardias. The permanent and paroxysmal forms of A-V nodal reciprocating tachycardias. *J Electrocardiol* 1975;8:79–90.
8. Neuss H, Buss J, Schleppe M, Berthold R, Mitrovic V, Kramer A, Musial WJ. Effects of flecainide on electrophysiological properties of accessory pathways in the Wolff-Parkinson-White syndrome. *Eur Heart J* 1983;4:347–353.
9. Littmann L, Saxonhouse SJ. Repetitive, incessant supraventricular tachycardia: noninvasive determination of the electrophysiologic mechanism. *Int J Cardiol* 2015;190:256–259.