



## ORIGINAL ARTICLE

# Customized photorefractive keratectomy to correct high ametropia after penetrating keratoplasty: A pilot study



Giuseppe De Rosa<sup>a,\*</sup>, Rosa Boccia<sup>a</sup>, Carmine Santamaria<sup>b</sup>,  
Lorenzo Fabbozzi<sup>a</sup>, Luigi De Rosa<sup>a</sup>, Michele Lanza<sup>a</sup>

<sup>a</sup> Multidisciplinary Department of Medical, Surgical and Dental Specialties, Seconda Università di Napoli, Napoli, Italy

<sup>b</sup> Private Practice, Italy

Received 16 October 2013; accepted 27 November 2013

Available online 21 August 2014

### KEYWORDS

Astigmatism;  
Customized PRK;  
Keratoconus;  
Penetrating  
keratoplasty

### Abstract

**Purpose:** To evaluate preliminarily the safety and efficacy of customized photorefractive keratectomy (PRK) to correct ametropia and irregular astigmatism after penetrating keratoplasty (PK).

**Methods:** This pilot study included five eyes of five patients with a mean spherical equivalent of  $-5.1 \pm 1.46$  D (range from  $-2.75$  to  $-6.50$  D). In all cases, ametropia and irregular astigmatism was corrected with topography-guided customized PRK. Ocular examinations with topographic analysis were performed preoperatively as well as at 1, 3 and 6 months after surgery.

**Results:** All eyes gained postoperatively at least three Snellen lines of uncorrected visual acuity. Mean refractive spherical equivalent was  $0.62 \pm 0.63$  D (range from  $-0.25$  to  $-1.75$  D) at 6 months postoperatively.

**Conclusion:** Our pilot study suggests that customized PRK can be a safe and effective method for treating ametropia and irregular astigmatism after PK. Future studies with larger samples and longer follow-ups should be performed to confirm these results.

© 2013 Spanish General Council of Optometry. Published by Elsevier España, S.L.U. All rights reserved.

\* Corresponding author.

E-mail address: [g.derosaoftalmologia@libero.it](mailto:g.derosaoftalmologia@libero.it) (G. De Rosa).

**PALABRAS CLAVE**

Ametropía;  
 Astigmatismo;  
 PRK personalizada;  
 Queratocono;  
 Queratoplastia  
 perforante;  
 Agudeza visual

## Queratectomía fotorrefractiva personalizada para corregir altas ametropías tras queratoplastia penetrante: estudio piloto

**Resumen**

**Objetivo:** Evaluar preliminarmente la seguridad y eficacia de la queratectomía fotorrefractiva personalizada (PRK) para corregir la ametropía y astigmatismo irregular tras queratoplastia penetrante (PK).

**Métodos:** Este estudio piloto incluía un total de 5 ojos de 5 pacientes con un equivalente esférico medio de  $-5,1 \pm 1,46$  D (rango entre  $-2,75$  y  $-6,50$  D). En todos los casos, la ametropía y astigmatismo irregular se corrigió mediante PRK personalizada guiada por topografía. Se realizaron exámenes oculares con análisis topográfico preoperatoriamente, así como a los 1, 3 y 6 meses tras la cirugía.

**Resultados:** Todos los ojos ganaron al menos 3 líneas de agudeza visual Snellen no corregida. El equivalente esférico medio fue de  $0,62 \pm 0,63$  D (rango entre  $-0,25$  y  $-1,75$  D) a los 6 meses tras la cirugía.

**Conclusión:** Nuestro estudio piloto sugiere que la PRK personalizada puede ser un método seguro y eficaz para el tratamiento de la ametropía y el astigmatismo irregular tras PK. Deben realizarse futuros estudios con muestras de pacientes mayores y seguimientos más largos que confirmen estos resultados.

© 2013 Spanish General Council of Optometry. Publicado por Elsevier España, S.L.U. Todos los derechos reservados.

**Introduction**

Keratoconus (KC) is characterized by progressive corneal protrusion and thinning, leading to irregular astigmatism and impairment of visual function. KC is among the best indications for doing a penetrating keratoplasty (PKP), with long-term graft survival rates surpassing those for any other indication.<sup>1,2</sup> Generally accepted indications for PKP in KC are poor visual acuity with contact lenses, contact lens intolerance or inability to fit/wear contact lenses, and non-resolving corneal hydrops. The percentage of patients with KC eventually requiring PKP varies widely in different reports.<sup>3-7</sup> Residual refractive error and corneal irregularity following PKP can be managed with spectacles or contact lenses. However, although advances in techniques and instrumentations for PKP, especially the introduction of femtosecond lasers, have greatly improved PKP results, high refractive errors, especially high astigmatism, associated to high levels of corneal irregularity, may appear postoperatively in spite of an uneventful surgical procedure. These optical errors are hardly correctable and very disturbing for the patient.<sup>8-10</sup> In order to reduce residual astigmatism after PKP, some options have been described: surgical approaches such as relaxing incisions,<sup>11,12</sup> wedge resection as well as selective removal of sutures, which is a less predictable and stable method.<sup>13-16</sup> Some of the most common related complications to this last method are the risk for wound dehiscence, transplant rejection, and unsolvable topographic and refractive fluctuations.<sup>17</sup> Crystalline lens extraction with IOL implantation can correct ametropia but not corneal aberrations and some risks are associated to this procedures, such as endophthalmitis, secondary glaucoma, retinal detachment, or endothelial cell loss.<sup>18-20</sup>

The use of the excimer laser is a safe and effective technique to correct post-keratoplasty ametropia.<sup>21-24</sup> How-

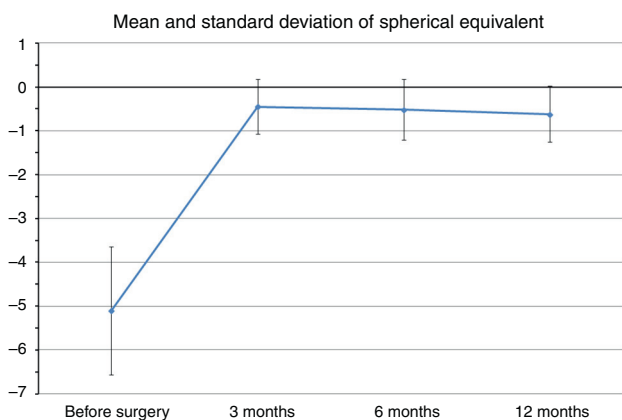
ever, conventional LASIK and PRK have limitations because they are unable to correct the irregularity of the post-transplantation corneal surface. Furthermore, some risks of the LASIK technique due to the creation of the flap should be considered, such as the creation of incomplete, irregular or even damaged flaps.<sup>25-27</sup> PRK is a safe and reliable technique but the risks of corneal haze and refractive regression should be also considered.<sup>28-31</sup>

Customized topography-guided corneal ablation with excimer laser is a procedure that can be used to correct not only ametropia after penetrating keratoplasty (PKP), but also irregular astigmatism.<sup>32</sup> We have used this technique to treat ametropia and irregular astigmatism after PKP in five of our patients in the attempt of verifying its efficacy, predictability, and safety. Therefore, the purpose of the current study was to evaluate preliminarily the safety and efficacy of topography-guided customized PRK for the correction of irregular astigmatism after PKP.

**Methods**

This study comprised of five eyes of five patients with significant residual ametropia (mean spherical equivalent  $-5.1 \pm 1.46$  D, range  $-2.75$  D to  $-6.50$  D) and irregular astigmatism after PKP that was treated by customized PRK. Patient age ranged from 49 years to 61 years. The sample included one male and four female patients.

All patients had undergone PKP at least 18 months before PRK, with removal of sutures at least 6 months before PRK. In all cases, PKP has been performed due to the presence of keratoconus of grade 3 or 4 according to the Amsler-Krumeich classification. After suture removal, no large changes in manifest refraction were observed. As a significant ametropia was present in the eye with previous PKP, a significant level of aniseikonia was present in all patients,



**Figure 1** Mean spherical equivalent in diopters (D) during the follow-up.

not allowing them the use of spectacles. Furthermore, in all cases, the refraction was stable for at least 6 months after suture removal. All eyes from the sample were intolerant to contact lenses.

An informed consent about the risks, benefits, and alternative treatment methods was signed by all the patients. This study received approval of the Ethics Committee of the hospital where the study was conducted, following the tenets of the Helsinki Declaration.

Preoperatively and in each postoperative visit (3, 6, and 12 months after surgery), a complete ophthalmic examination was performed in all patients including: uncorrected distance visual acuity (UDVA), corrected distance visual acuity (CDVA), corneal topography (Keratron, Optikon 2000 Inc.), corneal aberrometry (VISX WaveScan AMO Inc.), optical pachymetry (Oculus Pentacam HR, Oculus), air-puff tonometry (TonoRef II RKT-7700, Nidek) and endothelial cell analysis with a specular microscope (NonconRobo Sp-8000, Konan).

For the treatment, an acquisition of two very similar topography maps was performed, with a maximum difference of 3 micrometers between all the processed points in the 5 mm central zone of the cornea. This process was aimed at ensuring the obtainance of reliable corneal surface data. The elevation data obtained with the topographer, the patient's manifest refraction as well as the aberrometric data were uploaded to the software of calculation of the ablation profile. The customized ablation profile was then transferred to the excimer laser VISX Star S4 IR (AMO Inc.) computer. Only corneal aberrometric data were used to design the laser ablation profile. The procedure was planned to achieve the correction of the spherocylindrical refractive defect and the minimization of corneal HOAs. The ablation profile obtained was transferred to the laser computer for optimal positioning of the laser beam.

In each eye, one drop of 4% lidocaine was instilled 4 times every 5 min before treatment. The non-treated eye was occluded during surgery, whereas antibiotic drops of 0.3% netilmicin (Nettacin) were instilled in the affected eye. After epithelium removal with an Amoils rotating brush, the customized laser procedure was performed. To center the treatment, patient's pupil was automatically detected by the excimer laser and topographic and refrac-

**Table 1** Refractive data of each patient preoperatively and postoperatively.

Patient	age/sex/eye	Pre-op	3 months	6 months	12 months
1	54/F/left	sf - 4.00 = cyl - 3.00 × 140°	cyl - 1.00 × 135°	sf + 0.25 = cyl - 1.00 × 140°	sf + 0.25 = cyl - 1.00 × 140°
2	58/F/right	sf - 1.50 = cyl - 9.00 × 65°	cyl - 3.00 × 60°	sf - 0.50 = cyl - 2.50 × 55°	sf - 0.50 = cyl - 1.50 × 50°
3	49/F/right	sf - 1.00 = cyl - 3.50 × 5°	sf + 0.25 = cyl - 0.75 × 5°	cyl - 0.50 × 10°	cyl - 0.50 × 10°
4	61/F/right	sf - 3.00 = cyl - 3.50 × 160°	sf + 0.50 = cyl - 1.00 × 160°	sf + 0.25 = cyl - 0.75 × 155°	sf - 0.50 = cyl - 0.50 × 160°
5	51/M/right	sf - 4.00 = cyl - 5.00 × 10°	sf + 0.50 = cyl - 1.25 × 10°	sf + 0.25 = cyl - 1.00 × 10°	sf + 0.25 = cyl - 1.25 × 10°

**Table 2** Corrected distance visual acuity during the follow-up.

Patient	Pre-op	3 months	6 months	12 months
1	20/25	20/25	20/20	20/20
2	20/63	20/40	20/32	20/32
3	20/25	20/25	20/20	20/20
4	20/32	20/25	20/20	20/20
5	20/32	20/32	20/25	20/25

tive data were utilized. We did not use the transepithelial technique because of the corneal anomalies and irregularities that are usually present in post-PKP corneas, and also considering that there are some papers stating the effectiveness of the surgical procedure used.<sup>7,15,16</sup> One drop of netilmicin 0.3% (Nettacin), fluorometholone 0.1% (Fluaton) eye drops and a contact lens (Protek T&S, Contact Vision) were applied postoperatively. The postoperative treatment included netilmicin 0.3% eye drops 4 times daily for 1 month, clobetasone (Visucloben) eye drops 4 times a day for 1 week and then reducing during the next 3 weeks and hyaluronic acid 0.2% (Hyalistil eye drops 4 times daily for 3 months, then 3 times a day for the next 3 months).

## Results

The preoperative and postoperative patients' data are shown in Table 1. All eyes had an UDVA equal to or better than 20/400 (1.1 LogMAR) preoperatively. The treatment resulted in an improvement of UDVA that remained stable throughout the follow-up. After treatment, two eyes

achieved 20/50 (0.4 LogMAR) of UDVA and three eyes 20/100 (0.7 LogMAR), with a gain of three Snellen lines.

Mean preoperative SE was  $-5.1 \pm 1.46$  D (range  $-2.75$  to  $-6.5$  D), whereas at the last postoperative visit mean SE was  $-0.62 \pm 0.63$  D (range  $-0.25$  to  $-1.75$  D). Fig. 1 shows changes in mean SE during the entire follow-up. No patient lost lines of CDVA. A total of three patients gained two lines of CDVA, one patient gained three lines and another gained four lines. The visual outcomes remained stable at the last follow-up visit. Re-epithelization was observed in all cases in a period between 72 and 96 h after PRK.

At the 12-month postoperative examination, three patients achieved 20/20 (0.0 LogMAR) CDVA (Table 2). No patient needed secondary surgery. No patients had evident corneal haze, although two patients reported halos. Some subjective symptoms such as ocular discomfort, burning or slight pain was easily resolved after steroid therapy.

Table 3 shows the results obtained in the measurement of central corneal thickness, intraocular pressure and endothelial cell count. Corneal thickness was reduced on average  $108 \mu\text{m}$  with the laser ablation, remaining in all cases more than  $400 \mu\text{m}$  of residual cornea. Mean intraocular pressure values were similar during the postoperative follow-up without statistically significant differences ( $p=0.09$ , paired Student's *t*-test). Mean endothelial cell density did not change significantly between the preoperative and the 12-month postoperative visits ( $p=0.13$ , paired Student's *t*-test), with a cell loss of less than 2% at one year.

We did not observe a statistical significant change in spherical aberration (SphA) and coma at 12 months after surgery (Table 4). In addition, aberrometry showed a

**Table 3** Mean value  $\pm$  standard deviation of pachymetry, intraocular pressure (IOP), endothelial cell density (ECD), corrected distance visual acuity (CDVA), sphere in diopters (Sph), cylindrical value in diopters (Cyl), and spherical equivalent in diopters (SE) during the follow-up.

	Pre-op	3 months	6 months	12 months	<i>p</i> value (preop vs. 12 month postop)
Pachymetry ( $\mu\text{m}$ ) (SD)	531.8 (17.5)	427.6 (12.8)	427.8 (12.5)	423.4 (16.2)	<0.05
IOP (mmHg) (SD)	16 (0.70)	12 (1.58)	11.4 (0.89)	11.2 (0.83)	<0.05
ECD (cell/ $\text{mm}^2$ )	2162.2 (156.64)	2146.2 (149.77)	2143 (146.57)	2126.2 (138.65)	0.13
LogMAR CDVA	0.22 (0.16)	0.16 (0.09)	0.06 (0.09)	0.06 (0.09)	<0.05
LogMAR UDVA	1.08 (0.04)	0.58 (0.16)	0.58 (0.16)	0.58 (0.16)	<0.05
Sph (D)	-2.70 (1.39)	0.25 (0.25)	0.05 (0.32)	-0.05 (0.32)	<0.05
Cyl (D)	-4.80 (2.46)	-1.40 (0.91)	-1.15 (0.78)	-0.95 (0.45)	<0.05
SE (D)	-5.1 (1.4)	-0.44 (0.61)	-0.52 (0.68)	-0.62 (0.63)	<0.05

**Table 4** Difference between preoperative and after 12 months after surgery of Corneal Wavefront Aberrometry.

	Pre-op (mean $\pm$ SD)	12 months (mean $\pm$ SD)	Mean difference $\pm$ SD	Range	<i>p</i> value
Spherical aberration ( $\mu\text{m}$ )	0.0856 $\pm$ 0.11	0.0748 $\pm$ 0.27	-0.0034 $\pm$ 0.199089	From 0.203 to -0.319	0.971368
Coma ( $\mu\text{m}$ )	0.264 $\pm$ 0.15	0.208 $\pm$ 0.12	0.0556 $\pm$ 0.202758	From 0.385 to -0.127	0.572913
Total RMS ( $\mu\text{m}$ )	3.528 $\pm$ 1.77	1.724 $\pm$ 0.86	1.8438 $\pm$ 1.210581	From 3.342 to 0.086	<0.05

SfAb, spherical aberration; Coma, coma aberration; RMS, root mean square; SD, standard deviation.



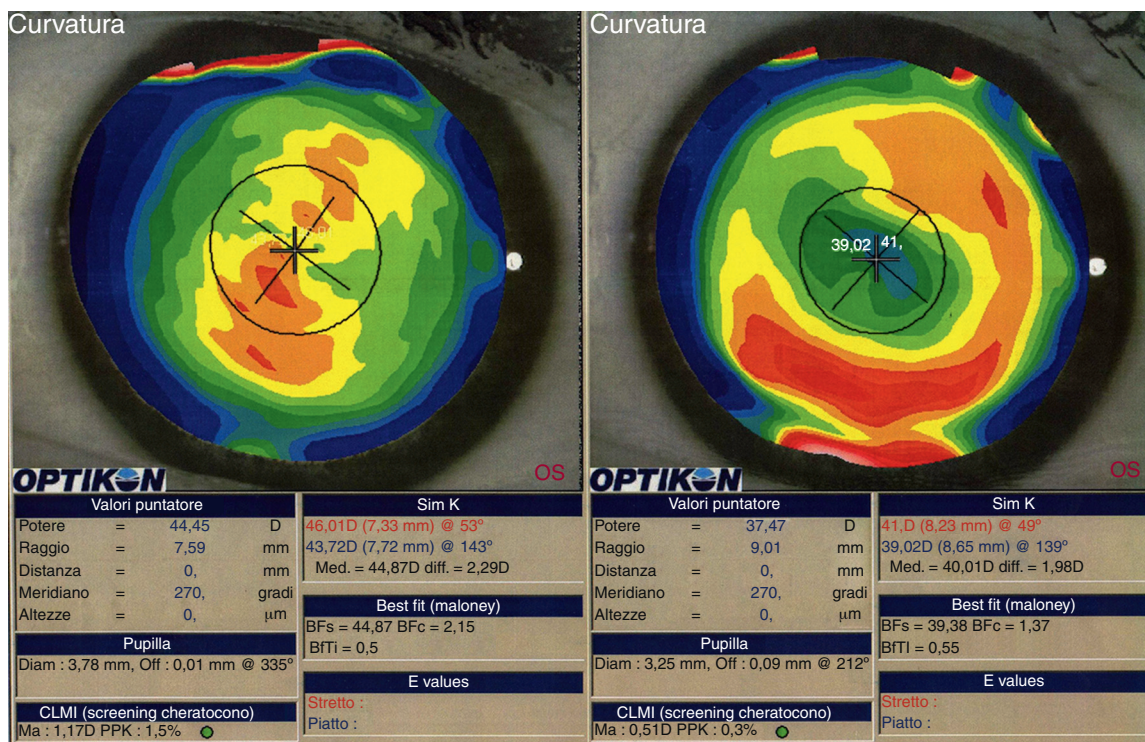


Figure 2 Corneal topography preoperatively (left) and postoperatively (right) (patient 3).

reduction of total aberrations root mean square (RMS). Indeed, a statistically significant difference in total RMS was found one year after treatment ( $p = 0.027$ , paired Student's  $t$ -test). Fig. 2 shows an example of preoperative and postoperative corneal topographies in one case from the sample.

## Discussion

Customized transepithelial photorefractive keratectomy (PRK) has been shown to be effective in reducing post-keratoplasty ametropia.<sup>33</sup> In our series, a mean correction of SE of 87.9% (range 79–94.3%) was found, with a strong improvement in UDVA. No patient lost any Snellen line of UDVA or CDVA. Therefore, the visual acuity improved in all patients with no regression during a period of 12 months postoperatively. As a consequence of the laser treatment, all patients could use spectacle correction after surgery, as a high reduction of ametropia was achieved.

Also CDVA was benefited from the laser treatment, improving on average three Snellen lines, even reaching 20/20 in three patients. The absence of haze and the negligible loss of endothelial cells demonstrated the safety and stability of the treatment. Also, although a reduction in total RMS was observed, coma and spherical aberration were not statistically reduced. This reduction in total corneal aberrations was the consequence of a change in some other HOAs induced by the excimer laser. It should be also noted that the small number of our series is a clear limitation for achieving statistical significance. The customized ablation allowed us to obtain a corneal surface much more uniform than preoperatively. Using the laser spot technology, with

variable diameter and modulated frequency, local irregularities can be corrected with saving of corneal tissue.<sup>34</sup> This saving of corneal tissue allows treatment of high levels of irregular astigmatism, inducing simultaneously a regular and smooth surface. The topo-aberrometric information transmitted to the excimer laser allows a precise treatment planning that combined with a highly precise alignment and an accurate centering lead to excellent levels of visual rehabilitation. Visual acuity improvement is related to the regularization of the corneal surface and the enhancement of topographic parameters. The reduction of the total aberrations lead to an improvement in the quality of the corneal front surface and so to a better image optical quality, as observed in other studies.<sup>35</sup> In our study, we have achieved the goal of reducing as much as possible the high astigmatism that was present in our post-PKP eyes to obtain a better visual acuity and a smoother corneal surface. The UDVA and CDVA improved without regression during the 12-month postoperative follow-up, which shows acceptable levels of predictability, efficiency and stability of treatment. The correction with spectacles after the treatment led to a binocular vision greatly appreciated by the patients and inducing a benefit in their daily life activities. Our results should be confirmed in further studies with longer follow-up periods and larger samples in order to define the customized PRK as a primary treatment strategy to correct stable ametropia after PKP.

## Conflicts of interest

The authors have no conflicts of interest to declare.

## References

1. Price FW, Whitson WE, Marks RG. Graft survival in four common groups of patients undergoing penetrating keratoplasty. *Ophthalmology*. 1991;98:322–328.
2. Pramanik S, Musch DC, Sutphin JE, Farjo AA. Extended long-term outcomes of penetrating keratoplasty for keratoconus. *Ophthalmology*. 2006;113:1633–1638.
3. Kennedy RH, Bourne WM, Dyer JA. A 48-year clinical and epidemiologic study of keratoconus. *Am J Ophthalmol*. 1986;101:267–273.
4. Smiddy WE, Hamburg TR, Kracher GP, Stark WJ. Keratoconus. Contact lens or keratoplasty? *Ophthalmology*. 1988;95:487–492.
5. Sray WA, Cohen EJ, Rapuano CJ, Laibson PR. Factors associated with the need for penetrating keratoplasty in keratoconus. *Cornea*. 2002;21:784–786.
6. Gordon MO, Steger-May K, Szczotka-Flynn L, et al. Baseline factors predictive of incident penetrating keratoplasty in keratoconus. *Am J Ophthalmol*. 2006;142:923–930.
7. Hodge C, Sutton G, Lawless M, Rogers C. Photorefractive keratectomy with mitomycin-C after corneal transplantation for keratoconus. *J Cataract Refract Surg*. 2011;37:1884–1894.
8. Perlman EM. An analysis and interpretation of refractive errors after penetrating keratoplasty. *Ophthalmology*. 1981;88:39–45.
9. Gaster RN, Dumitrascu O, Rabinowitz YS. Penetrating keratoplasty using femtosecond laser-enabled keratoplasty with zig-zag incisions versus a mechanical trephine in patients with keratoconus. *Br J Ophthalmol*. 2012;96:1195–1199.
10. Genvert GI, Cohen EJ, Arentsen JJ, et al. Fitting gas-permeable contact lenses after penetrating keratoplasty. *Am J Ophthalmol*. 1985;99:511–514.
11. Arffa RC. Results of a graded relaxing incision technique for post keratoplasty astigmatism. *Ophthalmic Surg*. 1988;19:624–628.
12. Lugo M, Donnenfeld ED, Arentsen JJ. Corneal wedge resection for high astigmatism following penetrating keratoplasty. *Ophthalmic Surg*. 1987;18:650–653.
13. Assil KK, Zarnegar SR, Schanzlin DJ. Visual outcome after penetrating keratoplasty with double continuous or combined interrupted and continuous suture wound closure. *Am J Ophthalmol*. 1992;114:63–71.
14. Binder PS. The effect of suture removal on postkeratoplasty astigmatism. *Am J Ophthalmol*. 1988;106:507.
15. Huang PY, Huang PT, Astle WF, et al. Laser-assisted subepithelial keratectomy and photorefractive keratectomy for post-penetrating keratoplasty myopia and astigmatism in adults. *J Cataract Refract Surg*. 2011;37:335–340.
16. Forseto Ados S, Marques JC, Nosé W. Photorefractive keratectomy with mitomycin-C after penetrating and lamellar keratoplasty. *Cornea*. 2010;29:1103–1108.
17. Goren MB, Dana MR, Rapuano CJ, et al. Corneal topography after selective suture removal for astigmatism following keratoplasty. *Ophthalmic Surg Lasers*. 1997;28:208–214.
18. Hardten DR, Lindstrom RL. Surgical correction of refractive errors after penetrating keratoplasty. *Int Ophthalmol Clin*. 1997;37:1–35.
19. Amm M, Halberstadt M. Implantation of toric intraocular lenses for correction of high post-keratoplasty astigmatism. *Ophthalmologie*. 2002;99:464–469.
20. Mohammadpour M. Toric IOL and postkeratoplasty astigmatism. *Ophthalmology*. 2007;114:825–826.
21. Buzard K, Febbraro JL, Fundingsland BR. Laser in situ keratomileusis for the correction of residual ametropia after penetrating keratoplasty. *J Cataract Refract Surg*. 2004;30:1006–1013.
22. Hardten DR, Chittcharus A, Lindstrom RL. Long term analysis of LASIK for the correction of refractive errors after penetrating keratoplasty. *Cornea*. 2004;23:479–489.
23. Alió JL, Javaloy J, Osman AA, Galvis V, Tello A, Haroun HE. Laser in situ keratomileusis to correct post-keratoplasty astigmatism; 1-step versus 2-step procedure. *J Cataract Refract Surg*. 2004;30:2303–2310.
24. Camellin M, Arba Mosquera S. Simultaneous aspheric wavefront-guided transepithelial photorefractive keratectomy and phototherapeutic keratectomy to correct aberrations and refractive errors after corneal surgery. *J Cataract Refract Surg*. 2010;36:1173–1180.
25. Knorz MC. Flap and interface complications in LASIK. *Curr Opin Ophthalmol*. 2002;13:242–245.
26. Arevalo JF. Posterior segment complications after laser-assisted in situ keratomileusis. *Curr Opin Ophthalmol*. 2008;19:177–184.
27. Kuryan J, Channa P. Refractive surgery after corneal transplant. *Curr Opin Ophthalmol*. 2010;21:259–264.
28. Amm M, Duncker GI, Schroder E. Excimer laser correction of high astigmatism after keratoplasty. *J Cataract Refract Surg*. 1996;22:313–317.
29. Bilgihan K, Ozdek SC, Akata F, Hasanreisoglu B. Photorefractive keratectomy for post-penetrating keratoplasty myopia and astigmatism. *J Cataract Refract Surg*. 2000;26:1590–1595.
30. Barreto Jr J, Netto MV, Reis A, Nakano M, Alves MR, Bechara SJ. Topography-guided (NIDEK customized aspheric treatment zone) photorefractive keratectomy with mitomycin C after penetrating keratoplasty for keratoconus: case report. *J Refract Surg*. 2009;25(Suppl.):S131–S135.
31. Solomon R, Donnenfeld ED, Perry HD. Photorefractive keratectomy with mitomycin C for the management of a LASIK flap complication following a penetrating keratoplasty. *Cornea*. 2004;23:403–405.
32. Rajan MS, O'Brart DP, Patel P, Falcon MG, Marshall J. Topography-guided customized laser-assisted subepithelial keratectomy for the treatment of postkeratoplasty astigmatism. *J Cataract Refract Surg*. 2006;32:949–957.
33. Kanellopoulos AJ, Binder PS. Management of corneal ectasia after LASIK with combined, same-day, topography-guided partial transepithelial PRK and collagen cross-linking: the Athens protocol. *J Refract Surg*. 2011;27:323–331.
34. La Tegola MG, Alessio G, Sborgia C. Topographic customized photorefractive keratectomy for regular and irregular astigmatism after penetrating keratoplasty using the LIGI CIPTA/LaserSight platform. *J Refract Surg*. 2007;23:681–693.
35. Pedrotti E, Sbabo A, Marchini G. Customized transepithelial photorefractive keratectomy for iatrogenic ametropia after penetrating or deep lamellar keratoplasty. *J Cataract Refract Surg*. 2006;32:1288–1291.