



Available online at  
**ScienceDirect**  
[www.sciencedirect.com](http://www.sciencedirect.com)

Elsevier Masson France  
**EM|consulte**  
[www.em-consulte.com/en](http://www.em-consulte.com/en)



Review article

# Post-traumatic osteoarthritis of the elbow



M. Chammas

Faculté de médecine de Montpellier, Université Montpellier 1, Hôpital Lapeyronie, CHU de Montpellier, avenue du Doyen-Giraud, 34295 Montpellier Cedex 5, France

## ARTICLE INFO

### Article history:

Accepted 15 November 2013

### Keywords:

Post-traumatic osteoarthritis  
 Elbow  
 Arthroplasty  
 Arthroscopy

## ABSTRACT

Post-traumatic osteoarthritis of the elbow is an uncommon condition in which the clinical manifestations are often at variance with the radiological findings. In symptomatic forms, pain and stiffness are variably combined. When non-operative management fails, the decision to perform surgery is taken on a case-by-case basis depending on age, activity level, patient discomfort, and osteoarthritis location and severity as assessed by CT scan arthrography. Elbow instability or subluxation should be sought. Post-traumatic elbow osteoarthritis raises difficult therapeutic problems in young patients. The goal of treatment is to obtain a low level of pain with sufficient motion range to ensure good function, while preserving future surgical options and delaying elbow arthroplasty to the extent possible.

© 2013 Elsevier Masson SAS. All rights reserved.

## 1. Introduction

Osteoarthritis is far less common at the elbow than at the other upper limb joints. In addition to trauma, causes include overuse injury, osteochondritis dissecans, osteochondromatosis, crystal-induced arthropathies, and sequelae of septic arthritis or haemophilia. Elbow injuries in children and adults can result in osteoarthritis due either to the initial cartilage damage or to sub-optimal internal fixation, malunion with joint surface incongruity, or instability. Although not a weight-bearing joint, the elbow is subjected to considerable forces whose resultant can reach 0.3 to 0.5 times the weight of the body at the humero-ulnar joint during everyday activities [1] and 3 times the weight of the body at the humero-ulnar and humero-radial joints during heavy labour [2]. Discordance between the clinical manifestations and radiological findings is common (Fig. 1).

In this lecture, the evaluation and various treatment options depending on age, clinical findings, and osteoarthritis location and severity are discussed.

## 2. Epidemiology

Few long-term data on post-traumatic elbow osteoarthritis are available. In a study of 139 patients, Guitton et al. [3] identified 32 patients who met Broberg and Morrey criteria for moderate-to-severe osteoarthritis 10 to 34 years after an elbow injury [4]. Osteoarthritis was more common after an intra-articular fracture of the distal humerus or fracture-dislocation than after a fracture

of the radial head or olecranon. Subsequent long-term studies assessed the occurrence of osteoarthritis according to the joint involved.

### 2.1. Osteoarthritis after an intra-articular fracture of the distal humerus

Of 30 patients evaluated 12 to 30 years after internal fixation of a distal humerus fracture, 80% had elbow osteoarthritis, which was mild-to-moderate in 74% of cases [5].

### 2.2. Osteoarthritis after fracture of the radial head

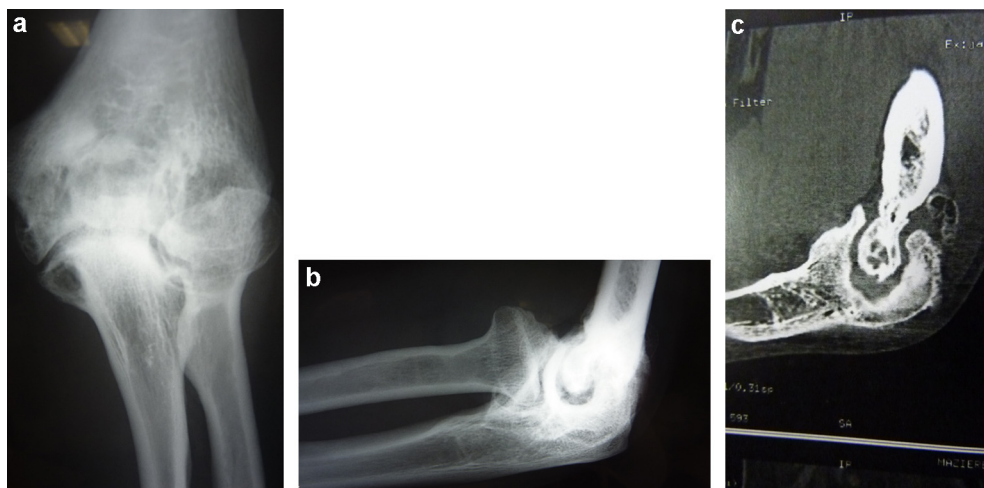Among 100 patients seen a mean of 18 years after non-operative management of Mason II or III fractures, 76% had mild-to-moderate osteoarthritis of the injured elbow compared to 16% for the uninjured elbow [6].

At re-evaluation 10 to 42 years after radial head resection for isolated radial head fracture in young patients, osteoarthritis was noted in 88% to 100% of elbows, with satisfactory function and no pain [7,8]. The osteoarthritis grade was II or III (89%) in one study [7] and I in most cases (65%) in another study [8].

Osteoarthritis is significantly less common after internal fixation of non-comminuted Mason II–III fractures than after radial head resection [9]. In Mason III fractures with more than three fragments, complications (inappropriate internal fixation, malunion, partial necrosis) are responsible for early osteoarthritic lesions that require revision surgery for arthroplasty or resection.

A fractured radial head silicone implant with inflammatory synovitis (known as siliconitis) is believed to worsen the osteoarthritic lesions secondary to elbow injuries and radial head resection. Among 20 patients seen 12 years after monoblock radial head

E-mail address: [m-chammas@chu-montpellier.fr](mailto:m-chammas@chu-montpellier.fr)



**Fig. 1.** a–c: sequelae in a 22-year-old man of a distal humerus fracture sustained in childhood. Occasional pain and severe stiffness. Able to play recreational rugby. Surgical abstention.

implantation [10], 9 had osteoarthritis confined to the humero-ulnar joint, which was mild in 6 patients, moderate in 2, and severe in 1. Another study evaluated 17 patients with a mean follow-up of 106 months after bipolar radial head arthroplasty [11]. Humero-ulnar osteoarthritis was noted in 12 patients, including 8 with grade I and 4 with grade II lesions; no patient had grade III osteoarthritis. The osteoarthritic changes did not correlate with pain intensity.

With a floating radial head prosthesis used to treat recent fractures, Judet et al. [12] found no evidence of osteoarthritis with a mean follow-up of 4 years. The risk of osteoarthritis is higher when arthroplasty is performed as a revision procedure or at a distance from the injury. Shore et al. [13] reported a 74% rate of osteoarthritis after 8 years in patients treated with metallic radial head arthroplasty 2.4 years on average after the injury.

### 2.3. Osteoarthritis after a fracture of the proximal ulna

Rochet et al. [14] reported grade I osteoarthritis in 6 of 18 patients 3 to 9 years after internal fixation for a comminuted fracture of the proximal ulna. The following criteria were of adverse prognostic significance:

- preoperatively, Regan and Morrey type 3 coronoid process, fracture-dislocation;
- postoperatively, joint surface step-off greater than 2 mm, joint surface incongruity [14].

### 2.4. Osteoarthritis after a fracture-dislocation of the elbow

Persistent incomplete reduction after the treatment of a fracture-dislocation of the elbow is among the lesions associated with the prompt development of osteoarthritis. Secondary treatment has been followed by osteoarthritis in 46% to 76% of cases [15].

### 2.5. Osteoarthritis after an elbow fracture in childhood

Very few long-term data are available. Osteoarthritis is due to incomplete reduction of intra-articular fractures, deformities related to growth-plate injury, or complications of the primary treatment (Fig. 1). The most common injuries are lateral condyle fractures; radial head fractures, which may be followed by hypertrophy with dysmorphism; olecranon fractures; and Monteggia fractures [16].

## 3. Evaluation

### 3.1. Clinical evaluation

In addition to patient age and location on the dominant or non-dominant side, the following should be recorded:

- the severity of the pain and stiffness, as well as the severity of instability if present. The characteristics of the pain should be analyzed in detail:
  - pain at the end of the motion range suggests an obstacle with impingement by an osteophyte,
  - pain throughout the motion range suggests advanced osteoarthritis,
  - nocturnal inflammatory pain should prompt an evaluation for a history of infection;
- occupational activities (manual labor or other) and sports activities, which influence the risk of progression;
- impact on recreational activities or on activities of daily living;
- level of functional demand;
- previous surgical procedures and postoperative events (e.g., impaired healing and infectious complications);
- previous non-operative treatments (e.g., local glucocorticoid injections and visco-supplementation).

The physical examination should include the following:

- an assessment of the skin (scars, flaps, fragile regions) and of any deformities;
- identification of painful sites and of the manoeuvres that trigger the pain;
- a search for a joint effusion and for evidence of inflammation;
- range of motion measurements, tests for stability, and a functional assessment based on Morrey's score [17];
- evaluations of:
  - the muscles and tendons, most notably the triceps tendon, as well as the attachments on the medial and lateral epicondyles,
  - nerve function, with special attention to the ulnar nerve (history of transposition, evidence of compression, instability, sensory evaluation [Weber's Test], and motor function) and posterior inter-osseous nerve, which is vulnerable to compression in front of a subluxated radial head or fractured silicone implant, usually in the absence of any deficit (radial tunnel syndrome);

- and, finally:
  - an evaluation of the wrist, most notably for an Essex-Lopresti fracture in patients with sequelae of a radial head fracture (distal radio-ulnar incongruity, ulno-carpal impaction),
  - a search for any concomitant lesions and a record of the use of walking aids.

3.2. Investigations

3.2.1. Laboratory tests

When a doubt exists about a history of infection or the evaluation shows evidence of inflammation, standard blood tests (erythrocyte sedimentation rate, blood cell counts, and C-reactive protein) and joint aspiration for cell counts and microbiological studies should be performed. The surgeon and patient should be aware that two-stage surgery might be needed, depending on the preoperative bacteriological data and intra-operative findings.

3.2.2. Imaging studies

The goals of the imaging work-up are as follows:

- to determine the location and severity of the osteoarthritic lesions:
  - involvement of the humero-ulnar joint and/or humero-radial joint,
  - central or marginal lesions, with osteophytes;
- to assess joint surface congruity;
- to detect possible filling of the olecranon and coronoid fossae and/or any foreign bodies;
- to analyze any deformities such as metaphyseal malunion, intra-articular deformities, major morphological abnormalities related to a childhood injury, and non-union;
- to evaluate any peri-articular ossifications;
- after internal fixation, to look for penetration of the material into the joint cavity, osteolysis and, for prosthetic material, osteolysis or loosening.

Standard radiographs constitute the first-line imaging study. Computed tomography (CT), preferably with contrast injection into the joint (CT-arthrography) is the second-line imaging study of choice. During this investigation, injection into the joint cavity of a glucocorticoid (provided the patient has no history of infection) or hyaluronan provides initial treatment. CT is often sufficient in severe osteoarthritis. Three-dimensional reformation is useful in the event of malunion.

Based on the results of the investigations, the location of the osteoarthritic lesions is determined, and their severity is assessed

using Broberg and Morrey criteria [18]. Any concomitant abnormalities are recorded (Fig. 2). The distal humerus bone stock is classified into four grades according to Larson and Morrey [19]:

- grade I: subchondral bone stock intact;
- grade II: medial and lateral columns intact;
- grade III: medial or lateral column absent;
- grade IV: entire distal part of the humerus absent.

3.2.3. Electrophysiological testing

Electrophysiological testing is in order in patients with clinical neurological manifestations suggestive of entrapment syndrome, particularly involving the ulnar nerve or posterior inter-osseous nerve. Secondary entrapment should be differentiated from nerve injury due to the trauma or surgery (timing of the symptoms relative to the trauma or to any previous surgical procedures).

4. Treatment

An important point to bear in mind is that the prevention of post-traumatic osteoarthritis in younger patients rests on high-quality osteoarticular reduction.

Discordance between the clinical and radiological findings is common in osteoarthritis of the elbow. The treatment strategy should not be based on the radiographs. Ulnar nerve entrapment at the elbow may be the only problem and requires release with transposition to avoid recurrences and instability.

Based on the pre-treatment work-up, several situations can be distinguished.

According to patient age and demand level: advanced elbow osteoarthritis in a young patient raises major therapeutic challenges. Total elbow arthroplasty is very rarely appropriate in this situation, as prosthesis survival times are limited. The treatment objective in a young patient is to achieve minimal pain with good function, while preserving future surgical options [20] and delaying arthroplasty for as long as possible.

According to the symptoms and functional impact: the treatment strategy differs between patients with little or no pain whose main complaint is elbow stiffness and patients with pain as the predominant complaint.

According to whether the osteoarthritic lesions involve the humero-radial joint, the humero-ulnar joint, or both.

According to whether the patient has severe osteoarthritis or early osteoarthritis with pain only at the end of the motion range, due to osteophyte impingement.

According to the presence or absence of subluxation, instability, or concomitant lesions.

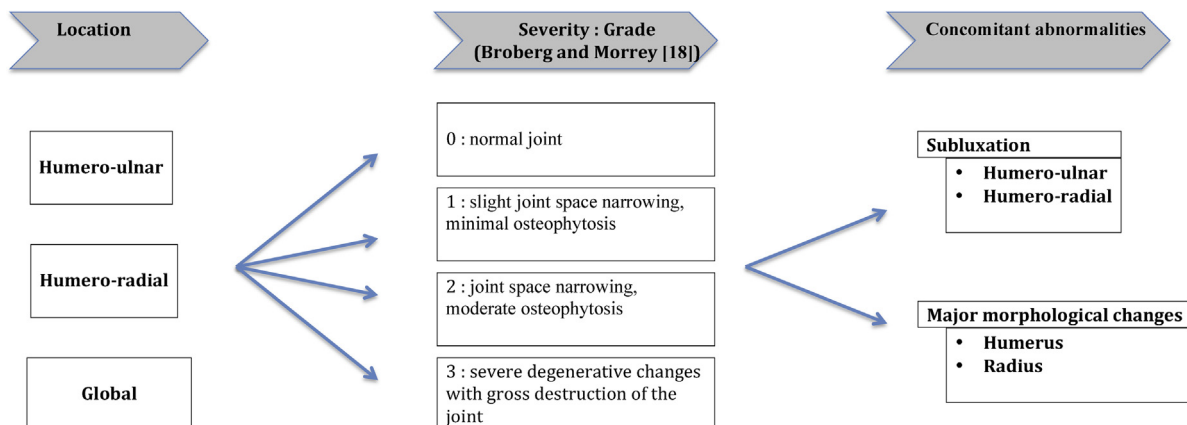


Fig. 2. Classification of elbow osteoarthritis.

According to whether the elbow stiffness is due to extrinsic factors (contracture of the capsule and ligaments, soft tissue scarring, heterotopic ossifications) and/or intrinsic factors (foreign bodies, intra-articular malunion, joint surface incongruity, osteophytes, intra-articular adhesions).

It should be borne in mind that patients' assessments of post-operative outcomes are influenced by pain severity to a far larger extent than by range of motion. Function can remain satisfactory despite motion range limitation:

- the functional range of motion at the elbow is  $-30^\circ$  of extension to  $130^\circ$  of flexion [21];
- in a study by Vasen et al. [22], the smallest functional range of motion that could be compensated for by other joints was  $-75^\circ$  of extension and  $120^\circ$  of flexion.

Finally, the surgical strategy should be based on both the clinical and the imaging study findings. A surgical decision algorithm is shown on Fig. 3 but should be viewed merely as providing general guidance, as the treatment decisions should be tailored to each individual patient.

4.1. Non-operative treatment

Elbow pain requires a decrease in the demands placed on the elbow. Systemic and local symptomatic treatments should be given. Local treatments include intra-articular glucocorticoid injections (in the absence of contra-indications) and visco-supplementation.

In a study of 18 patients with post-traumatic osteoarthritis, pain relief duration after visco-supplementation was 6 months at the most [23].

4.2. Surgical treatment

Surgery is indicated in patients with failure of non-operative treatment.

4.2.1. Humero-radial osteoarthritis

Radial head osteoarthritis and some cases of humeral condyle osteoarthritis are chiefly related to radial head malunion or implantation of a silicone radial head. Osteoarthritis of the capitellum may complicate an Essex-Lopresti fracture with humero-radial impingement.

The surgical decision rests on the presence of concordant clinical and imaging study findings, with lateral pain replicated during the physical examination, particularly by forearm rotation, and clearly identified osteoarthritic lesions.

4.2.1.1. Alternatives to arthroplasty.

4.2.1.1.1. Radial head resection. Radial head resection increases the mechanical stresses on the ulnar compartment, worsens the valgus, and carries a risk of proximal radial migration with ulnar variance alteration at the wrist. Isolated radial head resection is therefore controversial.

Nevertheless, among 26 patients younger than 40 years of age treated with radial head resection for isolated radial head fractures, 81% were pain-free 25 years later, despite the presence in every case of mild-to-moderate osteoarthritis [8]. Ulnar variance at the wrist was increased in 22 patients, by a mean of 3.1 mm (range, 0–9 mm); the increase was greater than 5 mm in only 3 patients. Another study found similar results [7].

In a case-series study of 12 patients treated by arthroscopic radial head resection, including 1 with post-traumatic osteoarthritis, Menth-Chiari et al. [24] found that pain and motion range were nearly consistently improved after a mean follow-up of 39 months.

Isolated radial head resection is not recommended in patients with elbow instability or subluxation before or during surgery.

4.2.1.1.2. Radial head resection with interposition. This technique was described by Sears et al. [20] to treat problems such as humero-radial impingement with radio-capitellar osteoarthritis after an Essex-Lopresti fracture. A distal ulnar shortening osteotomy is performed concomitantly.

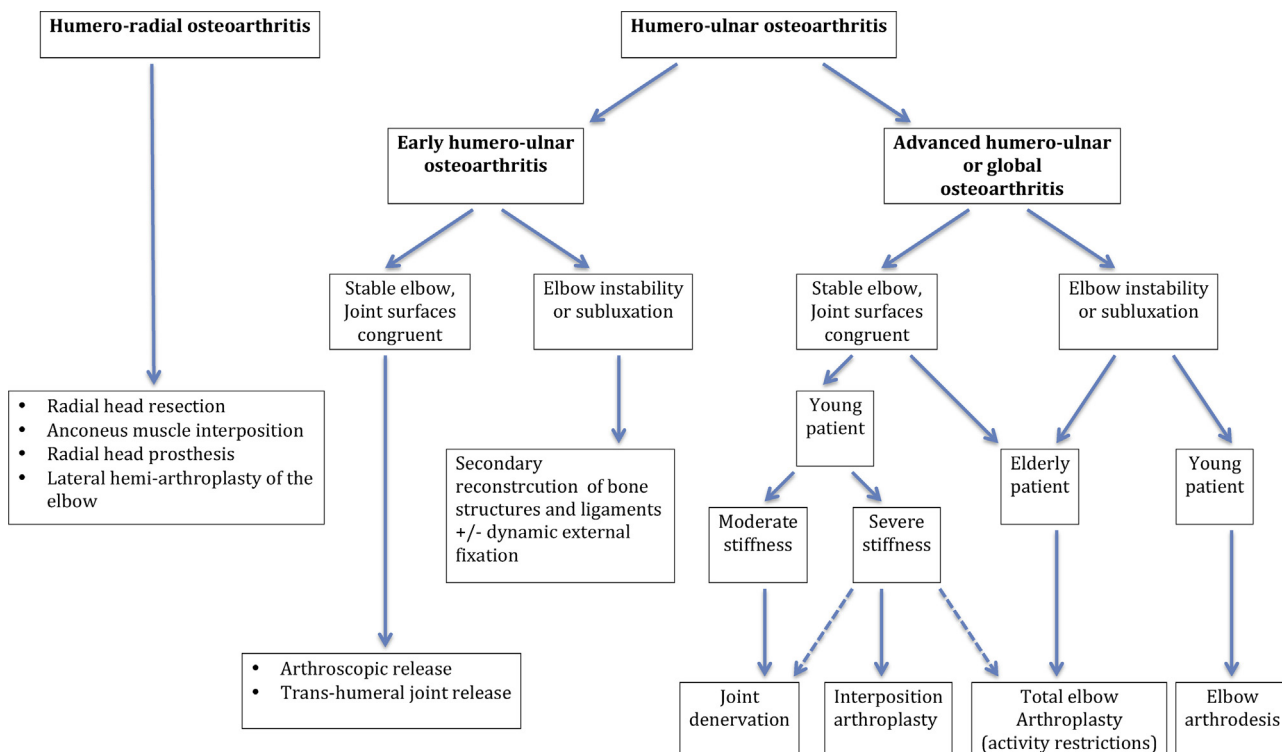


Fig. 3. Decision algorithm for surgical treatment in symptomatic post-traumatic elbow osteoarthritis refractory to non-operative management.

The anconeus muscle is detached distally and pedicled proximally, taking care to preserve its vessel and nerve supply. The muscle is then slipped between the proximal radius and the capitellum. In the small study by Broberg and Morrey [18], improved range of pronation-supination and pain relief were consistently obtained.

**4.2.1.2. Radial head arthroplasty with or without capitellum arthroplasty.** In patients with early humero-radial osteoarthritis, isolated radial head replacement can produce satisfactory results in the absence of severe condylar damage [13] (Fig. 4).

In a study by Shore et al. of 32 patients with radial head arthroplasty used to treat sequelae of radial head fractures [13], osteoarthritis was noted in 68% of cases after a mean follow-up of 8 years, although the results were good or excellent in 67% of cases. Thus, preoperative humero-ulnar osteoarthritis may progress at a slower rate after radial head replacement than after simple resection.

In patients with greater severity of the condylar lesions, lateral hemi-arthroplasty with condylar resurfacing and radial head replacement can be considered immediately or secondarily. Only short-term data are available. In a multicentre case-series study [25] including 9 patients with post-traumatic osteoarthritis managed with bipolar replacement or capitellar replacement, the outcomes after a mean follow-up of 23 months seemed satisfactory, with no instability or loosening, despite implant positioning errors or excessive implant size.

#### 4.2.2. Humero-ulnar osteoarthritis and global osteoarthritis

**4.2.2.1. Early humero-ulnar osteoarthritis with moderate stiffness and preserved stability.** Surgery is warranted in patients with incapacitating pain. The pain is usually due to osteophyte impingement at the end of the range of flexion and/or extension. The joint surfaces show little damage. Intra-articular foreign bodies may be present. In most cases, there is little or no limitation of the functional motion range. Adhesion release usually fails to restore the last few degrees of flexion or extension.

##### 4.2.2.1.1. Arthroscopic release.

**4.2.2.1.1.1. Principles.** In patients with major peri-articular scarring, the risk of poor visibility and of complications may contraindicate arthroscopic treatment. Arthroscopic joint release of the anterior and posterior compartments involves joint debridement, foreign body extraction, removal of osteophytes from the olecranon and coracoid process, and clearing of the olecranon and coracoid fossae.

At the end of the procedure, to avoid promoting serum extravasation, anterior capsulotomy at the upper third of the joint can be performed. However, in the post-traumatic elbow this procedure can result in complications, most notably nerve injuries, and is therefore considered undesirable by some authors [26].

**4.2.2.1.1.2. Results.** Most of the published data come from patients with lesions due to overuse injuries or degenerative disease [20]. Very few case-series studies included patients with post-traumatic osteoarthritis and moderate elbow stiffness [26,27].

The results seem similar in post-traumatic osteoarthritis and in osteoarthritis due to other causes. The pain is usually improved or completely resolved. The postoperative course is simpler than after open surgery.

In a study by Phillips and Strasburger [27] of 15 patients with a follow-up of 18 months, motion was improved in nearly all the patients. Fixed flexion decreased from 38° to 6° and flexion range increased from 117° to 135°. The study report does not mention the presence of osteoarthritic lesions. Kelly et al. [26] advised against arthroscopic radial head resection in patients with moderate-to-severe osteoarthritis of the humero-radial compartment. According to other authors and to our own experience, patients with little or no damage to the joint surfaces and with a predominance of

marginal osteophytes are more likely to experience good outcomes. No long-term data are available.

**4.2.2.1.2. Transhumeral joint release.** In 1978, Kashiwagi [28] described an original elbow release technique based on an idea by Outerbridge, as a treatment for stiffness due to degenerative disease. A posterior surgical approach is used, and the anterior compartment is accessed via a window fashioned between the two columns of the distal humerus. This technique is known as the Outerbridge-Kashiwagi procedure or ulno-humeral arthroplasty [20].

**4.2.2.1.2.1. Principles.** A posterior approach is used. After ulnar nerve release, a midline incision is made through the triceps, followed by a posterior capsular incision. Foreign bodies are extracted, the olecranon osteophyte is removed, and the olecranon fossa is cleared. The transhumeral window is delineated using a drill bit then cut out using an oscillating saw or trephine first then a gouge (Fig. 5). The window should be large enough to allow passage of the instruments, while preserving the columns and joint surfaces. Flexing the elbow provides access to the coronoid process. The anterior capsule is opened and partially resected. Postoperative mobilisation is started early.

**4.2.2.1.2.2. Results.** Hertel et al. [29] extended the indications of this procedure to post-traumatic patients and compared the outcomes to those seen in patients with degenerative elbow disease. A difference with the original technique is that the anterior capsulotomy is extended by passing on either side of the humeral columns. The case-series included 27 elbows in 26 patients, including 111 elbows with post-traumatic osteoarthritis and 6 with degenerative disease. Mean follow-up was 30 months. Postoperative pain intensity was unchanged, at a low level of 2.5/10 in the post-traumatic group compared to 6.7 to 5.8/10 in the degenerative-disease group. The range of flexion-extension increased from 66° to 100° in the post-traumatic group and from 79° to 102° in the degenerative-disease group. Radiological osteoarthritis progression was not seen in any of the patients.

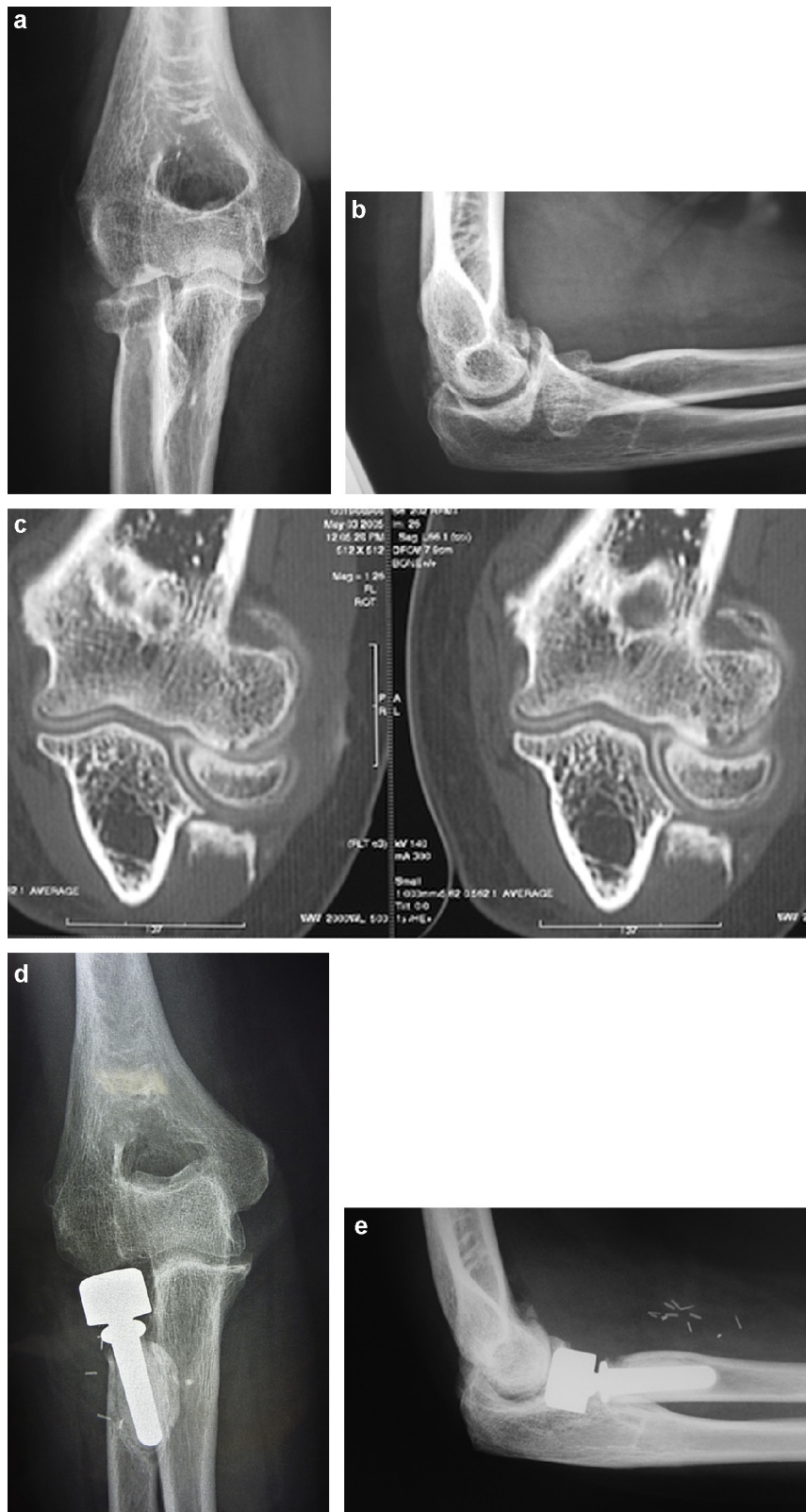Cohen et al. [30] compared open ( $n=18$ ) and arthroscopic ( $n=26$ ) debridement in patients with degenerative disease. After a follow-up of at least 12 months, pain relief was more marked in the arthroscopic group, whereas the motion range increase was greater in the open-surgery group.

Transhumeral joint release should be reserved for patients with moderate stiffness and pain at the end of the motion range, chiefly after distal humerus fractures. The surgical approach used is not appropriate for patients with severe stiffness.

**4.2.2.2. Early humero-ulnar osteoarthritis with severe stiffness and preserved elbow stability.** In this situation, conventional open joint release can be performed, either via two approaches, one medial and one lateral, as detailed by Judet in an instructional course lecture [31] or via a lateral approach according to the column procedure described by Sears et al. [20].

In the technique involving two approaches, in addition to the previous procedures, total anterior and posterior capsulectomy is performed, as well as on-demand section of the collateral ligaments, provided the middle heads of the epicondylar muscles are intact [31]. In these patients with severe stiffness, one of the main prognostic factors is osteoarthritis severity [32]. Despite good intra- and postoperative recovery of range of motion, the severe cartilage damage rapidly results in recurrent stiffness.

**4.2.2.3. Early osteoarthritis with moderate stiffness and elbow subluxation or instability.** In patients with damage to the humero-ulnar cartilage complicating chronic instability with valgus due to previous radial head resection, palliative radial head arthroplasty can ensure stabilisation. Nevertheless, osteoarthritis progression

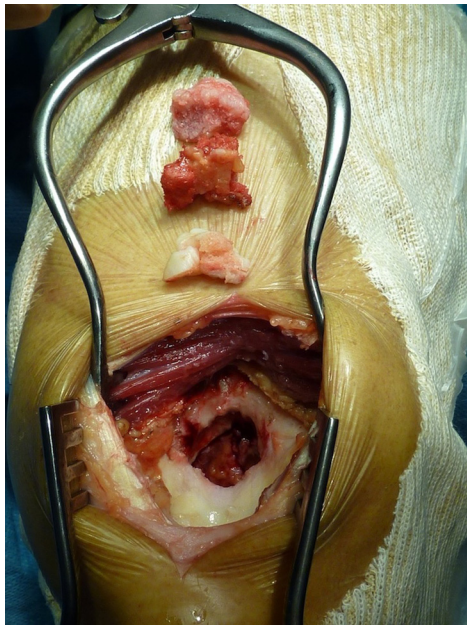


**Fig. 4.** a–e: painful osteoarthritis related to radial head malunion with posterior inter-osseous nerve compression in a 59-year-old woman. Radial head replacement and radial tunnel release. Sustained pain relief 8 years later.

is common after this revision procedure (68% of cases in a study by Shore et al. [13]).

Incompletely reduced fracture-dislocation of the elbow is among the lesions associated with the shortest times to

osteoarthritis development. These cases are also among the most difficult to treat secondarily, not only because of the cartilage damage sustained during the initial injury, but also and above all because of the persistent subluxation [33]:



**Fig. 5.** Transhumeral joint release. Humeral window seen through the posterior surgical approach.

- at the early stage characterized by moderate cartilage damage, open reduction with reconstruction of the stabilizing bony structures is warranted (fixation or reconstruction of the coronoid process, radial head fixation or replacement) with on-demand reconstruction of the ligaments, most notably the lateral collateral ligament. External fixation with a hinged device to allow early safe mobilization is often required [34]. This difficult secondary surgical treatment is not sufficient to halt the progression of the osteoarthritic lesions but can ensure satisfactory function for a fairly long time;
- in the event of advanced osteoarthritis, if consistent with the patient's age and demand level, total arthroplasty can be performed if required by the severity of the pain [33].

**4.2.2.4. Advanced osteoarthritis.** Discordance between the clinical and radiological findings is common, and some patients tolerate very severe osteoarthritis without difficulty because they experience little or no pain and gradually adapt to the motion range reduction. Other patients, however, experience significant pain throughout the range of motion. Greater range of motion is associated with more severe pain. In younger patients, every effort should be made to use alternatives to joint replacement.

**4.2.2.4.1. Resurfacing arthroplasty with interposition.** Arthroplasty with interposition is an alternative to total joint replacement in young and active patients whose level of demand is not consistent with the limitations associated with total elbow replacement. The indication is advanced elbow osteoarthritis with severe motion range limitation. Pre-requisites include sufficient bone stock with intact humeral columns (Morrey's grades I and II [19]), an ulnar notch, and preserved coronoid and olecranon reliefs. Contraindications are inadequate bone stock, major deformity, severe instability, uncontrolled infection, use of walking aids, and use of the upper limbs for transfers. Although the results are often modest, this procedure allows subsequent surgery consisting in a second interposition procedure or in total joint replacement [20]. Instability and weakness are common postoperative problems,

whose risk increases with the extent of motion range restoration.

**4.2.2.4.2. Principles.** The resection should spare the columns. The amount resected should not be so large as to worsen the instability but should be sufficient to avoid recurrent painful stiffness of the elbow. The radial head can be preserved in order to increase the contact surface area, in the absence of motion limitation or pain during forearm rotation. The interposed tissue can consist of fascia lata, de-epithelialised skin, or allogeneic graft material (e.g., Achilles tendon). The tissue is placed in contact with the distal humerus, preferably on bleeding bone, then secured by trans-osseous sutures.

The joint can be protected by a dynamic external fixation system for 1 month to allow early mobilisation [34]. Alternatively, the elbow is immobilised for 2–4 weeks, after which a programme of gradual rehabilitation is started.

**4.2.2.4.3. Results.** In a large case-series of 45 patients, including 34 with post-traumatic osteoarthritis, treated with interposition arthroplasty with an Achilles tendon allograft and dynamic external fixation then followed-up for a mean of 6.0 years, Larson and Morrey [19] found only a minimal effect on pain, contrasting with a motion arc increase from 51° to 97°. The results were good or excellent in 13 patients, fair in 14, and poor in 11; 7 patients required revision surgery. Preoperative instability was of adverse prognostic significance and was not improved by reconstruction of the collateral ligaments.

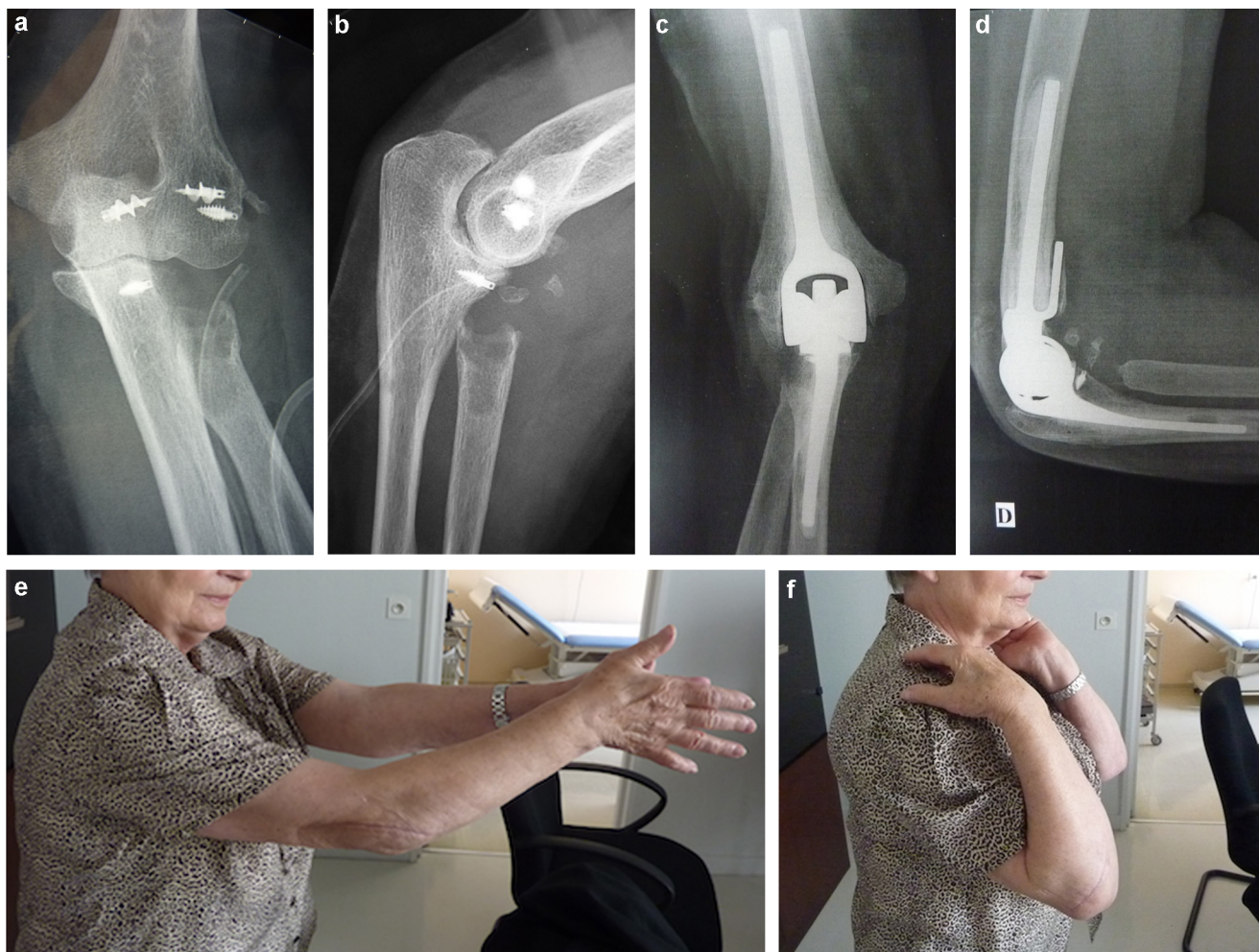Nolla et al. [35] used the same technique in 13 patients who were re-evaluated after a mean of 4 years. Only 38% of patients had good or excellent results. One third of patients had subluxation or dislocation, which resulted in poor outcomes. The motion arc improved from 48° to 110°. All the patients reported persistent pain, which was mild in 60% of cases. One patient experienced dislocation requiring arthrodesis.

**4.2.2.4.4. Total elbow arthroplasty.** Total elbow arthroplasty is the surgical procedure of last resort (Fig. 6). Because elbow prosthesis survival times are limited, total elbow arthroplasty is reserved for elderly patients and a very small number of carefully selected young patients. Partial arthroplasty using a convertible distal humeral implant has not yet been validated for use in post-traumatic osteoarthritis.

**4.2.2.4.4.1. Principles.** A posterior or lateral approach is used depending on the condition of the skin and on the osteoarticular lesions. A preoperative flap or skin expansion may be required. Multiple specimens should be collected in patients with a history of surgery on the elbow. The ulnar nerve is released and transposed anteriorly. Continuity of the extensor apparatus must be maintained, even in the absence of an olecranon. A disrupted extensor apparatus must be reconstructed. In patients who have intact ligaments and no deformities, a gliding prosthesis can be used. A design allowing for intra-operative conversion if needed can be chosen [36]. Absence of a condyle, condylar non-union, deformities, and/or ligament lesions often require the use of a semi-constrained prosthesis. The radial head is usually removed. Joint space height adjustment depends on the joint release performed, intra-operative mobility, and comparative measurements with the contra-lateral elbow.

Given the alterations in osteoarticular landmark position, the position of the prosthesis components in the horizontal plane should be determined based on the following:

- for the humerus, internal rotation of the elbow flexion-extension plane by  $14 \pm 4$  relative to the posterior aspect of the humeral shaft [37];



**Fig. 6.** a–f: sequelae of elbow fracture-dislocation after multiple surgical procedures in a 76-year-old woman. Total semi-constrained arthroplasty. Satisfactory outcome 2 years later.

- for the ulna, the trochlear ridge or, in patients with major remodeling, the flat portion of the posterior aspect of the ulna, which is perpendicular to the trochlear ridge [38].

**4.2.2.4.4.2. Results.** A case-series study of total elbow arthroplasty for post-traumatic osteoarthritis and chronic instability was reported at the 2004 SOFCOT symposium [39]. The 18 patients, including 12 with post-traumatic osteoarthritis, had a mean age of 54 years (range, 33–68 years) and a mean follow-up of 2 years. The clinical outcomes were satisfactory in 14 patients. Lucent lines were visible but loosening did not occur in any of the patients. Complications developed in 9 patients and required revision surgery in 5 (skin dehiscence,  $n = 1$ ; infection,  $n = 3$ ; and prosthesis disassembly,  $n = 1$ ).

Among 41 patients with a mean age of 57 years and a mean follow-up of 5 years 8 months after semi-constrained total elbow arthroplasty for post-traumatic osteoarthritis, 73% had little or no pain [40]. The motion arc improved from  $-40^\circ$  to  $118^\circ$  preoperatively to  $-27^\circ$  to  $131^\circ$  postoperatively. Complications occurred in 27% of patients; they were chiefly ascribable to mechanical wear related to physical activities and required revision surgery in 22% of cases.

Throckmorton et al. [41] found a 19% complication rate in 84 patients with post-traumatic osteoarthritis treated with total semi-constrained elbow arthroplasty then followed-up for a mean of 9 years. Among the complications, 75% occurred in patients

younger than 60 years of age. Infection was the leading cause of early failure, whereas late failures were due to component loosening or fracture. Among patients aged 40 years or younger studied by Celli and Morrey [42], the complication rate was 37% in the group with post-traumatic arthritis compared to 11% in the group with rheumatoid arthritis. Revision was required in 12 of 19 versus 7 of 30 cases in these two groups, respectively. Another case-series study compared outcomes after GSB-III prosthesis implantation in older patients with post-traumatic arthritis versus rheumatoid arthritis [43]. Mean age was 71 years versus 67 years and mean follow-up was 54 months. No differences in clinical or radiographic outcomes were found between the two groups. The patients reported a high level of satisfaction.

**4.2.2.4.5. Elbow arthrodesis.** Elbow arthrodesis is associated with the poorest functional tolerance among all arthrodesis procedures at the upper limb. This procedure is reserved for patients with severe post-traumatic osteoarthritis responsible for pain and major stiffness. It may be considered in the following situations:

- history of severe infection with a high risk of reactivation;
- young patient seeking a high level of elbow stability and strength;
- revision surgery for failure or complications of elbow arthroplasty;
- elbow deficit or severe neuromuscular defects.



There is no optimal position. To facilitate prehension, 90° of flexion is the least unfavourable position. Preoperative tests with an adjustable elbow brace are used to determine whether immobilisation provides pain relief and which position is best. Correcting any limitation in the range of pronation-supination is important. The main complications are non-union and secondary fractures.

## 5. Future prospects

New treatment methods are being developed for patients with early cartilage damage and for younger patients with advanced osteoarthritis but no indication for joint replacement surgery.

### 5.1. Osteochondral transplant

A graft harvested from the non-weight-bearing part of the lateral femoral condyle is transplanted into the defect. To date, only lesions of limited size have been successfully treated using this technique. In 7 patients followed-up for 55 months, the preliminary clinical and radiological results seemed satisfactory [44].

### 5.2. Denervation of the elbow

No satisfactory surgical treatment is available for advanced osteoarthritis with pain, functional mobility, and no indication for arthroplasty (based on age and/or functional demand level). Joint denervation techniques have been proved effective at the wrist and proximal interphalangeal joints, with an about 70% decrease in pain intensity.

We performed an anatomic study of elbow innervation [45] as a preliminary to the development of a standardised surgical procedure for complete or compartmental elbow denervation. The objective is to substantially decrease pain intensity without altering mobility. The preliminary results are encouraging and often allow postponement of joint replacement surgery.

## Disclosure of interest

The author declares that he has no conflicts of interest concerning this article.

## References

- [1] An KN, Kwak BM, Chao EY, Morrey BF. Determination of muscle and joint forces: a new technique to solve the indeterminate problem. *J Biomech* 1984;106:364–7.
- [2] Chadwick EK, Nicol AC. Elbow and wrist joint contact forces during occupational pick and place activities. *J Biomech* 2000;33:591–600.
- [3] Guitton TG, Zurakowski D, van Dijk NC, Ring D. Incidence and risk factors for the development of radiographic arthrosis after traumatic elbow injuries. *J Hand Surg Am* 2010;35:1976–80.
- [4] Broberg MA, Morrey BF. Results of delayed excision of the radial head after fracture. *J Bone Joint Surg Am* 1986;68:669–74.
- [5] Doornberg JN, van Duijn PJ, Linzel D, Ring DC, Zurakowski D, Marti RK, et al. Surgical treatment of intra-articular fractures of the distal part of the humerus. Functional outcome after twelve to thirty years. *J Bone Joint Surg Am* 2007;89:1524–32.
- [6] Herbertsson P, Josefsson PO, Hasselius R, Karlsson C, Besjakov J, Karlsson M, et al. Uncomplicated Mason type-II and III fractures of the radial head and neck in adults. A long-term follow-up study. *J Bone Joint Surg Am* 2004;86-A:569–74.
- [7] Iftimie PP, Calmet Garcia J, de Loyola Garcia Forcada I, Gonzalez Pedrouzo JE, Gine Goma J. Resection arthroplasty for radial head fractures: long-term follow-up. *J Shoulder Elbow Surg* 2011;20:45–50.
- [8] Antuña SA, Sanchez-Marquez JM, Barco R. Long-term results of radial head resection following isolated radial head fractures in patients younger than forty years old. *J Bone Joint Surg Am* 2010;92:558–66.
- [9] Ikeda M, Sugiyama K, Kang C, Takagaki T, Oka Y. Comminuted fractures of the radial head. Comparison of resection and internal fixation. *J Bone Joint Surg Am* 2005;87:76–84.
- [10] Harrington IJ, Sekyi-Otu A, Barrington TW, Evans DC, Tuli V. The functional outcome with metallic radial head implants in the treatment of unstable elbow fractures: a long-term review. *J Trauma* 2001;50:46–52.
- [11] Burkhart KJ, Mattyasovszky SG, Runkel M, Schwarz C, Kuchle R, Hessmann MH, et al. Mid- to long-term results after bipolar radial head arthroplasty. *J Shoulder Elbow Surg* 2010;19:965–72.
- [12] Judet T, Garreau de Loubresse C, Piriou P, Charnley G. A floating prosthesis for radial head fractures. *J Bone Joint Surg Br* 1996;78:244–9.
- [13] Shore BJ, Mozzon JB, MacDermid JC, Faber KJ, King GJ. Chronic post-traumatic elbow disorders treated with metallic radial head arthroplasty. *J Bone Joint Surg Am* 2008;90:271–80.
- [14] Rochet S, Obert L, Lepage D, Lemaire B, Leclerc G, Garbuio P. Proximal ulna comminuted fractures: fixation using a double-plating technique. *Orthop Traumatol Surg Res* 2010;96:734–40.
- [15] Papandrea RF, Morrey BF, O'Driscoll SW. Reconstruction for persistent instability of the elbow after coronoid fracture-dislocation. *J Shoulder Elbow Surg* 2007;16:68–77.
- [16] Milbrandt TA, Copley LA. Common elbow injuries in children: evaluation, treatment, and clinical outcomes. *Curr Opin Orthop* 2004;15:286–94.
- [17] Morrey BF, An KN. Functional evaluation of the elbow. In: Morrey BF, editor. *The elbow and its disorders*. Philadelphia: WB Saunders; 2000. p. 82–3.
- [18] Broberg MA, Morrey BF. Results of treatment of fracture-dislocations of the elbow. *Clin Orthop Relat Res* 1987;216:109–19.
- [19] Larson AN, Morrey BF. Interposition arthroplasty with an Achilles tendon allograft as a salvage procedure for the elbow. *J Bone Joint Surg Am* 2008;90:2714–23.
- [20] Sears BW, Puskas GJ, Morrey ME, Sanchez-Sotelo J, Morrey BF. Post-traumatic elbow arthritis in the young adult: evaluation and management. *J Am Acad Orthop Surg* 2012;20:704–14.
- [21] Morrey BF, Askew LJ, Chao EY. A biomechanical study of normal functional elbow motion. *J Bone Joint Surg Am* 1981;63:872–7.
- [22] Vasen AP, Lacey SH, Keith MW, Shaffer JW. Functional range of motion of the elbow. *J Hand Surg Am* 1995;20:288–92.
- [23] van Brakel RW, Eygendaal D. Intra-articular injection of hyaluronic acid is not effective for the treatment of post-traumatic osteoarthritis of the elbow. *Arthroscopy* 2006;22:1199–203.
- [24] Menth-Chiari WA, Ruch DS, Poehling GG. Arthroscopic excision of the radial head: clinical outcome in 12 patients with post-traumatic arthritis after fracture of the radial head or rheumatoid arthritis. *Arthroscopy* 2001;17:918–23.
- [25] Giannicola G, Sacchetti FM, Postacchini R, Postacchini F. Hemilateral resurfacing arthroplasty in post-traumatic degenerative elbow resulting from humeral capitellum malunion. *J Shoulder Elbow Surg* 2010;19:e12–7.
- [26] Kelly EW, Bryce R, Coghlan J, Bell S. Arthroscopic debridement without radial head excision of the osteoarthritic elbow. *Arthroscopy* 2007;23:151–6.
- [27] Phillips BB, Strasburger S. Arthroscopic treatment of arthrofibrosis of the elbow joint. *Arthroscopy* 1998;14:38–44.
- [28] Kashiwagi D. Intra-articular changes of the osteoarthritic elbow, especially about the fossa olecrani. *J Jpn Orthop Assoc* 1978;52:1367–82.
- [29] Hertel R, Pisan M, Lambert S, Ballmer F. Operative management of the stiff elbow: sequential arthrolysis based on a transhumeral approach. *J Shoulder Elbow Surg* 1997;6:82–8.
- [30] Cohen AP, Redden JF, Stanley D. Treatment of osteoarthritis of the elbow: a comparison of open and arthroscopic debridement. *Arthroscopy* 2000;16:701–6.
- [31] Judet T. L'arthrolyse dans les raideurs post-traumatiques du coude. In: *Conférences d'enseignement SOFCOT*. 2010. p. 333–49 [In French].
- [32] Mansat P, Morrey BF. The column procedure: a limited lateral approach for extrinsic contracture of the elbow. *J Bone Joint Surg Am* 1998;80:1603–15.
- [33] Mathew PK, Athwal GS, King GJ. Terrible triad injury of the elbow: current concepts. *J Am Acad Orthop Surg* 2009;17:137–51.
- [34] Judet R, Judet T. Arthrolyse et arthroplastie sous distracteur articulaire. *Rev Chir Orthop Reparatrice Appar Mot* 1978;64:353–65 [In French].
- [35] Nolla J, Ring D, Lozano-Calderon S, Jupiter JB. Interposition arthroplasty of the elbow with hinged external fixation for post-traumatic arthritis. *J Shoulder Elbow Surg* 2008;17:459–64.
- [36] Gramstad GD, King GJ, O'Driscoll SW, Yamaguchi K. Elbow arthroplasty using a convertible implant. *Tech Hand Up Extrem Surg* 2005;9:153–63.
- [37] Sabo MT, Athwal GS, King GJ. Landmarks for rotational alignment of the humeral component during elbow arthroplasty. *J Bone Joint Surg Am* 2012;94:1794–800.
- [38] Duggal N, Dunning CE, Johnson JA, King GJ. The flat spot of the proximal ulna: a useful anatomic landmark in total elbow arthroplasty. *J Shoulder Elbow Surg* 2004;13:206–7.
- [39] Mansat P, Chantelot C, Martinel V. Résultats des prothèses totales de coude dans les arthroses post-traumatiques et les instabilités chroniques. *Rev Chir Orthop Reparatrice Appar Mot* 2005;91(Suppl. 5) [2S80–2S83. In French].
- [40] Schneeberger AG, Adams R, Morrey BF. Semi-constrained total elbow replacement for the treatment of post-traumatic osteoarthritis. *J Bone Joint Surg Am* 1997;79:1211–22.
- [41] Throckmorton T, Zarkadas P, Sanchez-Sotelo J, Morrey B. Failure patterns after linked semi-constrained total elbow arthroplasty for post-traumatic arthritis. *J Bone Joint Surg Am* 2010;92:1432–41.

- [42] Celli A, Morrey BF. Total elbow arthroplasty in patients forty years of age or less. *J Bone Joint Surg Am* 2009;91:1414–8.
- [43] Amirfeyz R, Blewitt N. Mid-term outcome of GSB-III total elbow arthroplasty in patients with rheumatoid arthritis and patients with post-traumatic arthritis. *Arch Orthop Trauma Surg* 2009;129:1505–10.
- [44] Ansah P, Vogt S, Ueblacker P, Martinek V, Woertler K, Imhoff AB. Osteochondral transplantation to treat osteochondral lesions in the elbow. *J Bone Joint Surg Am* 2007;89:2188–94.
- [45] Winter W, Balaguer T, Coulet B, Lebreton E, Chammas M. Bases anatomiques de la technique de dénervation articulaire du coude. *Rev Chir Orthop Reparatrice Appar Mot* 2005;91(Suppl. 6):3S137.