



# Computer-assisted preoperative simulation for positioning and fixation of plate in 2-stage procedure combining maxillary advancement by distraction technique and mandibular setback surgery



Hideyuki Suenaga\*, Asako Taniguchi, Kazumichi Yonenaga, Kazuto Hoshi, Tsuyoshi Takato

Department of Oral-Maxillofacial Surgery, Dentistry and Orthodontics, The University of Tokyo Hospital, Tokyo, Japan

## ARTICLE INFO

### Article history:

Received 21 July 2016

Received in revised form

30 September 2016

Accepted 2 October 2016

Available online 4 October 2016

### Keywords:

Maxillary distraction osteogenesis

Orthognathic surgery

Maxillary positioning

Computer-assisted preoperative simulation

## ABSTRACT

**INTRODUCTION:** Computer-assisted preoperative simulation surgery is employed to plan and interact with the 3D images during the orthognathic procedure. It is useful for positioning and fixation of maxilla by a plate. We report a case of maxillary retrusion by a bilateral cleft lip and palate, in which a 2-stage orthognathic procedure (maxillary advancement by distraction technique and mandibular setback surgery) was performed following a computer-assisted preoperative simulation planning to achieve the positioning and fixation of the plate. A high accuracy was achieved in the present case.

**PRESENTATION OF CASE:** A 21-year-old male patient presented to our department with a complaint of maxillary retrusion following bilateral cleft lip and palate. Computer-assisted preoperative simulation with 2-stage orthognathic procedure using distraction technique and mandibular setback surgery was planned.

**DISCUSSION:** The preoperative planning of the procedure resulted in good aesthetic outcomes. The error of the maxillary position was less than 1 mm.

**CONCLUSION:** The implementation of the computer-assisted preoperative simulation for the positioning and fixation of plate in 2-stage orthognathic procedure using distraction technique and mandibular setback surgery yielded good results.

© 2016 The Author(s). Published by Elsevier Ltd on behalf of IJS Publishing Group Ltd. This is an open access article under the CC BY-NC-ND license (<http://creativecommons.org/licenses/by-nc-nd/4.0/>).

## 1. Introduction

Conventionally, one-stage 2-jaw surgery combined with Le Fort I osteotomy and mandibular setback surgery is performed to treat maxillomandibular discrepancies in the cleft lip/palate patients [1]. The maxillary distraction procedure is routinely performed using the distractors like RED-II system and zürich pediatric maxillary distractors, to achieve maxillary bone advancement and soft tissue lengthening. In case of the patients with mandibular excess (prognathism), an additional mandibular setback surgery is required to achieve a better aesthetic outcome, occlusal relationship and stability. However, this procedure necessitate several months for consolidation.

**Abbreviations:** 3D, three-dimensional; CT, computed tomography; IMF, intermaxillary fixation; CAD/CAM, computer-aided design and manufacture.

\* Corresponding author at: Department of Oral-Maxillofacial Surgery, Dentistry and Orthodontics, The University of Tokyo Hospital, 7-3-1 Hongo, Bunkyo-ku, Tokyo 113-8655, Japan.

E-mail address: [suenaga-tyk@umin.ac.jp](mailto:suenaga-tyk@umin.ac.jp) (H. Suenaga).

<http://dx.doi.org/10.1016/j.ijscr.2016.10.004>

2210-2612/© 2016 The Author(s). Published by Elsevier Ltd on behalf of IJS Publishing Group Ltd. This is an open access article under the CC BY-NC-ND license (<http://creativecommons.org/licenses/by-nc-nd/4.0/>).

The recent development of computerized three-dimensional (3D) computed tomography (CT) has simplified the process 3D planning by incorporating a computer-assisted virtual surgical procedure, which is carried out during the real-time surgery procedure. This 3D planning enables the surgeon to interact with the 3D images and facilitate the positioning of Maxilla required for the fixation of the plate [2]. The first application of 3-dimensional (3D) imaging for the placement of five maxillary marking screws and intermaxillary fixation of prefabricated occlusal splint using the TBNavis-CMFS navigation system (Multifunctional Surgical Navigation System, Shanghai, China) was performed on six adult goats. This process included simulation surgery and image-guided distraction osteogenesis during the preoperative planning stage. This technique enabled to achieve a desired length of the unilateral mandibular body (10 mm) with great accuracy. In addition, it developed a protocol for navigation guided mandibular distraction osteogenesis procedure [3]. Subsequently, this technique was further enhanced by other researchers who were able to achieve highly accurate length and rotational corrections through this procedure [4]. Sun

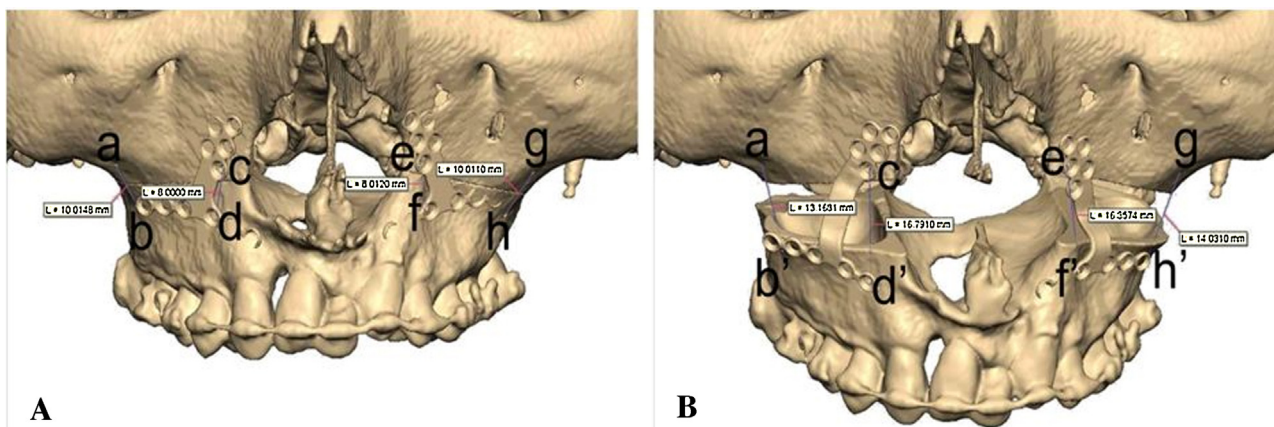


Fig. 1. Preoperative planning and simulation using the virtual titanium plate. A: Frontal views before the bone movement; B: Frontal views after the bones movement.

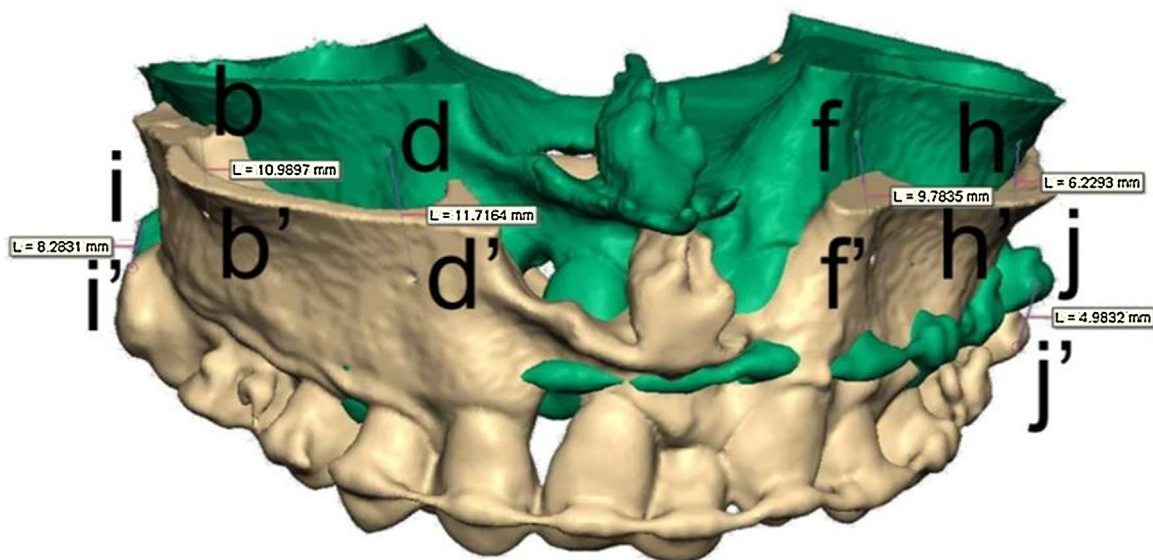


Fig. 2. Preoperative planning and simulation before and after the bone movement.

et al. [5] have also highlighted the importance of muscle pull influencing the postsurgical outcome in maxillomandibular surgery.

Here, we report a case wherein the computer-assisted preoperative simulation was carried out prior to the actual surgery through the 2-stage procedure employing distraction technique and mandibular setback surgery.

## 2. Presentation of case

A 21-year-old male patient presented to our department with a complaint of maxillary retrusion following bilateral cleft lip and palate. Computer-assisted preoperative simulation with 2-stage procedure combining maxillary advancement by employing distraction technique and mandibular setback surgery was planned. The patient was subjected to CT scan of the face using 320-row area detector CT scanner (Aquilion ONE, Toshiba, Tokyo, Japan), which acquired CT scans (slice thickness, 0.5 mm) of the maxilla. Based on the CT data, 3D surface models of the maxilla were constituted from image processing software (Mimics 16.0; Materialise, Leuven, Belgium). The cephalometric analysis and 3D planning were done using simulation software to obtain a normal profile and occlusal relationship. The 3D inspection and metrology of the maxilla was constituted using Geomagic Qualify (Geomagic, North Carolina, USA) and FreeForm plus 2014 software (Geomagic, North Carolina,

USA). The 3D models were built and superimposed through a fully automated voxel-wise method using the pre-surgery cranial base as reference. The 3D scanner (Rexcan DS2, Solutionix, Seoul, Korea) was used to obtain 3D surface data of the titanium plate (KLS Martin, Umkirch, Germany). The 3D surface data of titanium plate were imported to the Freeform Plus software (Rock Hill, USA).

In the preoperative simulation planning; the computer-assisted bone movement and positioning of the plate were carried out using 3D images (Fig. 1). The virtual Le Fort I osteotomy on the maxilla and forward movement of the virtual maxillary fragment was carried out using the Freeform Plus software. The hole was created using the virtual drill at the 3D position as computed by the preoperative simulation prior to the bone movement. The displacement distance between the points before and after the bone movement (Fig. 1A & B) and distance between the points which superimposed Lefort titanium plate of 11 mm (right) and 9 mm (left) were calculated using FreeForm plus software. (Fig. 2). In the second step, the mandible was moved backward till the occlusal relationship was achieved.

During the real-time surgery (1st stage) Lefort type I osteotomy was carried out and the zürich pediatric maxillary distractors were placed. The distractors were adjusted on a day to day basis and the predetermined advance movement of maxilla was obtained on the 23rd day. In the 2nd stage (i.e. on 23rd day) the distractor was

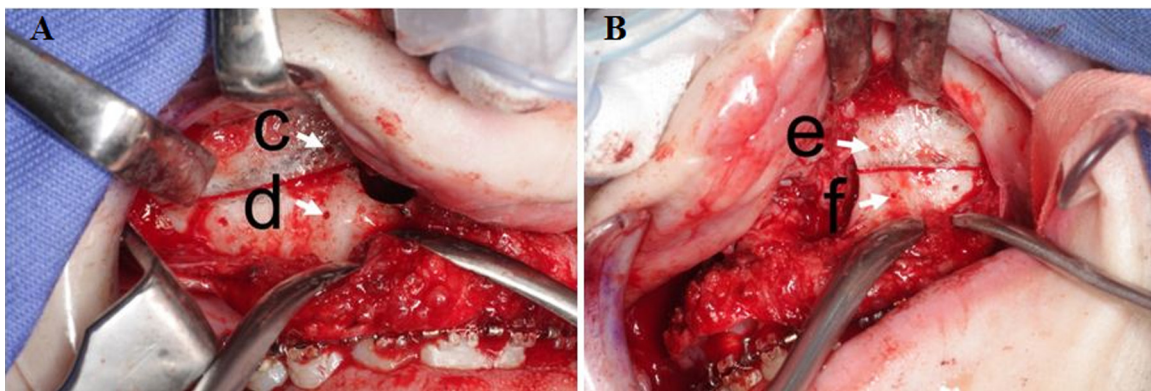


Fig. 3. Plate and screw position during the actual surgery. A: Right side views; B: Left side views.

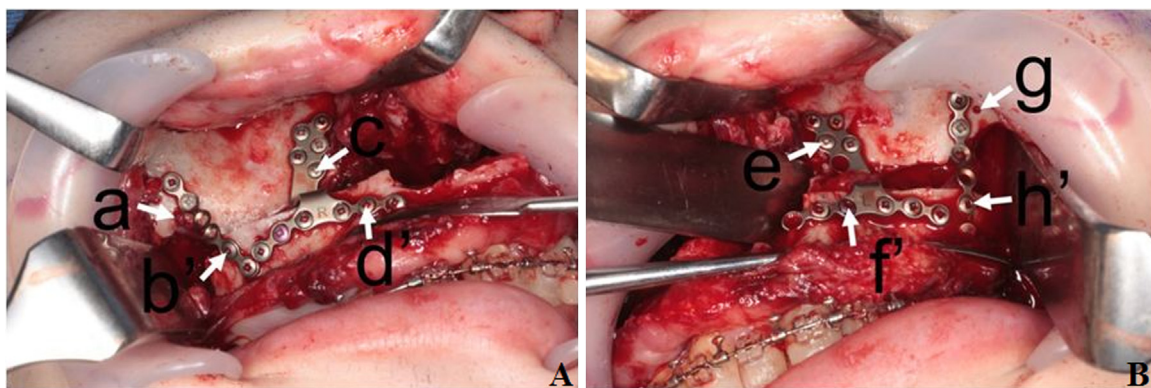


Fig. 4. Plate and screw position during the actual surgery. A: Right side views; B: Left side views.

removed and the maxillary bone was fixed using Lefort titanium plate (one Lefort plates of 9 mm, one Lefort plates of 11 mm and two Lefort plates). This enabled holding the maxilla at its advanced position and kept it stable by fixing the titanium plated to the screw holes created at the pre-designated site. The mandibular setback surgery (intraoral vertical ramus osteotomy) was performed, which manipulated the mandible and maxilla to obtain a planned normal occlusal relationship. The plate and screw position during the actual surgery and after the completion has been shown in Figs. 3–4.

The accuracy of the simulation results was analyzed using “3D comparison” with Geomagic Qualify (Rock Hill, USA). The cranial base and zygomatic arch were used as base to superimpose the virtual plan and postoperative scan images as the base bone were unaltered during the surgery. The differences between the virtual plans and postoperative results are shown in Fig. 5. In Fig. 3A and B, the arrows show the screw positions prior to the movement of the bone while the arrows in Fig. 4A and B show the screw positions after the movement of the bone. The error of the maxillary position was noted to be less than 1 mm. The preoperative planning employing a virtual plate was found to be more reliable and less time consuming. The required time for virtual surgical planning was about 60 min.

### 3. Discussion

Distraction osteogenesis is an accepted treatment option in the complex craniofacial deformities. Patients with congenital deformity and severe trauma often present with complex 3-dimensional (3D) soft and hard tissue deformities. The surgical intervention in these patients involves the immediate need for an advanced CT scan to visualize the vital anatomical structures and measurement of bony deformities with high accuracy, which is essential for per-

forming a surgery without causing injury to the vital structures (nerve and vessels). At the same time, the surgeon can simulate and manipulate the 3D image to facilitate appropriate treatment planning required to determine the most favourable osteotomy site that can yield the desired outcome and avoid any complications.

The planning of craniomaxillofacial distraction osteogenesis and its surgical outcome has become more predictable owing to the 3D simulation [6,7]. However, the computer-assisted planning is accompanied by several problems including factors that hinder the generation of the surgical outcomes despite the 3D planning based on muscular pull and mastication and prebending of the fixator devices. Therefore, the navigation guided surgery is required for the craniomaxillofacial deformity correction [8,9].

Cai et al. [3] performed a navigation-assisted distraction osteogenesis in six adult goats, wherein five titanium screws were placed in the maxillary alveolus as navigation markers, and four intermaxillary screws were placed for the intraoperative intermaxillary fixation (IMF) using the TBNavis-CMFS navigation system (Multifunctional Surgical Navigation System, Shanghai, China). They achieved intraoperative registration accuracy within 1 mm and the hemimandibular mean length was 10.02 mm (range 9.89–10.12). None showed significant differences between the simulation distraction and postoperative 3D measurements ( $P > 0.05$ ) [3]. This animal study was a preliminary protocol for the navigation guided mandibular distraction osteogenesis. Simpson et al. [4] performed the modified conventional technique in a laboratory using plastic phantoms, and conducted a pilot clinical study involving five patients, which yielded good outcome in terms of length and rotational errors (average correction errors of  $< 2^\circ$  total rotation and  $< 0.5$  mm total lengthening). The study results were clinically acceptable and not associated with any complications. This was possible by fixating the distressed bone with a mechanical fixa-

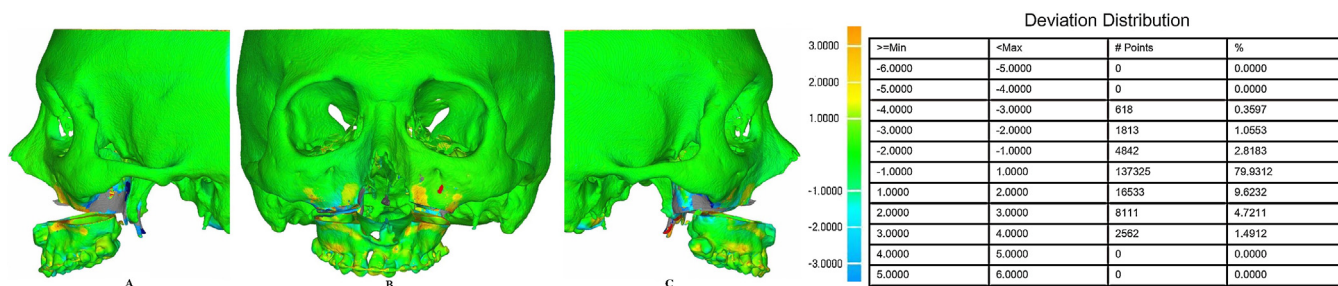


Fig. 5. Distance maps to visualize the distances between pre- and post-CT scan. A: Left side views; B: Frontal views; C: Right side views.

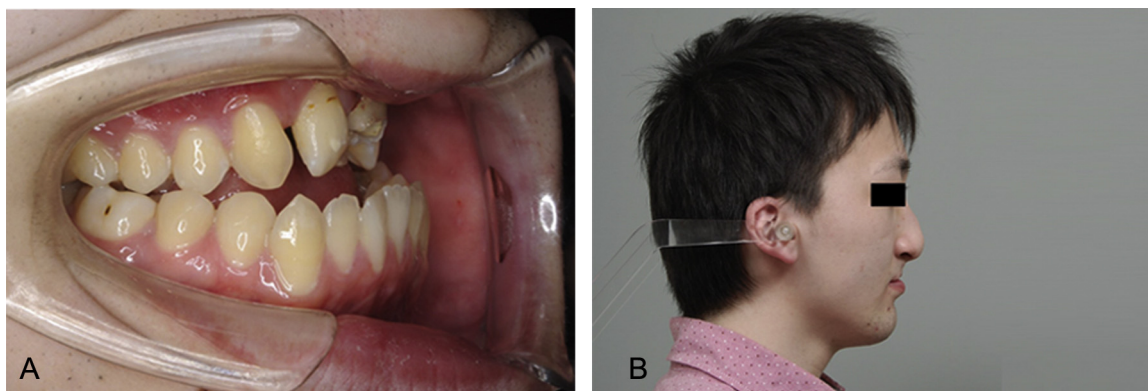


Fig. 6. Clinical photographs. A. Preoperative photograph; B. Preoperative Right side views.

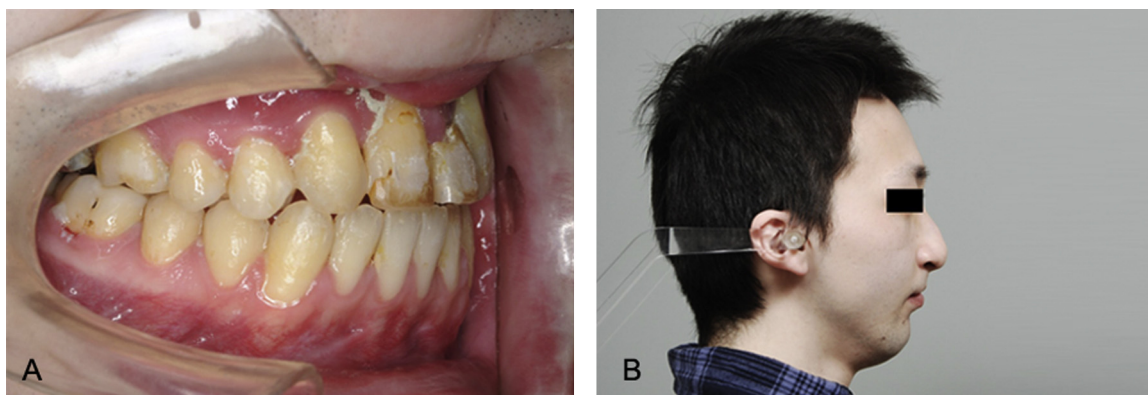


Fig. 7. Clinical photographs. A. Postoperative photograph; B. Postoperative Right side views.

tor, and carrying out the bone distraction according to the desired outcome.

Sun et al. [5] conducted a study to investigate the errors in the computer-aided designing and computer-aided manufacturing (CAD/CAM) method of unidirectional mandibular distraction osteogenesis in six patients with hemifacial microsomia. They found that the 3-dimensional superimposition of the preoperative simulation, and postoperative actual models at the end of consolidation had mean (SD) error between the actual and the predicted height of the ramus, which was noted to be 0.6(0.6) mm. In addition, the error between the actual and predicted intercondylar distance was 8.1 (2.1) mm. A significant difference was noted in the intercondylar distance between the simulated and actual groups ( $p=0.00024$ ). It was concluded that 3-dimensional CT-based planning results in the actual surgical outcome besides the pull by the lateral pterygoid muscle and pseudarthrosis. The intercondylar distance decreased compared with the predicted value. Therefore, the authors recommend the consideration of the various influential factors should while planning [5].

The computer-assisted surgery allows an intraoperative guidance for osteotomies in addition to the placement of the devices close to the vital structures [10]. However, the non-specificity of the tools leads to the lack of precision in the techniques [11]. d'Hauthuille et al. [12] compared two computer assisted surgical techniques to guide a mandibular distraction osteogenesis procedure. In addition, they showed that the osteogenesis vector estimation could be calculated during the procedure and reproduced with a higher degree of accuracy utilizing the present technology (Figs. 6–7).

#### 4. Conclusion

Although both one-stage 1and 2-stage procedure have been used for the correction in patients with maxillary retrusion by cleft lip and palate, the authors believe that the computer-assisted preoperative simulation for positioning and fixation of plate in 2-stage procedure combining maxillary advancement by distraction technique and mandibular setback surgery proves to be highly accurate

and in agreement with the previous reports. [5,10–12] It has several advantages over the conventional orthognathic surgery and has proved to be superior over them. Satisfactory results of the procedures with high degree of accuracy and better results make this procedure a much preferred one over the other. The operation time in this surgery is much shorter than some orthognathic procedures. Although the follow-up is more extensive, it is a most preferred method as it is easier and safer than the other conventional methods. The authors do mention that the finding and long term follow up data need to be confirmed by larger long-term studies in future. The conventional orthognathic surgery techniques tend to have a harmful impact including depression. On the other hand, Satisfaction with Life Score (SWLS) and quality of life is significantly improved in the 2-stage procedure. Although the surgical treatment initially decreases the level of confidence in patients, it produces more satisfaction in comparison to the conventional orthognathic surgery in the long run.

#### Author note

We have adhered to the SCARE Guideline, consisting of a 14-item checklist that will improve the reporting quality of surgical case reports [13].

#### Conflict of interest

None.

#### Funding

None.

#### Consent

Written informed consent was obtained from the patient for publication of this case report and accompanying images.

#### Author contribution

All authors have contributed equally in study concept or design, data collection, data analysis or interpretation and writing this paper.

#### Guarantor

Hideyuki Suenaga.

#### References

- [1] Y. Mori, T. Eguchi, M. Matsuzaki, Y. Ogihara, T. Susami, D. Chikazu, et al., A 2-stage procedure combining maxillary advancement by distraction technique with mandibular setback surgery in patients with cleft lip and palate, *Int. J. Oral Maxillofac. Surg.* 35 (2006) 594–597.
- [2] S. Mazzoni, G. Badiali, L. Lancellotti, L. Babbi, A. Bianchi, C. Marchetti, Simulation-guided navigation: a new approach to improve intraoperative three-dimensional reproducibility during orthognathic surgery, *J. Craniofac. Surg.* 21 (2010) 1698–1705.
- [3] M. Cai, G. Shen, A.H. Cheng, Y. Lin, D. Yu, M. Ye, Navigation-assisted mandibular body distraction osteogenesis: a preliminary study in goats, *J. Oral Maxillofac. Surg.* 72 (2014) 168, e1–e7.
- [4] A.L. Simpson, B. Ma, B. Slagel, D.P. Borschneck, R.E. Ellis, Computer-assisted distraction osteogenesis by Ilizarov's method, *Int. J. Med. Robot. Comput. Assist. Surg.* 4 (2008) 310–320.
- [5] H. Sun, B. Li, Z. Zhao, L. Zhang, G.F. Shen Steve, X. Wang, Error analysis of a CAD/CAM method for unidirectional mandibular distraction osteogenesis in the treatment of hemifacial microsomia, *Br. J. Oral Maxillofac. Surg.* 51 (2013) 892–897.
- [6] A. Varol, S. Basa, The role of computer-aided 3D surgery and stereolithographic modelling for vector orientation in premaxillary and trans-sinusoidal maxillary distraction osteogenesis, *Int. J. Med. Robot. Comput. Assist. Surg.* 5 (2009) 198–206.
- [7] M. Robiony, I. Salvo, F. Costa, N. Zerman, C. Bandera, S. Filippi, et al., Accuracy of virtual reality and stereolithographic models in maxillofacial surgical planning, *J. Craniofac. Surg.* 19 (2008) 482–489.
- [8] M. Heiland, P. Pohlentz, M. Blessmann, H. Werle, M. Fraederich, R. Schmelzle, et al., Navigated implantation after microsurgical bone transfer using intraoperatively acquired cone-beam computed tomography data sets, *Int. J. Oral Maxillofac. Surg.* 37 (2008) 70–75.
- [9] M. Heiland, C.R. Habermann, R. Schmelzle, Indications and limitations of intraoperative navigation in maxillofacial surgery, *J. Oral Maxillofac. Surg.* 62 (2004) 1059–1063.
- [10] R. Schmelzisen, R. Schon, A. Schramm, N.C. Gellrich, Computer-aided procedures in implantology, distraction and cranio-maxillofacial surgery, *Ann. R. Aust. Coll. Dent. Surg.* 16 (2002) 46–49.
- [11] J. Gateno, J.F. Teichgraber, J.J. Xia, Three-dimensional surgical planning for maxillary and midface distraction osteogenesis, *J. Craniofac. Surg.* 14 (2003) 833–839.
- [12] C. d'Hauthuille, F. Taha, B. Devauchelle, S. Testelin, Comparison of two computer-assisted surgery techniques to guide a mandibular distraction osteogenesis procedure. Technical note, *Int. J. Oral Maxillofac. Surg.* 34 (2005) 197–201.
- [13] R.A. Agha, A.J. Fowler, A. Saetta, I. Barai, S. Rajmohan, D.P. Orgill, The SCARE group, The SCARE statement: consensus-based surgical case report guidelines, *Int. J. Surg. Case Rep.* (2016) (article in press).

#### Open Access

This article is published Open Access at [sciedirect.com](http://sciedirect.com). It is distributed under the [IJSCR Supplemental terms and conditions](#), which permits unrestricted non commercial use, distribution, and reproduction in any medium, provided the original authors and source are credited.