

Leukocytoclastic vasculitis sparing a tattoo with halo effect

Chen (Amy) Chen, BA,^a Anar Mikailov, MD,^b Beverly Faulkner-Jones, MD, PhD,^c and Peggy A. Wu, MD, MPH^b
Boston, Massachusetts

Key words: leukocytoclastic vasculitis; palpable purpura; reverse Koebner phenomenon; sparing phenomenon; Wolf's isotopic nonresponse.

INTRODUCTION

The phenomenon of cutaneous diseases sparing sites of previous trauma has been described, although there are few case reports that illustrate this rare phenomenon. We report an unusual case of leukocytoclastic vasculitis (LCV) that completely spared tattooed skin with an additional halo effect around the tattoo.

CASE REPORT

A man in his 40s with recent intravenous drug use and hepatitis C was admitted to the medical intensive care unit with progressive respiratory failure in the setting of multifocal pneumonia, an epidural abscess, tricuspid valve endocarditis, oxacillin-sensitive *Staphylococcus aureus* bacteremia, and acute hepatorenal failure. Laboratory values on admission were notable for a white blood cell count of 20 K/ μ L, a hemoglobin level of 11.3 g/dL, international normalized ratio of 1.7, platelets of 30 K/ μ L, creatinine level of 6 mg/dL, and total bilirubin of 17.2 mg/dL. During his hospital stay, he received multiple antibiotics (levofloxacin, ceftriaxone, piperacillin-tazobactam, and nafcillin) and additional new medications (octreotide, pantoprazole, albumin, furosemide, lactulose). The patient had no known history of drug allergies. On day 5 postadmission, nonretiform, palpable purpura (Fig 1) developed consisting of well-defined, non-blanching, coalescing, 2- to 3-mm bright red to purple macules and papules primarily involving the legs. No splinter hemorrhages, stellate lesions, ulcerations, or blisters were noted. No additional symptoms were elicited, as the patient was intubated. Interestingly, the eruption exhibited a "sparing phenomenon," with a 2- to 3-cm halo of

Abbreviation used:

LCV: leukocytoclastic vasculitis

clinically normal skin around his tattoos (Fig 2, A and B). Laboratory data showed a hepatitis C viral load of 323,000 IU/mL. Cryoglobulins, antinuclear antibody, anti-neutrophil cytoplasmic antibodies, anti-mitochondrial antibody, and anti-smooth muscle antibody test results were all normal. A skin biopsy found a superficial perivascular neutrophilic infiltrate with sparse leukocytoclasia, red blood cell extravasation, and reactive vascular changes with complement C3 deposition, consistent with LCV (Fig 3). The etiology was presumed to be secondary to nafcillin, given the known association between penicillins and LCV¹ and the appearance of the rash 5 days after nafcillin was initiated. As a result, his nafcillin was discontinued and vancomycin started instead. By day 14 postadmission, the vasculitis was almost fully resolved without any further interventions.

DISCUSSION

LCV is an acute neutrophilic small vessel vasculitis resulting from vascular deposition of circulating immune complexes and subsequent activation of the complement cascade. This activation results in neutrophil chemotaxis and microvascular injury.² Clinically, LCV is characterized by palpable purpura, although less common findings can include urticarial plaques, vesicles, bullae, and pustules. LCV can be secondary to a variety of agents including medications, chemicals, infections, or underlying systemic disease; however, up to 60% of cases are idiopathic.²

From Harvard Medical School^a and the Departments of Dermatology^b and Pathology,^c Beth Israel Deaconess Medical Center. Funding sources: None.

Conflicts of interest: None declared.

Correspondence to: Peggy A. Wu, MD, MPH, Beth Israel Deaconess Medical Center, Department of Dermatology, 330 Brookline Avenue, Shapiro 2nd Floor, Boston, MA 02215-5400. E-mail: pwu2@bidmc.harvard.edu.

JAAD Case Reports 2015;1:269-71.

2352-5126

© 2015 by the American Academy of Dermatology, Inc. Published by Elsevier, Inc. This is an open access article under the CC BY-NC-ND license (<http://creativecommons.org/licenses/by-nc-nd/4.0/>).

<http://dx.doi.org/10.1016/j.jidcr.2015.06.002>

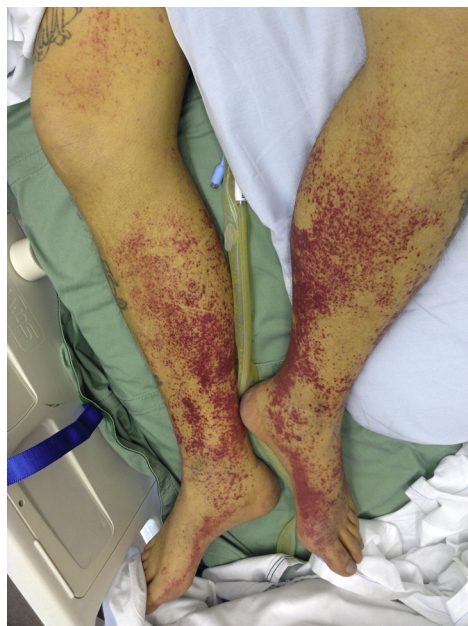

Fig 1. Extensive nonretiform palpable purpura on bilateral lower extremities.

Here we report, to our knowledge, an unusual case of LCV with sparing of tattooed skin to produce a “halo.” The phenomenon of one skin disease sparing the site of a previous skin condition has been recognized since 1981, when Cochran and Wilkin³ reported a case of a drug rash failing to appear in a previously irradiated site on a 12-year-old girl. Since then, various related terms have been used to describe this phenomenon, including the reverse Koebner phenomenon (nonappearance or disappearance of skin lesions at sites of trauma)⁴ and Wolf’s isotopic nonresponse (absence of a cutaneous eruption at the site of another unrelated and already healed skin disease).⁵ Although the exact mechanisms and pathophysiology behind these sparing phenomena are unknown, current hypotheses suggest that alterations in the local structure or immunologic microenvironment at these sites may play a role.⁶

To date, few articles report on sparing phenomenon in association with LCV. In 2011, Yadav et al⁷ reported a case of reverse Koebner phenomenon in a bandage-covered area in a patient with cutaneous small vessel immune complex vasculitis. The authors suggested that the sparing phenomenon may have been a result of diminished blood flow to the dermis secondary to mechanical pressure from the bandage and consequent failure of immune complex deposition. In 2014, Pinal-Fernandez and Solans-Laque⁸ reported a case of relative sparing of a purpuric rash over tattooed skin, although the purpuric rash still extended several centimeters into the area

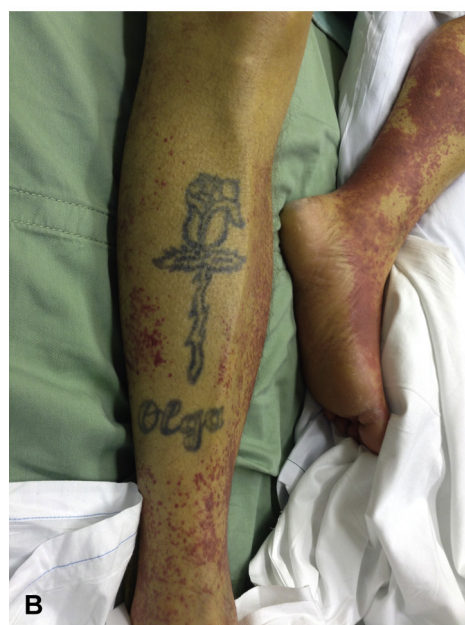
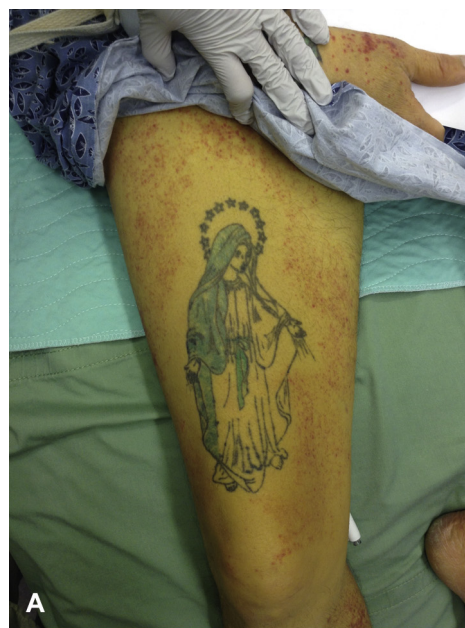
Fig 2. Palpable purpura exhibiting a “sparing phenomenon” with a 2- to 3-cm halo around a tattoo on the (A) right anterior thigh and (B) right anterior leg.

demarcated by the tattoo. The authors proposed several etiologic explanations for the sparing phenomenon over tattooed skin. These included the use of *Hamamelis virginiana*, a component of tattoo ink with known anti-tumor necrosis factor and anti-reactive oxygen species properties that may have had an inhibitory effect on the development of vasculitis, the potential of the tattoo dye to act as a photoprotective factor against light penetration into the dermis, and microvascular changes caused by tattooing.

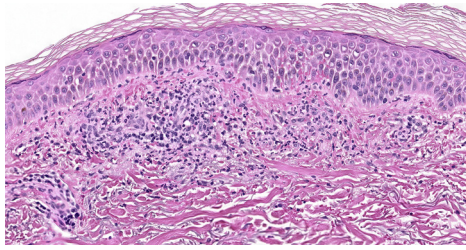


Fig 3. High-power image of a routine section. There is a superficial dermal and predominantly neutrophilic perivascular infiltrate with sparse leukocytoclasia and red blood cell extravasation, consistent with a leukocytoclastic vasculitis. (Hematoxylin and eosin stain; original magnification: $\times 290$.)

In this case, purpura not only spared the multiple tattoos but exhibited a unique halo effect of 2 to 3 cm of clinically normal skin surrounding the tattoos. The term *halo* is extrapolated from its use in the halo nevus where local immunologic changes account for perinevoid vitiligo. In the case of LCV, the halo effect could reflect local immunologic changes of the dermis caused by tattooing that inhibit neutrophil migration and subsequent cytokine cascade. The patient's tattoos were self-administered 20 years previously using ink made from burned plastic ashes, Colgate toothpaste, and Alberto VO5 shampoo. Fluoride in animal and human studies has been found to affect immune function through observed effects on T regulatory cells and neutrophils.^{9,10} Given the important role of neutrophil migration in effecting an immune response, we hypothesize that

the introduction of fluoride into the dermis through toothpaste may account for some degree of the observed halo effect. Distortion or destruction of postcapillary venules as a consequence of tattooing may also have a contributory effect. Further studies are required to elucidate the pathogenesis behind this novel phenomenon of LCV sparing a tattoo with halo effect.

REFERENCES

1. Wolkenstein P, Revuz J. Drug-induced severe skin reactions. Incidence, management and prevention. *Drug Saf.* 1995;13:56-68.
2. Lotti T, Ghersetich I, Comacchi C, Jorizzo JL. Cutaneous small-vessel vasculitis. *J Am Acad Dermatol.* 1998;39:667-687; quiz 688-690.
3. Cochran RJ, Wilkin JK. Failure of drug rash to appear in a previously irradiated site. *Arch Dermatol.* 1981;117:810-811.
4. Malakar S, Dhar S. Spontaneous repigmentation of vitiligo patches distant from the autologous skin graft sites: a remote reverse Koebner's phenomenon? *Dermatology.* 1998;197:274.
5. Wolf R, Brenner S, Ruocco V, Filioli FG. Isotopic response. *Int J Dermatol.* 1995;34:341-348.
6. Pakran J. Sparing phenomena in dermatology. *Indian J Dermatol Venereol Leprol.* 2013;79:545-550.
7. Yadav S, De D, Kanwar AJ. Reverse koebner phenomenon in leukocytoclastic vasculitis. *Indian J Dermatol.* 2011;56:598-599.
8. Pinal-Fernandez I, Solans-Laqué R. The 'sparing phenomenon' of purpuric rash over tattooed skin. *Dermatology.* 2014;228:27-30.
9. Bober J, Kucharsk E, Zawierta J, Machoy Z, Chlubek D, Ciechanowski K. The influence of fluoride ions in the viability, reduction of NBT, cytolysis, degranulation, and phagocytosis of human and rabbit neutrophils. *Fluoride.* 2000;33:108-114.
10. Hernandez-Castro B, Vigna-Perez M, Doniz-Padilla L, et al. Effect of fluoride exposure on different immune parameters in humans. *Immunopharmacol Immunotoxicol.* 2011;33:169-177.