View metadata, citation and similar papers at core.ac.uk
brought to you by CORE
provided by Elsevier - Publisher Connector

Eur J Vasc Endovasc Surg **20**, 177–182 (2000)
doi:10.1053/ejvs.1999.1051, available online at http://www.idealibrary.com on IDEAL®

Maximal Aneurysm Diameter Follow-up is Inadequate after Endovascular Abdominal Aortic Aneurysm Repair

J. J. Wever[1], J. D. Blankensteijn*[1], W. P. Th. M. Mali[2] and B. C. Eikelboom[1]

Departments of [1]Vascular Surgery and [2]Radiology, University Medical Center, Utrecht, The Netherlands

Background: *follow-up after endovascular abdominal aortic aneurysm repair (EAR) generally consists of serial diameter measurements. A size change after EAR, however, is the consequence of alterations of the excluded aneurysm sac volume.*
Objective: *to assess the agreement between diameter measurements and volume measurements after endovascular aneurysm repair.*
Patients and methods: *from 53 consecutive patients scheduled for EAR, follow-up of at least 6 months was available in 35 patients. CTA was performed on all patients at discharge, at 6 months and yearly thereafter. The resulting 113 datasets were processed on a workstation in a blinded and random order. Maximal aneurysm diameter (DMAX) was measured along the central lumen line. Total aneurysm volume was measured by manual segmentation. All measurements of an individual patient were compared with each other, resulting in 149 comparisons. The significance of individual size changes was classified based on the 95% confidence limits of the intra-observer variability, using difference-of-means analysis. DMAX changes were compared to volume changes.*
Results: *in 37% of the comparisons, discordance was found between DMAX and volume measurements. A decrease in aneurysm size was missed using DMAX in 14% of cases and an increase in 19% of cases.*
Conclusion: *aneurysm size changes after EAR are not noticed using maximal diameter measurements in over one-third of cases.*

Key Words: Endovascular aneurysm repair; Maximal diameter; Volume; Follow-up.

Introduction

Currently there is no clear definition of successful endovascular repair of an abdominal aortic aneurysm (EAR). Shrinkage of the excluded aneurysmatic sac in combination with the absence of endoleak is generally considered indicative of the aneurysm being protected from rupturing. Endoleak is demonstrated by visualisation of blood flow outside the graft but inside the aneurysm sac. However, completely excluded aneurysms can continue to grow. This may be caused by an unidentified endoleak, since the sensitivity of the detection methods for endoleak is not 100%. In this case, the aneurysm is probably at continued risk of rupture.[1] Measurement of aneurysm size during follow-up is therefore of great importance and it may be more important than detection of an endoleak.

Follow-up after EAR usually consists of serial maximal-diameter measurements. A size change after EAR, however, is a change in the volume of the aneurysm sac. Theoretically, maximal diameter measurements may fail to demonstrate all size changes of the aneurysm after exclusion. Consequently, it would make more sense to follow the volume of the excluded aneurysm sac but volume measurements are time-consuming and the availability of hardware and software to produce volume data is limited.

This study was performed to assess the agreement between maximal diameter measurements and volume measurements after EAR.

Methods

From January 1994 53 consecutive patients received an Ancure®/EVT endograft for an abdominal aortic aneurysm (AAA) (Guidant, Menlo Park, CA, U.S.A.). All patients with a follow-up of at least 6 months were included in this study, resulting in a study group of 35 patients. The reason for not reaching a follow-up period of 6 months was conversion in three patients, follow-up elsewhere in two patients and short duration of follow-up in 13 patients. The median age was 68

* Please address all correspondence to: J. D. Blankensteijn, Department of Vascular Surgery, G 04.232, University Medical Center, P.O. Box 85500, 3508 GA Utrecht, The Netherlands.

1078–5884/00/080177+06 $35.00/0 © 2000 Harcourt Publishers Ltd.

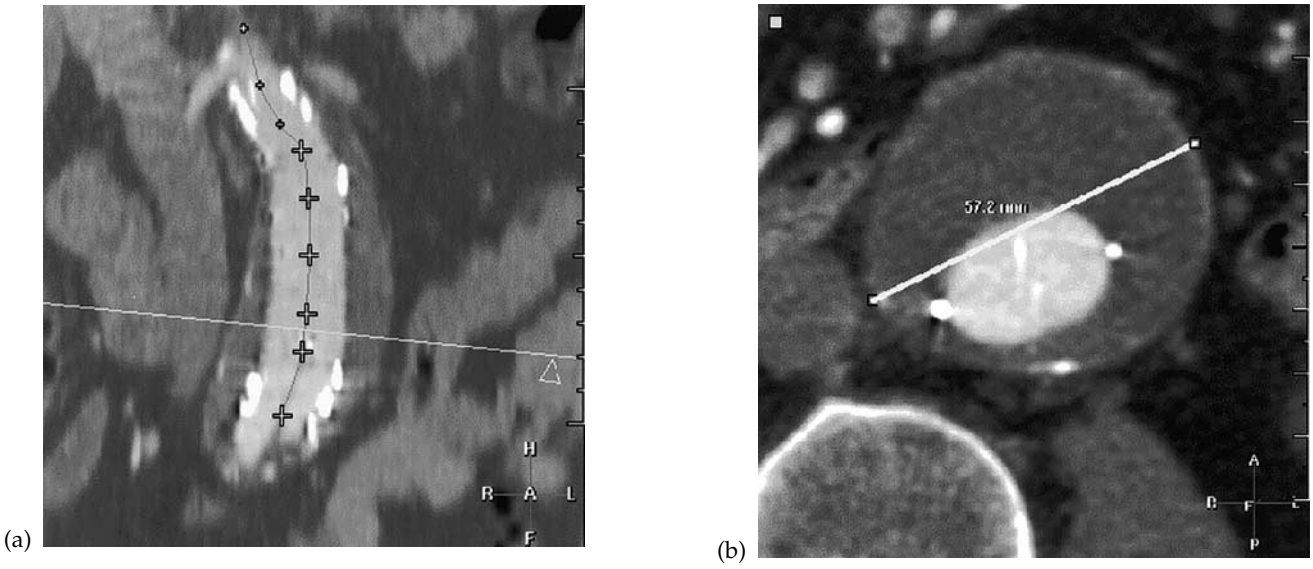

Fig. 1. (a) Drawing of the central lumen line. As well as drawing in the coronal plane, the central lumen line is also drawn in the sagittal and transverse plane. (b) Multiplanar reconstructions, perpendicular to the central lumen line, in which the DMAX measurements are performed.

years (IQ range 63–72). The male:female ratio was 7. Twelve tube-, 20 bifurcated and three aortomonoiliac grafts were implanted.

Helical computer tomographic angiography (CTA) was performed on all patients at discharge, at 6 months, and yearly thereafter. All data were acquired according to a standardised protocol using a Philips computed tomography (CT) scanner (Philips Medical Systems, Best, The Netherlands). Intravenous contrast, 140 ml, was administered at a rate of 3 ml per second, preceding scanning by 30 s. Scanning started at the level of the 12th thoracic vertebra, which is the presumed position of the coeliac trunk; 50–70 rotations of 1 second each were made. The collimation was set at 5 mm and the table speed at 5 mm per second, resulting in a pitch of 1. The length of the scanned volume was therefore at least 25 cm. The raw data were transferred to an Easy Vision workstation (Philips Medical Systems, Best, The Netherlands). The datasets were evaluated in a blinded and random order. A central lumen line was drawn manually through the lumen of the aorta by positioning points in the centre of the lumen in the axial, the sagittal and the coronal plane.[2] Multiplanar reformats, perpendicular to this central lumen line, were constructed (Fig. 1a and b). The maximal aneurysm diameter (DMAX) was measured in this reformatted set of images.

The aortic lumen was segmented using the threshold technique. The threshold was set to highlight the contrast-enhanced lumen and the vertebrae only.[3] Positioning a seeding point into the lumen enabled separation of the lumen from the rest of the thresholded voxels (Fig. 2). In areas of close contact, the aortic lumen and vertebrae were separated by hand-drawn cut-off lines. The volume of the contrast-enhanced lumen was reconstructed from the individually segmented axial slices, starting at the level immediately below the renal arteries and ending at the level of the native aortic bifurcation.

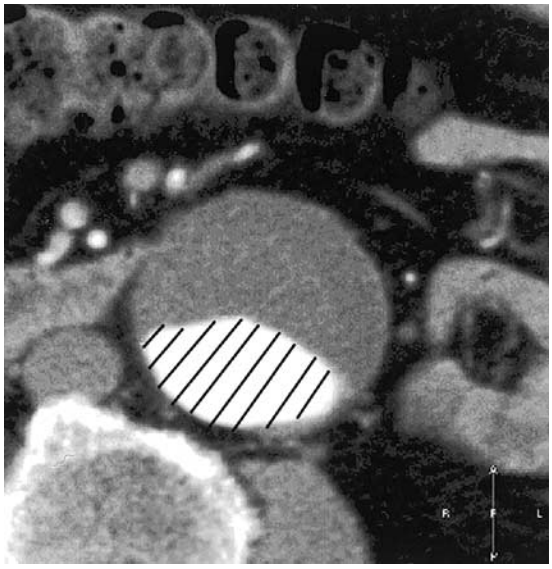

Fig. 2. Segmentation of the lumen part of the aneurysm.

Thrombus segmentation was fully manual (Fig. 3). A contour was drawn along the outer border of the thrombus on each slice. Segmentation of thrombus also started just below the level of the renal arteries and ended at the level of the native bifurcation. No

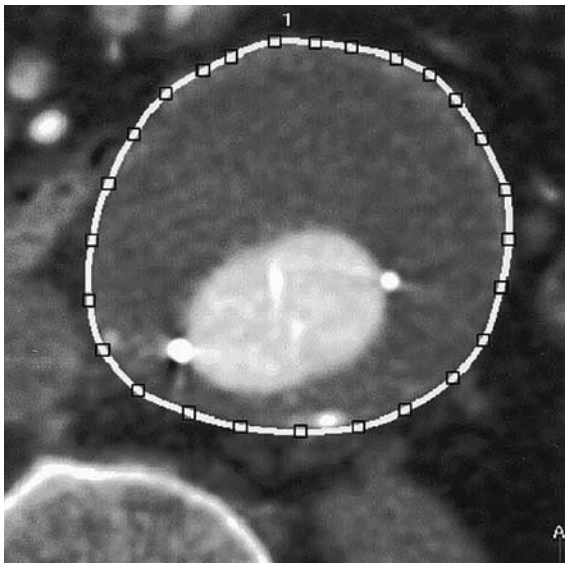

Fig. 3. Segmentation of the thrombus part of the aneurysm.

thrombus was found below this point. The result of this procedure was the volume of the thrombus plus the contrast-filled lumen within the thrombus. The actual thrombus volume was obtained by subtracting the volume of the contrast-filled lumen within the thrombus from the segmented thrombus volume.

All datasets of an individual patient were compared with each other. Changes in DMAX and volume were collected and classified based upon the 95% confidence limits of the intra-observer variability, according to Bland and Altman's difference-of-means analysis.[4] The repeatability coefficient (RC) used was 6.3% for maximal diameter and 3.2% for volume.[5] Size changes were classified as increase or decrease when exceeding the RC, and stable when not.

For all possible comparisons of datasets, changes of DMAX were compared to the concurrent changes of volume. In addition, interval-specific comparisons were made at 6 and 12 months for each patient.

In order to test the value of the most commonly used parameter for success, DMAX decrease, it was set out against volume changes. For normal 2×2 tables the results were divided into two groups: decrease in one group and stable or increase in the other, since the latter is an unsuccessful outcome of EAR. This enabled calculation of the sensitivity, specificity, positive-predictive value (PPV) and negative-predictive value (NPV) of decreasing maximal diameter compared to volume changes. For each table, the kappa value was calculated.

To indicate whether the volume measurements were more compatible with the endoleak status than the maximal diameter measurements, these were correlated with each other.

Results

There were nine patients with 6 months' follow-up, 17 patients with 12 months, four patients with 24 months, two patients with 36 months and three patients with 48 months of follow-up (Table 1). Comparison of the resulting 113 datasets produced 149 comparisons. Classification of volume changes showed an increase in 34, no change in 21 and a decrease in 94. Maximal diameter changes were classified as increased in six, stable in 67 and decreased in 76. The comparisons of DMAX and volume changes are shown in Table 2 and Figure 4. In 63% (94/149) of the comparisons, no discordance was seen between DMAX and volume. However, in 37% of the comparisons discordance was found (55/149). Decreasing volume was missed using diameter measurements in 14% (21/149) and increasing volume in 19% (29/149).

For the total of 149 comparisons, the sensitivity for detecting a decrease was 77% and the specificity 93%, accompanied by a PPV of 95% and a NPV of 70% (Table 3). When comparing individual patient data at 6 months (Table 4, Fig. 5), figures were 61%, 90%, 93% and 50%, respectively. Comparison at 12 months (Table 5, Fig. 6) showed a sensitivity of 90%, a specificity of 100%, a PPV of 100% and a NPV of 78%.

In our hospital, four patients of this study group with an initial endoleak were converted during follow-up because of a growing aneurysm. Two of these patients did not show an increase in maximal diameter, indicating that the decision to convert was based on the presence of an endoleak in combination with a volume increase.

There was poor correlation between the endoleak status and aneurysm growth, but the correlation between volume increase and endoleak was stronger ($r = 0.37$ at 6 months, $r = 0.25$ at 12 months) than the correlation between DMAX and endoleak ($r = -0.07$ and $r = 0.11$, respectively).

Discussion

Little is known about the use of volume measurements for follow-up of aneurysmal disease. Although the volumetric data from CTA are excellent for determination of aneurysm volume changes, volume measurements are very time-consuming and require accurate segmentation.[6]

Volume measurements are physically more logical to use, because changes can theoretically be encountered earlier. This is due to the fact that a change in three dimensions is reflected by a much smaller change in two dimensions.

Table 1. The available datasets for each individual patient and the possible comparisons.

	1	2	3	4	5	6	7	8	9	10	11	12	13	14	15	16	17	18	19	20	21	22	23	24	25	26	27	28	29	30	31	32	33	34	35	# sets
0 m	X	X	X	X	X	X	X	X	X	X	X	X	X	X	X	X	X	X	X	X	X	X	X	X	X	X	X	X	X	X	X	X	X	X	X	35
6 m	X	X	X	X	X	X	X	X	X	X	X	X	X	X	X	X	X	X	X	X	X	X	X	X	X	X			X	X	X	X	X	X		33
12 m	X	X	X	X	X	X	X	X	X	X	X	X	X	X	X	X	X	X	X	X	X	X	X	X	X	X	X	X	D	C	C					28
24 m	X	X	X	X	X	X	X	X	X	C																		D								9
36 m	X	X	X	X	X	X			X																											5
48 m	X	X	X	C																																3
# cmp	15	15	15	10	10	6	6	6	6	3	3	3	3	3	3	3	3	3	3	3	3	3	3	3	3	3	1	1	1	1	1	1	1	1	1	149

Armon *et al.* stated that the use of a one-dimensional measurement (diameter) to assess changes of a three-dimensional structure is a weakness in most studies, and that volumetric measurements using spiral CT are more accurate.[7]

In addition, most measurements performed for follow-up after EAR are diameter measurements on axial CT slices. These measurements show a considerably larger error as compared to measurements perpendicular to the vessel axis.[2,8,9] In the present study, all maximal diameter measurements were performed along the central lumen line.

Even using these more representative measurements perpendicular to the vessel axis, more than one-third of all volume changes are apparently not noticed using maximal diameter measurements. This can be explained partly by the fact that the measurements are influenced by patient-, equipment-, or technician-dependent factors when performing the CTA. For example, the position of the patient in the scanner may be different, the patient's blood pressure may be higher or lower, or the acquisition may differ from the previous scan. Also, the aneurysm sac may collapse on the lumbar spine when the patient is positioned supine on the CT table, even leading to an increase in maximal diameter in combination with decreasing volume. Probably the most important reason is, however, that maximal diameter only measures a small section of the aneurysm, while the majority of size changes involve the aneurysm sac as a whole. Therefore, volume was considered to be the most representative parameter to reflect morphologic aneurysm changes.

The 2×2 tables show a decreasing DMAX to be a good indicator of shrinkage of the excluded aneurysm (the PPV of decrease is 93% at 6 months and 100% at 12 months). On the basis of these data a follow-up strategy can be proposed. DMAX measurements are performed primarily; for diameter decrease more than $\pm 6\%$, no further measurement is necessary. If DMAX is inconclusive, volume measurements could be performed to determine more accurately the course the excluded aneurysm is taking.

In addition, the 2×2 tables at 6 and 12 months demonstrate improving test values of measuring maximal diameters over time. This indicates that DMAX changes need more time to reveal the changing volume than measuring volume itself. As such, at 6 months about half (15/33, Table 3) and about two-thirds (18/27, Table 4) at 12 months of patients can be reliably assured of having effective exclusion without using volume measurements.

The consequences of missing size changes of the

Table 2. The agreement between DMAX and volume for all comparisons.

		Volume			
		Decrease	Stable	Increase	Total
DMAX	Decrease	72	4	0	76
	Stable	21	17	29	67
	Increase	1	0	5	6
	Total	94	21	34	149

Kappa = 0.39.

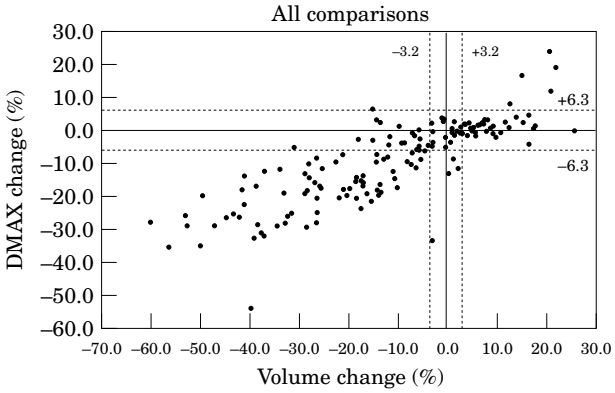

Fig. 4. Volume changes plotted against DMAX changes for all comparisons. The intra-observer limits are added to the graph.

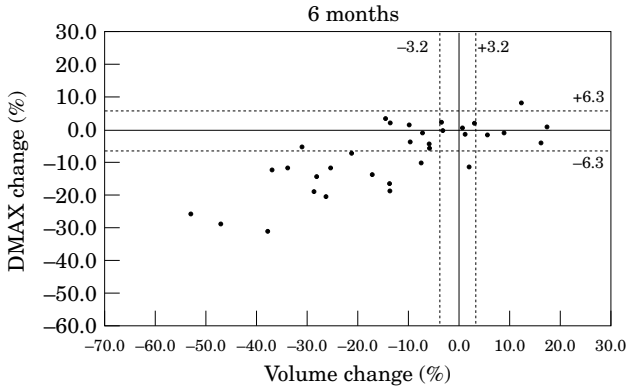

Fig. 5. Volume changes plotted against DMAX changes for the individual patients at 6 months of follow-up.

Table 3. The 2 × 2 table for all comparisons.

		Volume		
Comparisons		Decrease	Stable or increase	Total
DMAX	Decrease	72	4	76
	Stable or increase	22	51	73
	Total	94	55	149

Kappa = 0.65.

Table 4. The 2 × 2 table for the individual patients at 6 months.

		Volume		
6 months		Decrease	Stable or increase	Total
DMAX	Decrease	14	1	15
	Stable or increase	9	9	18
	Total	23	10	33

Kappa = 0.41.

aneurysm sac vary, depending on whether the sac actually decreases or increases. The more favourable of the two situations is missing a decrease, because the aneurysm sac will not, in fact, be at risk for rupture. However, the surgeon, not being aware of it, may call for unwarranted investigations and unnecessary reintervention. Missing aneurysm growth is potentially more dangerous because the aneurysm is still at risk for rupture, while the treatment appears successful.

An advantage of using volume measurements for follow-up is that any morphologic changes of the excluded aneurysm sac can be noticed. This is because volume measurements require 3-D reconstructions, on which morphologic changes can be appreciated, not showing in the volume figures. Also, volume meas-

Table 5. The 2 × 2 table for the individual patients at 12 months.

12 months		Volume		
		Decrease	Stable or increase	Total
DMAX	Decrease	18	0	18
	Stable or increase	2	7	9
	Total	20	7	27

Kappa = 0.82.

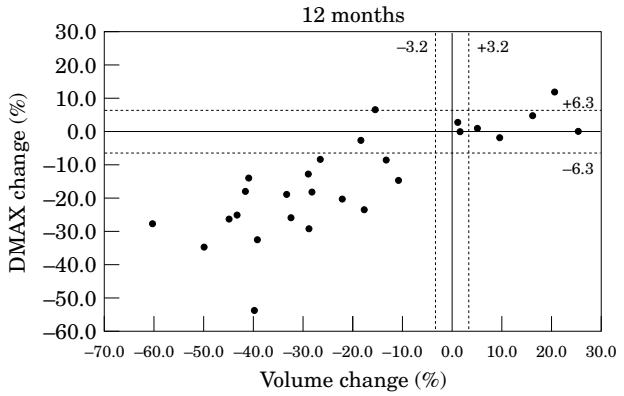

Fig. 6. Volume changes plotted against DMAX changes for the individual patients at 12 months of follow-up

urements show less variability compared to maximal diameter measurements and, therefore, have better reproducibility.[5] Disadvantages are that volume measurements are time-consuming and require advanced processing and measuring equipment. Currently it takes about 45 minutes to segment an aneurysm on the Philips workstation. Future development of automated volume-segmentation techniques will facilitate volume follow-up after EAR.[10]

In conclusion, volume follow-up provides a more accurate impression of the evolution of the aneurysm sac as compared to DMAX. Using DMAX follow-up only is therefore inadequate after endovascular AAA repair.

References

1 Malina M, Ivancev K, Chuter TA *et al.* Changing aneurysmal morphology after endovascular grafting: relation to leakage or persistent perfusion [see Comments]. *J Endovasc Surg* 1997; **4**: 23–30.
2 Broeders IA, Blankensteijn JD, Olree M, Mali W, Eikelboom BC. Preoperative sizing of grafts for transfemoral endovascular aneurysm management: a prospective comparative study of spiral CT angiography, arteriography, and conventional CT imaging. *J Endovasc Surg* 1997; **4**: 252–261.
3 Balm R, van Leeuwen MS, Noordzij J *et al.* Spiral CT for aortic aneurysms. In: Greenhalgh RM, ed. *Vascular Imaging for Surgeons.* W.B. Saunders Co Ltd., 1995: 191–202.
4 Bland JM, Altman DG. Statistical methods for assessing agreement between two methods of clinical measurement. *Lancet* 1986; **1**: 307–310.
5 Wever JJ, Blankensteijn JD, Rijn van JC *et al.* Inter- and intra-observer variability of CTA measurements in endovascular repair of abdominal aortic aneurysms. Submitted.
6 Rubin GD. Helical CT angiography of the thoracic aorta. *J Thorac Imaging* 1997; **12**: 128–149.
7 Armon MP, Yusuf SW, Whitaker SC *et al.* Thrombus distribution and changes in aneurysm size following endovascular aortic aneurysm repair. *Eur J Vasc Endovasc Surg* 1998; **16**: 472–476.
8 Rubin FD, Paik DS, Johnston PC, Napel S. Measurement of the aorta and its branches with helical CT. *Radiology* 1998; **206**: 823–829.
9 Balm R, Kaatee R, Blankensteijn JD, Mali WP, Eikelboom BC. CT-angiography of abdominal aortic aneurysms after transfemoral endovascular aneurysm management. *Eur J Vasc Endovasc Surg* 1996; **12**: 182–188.
10 Wink O, Niessen WJ, Wever JJ *et al.* Semi-automated quantification and segmentation of abdominal aorta aneurysms from CTA volumes. In: *Proc. Computer Assisted Radiology and Surgery.* Amsterdam: Elsevier Publishers, 1999: 208–212.

Accepted 3 November 1999