



The Brazilian Journal of INFECTIOUS DISEASES

www.elsevier.com/locate/bjid



Clinical image

Secondary syphilis with oral manifestation

Izabella Picinin Safe*, Daniela Cristina Caetano Maia

Tropical Medicine Foundation of Amazonas (FMTAM), Manaus, AM, Brazil

ARTICLE INFO

Article history:

Received 1 June 2013

Accepted 7 June 2013

Available online 23 October 2013

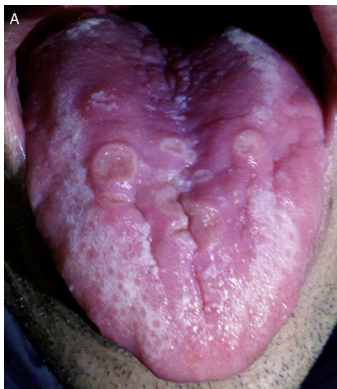

Fig. 1 – Asymptomatic ulcerated lesions in the tongue.

A 35-year-old man presented with a 3-week history of asymptomatic ulcerated lesions in the tongue (Fig. 1). He developed erythematous papules in the trunk and legs at the same time. The patient had no other systemic symptoms and reported having had unprotected sexual intercourse. Testing for the human immunodeficiency virus was positive. VDRL testing was positive with a titer of at least 1:64. A tongue biopsy revealed an inflammatory infiltrate suggestive of secondary syphilis with positive immunohistochemistry for *Treponema pallidum* (Fig. 2). The patient was treated with intramuscular benzathine penicillin for two weeks. The lesions completely resolved during a 4-week period. Syphilis is well known for

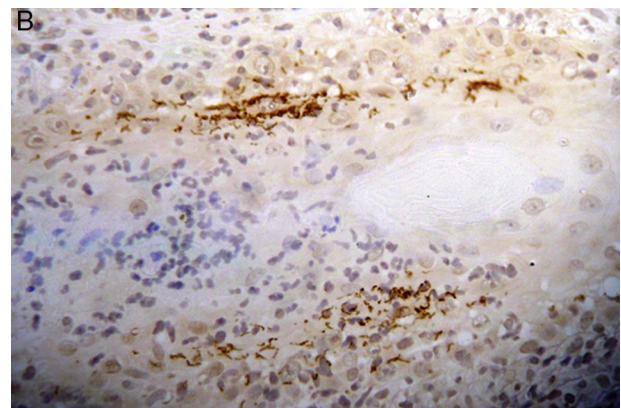


Fig. 2 – Positive immunohistochemistry for *Treponema pallidum*.

its diversity of clinical manifestations. For this reason oral syphilis needs to be considered and investigated in any patient who presents with a nonspecific oral ulceration. Concurrent HIV infection should be considered in any patient with a sexually transmitted disease.

Conflicts of interest

The authors declare no conflicts of interest.

* Corresponding author at: Fundação de Medicina Tropical, Dr. Heitor Vieira Dourado (FMT-HVD), Avenida Pedro Teixeira, 25, Dom Pedro, Manaus, AM 69040-000, Brazil.

E-mail address: izabellasafe@yahoo.com.br (I.P. Safe).