



Update article

Anterior cruciate ligament – updating article[☆]

Marcus Vinicius Malheiros Luzo, Carlos Eduardo da Silveira Franciozi*,
Fernando Cury Rezende, Guilherme Conforto Gracitelli, Pedro Debieux, Moisés Cohen

Universidade Federal de São Paulo, Escola Paulista de Medicina, Departamento de Ortopedia e Traumatologia, Grupo do Joelho, São Paulo, SP, Brazil

ARTICLE INFO

Article history:

Received 30 June 2015

Accepted 2 July 2015

Available online 6 June 2016

Keywords:

Anterior cruciate ligament

Patellar ligament

Joint instability

Knee

Reconstructive surgical procedures

ABSTRACT

This updating article on the anterior cruciate ligament (ACL) has the aim of addressing some of the most interesting current topics in this field. Within this stratified approach, it contains the following sections: ACL remnant; anterolateral ligament and combined intra and extra-articular reconstruction; fixation devices; and ACL femoral tunnel creation techniques.

© 2016 Sociedade Brasileira de Ortopedia e Traumatologia. Published by Elsevier Editora Ltda. This is an open access article under the CC BY-NC-ND license (<http://creativecommons.org/licenses/by-nc-nd/4.0/>).

Ligamento cruzado anterior – Artigo de atualização

RESUMO

Este artigo de atualização sobre ligamento cruzado anterior (LCA) visa abordar alguns dos tópicos mais interessantes e atuais sobre o tema. Dentro dessa abordagem estratificada incluem-se as seguintes seções: remanescente do LCA; ligamento anterolateral e reconstruções extra-articulares combinadas a intra-articulares; dispositivos de fixação; técnicas de confecção do túnel femoral.

© 2016 Sociedade Brasileira de Ortopedia e Traumatologia. Publicado por Elsevier Editora Ltda. Este é um artigo Open Access sob uma licença CC BY-NC-ND (<http://creativecommons.org/licenses/by-nc-nd/4.0/>).

Palavras-chave:

Ligamento cruzado anterior

Ligamento patelar

Instabilidade articular

Joelho

Procedimentos cirúrgicos
reconstrutivos

[☆] Study conducted at the Universidade Federal de São Paulo, Escola Paulista de Medicina, Departamento de Ortopedia e Traumatologia, Grupo do Joelho, São Paulo, SP, Brazil.

* Corresponding author.

E-mail: cacarlos66@hotmail.com (C.E.d.S. Franciozi).

<http://dx.doi.org/10.1016/j.rboe.2016.05.001>

2255-4971/© 2016 Sociedade Brasileira de Ortopedia e Traumatologia. Published by Elsevier Editora Ltda. This is an open access article under the CC BY-NC-ND license (<http://creativecommons.org/licenses/by-nc-nd/4.0/>).

Introduction

The anterior cruciate ligament (ACL) is one of the most studied topics in orthopedics nowadays. Due to new trends, such as the concept of anatomical reconstruction, which gained power in the last decade, new motivation has been given to the study of this ligament, with important advances and innovations. Supported by basic science, the ACL remnant is increasingly gaining prominence in reconstructive surgery, but there is still no consensus regarding the various reconstructions techniques and its preservation, a topic that will be addressed in this article. The so-called new ligament of the knee, the anterolateral ligament, has recently gained prominence and explains old concepts and theories that justify its increased restrictive effect on pivoting due to the greater lever arm relative to the central position of the ACL. This elucidates part of the biomechanics of reconstruction and extra-articular reinforcements. Orthopedics follows the advancement of medicine and currently, a myriad of fixation devices are available for surgeons, who, in light of such diversity, must improve their knowledge of the peculiarities, advantages, disadvantages, and comparisons between each one. Finally, also driven by the rediscovery of ACL anatomy, different techniques of femoral tunnel preparation have been developed, each with its own characteristics, turning necessary a detailed analysis of the most used options.

Therefore, this update on the ACL aimed to address some of the most interesting and current topics on the subject. In this stratified approach, the following sections are: ACL remnant; anterolateral ligament and extra-articular combined with intra-articular reconstructions; fixation devices; and techniques for creating the femoral tunnel.

ACL remnant

Partial ACL lesions are common (5–38%); recently, the remnant fibers have received more attention, aiming to preserve and incorporate them in ACL reconstruction (ACLR). Remnant-preserving ACLR should optimize ligamentization, since the functional remnant fibers biomechanically protect the graft, the vascularized synovial envelope of the remnant ligament contributes to the vascularization of the graft, the valve mechanism created by the tissue remnant in the tunnel prevents the entry of synovial fluid and decreases the enlargement of the tunnel, and the mechanoreceptors present in the remnant assist in proprioception, as demonstrated in histological studies.¹⁻¹²

The definition of ACL remnant-preserving reconstruction surgery is controversial because it involves three different procedures grouped under the same terminology: selective bundle augmentation (SBA; ACLR in a partial lesion involving only the posterolateral or anteromedial bundle); augmentation (AG; ACLR in a partial lesion involving one or both bundles with remnant functional tissue); non-functional remnant preservation (NFRP; ACLR in a complete lesion involving both bundles with non-functional remnant tissue). The definition of functional or non-functional remnant fiber should be

made arthroscopically, by palpation with the probe, with the knee in 90° flexion and also in the “figure-of-4” position.¹

For the arthroscopic classification of ACL injuries involving the remnant, a staged approach that evaluates the presence or absence of remnant tissue morphology and functionality is recommended. This staged approach involves (Fig. 1):

1. Remnant tissue: absent, present.
2. Morphological type of remnant: tibial stump (I), scarring to the PCL (II), scarring to the intercondylar roof (III), unidentifiable pattern scarring to the lateral femoral condyle (IV), anteromedial bundle (V), posterolateral bundle (VI).
3. Remnant functionality: functional, non-functional.

After ACLR, steps 1–3 should be repeated, since, during the reconstruction, part of the remnant tissue may be damaged, changing its initial status. Then, the type of reconstruction that preserves the remnant is determined: SBA, AG, or NFRP. Once the final pass of the graft is made, the percentage of graft coverage by the remnant tissue must be estimated and documented. It is important to document the estimated percentage of graft coverage to assess its possible role in the stability and postoperative function, since some studies have shown that higher coverage is related to better outcomes¹³ (Fig. 2).

The passage of the graft with preservation of the remnant can be performed in two main ways. The graft can be passed along the periphery of the tibial footprint, preserving the remnant tissue and being passed alongside it, thus maintaining the functional remnant fibers and their inserts (Fig. 3A and B). Another possibility is to pass the graft through the center of the tibial footprint, surrounding it with the remnant tissue, which will act as a biological sleeve, whether through the remnant synovial sheath, the remnant ligament tissue, or both (Fig. 3C and D). In this latter approach, it is recommended to gradually widen the tibial tunnel with successively larger drill bits until the final diameter is reached; care must be taken to stop the progression of drills when they breach the tibial plateau, so that the drill remains inside the remnant. When this happens, there is the impression that the ACL remnant tissue is “dancing” due to the drill action within the remnant enclosure. Then, a path is created inside the remnant enclosure with a shaver that opens it proximally, maintaining the entire peripheral tissue and creating only a central path to pass the graft.¹⁴

The placement of the femoral tunnel is more difficult in any of the three remnant-preserving techniques when compared with conventional surgery, in which the tunnel is debrided; sometimes, intraoperative fluoroscopy is recommended to confirm proper positioning of the tunnel.^{2,15,16} Biomechanical protection of the graft by the intact functional remnant fibers is an advantage in SBA and AG, but not in NFRP.^{3,17} Several studies have assessed the potential for better stability with remnant preservation, either through direct mechanical protection by the functional fibers or through better vascularization of the graft and improvement of the ligamentization process. It is believed that SBA provides better stability, followed by AG; NFRP is in last place in this regard.¹⁻¹² Tunnel enlargement is caused by inflammatory cytokines and agents present in the postoperative synovial fluid; it is more common in the tibia, due to severity. Remnant-preserving ACLR was






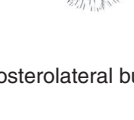
STEP 1 Remnant tissue	Absent Present
STEP 2 Morphological type of the remnant	Tibial stump (I) 
	Scarring to the PCL (II) 
	Scarring at the intercondylar roof (III) 
	Unidentifiable pattern scarring to the lateral femoral condyle (IV) 
	Anteromedial bundle (V) 
	Posterolateral bundle (VI) 

Fig. 1 – Arthroscopic classification of the ACL remnant.

proven to decrease tunnel enlargement when compared with conventional ACLR with remnant debridement, due to the valve mechanism created, which prevents or reduces the entry of synovial fluid.^{6,12} Several studies emphasize the potential of better graft revascularization when preserving the remnant. A

randomized clinical trial (RCT) that used magnetic resonance demonstrated the acceleration of this process, which certainly enhances ligamentization.⁸

Some studies defend the potential benefit of preserving the remnant tissue in the ligamentization process,

Remnant tissue	Recommended ACLR type	Percentage of graft coverage by the remnant tissue
Absent	Conventional
Single-bundle, presence of functional remnant tissue	SBA
Presence of functional remnant tissue	AG	Estimated percentage
Presence of non-functional remnant tissue	NFRP	Estimated percentage

Fig. 2 – Recommended ACLR type that preserves the remnant.

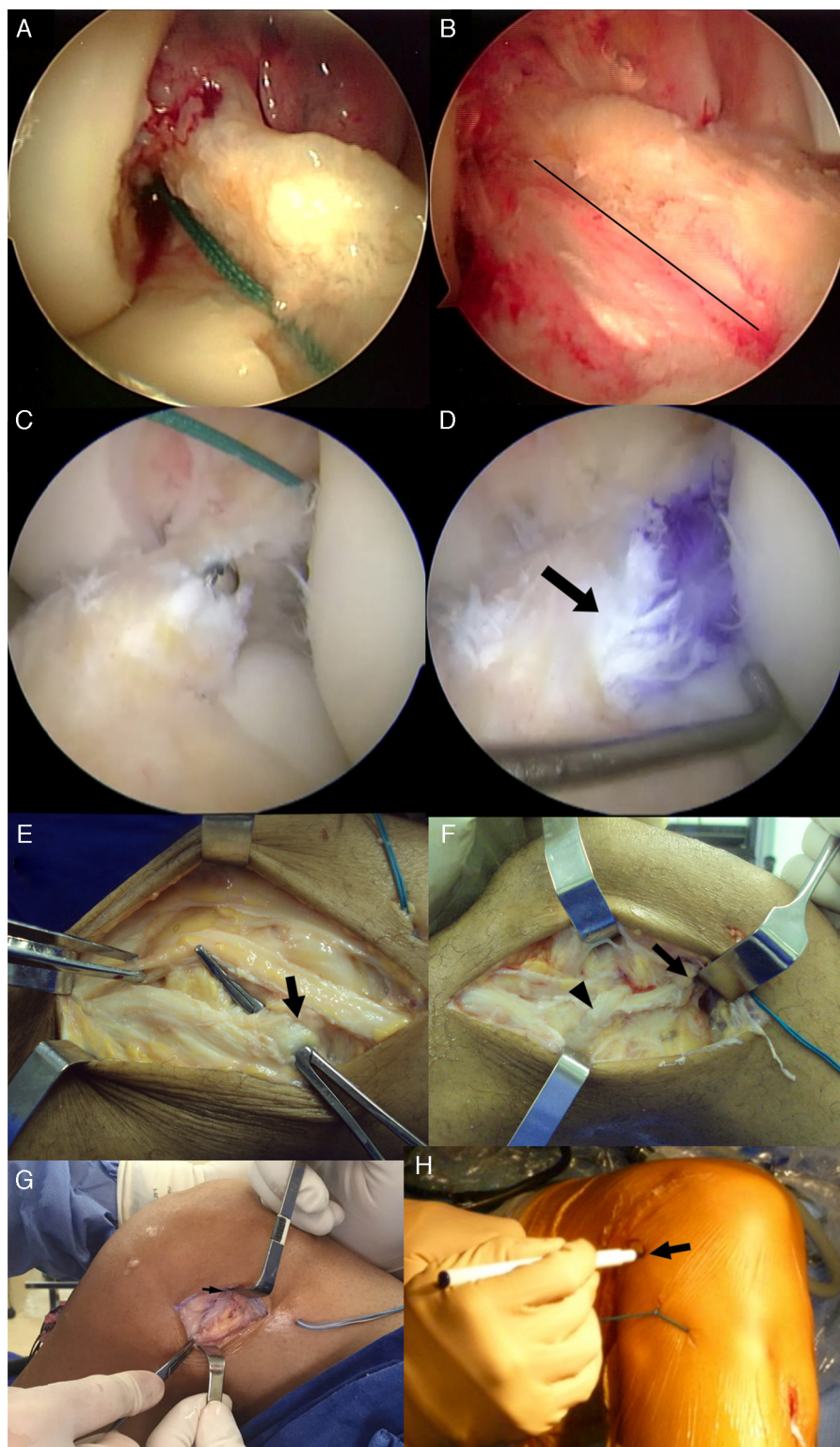


Fig. 3 – ACLR involving current concepts of remnant tissue preservation and extra-articular reinforcement with iliotibial tract band (monoloop) and reconstruction of the anterolateral ligament. (A) ACL injury with presence of remnant tissue. Morphological type: scarring at the intercondylar roof (III). Remnant functionality (assessed with probe): functional. No. 5 Ethbond wire passed from the femoral tunnel to the tibial tunnel, showing tissue preservation with tibial tunnel made in the periphery of the footprint and preserving the remnant. The graft will be passed alongside it, thus maintaining the remnant functional fibers and its tibial and femoral inserts. (B) AG ACLR that preserves the remnant. AG-augmentation: ACLR in a partial lesion involving one or both bundles with functional remnant tissue. Estimated percentage of graft coverage by the remnant tissue: 30%. The line separates the graft in the inferior region and the remainder in the superior portion. (C) ACL injury with presence of remnant tissue. Morphological type: unidentifiable pattern, scarred at the lateral

particularly the synovium of this tissue, as a potential source of mesenchymal cells. This potential is inversely proportional to injury chronicity and suggests better results when remnant-preserving ACLR is performed in more acute cases.¹⁸

Despite the supposed advantage of ACL remnant-preserving reconstruction shown in several studies with low level of evidence, when assessing RCTs, the functional outcomes and stability are similar, and the superiority of ACL remnant-preserving reconstruction is only demonstrated eventually. Thus, further studies are needed with larger sample size, appropriate methodology, and most importantly, consensus in defining the type of ACL remnant-preserving reconstruction. The terminology SBA, AG, NFRP, and the methodology described herein are suggested.^{2,4,5,10,11,13,15-17}

Anterolateral ligament and combined intra- and extra-articular reconstruction

Rotational stability control is a topic that attracts the attention of experts in the field of ACLR surgery. It remains uncertain whether the current arthroscopic ACLR techniques are sufficient to provide rotational stability in all cases of this ligament injury, and it is not fully understood how the different patterns of ACL injuries behave.^{19,20}

Persistent rotational instability after ACLR has been described and appears to correlate directly with decrease in satisfaction and deficit in knee function gain within the post-operative period.^{21,22} Furthermore, the lack of knee rotational control appears to act as a causal factor for new chondral and meniscal lesions.²³

This discussion gained momentum after the growing debate over the anterolateral ligament (ALL) of the knee,

whose injury appears to be associated with some cases of ACL injury. In 1879, Segond was the first to describe this ligament as a "resistant fibrous bundle" in the anterolateral knee compartment with the unique feature of tension in forced internal rotation.²⁴

Later, some authors suggested that this structure was merely a capsular thickening of the anterolateral compartment.²⁵ However, some studies have drawn attention to the importance of this portion of the iliotibial tract. The name anterolateral ligament was initially popularized in Brazil and published in this journal.²⁶ More recent studies have brought this controversy to light again, by defining this structure as a different ligament.²⁷⁻²⁹ Moreover, after biomechanical testing, a close correlation was established between ALL injury and the worsening of rotational stability, defined by a positive pivot-shift test.^{25,30} Thus, authors who advocate the association between ACL and ALL injuries have proposed the need for combined intra- and extra-articular ACLR, which appears reasonable from a biomechanical standpoint in the promotion of combined anteroposterior and rotational stability.^{28,31}

In a recently published meta-analysis of RCTs, the present authors compared isolated ACLR techniques with combined intra- and extra-articular reconstruction techniques. Although the functional scores results were similar between the groups, there was an improvement in the knee stability outcome observed in both pivot-shift and Lachman tests.³² Despite previous studies suggested that these rates would increase, no differences were observed in the rates of knee stiffness, infection, and lateral compartment arthritis among the study groups during the assessed follow-up time.³²⁻³⁴ However, due to the lack of functional improvement associated with extra-articular reconstruction, the authors

femoral condyle (IV). Remnant functionality (assessed with probe): nonfunctional. A path was created within the remnant shell with the shaver, which opens it proximally (the tip of the shaver can be seen protruding through the remainder of the enclosure). All tissue in the periphery is maintained, and only a central path is created, to pass the graft. (D) ACL Remnant-preserving reconstruction type NFRP. NFRP – nonfunctional remnant preservation: ACLR in a complete lesion involving both bundles with non-functional remnant tissue. The graft was passed through the center of the tibial footprint and encased by the remnant tissue, which will act as a biological sleeve, whether by the remnant synovial sheath, remnant ligament tissue, or both. Estimated percentage of graft coverage by the remnant tissue: 60%. Arrow shows graft exit within the remnant. (E) Extra-articular ACL reinforcement with isolated iliotibial band (derivative monoloop, similar to the extra-articular techniques by MacIntosh and Lemaire). The central one-third of the iliotibial tract is dissected with 1–1.5 cm thicknesses, maintaining its distal insertion and releasing its proximal insertion. This is prepared with Krackow suture with No. 5 Ethbond wire. A Kelly clamp is passed deeply into the lateral collateral ligament (arrow) to allow for central iliotibial tract band passage after proximal release and preparation. The central third of the iliotibial tract with 1–1.5 cm thicknesses is already made. (F) Center band of the iliotibial tract already deeply passed by the lateral collateral ligament (arrowhead) and inserted into the distal insertion of the lateral intermuscular septum of the femur, as shown by the arrow (one of the recommended points for insertion of extra-articular reinforcements in ACLR) after satisfactory isometric test. The reinforcement is fixed with an interference screw or anchor with knee at 90° flexion and neutral rotation after ACLR and fixation. In this case it was made with quintuple flexor grafts, outside-in femoral tunnel (aiming to avoid conflict with the femoral tunnel for the fixation of extra-articular reinforcement) and fixation with absorbable interference screw in the femur and tibia. This case demonstrates primary ACLR and extra-articular reinforcement was indicated due to the presence of explosive pivot. (G) Open reconstruction of the anterolateral ligament with gracilis graft combined with ACLR with triple semitendinosus graft. The arrow shows the femoral insertion of the anterolateral ligament. (H) Percutaneous reconstruction of the anterolateral ligament with gracilis graft combined with ACLR with triple semitendinosus graft. The arrow shows the femoral origin and the wire demonstrates the bone tunnels used for tibial insertion of the anterolateral ligament. In this type of reconstruction, the graft is passed superficially to the lateral collateral ligament.

concluded that it is still uncertain whether this stability gain outweighs the morbidity associated with the increase in the use of this procedure in the anterolateral aspect of the knee. Conversely, the same meta-analysis also included studies of extra-articular reconstruction using possibly more obsolete techniques; a deeper understanding of ALL can enhance and lead to more anatomical and minimally invasive techniques for extra-articular reconstruction and improve its results. Furthermore, the authors concluded that there is still considerable room for research in the field of intra- and extra-articular ACLR, not only for improving the technique, but also regarding the groups of individuals that would benefit from the combined procedure. In fact, in a recent publication, Sonnery-Cottet et al.³⁵ presented a recommendation regarding which groups of individuals are candidates for percutaneous intra- and extra-articular ACLR through the technique described in their article: those with pivot grade 2 or 3, Second fracture, chronic ACL injuries, high-level sports activity (such as soccer, rugby, handball, and basketball) and radiographs showing the notch sign in the lateral femoral condyle. According to the criteria described by these authors, a simple restoration of the central axis through isolated ACLR would not be enough to restore rotational stability and would require a peripheral strengthening to the central pivot reconstruction.

A variety of techniques are described in the literature for combined intra- and extra-articular ACLR.²⁸ Classically, tenodesis with the use of a central bundle of fascia lata has been used since the early isolated extra-articular ACLR described by Lemaire³⁶ in 1967. Other authors have used minimally invasive techniques to extend the semitendinosus graft passing through the over the top position or also as an extension of the femoral tunnel of intra-articular ACLR.³¹ However, such techniques are based more on the principle of providing peripheral stabilization of the anterolateral aspect of the knee than properly on different anatomical points that take into account the structure of the anterolateral ligament. Therefore, an in-depth study of the anterolateral compartment of the knee anatomy is very important with regard to better understanding of the anatomical characteristics and isometrics of ALL, in addition to the best graft option for reconstruction. Thus, reconstructions that reproduce the anatomy of this ligament with less surgical morbidity may emerge, possibly improving the results. More clinical studies are also needed to determine the actual need of combined reconstruction within the general population of individuals with ACL injury or if only specific groups of individuals would benefit from these techniques, as for example in case of ACLR revision, chronic injuries, or cases with excessive rotational instability evidenced by an explosive pivot-shift at clinical evaluation (Fig. 3E-H).

Fixation devices

Since the success of the reconstruction depends unequivocally on graft position, the development of fixation devices that keep this neoligament in the proper position despite movements and post-operative rehabilitation techniques allows rehabilitation to begin early and extensively without loss of this positioning, which in turn reduces the risk of complications such as arthrofibrosis and deep vein thrombosis, among

others. A suitable attachment mechanism must keep the graft firmly in the desired place for at least eight weeks, so that it has a chance to establish continuity with the bone tissue.³⁷ Currently, the existing techniques can be subdivided into intra- and extra-tunnel fixations. These are subdivided into suspensory, transfemoral in the buttress position, and transfemoral transfixation techniques.³⁸ Those are represented by compression/interference fixation devices with the bone-graft interface.³⁹ The fact is that there is no gold standard for graft fixation in ACLR.⁴⁰

Biomechanical studies have compared the different fixation methods under different perspectives. Fixation in terms of strength, stiffness, and elongation was favorable to suspensory methods when compared to the buttress and compression methods.⁴¹ The same was observed regarding graft sliding.⁴² The load required to cause loss of fixation was lower with interference screws when compared with extra-tunnel methods (Endobutton and cross-pin).⁴² In contrast, suspensory fixation devices have particular complications, whether the “bungee-effect” (or pistoning)⁴³ or the “windshield effect.”⁴⁴ Such complications can potentially lead to a delay in graft integration in its bone bed and to tunnel dilation over time, which may impair or even make a single revision surgery impossible in the event of re-injury. However, none of these could be associated with worsening of clinical parameters.

In order to resolve the issue, Colvin et al.⁴⁰ conducted a level-1 meta-analysis that compared intra-tunnel (interference screws) with extra-tunnel fixation methods (Endobutton and shear pins) for hamstring tendon graft fixation in ACLR. Thus, following the Cochrane and Quorum methodologies, those authors selected eight studies (RCTs), five of which were included in the meta-analysis. After data analysis, they observed that there was no difference between fixation methods for the outcomes regarding the function and quality of life within the stipulated follow-up period. However, when the analyzed outcome was treatment failure during surgery, despite the absence of statistical significance (RR=0.52; CI: 0.1794–1.3122; $p=0.1542$), there was a clear trend in favor of the interference screw, which presented fewer failures in all retrieved studies.⁴⁰ Those authors suggested that a close fixation of the joint may be biomechanically favorable.⁴⁵ Similarly, Saccomanno et al.⁴⁶ conducted a systematic review (level 1) and compared the suspensory fixation (Endobutton) with fixation in the buttress position (transverse pin). Five studies (317 patients) were included after a search that once again followed the Cochrane protocols. No differences between fixation methods were observed regarding the Lysholm and IKDC scores (the only scores in which the meta-analysis could be performed). Although there were statistically lower tunnel enlargement with the use of transverse pins, this fact had no clinical consequences.⁴⁶

Regarding the different types of interference screws, Debieux et al.⁴⁷ compared metal screws with different types of bioabsorbable screws. Although there was no difference in clinical outcomes (Lysholm, IKDC, Tegner), the metal screw presented a statistically smaller number of implant failures and fewer cases of “overall treatment failures” (when adding all treatment failures analyzed). Thus, although both methods present the same efficiency, metal screw is safer. Of course,

these data should be analyzed in light of the limitations that were not assessed (interference in post-operative imaging and greater difficulty in revision surgeries with metal screws). The authors also found a tendency (not statistically significant) of higher inflammatory activity when the bioabsorbable material was PGA, and better Lysholm score with PLLA.

It is noteworthy that femoral fixation can be properly achieved without any fixation method. Conceived in France in the 1980s, the press-fit method consists of making a bone plug slightly larger than the femoral tunnel. This plug is inserted into the tunnel under pressure and becomes stuck inside, as a "champagne cork." Sarzaem et al.⁴⁸ promoted a RCT comparing this press-fit fixation with the interference screw. In a 12-month follow-up study with 158 patients divided into two groups, no differences were observed in any of the outcome measures (Lysholm, IKDC, KT-1000, Lachman, pivot).

In summary, despite the small biomechanical differences among the methods, each of them was effective and efficient in graft fixation in the period between the postoperative period and ligamentization. Nonetheless, attention should be given not only to individual fixation (tibial and femoral), but also to the relationship between them, since a very large discrepancy between the two fixation methods can generate a weak link in the reconstruction, which can lead to an overlap of one point over another and, consequently, failure.⁴⁹

Techniques for creating the femoral tunnel

In recent years, an increase has been observed in the indications of independent techniques for femoral drilling in ACLR, represented by the transportal or inside-out technique (TP), outside-in (OI), and OI retrograde. In 2013, the Canadian Orthopedic Association reported that 68% of surgeons used independent techniques for femoral drilling and only 31% used the transtibial technique (TT).⁵⁰ Despite this technical change in ACLR in the past decade, there is still doubt about its objective and subjective clinical superiority, as well as the biomechanical advantages of the different techniques used.

Riboh et al.⁵¹ published a systematic review that included six RCTs. Four compared OI *versus* TT and two, TP *versus* TT. In that review, 26 biomechanical studies and studies that analyzed the positioning of the graft in cadavers and *in vivo* were also included. The clinical outcomes measured in RCTs showed no difference between the techniques when considering the incidence of failure, objective IKDC, and scales of physical activities such as Tegner. When evaluated by the Lysholm score, a slight superiority of TT was observed. However, despite the proven statistical difference, it was not considered clinically relevant (mean: -0.62, 95% CI: -1.09 to -0.15). RCTs showed lower anterior looseness in favor of independent techniques when measured by arthrometers in mm (mean: 0.33, 95% CI: 0.10-0.55).⁵¹

In the same review, the biomechanical studies and the studies that assessed graft positioning *in vivo* and in cadaver showed that the independent technique, OI, also showed less anterior translation when measured by Lachman (mean: 2.2, 95% CI: 0.34-4.07), less anterior translation with strength

of 134 N (mean: 1.0, 95% CI: 0.29-1.71), and increased rotational stability (mean: 3.36, 95% CI: 1.88-4.85) when compared with TT. Independent techniques also showed a more oblique femoral tunnel in the coronal and sagittal plane, resulting in greater similarity between the original strengths of the native ACL, but had a higher risk of explosion of the posterior wall of the lateral femoral condyle during drilling.⁵¹

Recently, Robin et al.⁵² published a systematic review without meta-analysis that included ten clinical studies, ten descriptions of surgical technique, five cadaveric studies, one kinematic study, and one literature review. The review identified the advantages and disadvantages of the different ACLR techniques. The main results, as well as others pointed out by the authors of this study, are summarized in Table 1.

Rahr-Wagner et al.⁵³ compared the results of different ACLR techniques from the Danish national register, considered one of the best and most complete records of global medical data. In that retrospective study, 1945 TP reconstructions and 6430 TT reconstructions were analyzed, including failure as the primary outcome, determined by ACLR revision, and as secondary outcomes the pivot-shift test and functional scores (KOOS and Tegner). A significantly increased risk of ACLR revision was observed with TP, with a mean relative risk of 2.04 (95% CI: 1.39-2.99) when compared with TT. Surprisingly, TP also showed increased relative risk to the pivot, with mean RR=2.86 (95% CI: 2.40-3.41), and increased relative risk for anterior instability, with mean RR= 3.70 (95% CI: 3.09-4.43). In addition, there were no differences between the techniques regarding functional scores. That study had some limitations, among them the biases of any retrospective study of data, besides the probable learning curve, by Danish physicians, of the TP included in the evaluation period of the study, due to the recent adoption of the technique in that country.⁵³

The increased risk of revision using TP was also observed in a prospective cohort study that compared TP technique *versus* TT with patellar graft.⁵⁴ Another article showed that the anatomical reconstruction of the AM bundle places more tension on the graft than the AM bundle in a higher position, similar to that achieved by TT technique. Therefore, a graft placed more anatomically than isometrically would be subject to higher tension and more susceptible to rupture. In TT, the graft would be subjected to less tension, but would theoretically dissipate the load through other intra-articular structures, such as the cartilage and meniscus. Only long-term prospective and randomized studies will demonstrate whether the independent techniques of femoral drilling will be able to prevent joint degeneration and osteoarthritis.⁵⁵ Among other possible explanations for the increased risk of re-rupture by independent drilling techniques, OI, are shorter femoral tunnels, which generate less integration between the graft-bone and cases of blow-out of the posterior wall of the lateral condyle, which compromise graft integration.⁵⁶⁻⁵⁸

In short, reconstruction by independent OI technique appears to be related to greater rotational control and less postoperative laxity, despite the higher revision index described in the literature. However, more RCTs are needed to determine the superiority of one technique over another.^{59,60}

Table 1 – Advantages and disadvantages of each femoral tunnel construction technique.

Surgical technique	Transtibial	Transportal	Outside-in	Outside-in retrograde
Advantages	Single incision; less invasive than double incision	Allows access to the footprint of the anteromedial and posterolateral bundles	More predictable and anatomical femoral positioning	More predictable and anatomical femoral positioning
	More isometric graft function along the ADM	Independent tunnels	No need for knee hyperflexion	No need for knee hyperflexion
	Most patients with stable Lachman score	Interference screw placed in parallel	Useful for epiphyseal techniques in skeletally immature patients	Useful for epiphyseal techniques in skeletally immature patients
	Axis of the femoral tunnels similar to the ACL, leading to a lower chance of graft-tunnel and graft-intercondyle impact.	Re-establishes the natural rotational forces during the stance and balance gait phases.	Lower risk of blow-out of the posterior wall	Lower risk of blow-out of the posterior wall
	Low risk of collision of the associated posterolateral reconstruction tunnels	Allows preservation of intact bundles and selective reconstructions	Lower bone resorption at the bone-graft interface due to a more even distribution of contact pressure in the anterior and lateral walls	Smaller lateral incision when compared with the classic outside-in
	Large tunnel length	All-inside techniques can be used It can be used without special guides Intermediate length of the tunnel		
Disadvantages	The tibial tunnel is dependent on the femoral tunnel	Harder to visualize and alter the superior, inferior, superficial, and deep references with the knee in hyperflexion	Need for two incisions and increased surgical morbidity	Increased surgical time
	The femoral tunnel is more anterior and vertical than the anatomical positioning, which can generate rotational instability	Increased risk of iatrogenic chondral lesions	Short tunnel length	Increased costs due to the special instruments
	Verticalized graft generates excessive femoral rotation in the stance phase of gait	Greater chance of rupture of the posterior wall of the lateral condyle	Risk of iatrogenic injury originated at the lateral collateral ligament	A very horizontalized tunnel can further wear out the graft
	Sulcoplasty is sometimes necessary to visualize the femoral origin of the ACL	Technically harder	High risk of collision of the associated posterolateral reconstruction tunnels	
		Higher revision index Increased risk of peroneal nerve injury Need for an assistant to hold the hyperflexion of the knee during drilling Intermediate risk of collision of the associated posterolateral reconstruction tunnels		

Conflicts of interest

The authors declare no conflicts of interest.

REFERENCES

- da Silveira Franciozi CE, Ingham SJ, Gracitelli GC, Luzo MV, Fu FH, Abdalla RJ. Updates in biological therapies for knee injuries: anterior cruciate ligament. *Curr Rev Musculoskelet Med.* 2014;7(3):228-38.
- Colombet P, Dejour D, Panisset JC, Siebold R, French Arthroscopy Society. Current concept of partial anterior cruciate ligament ruptures. *Orthop Traumatol Surg Res.* 2010;96 8 Suppl.:S109-18.
- Crain EH, Fithian DC, Paxton EW, Luetzow WF. Variation in anterior cruciate ligament scar pattern: does the scar pattern affect anterior laxity in anterior cruciate ligament-deficient knees? *Arthroscopy.* 2005;21(1):19-24.
- Buda R, Ruffilli A, Parma A, Pagliuzzi G, Luciani D, Ramponi L, et al. Partial ACL tears: anatomic reconstruction versus nonanatomic augmentation surgery. *Orthopedics.* 2013;36(9):e1108-13.
- Dejour D, Ntangiopoulos PG, Saggin PR, Panisset JC. The diagnostic value of clinical tests, magnetic resonance imaging, and instrumented laxity in the differentiation of complete versus partial anterior cruciate ligament tears. *Arthroscopy.* 2013;29(3):491-9.
- Demirağ B, Ermutlu C, Aydemir F, Durak K. A comparison of clinical outcome of augmentation and standard reconstruction techniques for partial anterior cruciate ligament tears. *Eklemler Hastalıkları Cerrahisi.* 2012;23(3):140-4.
- Dhillon MS, Bali K, Vasistha RK. Immunohistological evaluation of proprioceptive potential of the residual stump of injured anterior cruciate ligaments (ACL). *Int Orthop.* 2010;34(5):737-41.
- Gohil S, Annear PO, Breidahl W. Anterior cruciate ligament reconstruction using autologous double hamstrings: a comparison of standard versus minimal debridement techniques using MRI to assess revascularisation. A randomized prospective study with a one-year follow-up. *J Bone Joint Surg Br.* 2007;89(9):1165-71.
- Hong L, Li X, Zhang H, Liu X, Zhang J, Shen JW, et al. Anterior cruciate ligament reconstruction with remnant preservation: a prospective, randomized controlled study. *Am J Sports Med.* 2012;40(12):2747-55.
- Muneta T, Koga H, Ju YJ, Horie M, Nakamura T, Sekiya I. Remnant volume of anterior cruciate ligament correlates preoperative patients' status and postoperative outcome. *Knee Surg Sports Traumatol Arthrosc.* 2013;21(4):906-13.
- Pujol N, Colombet P, Potel JF, Cucurulo T, Graveleau N, Hulet C, et al. Anterior cruciate ligament reconstruction in partial tear: selective anteromedial bundle reconstruction conserving the posterolateral remnant versus single-bundle anatomic ACL reconstruction: preliminary 1-year results of a prospective randomized study. *Orthop Traumatol Surg Res.* 2012;98 8 Suppl.:S171-7.
- Zhang Q, Zhang S, Cao X, Liu L, Liu Y, Li R. The effect of remnant preservation on tibial tunnel enlargement in ACL reconstruction with hamstring autograft: a prospective randomized controlled trial. *Knee Surg Sports Traumatol Arthrosc.* 2014;22(1):166-73.
- Nakamae A, Ochi M, Deie M, Adachi N, Shibuya H, Ohkawa S, et al. Clinical outcomes of second-look arthroscopic evaluation after anterior cruciate ligament augmentation: comparison with single- and double-bundle reconstruction. *Bone Joint J.* 2014;96-B(10):1325-32.
- Sonnery-Cottet B, Freychet B, Murphy CG, Pupim BH, Thaunat M. Anterior cruciate ligament reconstruction and preservation: the Single-Anteromedial Bundle Biological Augmentation (SAMBBA) technique. *Arthrosc Tech.* 2014;3(6):e689-93.
- Abat F, Gelber PE, Erquicia JI, Pelfort X, Tey M, Monllau JC. Promising short-term results following selective bundle reconstruction in partial anterior cruciate ligament tears. *Knee.* 2013;20(5):332-8.
- Kazusa H, Nakamae A, Ochi M. Augmentation technique for anterior cruciate ligament injury. *Clin Sports Med.* 2013;32(1):127-40.
- Mifune Y, Ota S, Takayama K, Hoshino Y, Matsumoto T, Kuroda R, et al. Therapeutic advantage in selective ligament augmentation for partial tears of the anterior cruciate ligament: results in an animal model. *Am J Sports Med.* 2013;41(2):365-73.
- Lee DH, Ng J, Chung JW, Sonn CH, Lee KM, Han SB. Impact of chronicity of injury on the proportion of mesenchymal stromal cells derived from anterior cruciate ligaments. *Cytotherapy.* 2014;16(5):586-98.
- Logan MC, Williams A, Lavelle J, Gedroyc W, Freeman M. Tibiofemoral kinematics following successful anterior cruciate ligament reconstruction using dynamic multiple resonance imaging. *Am J Sports Med.* 2004;32(4):984-92.
- Ristanis S, Stergiou N, Patras K, Vasiliadis HS, Giakas G, Gergoulis AD. Excessive tibial rotation during high-demand activities is not restored by anterior cruciate ligament reconstruction. *Arthroscopy.* 2005;21(11):1323-9.
- Chouliaras V, Ristanis S, Moraiti C, Stergiou N, Georgoulis AD. Effectiveness of reconstruction of the anterior cruciate ligament with quadrupled hamstrings and bone-patellar tendon-bone autografts: an in vivo study comparing tibial internal-external rotation. *Am J Sports Med.* 2007;35(2):189-96.
- Kocher MS, Steadman JR, Briggs KK, Sterett WI, Hawkins RJ. Relationships between objective assessment of ligament stability and subjective assessment of symptoms and function after anterior cruciate ligament reconstruction. *Am J Sports Med.* 2004;32(3):629-34.
- Stergiou N, Ristanis S, Moraiti C, Georgoulis AD. Tibial rotation in anterior cruciate ligament (ACL)-deficient and ACL-reconstructed knees: a theoretical proposition for the development of osteoarthritis. *Sports Med.* 2007;37(7):601-13.
- Segond P. Recherches cliniques et expérimentales sur les épanchements sanguins du genou par entorse. Paris: National Library of France; 1879. p. 1-85. Available from <http://www.patrimoine.edilivre.com/recherches-cliniques-et-experimentales-surles-epanchements-sanguins-du-genou-par-entorse-parpaul-segond-segond-paul-ferdinand-dr-1879-ark-12148-bpt6k5712206r.html>.
- Hugston JC, Andrews JR, Cross MJ, Moschi A. Classification of knee ligament instabilities. Part II. The lateral compartment. *J Bone Joint Surg Am.* 1976;58(2):173-9.
- Cohen M, Vieira EA, Silva RT, Vieira ELC, Berlfein PAS. Estudo anatômico do trato iliotibial: revisão crítica de sua importância na estabilidade do joelho. *Rev Bras Ortop.* 2002;37(8):328-35.

27. Claes S, Vereecke E, Maes M, Victor J, Verdonk P, Bellemans J. Anatomy of the anterolateral ligament of the knee. *J Anat*. 2013;223(4):321-8.
28. Dodds AL, Halewood C, Gupte CM, Williams A, Amis AA. The anterolateral ligament: anatomy, length changes, and association with the Segond fracture. *Bone Joint J*. 2014;96(3):325-31.
29. Helito CP, Demange MK, Bonadio MB, Tíríco LE, Gobbi RG, Pécora JR, et al. Anatomy and histology of the knee anterolateral ligament. *Orthop J Sports Med*. 2013;1(7), <http://dx.doi.org/10.1177/2325967113513546>. Available from <http://ojs.sagepub.com/content/1/7/2325967113513546.full.pdf+html>.
30. Monaco E, Ferretti A, Labianca L, Maestri B, Speranza A, Kelly MJ, et al. Navigated knee kinematics after cutting of the ACL and its secondary restraint. *Knee Surg Sports Traumatol Arthrosc*. 2012;20(5):870-7.
31. Marcacci M, Zaffagnini S, Giordano G, Iacono F, Presti ML. Anterior cruciate ligament reconstruction associated with extra-articular tenodesis: a prospective clinical and radiographic evaluation with 10- to 13-year follow-up. *Am J Sports Med*. 2009;37(4):707-14.
32. Rezende FC, de Moraes VY, Martimbianco AL, Luzo MV, da Silveira Franciozi CE, Belloti JC. Does combined intra- and extraarticular ACL reconstruction improve function and stability? A meta-analysis. *Clin Orthop Relat Res*. 2015;473(8):2609-18.
33. Anderson AF, Snyder RB, Lipscomb AB Jr. Anterior cruciate ligament reconstruction: a prospective randomized study of three surgical methods. *Am J Sports Med*. 2001;29(3):272-9.
34. Sonnery-Cottet B, Archbold P, Zayni R, Bortolletto J, Thaanat M, Prost T, et al. Prevalence of septic arthritis after anterior cruciate ligament reconstruction among professional athletes. *Am J Sports Med*. 2011;39(11):2371-6.
35. Sonnery-Cottet B, Thaanat M, Freychet B, Pupim BH, Murphy CG, Claes S. Outcome of a combined anterior cruciate ligament and anterolateral ligament reconstruction technique with a minimum 2-year follow-up. *Am J Sports Med*. 2015;43(7):1598-605.
36. Lemaire M. Ruptures anciennes du ligament croise anterieur du genou. *J Chir*. 1967;93:311-20.
37. Scheffler SU, Sudkamp NP, Gockenjan A, Hoffman RF, Weiler A. Biomechanical comparison of hamstring and patellar tendon graft anterior cruciate ligament reconstruction techniques: the impact of fixation level and fixation method under cyclic loading. *Arthroscopy*. 2002;18(3):304-15.
38. Clark R, Olsen RE, Larson BJ, Goble EM, Farrer RP. Cross-pin femoral fixation: a new technique for hamstring anterior cruciate ligament reconstruction of the knee. *Arthroscopy*. 1998;14(3):258-67.
39. McGuire DA, Barber FA, Elrod BF, Paulos LE. Bioabsorbable interference screws for graft fixation in anterior cruciate ligament reconstruction. *Arthroscopy*. 1999;15(5):463-73.
40. Colvin A, Sharma C, Parides M, Glashow J. What is the best femoral fixation of hamstring autografts in anterior cruciate ligament reconstruction: a meta-analysis. *Clin Orthop Relat Res*. 2011;469(4):1075-81.
41. Milano G, Mulas PD, Zirano F, Piras S, Manunta A, Fabbriani C. Comparison between different femoral fixation devices for ACL reconstruction with doubled hamstring tendon graft: a biomechanical analysis. *Arthroscopy*. 2006;22(6):660-8.
42. Ahmad CS, Gardner TR, Groh M, Arnouk J, Levine WN. Mechanical properties of soft tissue femoral fixation devices for anterior cruciate ligament reconstruction. *Am J Sports Med*. 2004;32(3):635-40.
43. Fu FH, Bennett CH, Lattermann C, Ma CB. Current trends in anterior cruciate ligament reconstruction. Part I: biology and biomechanics of reconstruction. *Am J Sports Med*. 1999;27(6):821-30.
44. Kousa P, Jarvinen TL, Vihavainen M, Kannus P, Jarvinen M. The fixation strength of six hamstring tendon graft fixation devices in anterior cruciate ligament reconstruction. *Am J Sports Med*. 2003;31(2):174-81.
45. Rodeo SA, Kawamura S, Kim HJ, Dynybil C, Ying L. Tendon healing in a bone tunnel differs at the tunnel entrance versus the tunnel exit. *Am J Sports Med*. 2006;34(11):1790-800.
46. Saccomanno MF, Shin JJ, Mascarenhas R, Haro M, Verma NN, Cole BJ, et al. Clinical and functional outcomes after anterior cruciate ligament reconstruction using cortical button fixation versus transfemoral suspensory fixation: a systematic review of randomized controlled trials. *Arthroscopy*. 2014;30(11):1491-8.
47. Debieux P, Franciozi CE, Lenza M, Faloppa F, Bellotti JC, Tamaoki MJS. Bioabsorbable versus metallic interference screws for graft fixation in anterior cruciate ligament reconstruction. *Cochrane Database Syst Rev*. 2012;(4):1-5.
48. Sarzaeem MM, Najafi F, Razi M, Najafi MA. ACL reconstruction using bone-patella tendon-bone autograft: press-fit technique vs. interference screw fixation. *Arch Orthop Trauma Surg*. 2014;134(7):955-62.
49. Monaco E, Labianca L, Speranza A, Agrò AM, Camillieri G, D'Arrigo C, et al. Biomechanical evaluation of different anterior cruciate ligament fixation techniques for hamstring graft. *J Orthop Sci*. 2010;15(1):125-31.
50. Chechik O, Amar E, Khashan M, Lador R, Eyal G, Gold A. An international survey on anterior cruciate ligament reconstruction practices. *Int Orthop*. 2013;37(2):201-6.
51. Riboh JC, Hasselblad V, Godin JA, Mather RC 3rd. Transtibial versus independent drilling techniques for anterior cruciate ligament reconstruction: a systematic review, meta-analysis, and meta-regression. *Am J Sports Med*. 2013;41(11):2693-702.
52. Robin BN, Jani SS, Marvil SC, Reid JB, Schillhammer CK, Lubowitz JH. Advantages and disadvantages of transtibial, anteromedial portal, and outside-in femoral tunnel drilling in single-bundle anterior cruciate ligament reconstruction: a systematic review. *Arthroscopy*. 2015;31(7):1412-7.
53. Rahr-Wagner L, Thillemann TM, Pedersen AB, Lind MC. Increased risk of revision after anteromedial compared with transtibial drilling of the femoral tunnel during primary anterior cruciate ligament reconstruction: results from the Danish Knee Ligament Reconstruction Register. *Arthroscopy*. 2013;29(1):98-105.
54. Alentorn-Geli E, Lajara F, Samitier G, Cugat R. The transtibial versus the anteromedial portal technique in the arthroscopic bone-patellar tendon-bone anterior cruciate ligament reconstruction. *Knee Surg Sports Traumatol Arthrosc*. 2010;18(8):1013-37.
55. Xu Y, Liu J, Kramer S, Martins C, Kato Y, Linde-Rosen M, et al. Comparison of in situ forces and knee kinematics in anteromedial and high anteromedial bundle augmentation for partially ruptured anterior cruciate ligament. *Am J Sports Med*. 2011;39(2):272-8.
56. Golish SR, Baumfeld JA, Schoderbek RJ, Miller MD. The effect of femoral tunnel starting position on tunnel length in anterior cruciate ligament reconstruction: a cadaveric study. *Arthroscopy*. 2007;23(11):1187-92.
57. Chang CB, Yoo JH, Chung BJ, Seong SC, Kim TK. Oblique femoral tunnel placement can increase risks of short femoral tunnel and cross-pin protrusion in anterior cruciate ligament reconstruction. *Am J Sports Med*. 2010;38(6):1237-45.
58. Lubowitz JH. Anteromedial portal technique for the anterior cruciate ligament femoral socket: pitfalls and solutions. *Arthroscopy*. 2009;25(1):95-101.

-
59. Linko E, Harilainen A, Malmivaara A, Seitsalo S. Surgical versus conservative interventions for anterior cruciate ligament ruptures in adults. *Cochrane Database Syst Rev.* 2005;18(2):CD001356.
60. Tiamklang T, Sumanont S, Foocharoen T, Laopaiboon M. Double-bundle versus single-bundle reconstruction for anterior cruciate ligament rupture in adults. *Cochrane Database Syst Rev.* 2012;(11):CD008413.