

Available online at [www.sciencedirect.com](http://www.sciencedirect.com)

ScienceDirect

Biomedical Journal

journal homepage: [www.elsevier.com/locate/bj](http://www.elsevier.com/locate/bj)

## Correspondence

# A trigger-happy soldier with bilateral ptosis and dysphagia



F.M.H. Ahmad, K.V.S. Hari Kumar\*

Departments of Neurology and Endocrinology, Command Hospital, Chandimandir, Panchkula, Haryana, India

## ARTICLE INFO

## Article history:

Received 16 January 2015

Accepted 14 March 2015

Available online 10 March 2016

## Keywords:

Dysphagia

Myotonic dystrophy

Muscular dystrophy

Ptosis

Tongue atrophy

## ABSTRACT

Muscular dystrophy encompasses a group of disorders characterized by the progressive weakness of the skeletal muscles. These disorders are mostly inherited and have characteristic age and muscle group predilection. Lingual muscle involvement is an unusual feature in patients with the muscular dystrophy and helps in the differential diagnosis. We recently encountered a serving soldier presenting with complaints of bilateral ptosis and dysphagia of 5 years duration. Examination showed bilateral ptosis, percussion myotonia, generalized muscular atrophy including that of tongue muscles, and a characteristic hatchet facies. Investigations revealed elevated creatine kinase and myotonic discharges on electromyography leading to a diagnosis of myotonic dystrophy type 1. Muscular dystrophy has a varied presentation and can pose a diagnostic problem in clinical practice. We present the case to highlight the differential diagnosis of tongue atrophy in patients with muscular dystrophy.

In September 2014, a 48-year-old soldier presented with complaints of bilateral ptosis and dysphagia of 5 years duration. He also noticed a gradual thinning of the limbs over the same duration. He is a soldier by profession and had trouble in handling the personal weapon. He noticed difficulty in releasing the hand grip over the rifle butt after each firing. His colleagues used to ridicule him for his fondness of holding the rifle butt and delayed release of the hand grip. Neurological examination revealed normal cognitive function and cranial nerves, proximal muscle weakness, and winging of the scapula. Facial examination reveals bilateral ptosis [Fig. 1A], tongue atrophy [Fig. 1B], and atrophy of the temporalis muscles, giving a characteristic appearance of the hatchet facies. Muscle atrophy was marked in all the groups and there was evidence of percussion myotonia over the deltoid and quadriceps. The rest

of the systemic examination was normal without any evidence of insulin resistance and hypogonadism.

The results of the routine biochemistry were normal except for mild elevation of creatine kinase (252 IU/l, normal 25–225). Slit-lamp examination confirmed the presence of early cataract. ECG did not show evidence of conduction blocks and echocardiography was normal. MRI image showed marked atrophy of the tongue with replacement of the muscle tissue by the fat strands [Fig. 1C]. Muscle biopsy revealed mild atrophy of type 1 fibers with no features to suggest mitochondrial disorders. Electromyography showed diffuse myotonic discharges in atypical manner. The constellation of the findings led us to the clinical diagnosis of adult-onset myotonic dystrophy type 1. Unfortunately, we could not perform the genetic analysis due to lack of such facility at our hospital.

\* Corresponding author. Departments of Neurology and Endocrinology, Command Hospital, Chandimandir Cantonment, Panchkula, Haryana, India. Tel.: +91 814 614 1700; fax: +91 172 285 1058.

E-mail address: [hariendo@rediffmail.com](mailto:hariendo@rediffmail.com) (K.V.S. Hari Kumar).

Peer review under responsibility of Chang Gung University.

<http://dx.doi.org/10.1016/j.bj.2015.03.001>

2319-4170/Copyright © 2016, Chang Gung University. Publishing services provided by Elsevier B.V. This is an open access article under the CC BY-NC-ND license (<http://creativecommons.org/licenses/by-nc-nd/4.0/>).

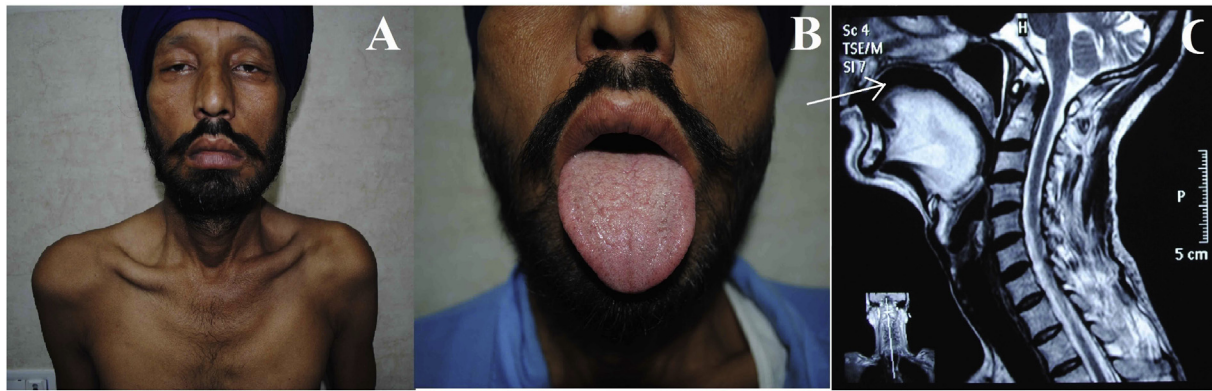


Fig. 1 – Figure showing (A) bilateral ptosis, hatchet facies and (B, C) tongue atrophy.

Our patient had many unique features in his presentation, which were the index case in the family, marked atrophy of the tongue, and lack of systemic features. The differential diagnosis of such presentation includes oculopharyngeal muscular dystrophy, facioscapulohumeral dystrophy, chronic progressive external ophthalmoplegia, mitochondrial myopathy, ocular myasthenia, and spinobulbar muscular atrophy [1]. Myotonic dystrophy type 1 is a trinucleotide repeat disorder characterized by the presence of progressive muscle weakness, wasting, and myotonia, in addition to systemic involvement [2]. The disease is inherited in an autosomal dominant fashion, but none of the family members were involved in our case. The disease presents in many forms like adult onset, congenital, childhood onset, and oligosymptomatic variants [3].

Atrophy of the tongue along with the facial muscles is classically described in cases of oculopharyngeal muscular dystrophy. Lingual muscle involvement is considered as the exclusion criterion for the diagnosis of facioscapulohumeral dystrophy [4]. Myotonia means slow relaxation of the muscle after a contraction. Our patient had a unique problem restricted to the soldiers who have to hold the rifle tightly prior to the release of the trigger. The myotonia in our patient contributed to the sarcastic label of a trigger-happy soldier. Myotonia is seen in many neurological disorders, including myotonic dystrophy, myotonia congenita, channelopathies, and metabolic myopathies [5]. Pseudomyotonia is a slow relaxation after muscle contraction without a myotonic

discharge on electromyography and is described typically in primary hypothyroidism.

#### Source of support

Nil.

#### Conflict of interest

None declared.

#### REFERENCES

- [1] Walters RJ. Muscle diseases: mimics and chameleons. *Pract Neurol* 2014;14:288–98.
- [2] Udd B, Krahe R. The myotonic dystrophies: molecular, clinical, and therapeutic challenges. *Lancet Neurol* 2012;11:891–905.
- [3] Arsenault ME, Prevost C, Lescault A, Laberge C, Puymirat J, Mathieu J. Clinical characteristics of myotonic dystrophy type 1 patients with small CTG expansions. *Neurology* 2006;66:1248–50.
- [4] Yamanaka G, Goto K, Matsumura T, Funakoshi M, Komori T, Hayashi YK, et al. Tongue atrophy in facioscapulohumeral muscular dystrophy. *Neurology* 2001;57:733–5.
- [5] Miller TM. Differential diagnosis of myotonic disorders. *Muscle Nerve* 2008;37:293–9.