


Available online at  
 ScienceDirect  
[www.sciencedirect.com](http://www.sciencedirect.com)

Elsevier Masson France  
  
[www.em-consulte.com/en](http://www.em-consulte.com/en)



## IMAGE

## Use of umbilical venous catheter before performing Rashkind's procedure

Un cathéter veineux ombilical en attendant la manœuvre de Rashkind

Pierre-Emmanuel Séguéla\*, Sébastien Hascouët,  
Philippe Acar

*Service de cardiologie pédiatrique, hôpital des Enfants, Toulouse University Hospital,  
TSA 70034, 31059 Toulouse cedex 9, France*

Received 26 November 2010; received in revised form 20 December 2010; accepted 21 December 2010

### KEYWORDS

Congenital heart disease;  
Echocardiography;  
Cardiac catheterization;  
Transposition of the great arteries

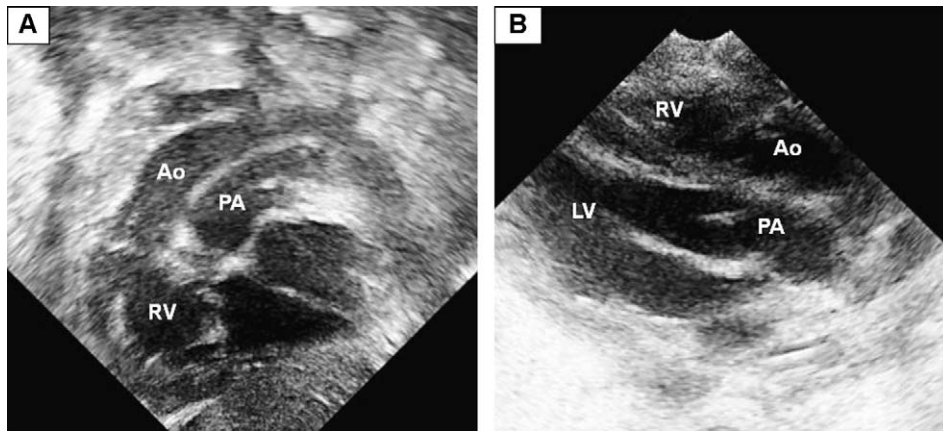
### MOTS CLÉS

Cardiopathie congénitale ;  
Échocardiographie ;  
Cathétérisme cardiaque ;  
Transposition des gros vaisseaux

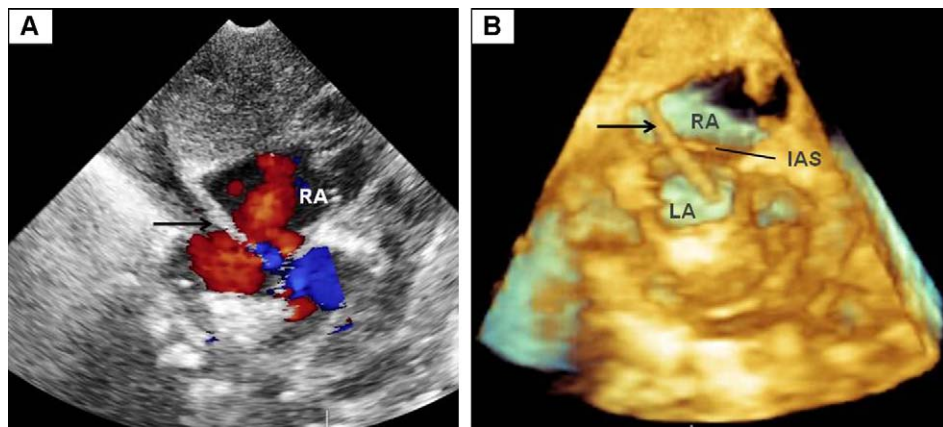
A full-term newborn was referred to our paediatric intensive care unit for persistent cyanosis. There was no dyspnoea and cardiac auscultation was normal. Chest radiography showed a heart of normal size with pulmonary vascular overload. No improvement in capillary saturation was observed after a hyperoxia test, suggesting cyanotic congenital heart disease. An umbilical venous catheter was then placed in order to administrate intravenous prostaglandin therapy, and capillary saturation increased from 56 to 83%. Afterwards, the patient was transferred to our hospital to perform echocardiography and to continue care. Two-dimensional (2D) echocardiography revealed a transposition of the great arteries (Fig. 1). On 2D and 3D echocardiography, the umbilical catheter was seen passing through the foramen ovale (Fig. 2, Videos 1 and 2). Left-to-right atrial shunt was then sufficient to discharge the left atrium (Fig. 2A, Video 1). As soon as the catheter was removed, the foramen ovale became restrictive, with a concomitant decrease in saturation to 55% (Fig. 3A). A Rashkind procedure was performed, which improved blood flow between the two atria (Fig. 3B) and increased capillary saturation to 85%. The fossa ovalis membrane, which had restricted the blood flow (Fig. 3C, Video 3), was torn up by the procedure (Fig. 3D, Video 4).

Transposition of the great arteries is a well-known cause of isolated neonatal cyanosis. When the atrial septal defect is restrictive before surgery (consisting of an arterial switch a few days after the birth), a percutaneous atrioseptostomy (Rashkind procedure) is required. Sometimes, this invasive procedure has to be performed promptly in order to avoid premature death. Our observation shows that, in patients admitted to hospitals located far from centre specialized in this procedure, an umbilical venous catheter pushed into the left atrium (further than normally) may keep open the foramen ovale until the Rashkind procedure can be performed. To our knowledge, this is the first report of this rescue technique.

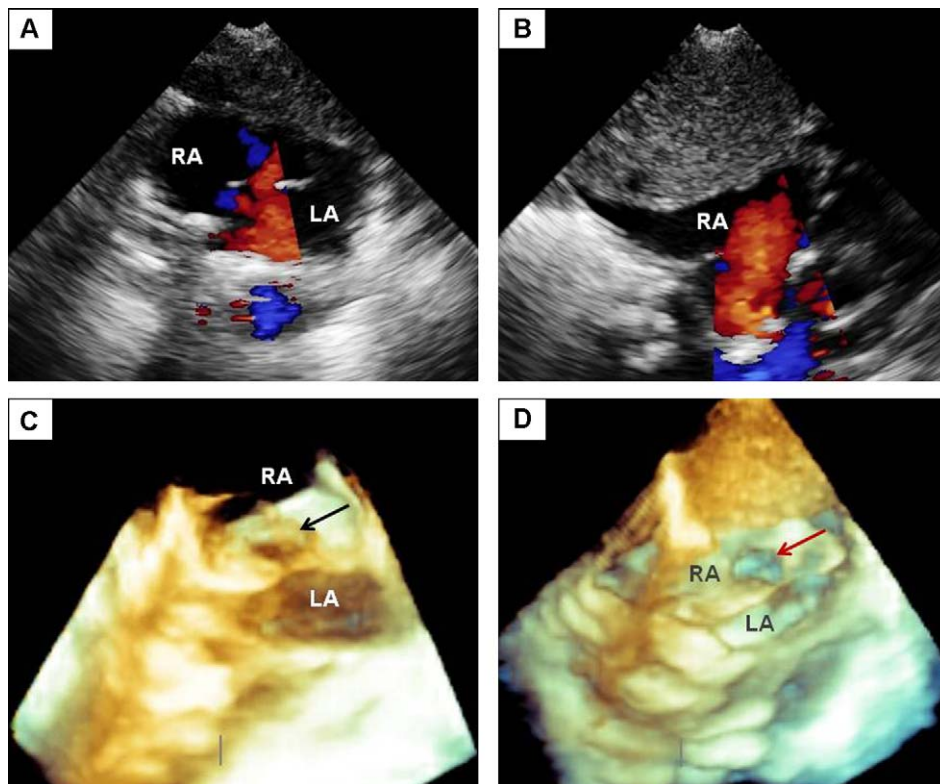
\* Corresponding author. Fax: +00 33 5 34 55 86 63.  
E-mail address: [pesegueta@yahoo.fr](mailto:pesegueta@yahoo.fr) (P.-E. Séguéla).



**Figure 1.** Transposition of the great arteries seen on 2D echocardiography. (A) Subcostal view and (B) long-axis view showing the typical parallel course of the two great vessels. The aorta arises from the right ventricle and the pulmonary artery from the left ventricle. Ao: aorta; LV: left ventricle; PA: pulmonary artery; RV: right ventricle.



**Figure 2.** (A) Two-dimensional subcostal Doppler colour view and (B) three-dimensional subcostal view showing the umbilical venous catheter (black arrow) passing through the interatrial septum. Because the foramen ovale was opened wide by the catheter, left-to-right atrial shunt allowed the left atrium discharge. IAS: interatrial septum; LA: left atrium; RA: right atrium.



**Figure 3.** Two-dimensional subcostal views showing (A) the small left-to-right shunt through the foramen ovale after removal of the umbilical venous catheter and before the Rashkind procedure; and (B) the nonrestrictive atrial septal defect after the Rashkind procedure. Three-dimensional subcostal views showing (C) the fossa ovalis membrane (black arrow) hindering blood flow through the foramen ovale before the Rashkind procedure; and (D) the large atrial septal defect (red arrow) created by the percutaneous atrioseptostomy. LA: left atrium; RA: right atrium.

### Disclosure of interest

The authors declare that they have no conflicts of interest concerning this article.

### Appendix A. Supplementary data

Supplementary data associated with this article can be found, in the online version, at [doi:10.1016/j.acvd.2010.12.009](https://doi.org/10.1016/j.acvd.2010.12.009).