



Contents lists available at ScienceDirect

International Journal of Surgery Case Reports

journal homepage: www.casereports.com

Surgical management of neurologically complicated kyphoscoliosis using transposition of the spinal cord: Case report



V.V. Novikov*, A.S. Vasyura, M.N. Lebedeva, M.V. Mikhaylovskiy, M.A. Sadovoy

Novosibirsk Research Institute of Traumatology and Orthopaedics n.a. Ya.L. Tsivyan, Russia

ARTICLE INFO

Article history:

Received 10 May 2016

Received in revised form 18 July 2016

Accepted 23 July 2016

Available online 27 July 2016

Keywords:

Severe kyphoscoliosis

Neurological complications

Surgical management

Transposition of the spinal cord

Case report

ABSTRACT

BACKGROUND: Transposition of the spinal cord made it possible to achieve mobilization of the fixed kyphoscoliosis, significantly increase spinal canal volume and improve spinal canal shape. This helped to eliminate spinal cord compression and achieve complete regression of the existing neurological symptoms.

METHODS AND RESULTS: We report the clinical case of surgical management of neurologically complicated kyphoscoliotic deformity of the thoracic spine by transposition of the spinal cord and correction using posterior segmental spinal instrumentation.

CONCLUSIONS: The required correction of severe kyphoscoliosis was performed; the risks of trunk imbalance, deformity progression, and instrumentation failure in the long-term postoperative period were reduced.

LEVEL OF EVIDENCE: Level IV – 1 case.

© 2016 The Authors. Published by Elsevier Ltd on behalf of IJS Publishing Group Ltd. This is an open access article under the CC BY-NC-ND license (<http://creativecommons.org/licenses/by-nc-nd/4.0/>).

1. Introduction

Idiopathic rigid decompensated kyphoscoliosis is a severe spinal deformity tending to progress without surgical treatment.

Surgical management methods include the posterior, anterior, and combined anterior–posterior approaches [1]. Fairly good correction with short fusion level can be achieved using anterior instrumentation. However, the approaches differ in regard to some complications, such as injuries to the adjacent aorta and organs, as well as reduced pulmonary function [2]. Pedicle screws, hook or hybrid constructs are used in posterior instrumentation. The posterior approach is currently widely used as it ensures good correction outcomes and the relatively low complication rate [3,4]. The combined anterior–posterior approach implies anterior release and/or fusion with subsequent posterior instrumentation and fusion involving either one or two stages. In case of severe and rigid spinal curve, surgeons tend to choose the combination of the anterior and posterior approaches [5,6]. The reason is that the combined anterior and posterior surgery has proved to be quite safe with effective 3D curve correction being achieved [7,8]. However, it was demonstrated in some studies that the posterior-only approach is sufficient for achieving fairly good correction of the spinal curve, so the anterior approach is actually not required.

If a spinal deformity is rather long (involving 3–7 levels) and there is extensive spinal cord compression, osteoplasty after this type of resections can turn out to be inefficient. Elimination of spinal cord compression in this case may require to further increase the resection volume and the number of surgical levels. Hence, transposition of the spinal cord can be the most effective surgical intervention method [7]. Elimination of spinal stenosis by resecting bone structures that compress the spinal cord only allows one to manage the existing neurological deficit. This decompression of spinal cord makes it impossible to subsequently correct the spine deformity. The methods for single-stage radical correction of severe kyphoscoliotic deformities using vertebral instrumentation often cause neurological complications, including development of traction-ischemic myelopathy in early postoperative period [3]. The attempts to correct these deformities non-radically are often unsuccessful, since the kyphotic and scoliotic curves remain largely unchanged and the biomechanics is disturbed, resulting in pseudoarthrosis, loss of correction, trunk imbalance, and further deformity progression. Sometimes instrumentation needs to be removed because of its breakage and failure of bone fixation points [4]. This case report is given to demonstrate the method for successful single-stage decompression of the spinal cord followed by transposition. Based on their own experience, surgeons in the Clinic of Pediatric and Adolescent Vertebrology (Novosibirsk Research Institute of Traumatology and Orthopaedics) designed the method for transposition of the spinal cord in kyphoscoliotic patients [9]. Transposition of the spinal cord includes the anterior stage where transposition of the spinal cord is performed through the transthoracic approach to the anterior vertebral portions; and the posterior

* Corresponding author at: Frunze Str., 17, Novosibirsk 630091, Russia.

E-mail addresses: priboy_novikov@mail.ru (V.V. Novikov), awasera@mail.ru (A.S. Vasyura), MSadovoi@niito.ru (M.N. Lebedeva), MSadovoi@niito.ru (M.V. Mikhaylovskiy), MSadovoi@niito.ru (M.A. Sadovoy).

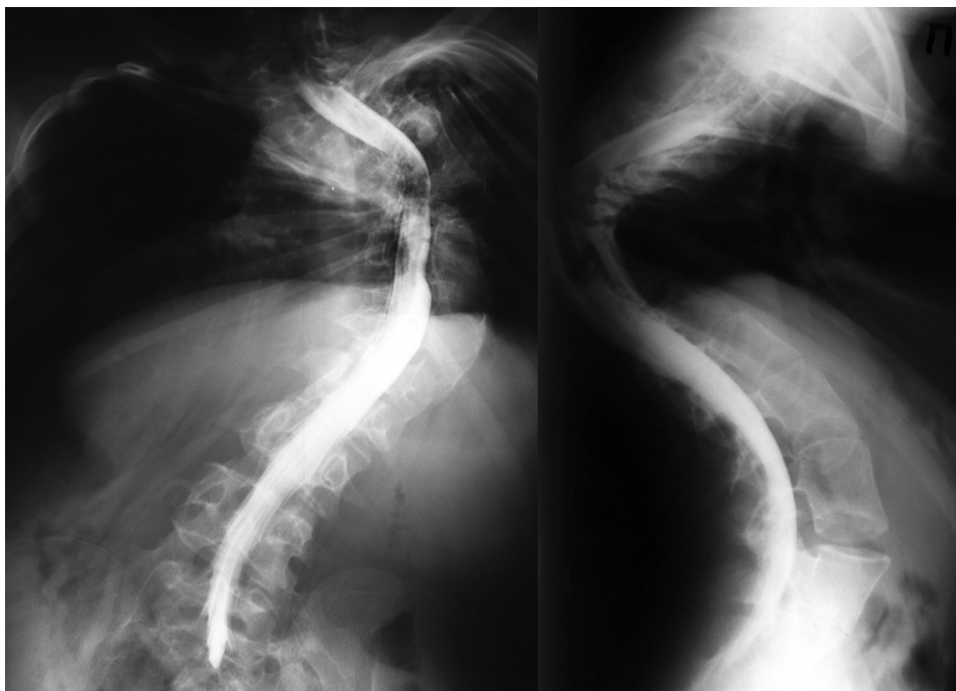


Fig. 1. Myelograms of the patient. (a) – Kink and stenosis of the dural sac in the frontal view at the T9–T10 level. (b) – Absence of reserve subdural space in the sagittal plane at the T9–T10 level.

stage where spinal deformity is corrected after performing several spine osteotomies at the apex of the curve.

2. Case report

A 15-year-old female patient S., was admitted to the Clinic of Pediatric and Adolescent Vertebrology (Novosibirsk Research Institute of Traumatology and Orthopaedics) with complicated progressive decompensated rigid right-sided thoracic kyphoscoliosis (degree IV) caused by multiple developmental anomalies of the thoracic spine. The patient also had thoracic myelopathy presenting as spastic paraparesis of the lower limbs without pelvic organ dysfunction; kyphoscoliotic heart disease; and degree II respiratory failure (vital capacity of lungs – 1000 mL). It was known from past medical history that spinal deformity had been revealed at an early age. It progressed gradually despite conservative treatment. Rapid progression was observed when the patient was 11–12 years old. Spondylograms recorded for the patient in standing position showed that the Cobb angle of the scoliotic curve at the T4–L1 level was 148°; the Cobb angle of the kyphotic curve was 155°. Multiple developmental anomalies of the thoracic spine were revealed (posterolateral wedge-shaped T9, T10, and T11 hemivertebrae; concrescence of the posterior segments at the apex of deformity on the concave side; and hypoplasia of intervertebral discs at the apex). X-ray images and myelograms of the thoracic spine showed narrowing of the free space on the concave side of the spinal deformity. The kink of the dural sac on the apex of the deformity is clearly visible (Fig. 1). Since the spine deformity was strongly pronounced, X-ray images showed overlapping of different spinal segments on the cross-sections of the vertebral arch apex. A conclusion about the location, degree, and length of spinal cord compression has been drawn based on the myelograms. The kink and compression of the dural sac were detected at the level of the T9–T10 vertebrae in myelograms. The patient was able to walk, although signs of spastic gait were observed. The knee-jerk and plantar reflexes were noticeably more brisk on both sides, being pronounced stronger on the left-hand side, with plantar and patellar clonus and patho-

logical plantar response (Babinski's sign). Traction test involved vertical traction using a Glisson's loop with the patient's total body weight. Traction test showed aggravation of neurological deficit, emergence of bilateral plantar and patellar clonus, and aggravation of the Babinski's sign.

The patient was operated on at the Novosibirsk Research Institute of Traumatology and Orthopaedics (NVV being the operating surgeon). All the procedures were performed sequentially within the same day. The surgery involved dural sac decompression and spinal cord transposition at the T7–T11 level through the transthoracic transpleural approach with resection of the fifth rib. Only in this case sufficient reserve epidural space for subsequent correction of spinal deformity was achieved without the risk of spinal cord compression.

We used the posterior approach for laminectomy throughout the deformity, dissected the dura mater, removed the facet joints, transverse processes, and arch roots, and resected the posterior portions of the vertebral bodies compressing the spinal cord. This resulted in displacement of the spinal cord anteriorly, to a new bed. In this case, the spinal cord transposition occurred spontaneously, by moving the cord to the place of resected bone structures compressing the spinal cord. This procedure decompressed the spinal cord without damage to it.

The consecutive stages of correction included: anterolateral transposition of the spinal cord at the T7–T11 levels through the right-sided transthoracic approach; skeletal cranio-tibial traction; posterior wedge-shaped vertebrotoomy at the T7–T11 levels; correction of the spine deformity using a CD Horizon instrumentation and posterior fusion with local bone autograft along the entire length of the instrumentation (T1–L4) (Fig. 2). The surgery was carried out under multicomponent total intravenous anesthesia and mechanical ventilation. Intraoperative control of the status of spinal cord was carried out by monitoring somatosensory evoked potentials; no negative dynamics were revealed. The total duration of surgical manipulations was 480 min; perioperative and postoperative blood loss volume was 2000 and 650 mL, respectively. The first stage of transposition of the spinal cord that involved its com-

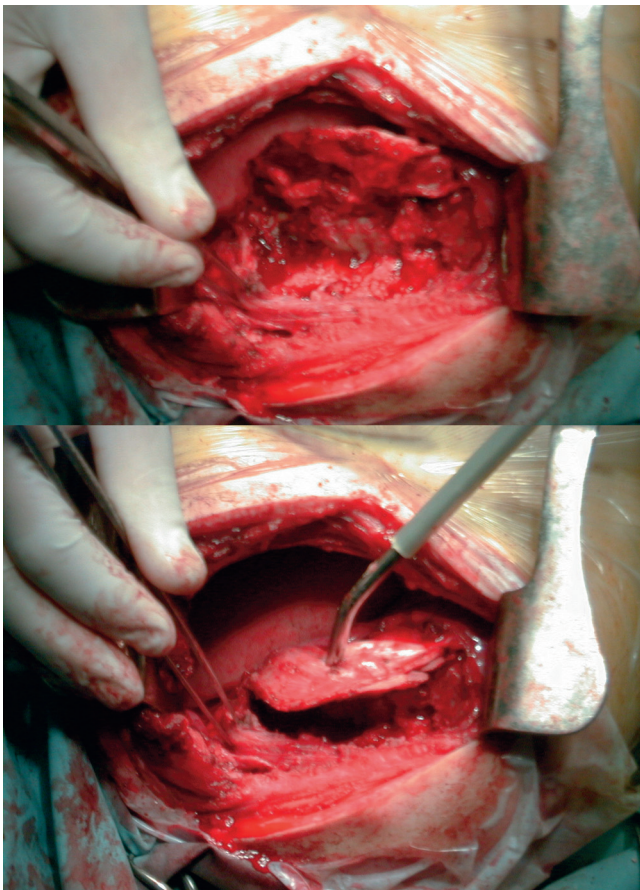


Fig. 2. The first transthoracic stage of antero-lateral spinal cord transposition. (a) Spinal cord is released from being decompressed by walls of the spinal canal, displaced forward and toward the concave side at the T7–T11 level. The new bed of the spinal cord was formed to correct spinal deformity preventing the risk of potential spinal cord decompression in future; the flap of the anterior longitudinal ligament is turned up. (b) Completion of the first stage of spinal cord transposition (the flap of the anterior longitudinal ligament is returned to its original site).

plete decompression and formation of free space around the spinal cord along the entire length of the apex of spinal deformity enabled successful intraoperative halo-tibial traction; a traction force of half of the patient's total body weight was achieved. During spinal cord

decompression followed by its transposition, the anterior spinal segments along the anterior and the partially-convex surface of vertebral bodies that were sufficient to play the supporting role remained intact. Hence, the supportive capacity of the spine was preserved, enabling the vertical weight-bearing load and postoperative formation of both the spontaneous and artificial anterior bone blocks at the site of transposition of the spinal cord. The intra- and postoperative periods were not complicated; the patient's condition was stable the next day after surgery so she was transferred from the intensive care unit to a specialized medical care department.

Examination of the patient during the postoperative period showed complete regression of neurological symptoms (regression of lower spastic paraparesis). Pronounced clinical and aesthetic effects were noted. The patient was able to stand one week after the surgery. After having adapted to maintaining a vertical position, she was discharged from the clinic for further outpatient care. No external immobilization was required. An X-ray examination showed that the Cobb angle of the scoliotic curve decreased from 148 to 64°. The Cobb angle of the kyphotic curve decreased from 155 to 69°. The lung function was improved postoperatively: vital capacity was increased to 1500 mL (in the postoperative period) and 1700 mL 2 years after surgery. No loss of correction was observed by the end of follow-up (5 years). Instrumentation remained unbroken and was fixed through the bone structures. Thick artificial and spontaneous anterior and posterior bone blocks were formed along the entire length of the spinal system; no spinal canal stenosis was revealed (Figs. 3 and 4). Patient's appearance improved significantly and the trunk balance was recovered (Fig. 5).

3. Discussion

Different scholars appeal to the efficiency and employ different approaches and instrumentation to correct severe spinal deformities.

Many surgeons believe that the combined anterior–posterior approach is a rather effective and safe method. The one- and two-stage anterior and posterior spinal fusion methods, and combined anterior–posterior approach were compared in several prospective randomized trials and in meta-analysis [5,6,2]. Bullmann et al. [10] found it to be safe, effective, and to ensure fairly good 3D curve correction in severe and rigid idiopathic patients having multiple neuromuscular complications, pseudarthrosis, and infection.

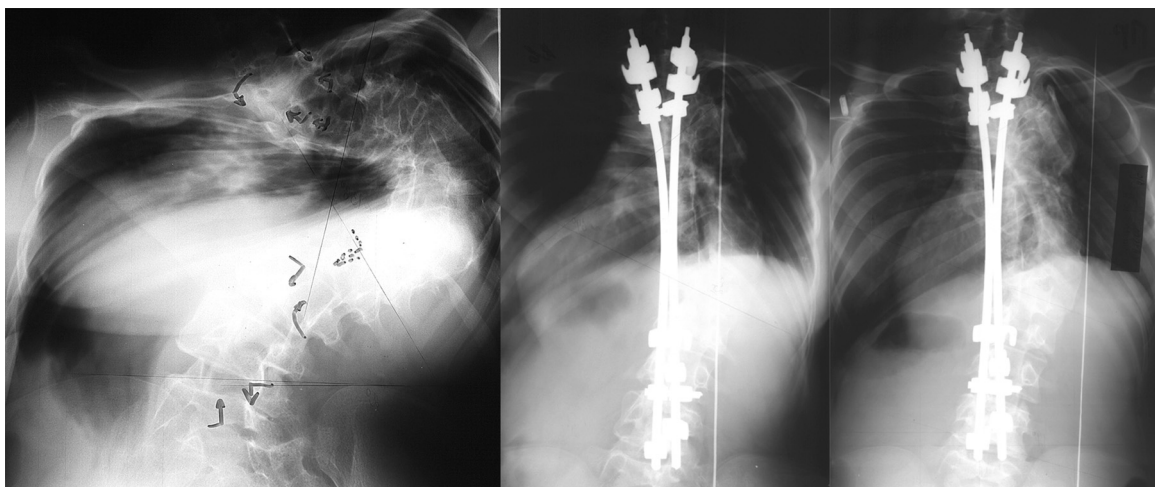


Fig. 3. The outcome of surgical treatment observed on spondylograms (frontal view). (a) – The Cobb angle of scoliosis in the standing patient before surgery is 148°. (b) – The Cobb angle of scoliosis in the standing patient after correction is 64°; the frontal body balance has been recovered. (c) – The Cobb angle of scoliosis in the standing patient 5 years after surgery is 64°. Artificial anterior and posterior bone blocks have been formed.

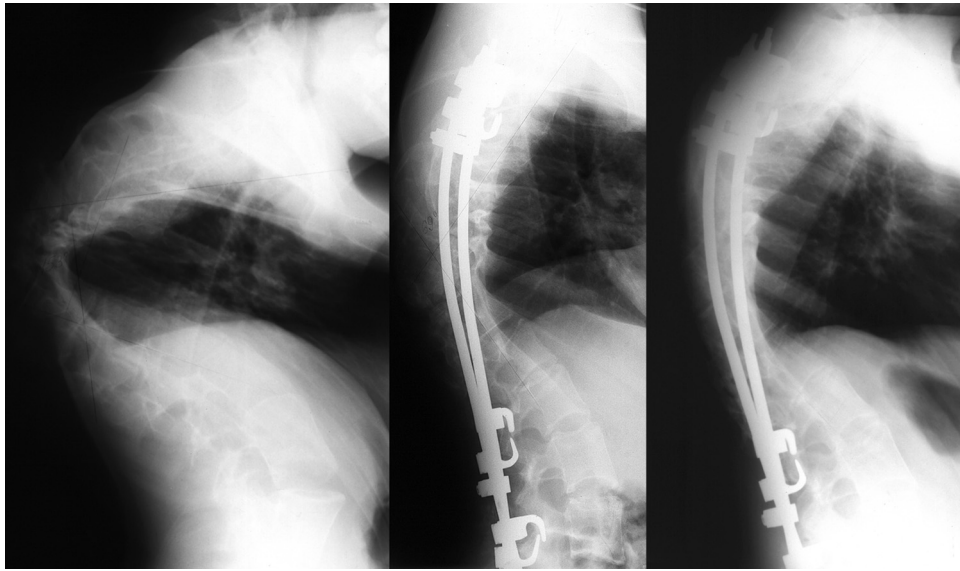


Fig. 4. The outcome of surgical treatment observed on spondylograms (lateral view). (a) – The Cobb angle of kyphosis in the standing patient before surgery is 155°. (b) – The Cobb angle of kyphosis in the standing patient after surgery is 69°; the sagittal body balance has been recovered. (c) – The Cobb angle of kyphosis in the standing patient 5 years after surgery is 69°. Artificial anterior and posterior bone blocks have been formed.

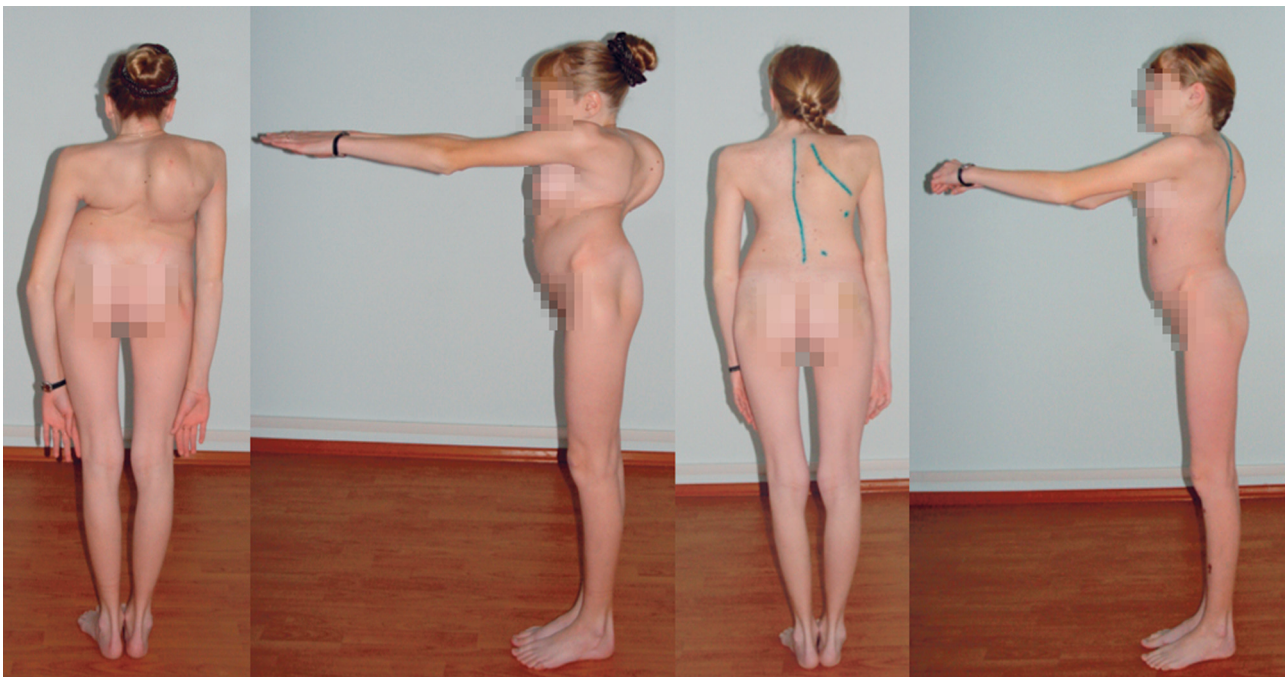


Fig. 5. Patient's appearance. (a) Back view before surgical management. (b) Lateral view before surgical management. (c) Back view after surgical management. (d) Lateral view after surgical management.

It was subsequently demonstrated by Shen [6] in a randomized prospective study that both the one- and two-stage anterior and posterior spinal fusion methods were safe and effective for treating rigid adolescent idiopathic scoliosis. In general, the combined anterior-posterior approach is more complex and is required for more skilled surgeon. Sparing operation is one of advantages of combined approach and gives the possibility to save both anterior and posterior support points of spine without losing the correction volume. It is recommended using the combined anterior-posterior approach to treat patients with the Cobb angle more than 80°. The combined approach could be more effective and safe in certain sit-

uations [10] but though hospital stay and costs are more expensive [1].

Meanwhile, some researchers showed that the posterior-only approach was sufficiently effective for correcting both moderate and severe curves and can eliminate the adverse effects of the anterior approach [5]. However, the posterior-only approach yielded similar outcomes compared to the anterior and posterior approaches. The reported case shows that transposition of the spinal cord and spinal deformity correction can be employed simultaneously using the combined anterior-posterior approach.

Transposition of the spinal cord is based on dividing the stages into the anterior (when the anterior spinal segments are approached) and the posterior ones (when correction of the spinal deformity is performed directly and the second stage of transposition of the spinal cord is carried out). At the anterior stage, transposition of the spinal cord is performed by subtotal resection of the anterior and lateral spinal segments at the apex of deformity shaped as a wedge with its base facing the convex side. The medial portion of vertebral bodies and discs is then resected in the caudal and cranial direction; the spinal canal is opened in the zone where its anterior wall contacts the dural sac until the epidural space appears in such a way as to provide a space for further displacement of the spinal cord during deformity correction without putting pressure on the remaining thin anteromedial portion of the bodies of the resected vertebrae. The posterior approach to spine deformity is then performed. After transversal defects of the posterior supporting complex are formed, the spinal cord is continued to be displaced into a new bed by correcting the deformity using the posterior vertebral instrumentation. Transposition of the spinal cord made it possible to significantly increase the spinal canal shape and improve its volume; eliminated spinal cord compression; and ensured total regression of the existing neurological symptoms. As a result, it became possible to correct the severe kyphoscoliotic spinal deformity and to reduce the risks of trunk imbalance, deformity progression, and instrumentation failure in the long-term postoperative period.

4. Conclusions

The clinical case demonstrates that single-stage correction of severe congenital kyphoscoliotic spinal deformities can be performed using the combined anterior-posterior approach, resulting in improved spinal canal shape, eliminated compression of the spinal cord, and regression of the existing neurological deficit. Transposition of the spinal cord followed by correction using vertebral instrumentation made it possible to improve trunk balance, stop deformity progression, and achieve successful instrumentation.

Conflict of interests

The authors have no conflict of interests to declare.

Funding

The authors did not receive any grants or outside funding in support of their work or preparation of this manuscript. Authors have no relevant financial or nonfinancial relationships to disclose.

Ethical approval

Described surgical methods were approved by the local ethics committee of the NRITO.

Consent

Written informed consent was obtained from the patient for publication of this case report and any accompanying images.

Authors' contributions

NVV, ASV, MNL – data collection and data analysis NVV, MVM, – operating surgeon, fata interpretation NVV, MVM, MAS – article design and concept.

Guarantor

NVV.

References

- [1] C. Ren, L. Liu, Y. Song, C. Zhou, H. Liu, T. Li, Comparison of anterior and posterior vertebral column resection versus anterior release with posterior internal distraction for severe and rigid scoliosis, *Eur. Spine J.* 23 (June (6)) (2014) 1237–1243, <http://dx.doi.org/10.1007/s00586-014-3270-6>.
- [2] Y. Gitelman, L.G. Lenke, K.H. Bridwell, J.D. Auerbach, B.A. Sides, Pulmonary function in adolescent idiopathic scoliosis relative to the surgical procedure: a 10-year follow-up analysis, *Spine (Phila Pa 1976)* 36 (September (20)) (2011) 1665–1672, <http://dx.doi.org/10.1097/BRS.0b013e31821bcf4c>.
- [3] J. Delecrin, J.M. Bernard, Y. Pereon, et al., Various mechanisms of spinal cord injury during scoliosis surgery, *Neurological Complications of Spinal Surgery. Proceedings of the 11th GICD Congress. Arcachon, France (1994)* 13–14.
- [4] B.K. Potter, K.L. Kirk, S.A. Shah, T.R. Kuklo, Loss of coronal correction following instrumentation removal in adolescent idiopathic scoliosis, *Spine (Phil Pa 1976)* 31 (January (1)) (2006) 67–72.
- [5] Z. Chen, L. Rong, Comparison of combined anterior-posterior approach versus posterior-only approach in treating adolescent idiopathic scoliosis: a meta-analysis, *Eur. Spine J.* 25 (February (2)) (2016) 363–371, <http://dx.doi.org/10.1007/s00586-015-3968-0>, Epub 2015 Apr 22.
- [6] J. Shen, G. Qiu, Y. Wang, Z. Zhang, Y. Zhao, Comparison of 1-stage versus 2-stage anterior and posterior spinal fusion for severe and rigid idiopathic scoliosis—a randomized prospective study, *Spine (Phila Pa 1976)* 31 (October (22)) (2006) 2525–2528.
- [7] E.F. Shenouda, I.W. Nelson, R.J. Nelson, Anterior transvertebral transposition of the spinal cord for the relief of paraplegia associated with congenital cervicothoracic kyphoscoliosis. Technical note, *J. Neurosurg. Spine* 5 (October (4)) (2006) 374–379.
- [8] F.J. Mueller, H. Gluch, Cotrel-dubouset instrumentation for the correction of adolescent idiopathic scoliosis. Long-term results with an unexpected high revision rate, *Scoliosis* 7 (January (1)) (2012) 13, <http://dx.doi.org/10.1186/1748-7161-7-13>.
- [9] V.A. Gavrilov, A.F. Matyushin, Method for transposition of the spinal cord in kyphoscoliosis patients // RF Patent No. 2152760. –2000.
- [10] V. Bullmann, H.F. Halm, T. Schulte, T. Lerner, T.P. Weber, U.R. Liljenqvist, Combined anterior and posterior instrumentation in severe and rigid idiopathic scoliosis, *Eur. Spine J.* 15 (April (4)) (2006), 440–.

Open Access

This article is published Open Access at sciendo.com. It is distributed under the [IJSCR Supplemental terms and conditions](#), which permits unrestricted non commercial use, distribution, and reproduction in any medium, provided the original authors and source are credited.