

Endocarditis

Risk of Embolization After Institution of Antibiotic Therapy for Infective Endocarditis

Isidre Vilacosta, MD,* Catherine Graupner, MD,* José Alberto San Román, MD,† Cristina Sarriá, MD,‡
Ricardo Ronderos, MD,§ Cristina Fernández, MD,* Leonardo Mancini, MD,§ Olga Sanz, MD,†
Juan Victor Sanmartín, MD,‡ Walter Stoermann, MD||

Madrid and Valladolid, Spain and La Plata and San Juan, Argentina

OBJECTIVES	This study was designed to assess the risk of systemic embolization in patients with left-sided infective endocarditis, once adequate antibiotic treatment had been initiated, on the basis of prospective clinical follow-up.
BACKGROUND	As one of the complications of infective endocarditis, embolization has a great impact on prognosis. Prediction of an individual patient's risk of embolization is very difficult.
METHODS	We studied 217 episodes of left-sided endocarditis that were experienced among a cohort of 211 prospectively recruited patients. According to the Duke criteria, 91% of the episodes were definite infective endocarditis. Seventy-two episodes involved infections located on prosthetic valves. All patients were studied by transthoracic and transesophageal echocardiography. Clinical, echocardiographic and microbiologic data were entered in a data base. The mean follow-up interval was 151 days.
RESULTS	Twenty-eight episodes (12.9%; group I) of endocarditis had embolic events after the initiation of antibiotic therapy. The remaining 189 episodes did not embolize (group II). Most emboli (52%) affected the central nervous system, and 65% of the embolic events occurred during the first two weeks after initiation of antibiotic therapy. Previous embolism was associated with new embolism (relative risk [RR] 1.73, 95% confidence interval [CI] 1.02 to 2.93; $p = 0.05$). There was an increase in the risk of embolization with increasing vegetation size (RR 3.77, 95% CI 0.97 to 12.57; $p = 0.07$). Vegetation size had no impact on the risk of embolization in streptococcal endocarditis or aortic infection. By contrast, large (≥ 10 mm) vegetations had a higher incidence of embolism when the microorganism was staphylococcus ($p = 0.04$) and the mitral valve was infected ($p = 0.03$). The increase in vegetation size at follow-up showed a higher risk for embolization (RR 2.64, 95% CI 0.98 to 7.16; $p = 0.02$).
CONCLUSIONS	Embolism before antimicrobial therapy is a risk factor for new emboli. The risk of embolization seems to increase with increasing vegetation size, and this is particularly significant in mitral endocarditis and staphylococcal endocarditis. An increase in vegetation size, despite antimicrobial treatment, may predict later embolism. (J Am Coll Cardiol 2002; 39:1489-95) © 2002 by the American College of Cardiology Foundation

As one of the complications of infective endocarditis, embolization has a great impact on the patient's prognosis. Systemic embolization is said to occur in 22% to 50% of cases of endocarditis, and most emboli involve the central nervous system (1). Prediction of an individual patient's risk of embolization has proven to be very difficult. Emboli can occur before diagnosis, during treatment or after therapy is completed. Notwithstanding, some investigators maintain that the rate of embolization decreases after adequate antibiotic therapy (2).

Some studies have attempted to use echocardiography to identify a high-risk group of patients who might benefit from early surgery to avoid embolization (2-17). However, definitive conclusions cannot be drawn, for several reasons: transesophageal echocardiography (TEE) was not performed in every study (2-8,11); some studies were retro-

spective (2,11,16); and trials have been composed of heterogeneous populations, including patients with right- and left-sided endocarditis (9-11,17). In addition, many other clinical and microbiologic aspects of this disease may be involved in the risk of embolization.

With all these considerations in mind, we undertook an investigation to assess the risk of systemic embolization in patients with left-sided infective endocarditis, once adequate antibiotic treatment had been initiated, on the basis of prospective clinical follow-up. There were two main objectives of this study: 1) to know the incidence of embolic events after the institution of adequate antimicrobial therapy; and 2) to assess the clinical relevance of the vegetation size, type of microorganism and valve infected.

METHODS

Patient group. This clinical study examined 217 episodes of left-sided endocarditis, experienced among a cohort of 211 patients who were prospectively recruited between April 1996 and June 2000. All patients with the diagnosis of

From the *Hospital Universitario San Carlos, Madrid; †Hospital Universitario de Valladolid, Valladolid; and ‡Hospital de la Princesa, Madrid, Spain; and §Hospital San Juan de Dios, La Plata; and ||CIMAC, San Juan, Argentina.

Manuscript received June 19, 2001; revised manuscript received January 28, 2002, accepted February 6, 2002.

Abbreviations and Acronyms

CI	= confidence interval
RR	= relative risk
TEE	= transesophageal echocardiography
TTE	= transthoracic echocardiography

endocarditis (n = 211; 135 men and 76 women; mean age 57 ± 15 years) in the five centers were included in the study. In 84 episodes (38.7%), the patient was ≥65 years old. According to the Duke criteria, 198 episodes (91%) were definite and 19 (9%) were possible infective endocarditis (18). Seventy-two episodes (33%), involved infections located on the prosthetic valve; 37 involved early (≤1 year) and 35 involved late (>1 year) prosthetic valve endocarditis. In 66 episodes (30%), both valves—mitral and aortic—were affected by the disease.

Patients were clinically followed for 1 to 942 days (mean follow-up interval of 151 days). Since the beginning of the study, all historical, clinical, laboratory, echocardiographic and microbiologic data were entered in a data base specifically designed for this investigation.

Definition of terms. “Embolic events” were diagnosed by the clinical investigators who took care of these patients. The diagnosis of embolism was clinical (i.e., on the basis of clinical signs [e.g., acute onset of organ system dysfunction according to symptoms and signs found during physical examination] and data derived from radiologic procedures [e.g., tomography, echocardiography, arteriography, magnetic resonance imaging]). Cutaneous manifestations of endocarditis were excluded from the analysis because their pathogenesis is still questionable and they do not contribute to morbidity or mortality. Embolic events occurring before treatment were recorded separately from emboli occurring after the initiation of antibiotic treatment.

“Adequate antibiotic therapy” was defined as high-dose intravenous antibiotic combinations known to be bactericidal in vitro against the isolated microorganisms. Empiric antibiotic regimens were chosen for culture-negative cases.

Echocardiography. The echocardiographic examinations were done with commercially available instruments (Toshiba, Advanced Technology Laboratories and Hewlett-Packard). All patients were subjected to both modalities of echocardiographic imaging—transthoracic echocardiography (TTE) and TEE. The TTE examination was performed before starting adequate antibiotic therapy. The TEE examination was performed within 72 h of TTE, but in many cases, both were performed consecutively. Both echocardiographic modalities were used before any occurrence of a new embolic event. The TEEs were performed with a 5-MHz transducer, following the standard procedure, and the probes used were monoplane (n = 11), biplane (n = 90) and multiplane (n = 116). In all patients, TEE was done within 72 h of starting antibiotic therapy.

During follow-up (mean 14 ± 10 days), TEE was repeated in 122 episodes.

A “valvular vegetation” was defined as a localized mass of shaggy echoes adherent to a valve leaflet or prosthetic material with a distinctive erratic motion. The morphologic characteristics of vegetations—size, mobility and echogenicity—were analyzed by TEE. M-mode tracing of the masses was performed to better define the motion of these structures. Non-specific valvular thickening was not interpreted as a vegetation. Vegetations were measured in various planes, and the maximum diameter was used for subsequent analysis. In cases of multiple vegetations or mitro-aortic endocarditis, the largest vegetation was measured. The mobility of vegetations was categorized in three grades, as follows: grade I = insignificant, independent motion; grade II = motion between grades I and III; grade III = a highly mobile vegetation, usually pedunculated, with the motion of the vegetative mass at an angle superior to 90°. Echogenicity was also graded in three categories: low = mass with equal or less echogenicity than that of myocardial echoes; intermediate = echogenicity between low and high; and high = mass with equal or higher reflectivity than that of pericardial tissue.

The existence of periannular complications (e.g., abscesses, pseudoaneurysms, fistulae) was specifically sought. A “perivalvular abscess” was defined as a circular or more irregularly delineated region (>10 mm) of reduced echo density without flow in its interior. When flow into these cavities was detected, the lesion was named “pseudoaneurysm,” and generally it appeared as a pulsatile echo-free perivalvular pouch. A “fistula” was defined as a color Doppler tract communicating between two adjacent cardiac chambers.

Valvular regurgitation and its severity were graded by color Doppler imaging, using semiquantitative standard criteria (19,20).

Statistical analysis. The Student *t* test or analysis of variance was used to compare continuous variables (expressed as the mean value ± SD), whereas categorical variables were compared using the chi-square test. Variables shown to have significant influence by univariate analysis were included in a multivariate logistic regression analysis.

Adjusted relative risks (RR) and 95% confidence intervals (CI) were calculated with the use of the estimated regression coefficients and their standard errors in the logistic regression analysis. The existence of interactions was evaluated. Variables with a p value < 0.15 in the univariate analysis were selected for the multivariate analysis. The null hypothesis was rejected in each statistical test when p < 0.05. For data analysis, the statistical program Windows SPSS, version 10.0, was used.

RESULTS

Embolic events. There were 34 embolic events accompanying 28 of 217 episodes of endocarditis (12.9%; group I) after the initiation of antibiotic therapy. Six of these episodes had two embolisms each. The sites of embolization

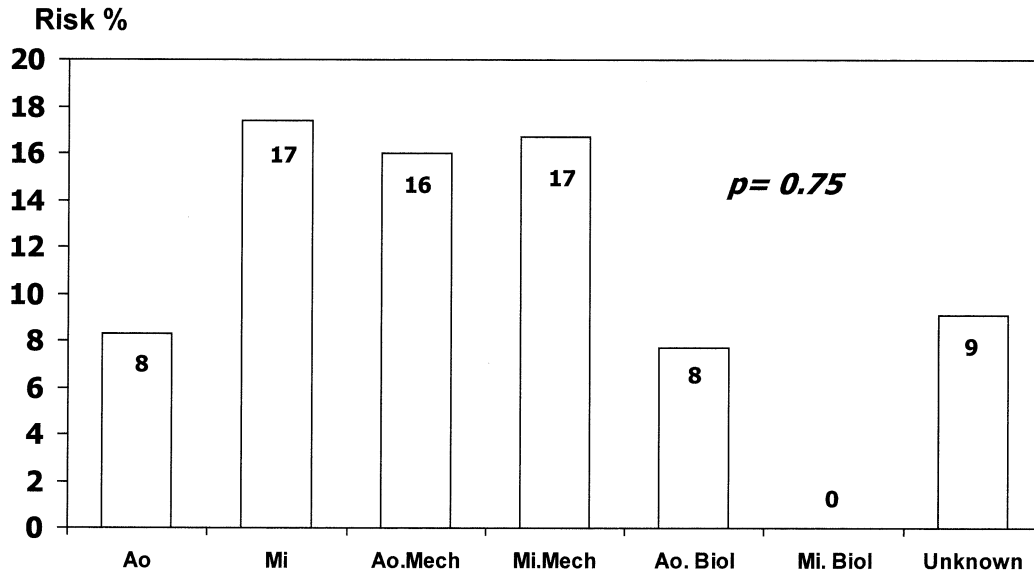


Figure 1. Risk of embolism stratified by the location of infection. Ao = native aortic valve; Ao. Biol = biologic aortic prosthesis; Ao. Mech = mechanical aortic prosthesis; Mi = native mitral valve; Mi. Biol = biologic mitral prosthesis; Mi. Mech = mechanical mitral prosthesis.

were the central nervous system (n = 18, 52%), superior extremities (n = 3, 9%), inferior extremities (n = 7, 21%) and renal and splenic circulation (n = 6, 18%). Twenty-two (65%) of these emboli occurred within the first two weeks after TEE and antibiotic therapy. The remaining 189 episodes did not embolize (group II). The number of embolic events during the whole course (before, during and after treatment) of the episodes of endocarditis was 91 (71 episodes, 32.7%).

Clinical and microbiologic data. There were no statistical differences between episodes with and those without emboli in terms of age (54 ± 17 vs. 57 ± 15 years, $p = 0.32$), gender (57% vs. 66% males, $p = 0.40$), the incidence of atrioventricular block (7.1% vs. 9.0%, $p = 1$), the duration of symptoms before diagnosis (<15 days: 42.9% vs. 44.1%, $p = 1$), the need for surgery (46.4% vs. 54.0%, $p = 0.54$) or mortality (42.9% vs. 30.2%, $p = 0.19$). The most frequent pre-existing heart diseases were the presence of a prosthetic valve (n = 76, 35%), rheumatic valve disease (n = 26, 12%) and degenerative valve disease (n = 21, 9.8%). Sixty-four episodes (29.5%) had no detectable pre-existing heart condition. There were no differences in the incidence of embolism on the basis of pre-existing heart disease, presence of atrial fibrillation, anticoagulation or predisposing systemic conditions, except for the case of intravenous drug use (RR 3.12, 95% CI 1.31 to 7.43, $p = 0.04$). There were no statistically significant differences in the incidence of embolism on the basis of the location of infection (posterior vs. anterior mitral leaflet, and native vs. prosthetic valve) (Fig. 1 and 2). Nonetheless, the risk of embolism was higher in episodes of mitral endocarditis than in episodes of aortic endocarditis. In 11 episodes, the site of valve involvement could not be determined. Previous embolism occurred in 11 patients in group I (39%), and it showed a higher risk of a new embolism (RR 1.73, 95% CI 1.02 to 2.93, $p = 0.05$).

There were no significant differences in the risk of embolism according to the infecting microorganism (Table 1). *Staphylococcus aureus* (38 episodes), *Streptococcus viridans* (34 episodes) and coagulase-negative staphylococci (29 episodes) were the microorganisms most frequently isolated. *Streptococcus* and *Enterococcus* showed the greatest improvement in embolic risk after the institution of antibiotic therapy. In early prosthetic valve endocarditis, the most commonly isolated microorganisms were staphylococci (n = 21, 58.3%), whereas in late prosthetic endocarditis, they were staphylococci (n = 8, 22.9%), *S. viridans* (n = 6, 17.1%) and enterococci (n = 6, 17.1%). Thirty-two episodes (15%) were culture-negative.

Surgery was performed in 115 episodes (53%) because of one of the following situations: heart failure (47 episodes), persistent signs of infection (17 episodes), persistent signs of infection and heart failure (14 episodes), severe valvular dysfunction (27 episodes), periannular complications (3 episodes) and embolization (7 episodes; in 6 instances the

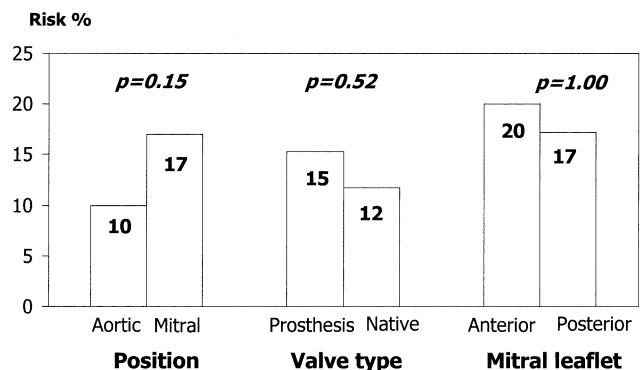


Figure 2. Risk of embolism stratified by location of infection, valve type and mitral leaflet.

Table 1. Risk of Embolism According to the Infecting Microorganism

Microorganisms	Risk Before and After Starting Antibiotic Therapy	Risk After Antibiotic Therapy
<i>Staphylococcus aureus</i>	34.2 (38)	13.2 (38)
Coagulase-negative staphylococci	34.5 (29)	17.2 (29)
<i>Streptococcus viridans</i>	29.4 (34)	8.8 (34)
<i>Enterococcus</i>	30.8 (26)	7.7 (26)
<i>Streptococcus bovis</i>	28.6 (7)	0 (7)
Other streptococci	42.1 (19)	10.5 (19)
Gram-negative bacilli	36.4 (11)	18.2 (11)
Fungi	66.7 (6)	50.0 (6)
Others	45.4 (11)	16.7 (12)
Culture negative	21.9 (32)	12.5 (32)
p Value	0.69	0.54

Data are presented as the percentage (n) of patients.

patient had 2 major embolic events). No patient underwent surgery solely because of the size of the vegetation.

Echocardiography. Echocardiography was able to identify vegetative masses in 119 episodes by TTE (54.8%) and in 185 episodes by TEE (85.3%, $p < 0.001$). Transesophageal echocardiography could not detect vegetations in 26 episodes of endocarditis. When the episodes with echocardiographically documented vegetations were compared with those without vegetations, a similar frequency of embolization was found in both echocardiographic modalities (Table 2). The mean size of the vegetations was 15.2 ± 8.6 mm (range 2 to 47). The vegetation size as shown by TEE was found to be a risk factor for embolism. There was an increase in the risk of embolization with increasing vegetation size—from 6.5% at <10 mm to 20.8% at >20 mm (RR

Table 2. Echocardiographic Data: Prognostic Factors of Embolism by Univariate Analysis

	Risk	RR (95% CI)	p Value
Perivalvular complications			0.84
Yes	13.4 (82)	1.06 (0.52–2.16)	
No	12.6 (135)	1	
Vegetation size at follow-up			0.02
Increase	26.7 (15)	2.64 (0.98–7.16)	
No change	10.1 (119)	1	
Decrease	22.6 (31)	2.24 (0.96–5.21)	
Vegetations by TTE			0.84
Yes	13.6 (118)	1.11 (0.56–2.25)	
No	12.1 (99)	1	
Vegetations by TEE			0.58
Yes	13.6 (184)	1.49 (0.48–4.67)	
No	9.1 (33)	1	
Echogenicity by TEE			0.56
Low	20.0 (35)	1	
Intermediate	14.0 (86)	0.70 (0.30–1.62)	
High	10.7 (28)	0.54 (0.15–1.88)	
Mobility by TEE			0.58
Grade I	7.1 (14)	1	
Grade II	12.8 (39)	1.79 (0.23–14.06)	
Grade III	16.3 (98)	2.29 (0.33–15.92)	

Risk data are presented as the percentage (n) of patients.

CI = confidence interval; RR = relative risk; TEE = transesophageal echocardiography; TTE = transthoracic echocardiography.

3.77, 95% CI 0.97 to 12.57) (Fig. 3). Among episodes with streptococcal endocarditis, the vegetation size had no effect on the risk of embolization, by contrast with those cases with staphylococcal endocarditis, which was associated with a higher incidence of embolism when the vegetation was large (≥ 10 mm) (Table 3). The vegetation size in the mitral position tended to be larger than that in the aortic position (17.11 ± 9.11 vs. 14.43 ± 9.9 mm, $p = 0.07$), but it was not statistically significant. The size of vegetations also tended to be larger in native valves than in prosthetic valves (16.5 ± 9.9 vs. 13.46 ± 8.3 mm, $p = 0.058$), but, again, it did not reach a statistically significant difference. The effect of vegetation size on the valve infected was also studied: larger vegetations were associated with a higher incidence of embolism when the mitral valve was infected, although this was not the case when the aortic valve was involved (Table 3). The development of heart failure, the need for surgery, and death were not shown to be associated with vegetation size (<10 mm. vs. ≥ 10 mm: 58.7% vs. 60.5%, $p = 0.6$; 47.8% vs. 57.3%, $p = 0.3$; and 28.3% vs. 32.2%, $p = 0.7$, respectively). Changes in vegetation size during antibiotic treatment were assessed by TEE. Modification of vegetation size at follow-up, especially an increase in size, was shown to be associated with a higher risk of embolization (Table 2). Vegetation mobility and echogenicity were not statistically different between groups I and II (Table 2). Periannular complications were documented by echocardiography or demonstrated by anatomy (surgery or necropsy) in 82 episodes. There were 52 abscesses, 37 pseudoaneurysms and 13 fistulae. There was no relationship between the existence of these perivalvular complications and the incidence of embolism (Table 2).

After including previous embolisms, localization of the infection, type of microorganism and vegetation size in a multivariate analysis, the only independent variable predictive of embolism was vegetation size (Fig. 3).

DISCUSSION

One of the most devastating consequences of endocarditis is systemic embolization. For the clinician who takes care of the patient, it is essential to be able to avoid this serious complication. It has been demonstrated that once antibiotic therapy is initiated, the rate of embolism decreases dramatically (12). Therefore, with this important fact in mind, this study focused on embolization after the initiation of adequate antibiotic therapy. This series is unique compared with other studies, in the following ways: 1) The period of observation for embolic events was defined; this was not the case in most series (10,11,16,17). 2) Our study is prospective and was especially designed to investigate embolism in endocarditis; many other studies are retrospective (2,11,16). 3) This is a large-scale study, the largest to date, with a homogeneous population of patients with native and prosthetic valves. Patients with right-sided endocarditis were not included, as they were in many other studies (9–11,17).

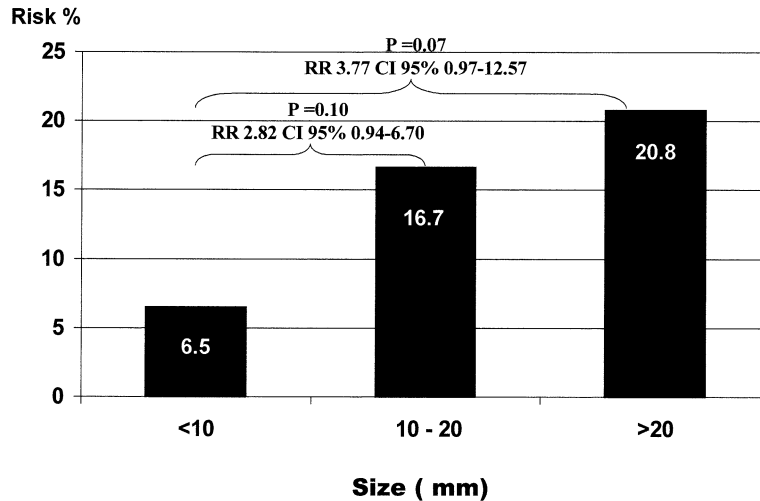


Figure 3. Risk of embolism stratified by vegetation size. CI = confidence interval; RR = relative risk.

4) In most studies, the embolic events that took place before antibiotic treatment and before echocardiography are included in the statistical analysis. This increases the number of episodes with embolism and small or no vegetations. In addition, this policy underestimates the effect of antibiotic therapy on the risk of embolization. In this study, echocardiography was performed at the beginning of the risk period; we were thereby able to evaluate the potential of vegetation status to predict embolization under adequate antibiotic treatment. Finally, 5) the use of TEE improves the vegetation detection rate and, because of better visualization, should also improve the accuracy of measurements; most previous studies used TTE (2-8,11).

In our study, the incidence of embolization after antibiotic therapy was 12.9%, much less than the incidence of embolism during the whole course of the endocarditis episode (32.7%). We, like Steckelberg et al. (2), have demonstrated that the risk of embolic events very clearly drops after the second week of successful antibiotic treatment (65% of embolisms took place during the first two weeks of therapy). In this series, six episodes of endocarditis had two major embolic events each; therefore, only six

Table 3. Effect of Vegetation Size on Embolism Stratified by Type of Microorganism and Valve Infected

	Risk	RR (95% CI)	p Value
<i>Streptococcus</i>			
<10 mm	0.0 (10)	Undefined	1.00
≥10 mm	7.5 (40)	1	
<i>Staphylococcus</i>			
<10 mm	0.0 (16)	Undefined	0.04
≥10 mm	23.7 (38)	1	
Aortic position			
<10 mm	6.9 (29)	0.64 (0.14-2.99)	0.71
≥10 mm	10.7 (56)	1	
Mitral position			
<10 mm	0.0 (16)	Undefined	0.03
≥10 mm	23.5 (68)	1	

Risk data are presented as the percentage (n) of patients.
 Abbreviations as in Table 2.

patients underwent surgery by reason of this traditional surgical indication alone. As in other studies (1), we found that the most frequent site of embolization was the central nervous system (53%). In our study, intravenous drug users were at higher risk of embolism. The number of intravenous drug users in our study group is small, and this may have contributed to a population bias.

Vegetation morphology. Vegetations are the primary lesion in patients with endocarditis. Despite the new echocardiographic imaging technology, the sensitivity of TTE in this series was inferior to that of TEE. The difference in the vegetation detection rate between the two echocardiographic modalities was most striking in prosthetic valve endocarditis. Most episodes of endocarditis in this series had vegetations detected by TEE (85%). Consequently, the prognostic implications, if any, would probably be more dependent on vegetation morphology than on the presence or absence of vegetations alone.

The relevance of vegetation size as a predictor of embolism has previously been argued in echocardiographic studies. Our findings are in agreement with several studies and in disagreement with others. Much of this controversy stems from the fact that the majority of studies included a small number of patients, thereby introducing the possibility of beta error. In the study by Mügge et al. (10), when the infection involved a native aortic or prosthetic valve (in either the aortic or mitral position), the size of the vegetation was not significantly different between episodes involving embolism and those not involving embolism. However, among patients with an infected native mitral valve, those with a large vegetation (>10 mm) had a higher incidence of embolism than those with a small vegetation. In the study by Mügge et al., some echocardiograms were obtained after the emboli were known to have occurred, and a temporal relationship among antimicrobial therapy, emboli and TEE was not controlled. Tischler and Vaitkus (21) undertook a meta-analysis to determine whether vegetation size is an important determinant of clinical outcome. Their results

support the hypothesis that large (>10 mm), left-sided vegetations pose an increased risk of systemic embolization. However, several studies were not included in their analysis; selection of the studies was not done within a quality scale; a measurable period to evaluate the embolic event was not defined; and finally, it was an observational study, and the univariate RRs were done without adjustments. Therefore, their conclusions were global, and they did not consider other variables. Many other drawbacks could be pointed out in this meta-analysis (21). The present study showed a clinically relevant increase in the risk of embolization with increasing vegetation size (Fig. 3). As in the study by Mügge et al. (10), the impact of vegetation size on embolism was statistically significant in the mitral position and in staphylococcal endocarditis.

Normally, a large, pedunculated vegetation is also a very mobile one, and therefore, mobility was not a further independent variable to determine the patient's risk of embolism. Other investigators have hypothesized that the echogenicity of a vegetation could have prognostic significance (8,16,22). In theory, a low-density vegetation would correspond to a fresh and friable vegetation, and consequently, it would have a greater capacity to embolize than a high-density vegetation, which would signify a more chronic and healed vegetative mass. Our data demonstrate that there is no relationship between the echogenicity of the vegetation and the risk of embolization. Other investigators have found similar results (16). We used a very simple data analysis to study vegetation echogenicity, which can be easily used in every echocardiography laboratory. Nonetheless, it probably has a lot of technical drawbacks (e.g., gain, setting, lateral resolution) that could prevent proper tissue characterization. Furthermore, we know that vegetations are not static lesions, but are very dynamic, and in most cases, the vegetative mass is heterogeneous in composition, with a mixture of both chronic and fresh areas. Thus, this evaluation parameter does not seem to be very useful for wide-scale analyses of patients with endocarditis.

Vegetation size at follow-up. The present study and other studies (15) have demonstrated that the vegetation morphology changes during the course of this disease. Some investigators maintain that a reduction in vegetation size during antibiotic treatment indicates a rapid healing of the infectious process and that these patients develop fewer complications (15). The mechanism by which some antibiotics may reduce vegetation size is not well known. Some antibiotics seem to reduce the platelet count and alter platelet function—aspects that could modify vegetation size. The reduction of titers of bacterial toxins by antibiotics could decrease the vegetation size. Also, microembolization of the more friable parts of the vegetative mass could diminish the vegetation size. Previous follow-up reports of vegetation size, using TTE or TEE, are scarce (15). A few investigators have shown a reduction in vegetation size during treatment; nonetheless, despite antimicrobial therapy, many vegetations remain constant in size (83.8% in our

series), and this does not worsen the patient's prognosis. In our study group, TEE demonstrated an increase in vegetation size in 10.5% of the episodes of endocarditis; these episodes involved a higher incidence of embolization than those not showing an increase in the vegetative mass (Table 2). Other investigators had a similar experience (15). In many instances (60%), an increase in vegetation size was accompanied by persistent signs of infection; therefore, an increase in vegetation size could reflect poor infection control. The decrease in vegetation size at follow-up also appeared to increase the embolic risk (Table 2). Our hypothesis is that fragmentation and embolization of the vegetation could explain this finding. Along these lines, TEE might be able to estimate the efficacy of treatment and thus be used to guide patient management. In the present study, periannular complications had no significant influence on the incidence of embolism.

Microorganisms. Previous clinical reports have suggested that certain microorganisms, such as *Staphylococcus* and fungi, carry an increased risk of embolization (1,2). In our series, although half of the episodes caused by fungi ($n = 3$) did embolize, there were no significant differences in the risk of embolism, stratified by the infecting microorganism, neither after the initiation of antibiotic therapy nor during the whole course of endocarditis (Table 1). Steckelberg et al. (2) found that the rate of embolism was higher among patients with *S. aureus* endocarditis than among patients with streptococcal endocarditis. In our study, among patients with staphylococcal endocarditis, those with large vegetations had a higher incidence of embolism. In contrast, among patients with streptococcal endocarditis, the vegetation size had no impact on the risk of embolization. In the study by Steckelberg et al., among patients with *S. aureus* endocarditis, the presence of vegetations on the echocardiogram had no effect on the rate of emboli. Their study differed from ours in that it was retrospective, the echocardiographic modality was TTE, only cases of native valve endocarditis were included and incidence rate, rather than risk, was reported.

Previous embolism. Finally, a piece of important information is that in the present study, a previous embolism was a risk factor for new emboli. Other groups had a similar experience (2), which probably reflects some unknown patient factors in the risk of embolization.

Study limitations. All emboli in the present study were symptomatic. It is difficult to assess the real incidence of embolic events during the course of the disease because some of them remain clinically silent. In this series, 52 patients had an operation during the first two weeks of therapy and, consequently, before a potential embolic event. This bias seems unavoidable because, in most cases, the surgical indication was heart failure or persistent signs of infection.

For several of the sub-analyses, the present study may not have sufficient patient numbers to have adequate power to demonstrate differences. Nonetheless, we want to empha-

size the clinical relevance of these findings, as well as the confidence intervals.

A larger series with a larger number of episodes caused by common microorganisms (*Streptococcus*) and also with a more notorious representation of infrequent microorganisms, such as fungi, gram-negative bacillus, *Coxiella* and others, could shed more light on the protagonism of microorganisms in the embolic risk of patients with endocarditis.

Conclusions. The present study demonstrates that embolism after adequate antimicrobial treatment is frequent, and most emboli occur within the first two weeks of therapy. Embolism before antimicrobial therapy is a risk factor for emboli after antimicrobial therapy has begun. Control of infection plays a leading role in the prevention of embolism. An increase in vegetation size, as detected by TEE, despite antimicrobial treatment, may predict a later embolism. The type of infecting microorganism was not a risk factor for embolism. The risk of embolization seems to increase with increasing vegetation size, and this is particularly significant in mitral valve endocarditis and staphylococcal endocarditis.

Reprint requests and correspondence: Dr. Isidre Vilacosta, Instituto de Cardiología, Hospital Universitario de San Carlos, 28040, Madrid, Spain. E-mail: ivilac@medynet.com.

REFERENCES

1. Bayer AS, Bolger AF, Taubert KA, et al. Diagnosis and management of infective endocarditis and its complications. *Circulation* 1998;98:2936-48.
2. Steckelberg JM, Murphy JG, Ballard D, et al. Emboli in infective endocarditis: the prognostic value of echocardiography. *Ann Intern Med* 1991;114:635-40.
3. Bardy GH, Talano JV, Reisberg B, Lesch M. Sensitivity and specificity of echocardiography in a high-risk population of patients for infective endocarditis: significance of vegetation size. *J Cardiovasc Ultrason* 1983;2:23-7.
4. Stewart JA, Silimperi D, Harris P, Wise NK, Fraker T, Kisslo J. Echocardiographic documentation of vegetative lesions in infective endocarditis: clinical implications. *Circulation* 1980;61:374-80.
5. Wong D, Chandraratna AN, Wishnow RM, Dusitnanond V, Nimalasuriya A. Clinical implications of large vegetations in infectious endocarditis. *Arch Intern Med* 1983;143:1874-7.
6. Stafford W, Petch J, Radford D. Vegetations in infective endocarditis: clinical relevance and diagnosis by cross-sectional echocardiography. *Br Heart J* 1985;53:310-3.
7. Buda AJH, Zotz RJ, Lemire MS, Bach DS. Prognostic significance of vegetations detected by two-dimensional echocardiography in infective endocarditis. *Am Heart J* 1986;112:1291-6.
8. Lutas EM, Roberts RB, Devereux RB, Prieto LM. Relation between the presence of echocardiographic vegetations and the complication rate in infective endocarditis. *Am Heart J* 1986;112:107-13.
9. Erbel R, Rohmann S, Drexler M, et al. Improved diagnostic value of echocardiography in patients with infective endocarditis by transesophageal approach: a prospective study. *Eur Heart J* 1988;9:43-53.
10. Mügge A, Daniel WG, Frank G, Lichtlen PR. Echocardiography in infective endocarditis: reassessment of prognostic implications of vegetation size determined by the transthoracic and the transesophageal approach. *J Am Coll Cardiol* 1989;14:631-8.
11. Sanfilippo AJ, Picard MH, Newell JB, et al. Echocardiographic assessment of patients with infectious endocarditis: prediction of risk for complications. *J Am Coll Cardiol* 1991;18:1191-9.
12. Jaffe WM, Morgan DE, Pearlman AS, Otto CM. Infective endocarditis, 1983-1988: echocardiographic findings and factors influencing morbidity and mortality. *J Am Coll Cardiol* 1990;15:1227-33.
13. Hwang J, Shyu K, Chen J, et al. Infective endocarditis in the transesophageal echocardiography era. *Cardiology* 1993;83:250-7.
14. Rohmann S, Erbel R, Gorge G, et al. Clinical relevance of vegetation localization by transesophageal echocardiography in infective endocarditis. *Eur Heart J* 1992;12:446-52.
15. Rohmann S, Erbel R, Darius H, et al. Prediction of rapid versus prolonged healing of infective endocarditis by monitoring vegetation size. *J Am Soc Echocardiogr* 1991;4:465-74.
16. De Castro S, Magni G, Beni S, et al. Role of transthoracic and transesophageal echocardiography in predicting embolic events in patients with active infective endocarditis involving native cardiac valves. *Am J Cardiol* 1997;80:1030-43.
17. Di Salvo G, Habib G, Pergola V, et al. Echocardiography predicts embolic events in infective endocarditis. *J Am Coll Cardiol* 2001;37:1069-76.
18. Li JS, Sexton DJ, Mick N, et al. Proposed modifications to the Duke criteria for the diagnosis of infective endocarditis. *Clin Infect Dis* 2000;30:633-8.
19. Perry GJ, Helmcke F, Nanda NC, Byard C, Soto B. Evaluation of aortic insufficiency by Doppler color flow mapping. *J Am Coll Cardiol* 1987;9:952-9.
20. Helmcke F, Nanda NC, Hsiung MC, et al. Color Doppler assessment of mitral regurgitation with orthogonal planes. *Circulation* 1987;75:175-83.
21. Tischler MD, Vaitkus PT. The ability of vegetation size on echocardiography to predict clinical complications: a meta-analysis. *J Am Soc Echocardiogr* 1997;10:562-8.
22. Tak R, Rahimtoola SH, Kumar A, Gamage N, Chandraratna PA. Value of digital image processing of two-dimensional echocardiograms in differentiating active from chronic vegetations of infective endocarditis. *Circulation* 1988;78:116-23.