

Rhinoscleroma causing severe bilateral nasal obstruction

Authors

Mário Augusto Pinto de Moraes, MD¹
 Albino Verçosa de Magalhães, MD¹
 Larissa Cardoso Marinho, MD¹
 Ana Emília Borges de Azevedo, MD¹
 Fabiana Pirani Carneiro, MD¹
 Igor Teixeira Raymundo MD²

¹Department of Pathology, Hospital Universitário de Brasília, Brasília, Brazil.

²Department of Otorhinolaryngology, Hospital Universitário de Brasília, Brasília, Brazil.

Submitted on: 09/27/2009
 Approved on: 11/03/2009

Correspondence to:

Fabiana Pirani Carneiro, M.D.
 Centro de Anatomia Patológica
 Hospital Universitário de Brasília, UNB
 Via L2 Norte, SGAN 604/605, Módulo C
 Brasília – DF – Brasil.
 CEP: 70840-050
 Phone: 55 61 - 34485499
 E-mail: fabianapirani@hotmail.com

We declare no conflict of interest.

ABSTRACT

Rhinoscleroma is a chronic, infectious and granulomatous disease of the respiratory tract. There is often a delay in diagnosis due to unfamiliarity with the disease and also because culture is not always positive. We report a case in a 26-year-old woman with granular mass obstructing bilateral nasal cavities and causing breathing difficulty. Histopathological examination showed characteristic Mikulicz histiocytes containing numerous Gram-negative intracellular rod-shaped bacilli consistent with the diagnosis of rhinoscleroma. The patient was treated with gemifloxacin and tetracycline and remains asymptomatic over a year follow-up period. It is important to consider rhinoscleroma in cases of chronic nasal obstruction. As culture is not always positive, histopathological examination may be crucial to the diagnosis.

Keywords: rhinoscleroma, nasal obstruction, histopathology.

[*Braz J Infect Dis* 2010;14(2):190-192]©Elsevier Editora Ltda. Este é um artigo Open Access sob a licença de [CC BY-NC-ND](https://creativecommons.org/licenses/by-nc-nd/4.0/)

INTRODUCTION

Rhinoscleroma is an unusual chronic granulomatous disease that usually affects the respiratory tract mucosa and is caused by *Klebsiella rhinoscleromatis*, a Gram-negative rod-shaped bacteria.¹ Most of the cases have been reported from many countries of the Middle East, tropical Africa, India, south-east Asia, Central and South America but, in recent years, some cases in non-endemic areas have been reported because of the increased migration of the population over the world.^{2,3} We found few isolated cases described in Brazilian patients.⁴⁻⁸ However, more than 16,000 cases have been reported from different parts of the world since 1960.¹ We reported a case of rhinoscleroma causing severe bilateral nasal obstruction which diagnosis was based on characteristic histological findings.

CASE REPORT

A 26-year-old Brazilian woman presented with a 2-year history of mucopurulent nasal discharge, nasal obstruction, epistaxis and headache. Examination of the nose revealed synechia obstructing bilateral nasal vestibules and septal deviation. The patient was submitted to septoplasty and presented symptomatic improve-

ment. One year after surgery, she returned with the same complains and presenting, on examination of the nose, a granular mass obstructing bilateral nasal cavities (Figure 1). Computed tomography revealed bilateral soft-tissue mass located in the nasal cavities without extension into the paranasal sinuses. An incisional biopsy was performed to establish the diagnosis. Histopathological examination revealed a diffuse

Figure 1: (A) e (B) Granular mass obstructing bilateral nasal cavities.

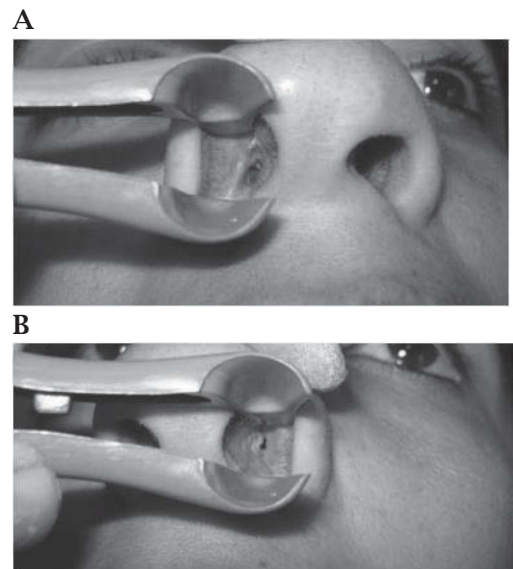
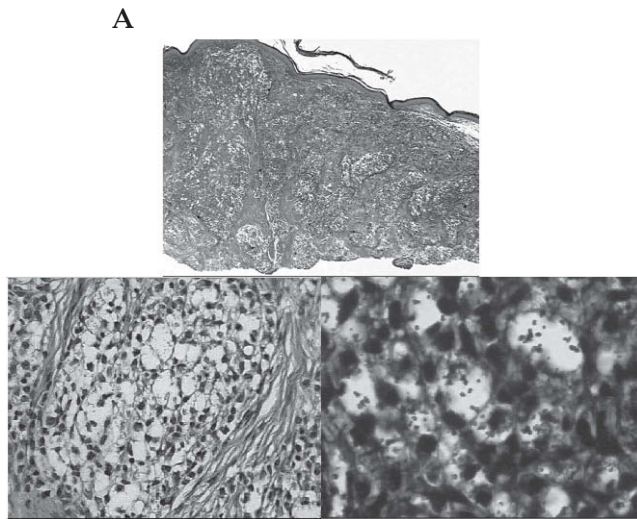


Figure 2: Histopathological examination. (A) Diffuse inflammatory infiltrate (HE, 25x). (B) Large foamy macrophage (Mikulicz cells) and mononuclear cells (HE, 400x). (C) Rod-shaped bacilli inside macrophage (Warthin-Starry stain, 1000x).



inflammatory infiltrate predominantly of mononuclear cells with large foamy macrophage containing small rod-like bacteria. These organisms were Gram-negative and stained with both Warthin-Starry and periodic acid-Schiff stains (Figure 2). Acid-fast bacilli stain was negative for microorganisms. Treatment with tetracycline (500 mg - 6/6h for 1 month) and gemifloxacin (320 mg/day for 2 weeks) was followed by significant symptomatic improvement, but a discrete stenosis in nasal cavity persisted. One year after the treatment, the patient remains asymptomatic.

DISCUSSION

The diagnosis of rhinoscleroma requires a high index of suspicion and clinicopathological correlation.⁹ This disease is more frequent in middle aged women, living with poor hygienic and nutritional condition.¹⁰ Cellular immunity may be impaired in affected patients; however, our patient was immunocompetent.¹¹ The symptoms are nonspecific such as mucopurulent rhinorrhea, cough, breathing difficulty due to nasal obstruction, dysphonia, epistaxis and headache.^{12,13}

Three overlapping stages were described in rhinoscleroma: catarrhal-atrophic, granulomatous (proliferative or nodular) and sclerotic (cicatrical or fibrotic).² Microscopically, the catarrhal/atrophic stage exhibits squamous metaplasia and a nonspecific subepithelial infiltrate of polymorphonuclear leukocytes with granulation tissue. The diagnostic features are found in the granulomatous stage. The histologic hallmark for diagnosis of rhinoscleroma is the subepithelial presence of Mikulicz cells, large vacuolated macrophages containing rod shaped bacilli. The sclerotic stage displays extensive fibrosis, which may lead to stenosis and disfiguration. Biopsies of the fibrotic stage may be quite nonspecific. In present case, the patient was in granulomatous stage since numerous Mikulicz cells were found.

The differential diagnosis includes mainly several infectious granulomatous processes: bacterial (tuberculosis, actinomycosis, syphilis, and leprosy), fungal (histoplasmosis, paracoccidioidomycosis, and sporotrichosis) and parasitic (mucocutaneous leishmaniasis).¹⁴ Rhinoscleroma also should be distinguished from Wegener granulomatosis, lymphomas and carcinomas. Specific diagnosis is made by identification in biopsy samples of histopathologic features and rod-shaped bacilli that are positive to periodic acid-Schiff (PAS) and Warthin-Starry stain. Immunoperoxidase staining with anticapsular antisera has also proved useful. Bacterial culture (blood or MacConkey agar) is positive in only 50% of the cases.¹⁵

Rhinoscleroma is a slowly progressive disease characterized by periods of remission and relapse. Early diagnosis and prolonged therapy are critical to avoid recurrence and late sequelae. In previous study, oxytetracycline and ciprofloxacin were used with good results and without relapse during six to 12 months of follow-up.² Untreated patients tend to progress to involvement of other parts of the respiratory system. In trachea the disease can lead to progressive airway obstruction, a life-threatening complication.¹⁶ Mortality from rhinoscleroma is extremely rare, resulting from upper airway obstruction in patients with undiagnosed disease or as a complication of a surgical procedure.

CONCLUSION

It is important to consider rhinoscleroma in cases of chronic nasal obstruction. As culture is not always positive, histopathological examination may be crucial to the diagnosis.

REFERENCES

- Hart CA, Rao SK. Rhinoscleroma. *J Med Microbiol* 2000; 49:395-6.
- Maguiña C, Cortez-Escalante J, Osoreo-Plenge F *et al.* Rhinoscleroma: eight Peruvian cases. *Rev Inst Med Trop Sao Paulo* 2006; 48:295-9.
- Andraca R, Edson RS, Kern EB. Rhinoscleroma: a growing concern in the United States? Mayo Clinic experience. *Mayo Clin Proc* 1993; 68:1151-7.
- Simons ME, Granato L, Oliveira RC, Alcantara MP. Rhinoscleroma: case report. *Braz J Otorhinolaryngol* 2006; 72:568-71.
- Granato L, Jorge Jr JJ, Souza DG, França LCM. Rhinoscleroma - Considerações sobre um caso. *Revista Brasileira de Otorrinolaringologia* 1977; 43:1-11.
- Oliveira HF, Carvalho ASPA, Argollo NCS, Neves CA, Dossi MO. Rhinoscleroma e Linfoma não-Hodgkin Nasal. *Intl Arch Otorhinolaryngol* 2009; 13:96-8.
- Mello LR, Albertino S, Tonon S. Rhinoscleroma-tratamento cirúrgico. *Rev Col Bras Cir* 1984; 11:125-9.
- Barbosa AA, Teixeira JC, Andrade JS. Escleroma (rhinoscleroma). *An Fac Med Univ. Fed Minas Gerais* 1985; 34:217-21.
- Stiernberg CM, Clark WD. Rhinoscleroma: a diagnostic challenge. *Laryngoscope* 1983; 93:866-870.

10. Casanova JL. Rhinoscleroma: a French national retrospective study of epidemiological and clinical features. *Clin Infect Dis* 2008; 47:1396-402.
11. Berron P, Berron R, Ortiz-Ortiz L. Alterations in the T-lymphocyte subpopulation in patients with rhinoscleroma. *J Clin Microbiol* 1988; 26:1031-3.
12. Shum TK, Whitker CW, Meyer PR. Clinical update on rhinoscleroma. *Laryngoscope* 1982; 92:1149-55.
13. Abalkhail A, Satti MB, Uthman MA *et al.* Rhinoscleroma: a clinicopathological study from the Gulf region. *Singapore Med J* 2007; 48:148-51.
14. Fuchs HA, Tanner SB. Granulomatous disorders of the nose and paranasal sinuses. *Curr Opin Otolaryngol Head Neck Surg* 2009; 17:23-7.
15. Meyer PR, Shum TK, Becker TS, Taylor CR. Scleroma (Rhinoscleroma). A histologic immunohistochemical study with bacteriologic correlates. *Arch Pathol Lab Med* 1983; 107:377-83.
16. Yigla M, Ben-Izhak O, Oren I, Hashman N, Lejbkowitz F. Laryngotracheobronchial involvement in a patient with non-endemic rhinoscleroma. *Chest* 2000; 117:1795-8.