



# Large mucinous neoplasm of the appendix mimicking adnexal mass in a postmenopausal woman



Levent Akman<sup>a,\*</sup>, Behiye Seda Hursitoglu<sup>a</sup>, İsmet Hortu<sup>a</sup>, Taylan Sezer<sup>b</sup>,  
Kemal Oztekin<sup>a</sup>, Basak Dogan Avsargil<sup>c</sup>

<sup>a</sup> Ege University Medical School, Department of Obstetrics and Gynecology, Bornova, İzmir, Turkey

<sup>b</sup> Ege University Medical School, Department of Surgery, Bornova, İzmir, Turkey

<sup>c</sup> Ege University Medical School, Department of Pathology, Bornova, İzmir, Turkey

## ARTICLE INFO

### Article history:

Received 10 August 2014

Received in revised form

12 November 2014

Accepted 13 November 2014

Available online 21 November 2014

### Keywords:

Adnexal mass

Appendiceal neoplasm

Diagnosis

## ABSTRACT

**INTRODUCTION:** Appendiceal tumors are rare, late-diagnosed neoplasms that may not be differentiated from adnexal masses even by advanced imaging methods and other diagnostic procedures. They may be asymptomatic and remain undiagnosed until surgery.

**PRESENTATION OF CASE:** We report a case of 81-year-old postmenopausal woman presented with abdominal pain. A magnetic resonance imaging revealed right adnexal mass. Laparotomy was performed and detected a 12 cm × 9 cm mucinous tumoral mass arising in the appendix. An appendectomy and a right hemicolectomy with ileo-transverse anastomosis were performed. Histopathological examination was revealed appendiceal mucinous neoplasm with low malignancy potential.

**DISCUSSION:** Gastrointestinal tumors such as appendiceal tumors can mimicking adnexal mass. Therefore, appendiceal tumor kept in mind in a patient with diagnosed adnexal mass, especially patient had non-specific clinical symptoms, laboratory and radiologic findings.

**CONCLUSION:** Gastrointestinal tumors such as appendiceal tumors kept in mind in a patient with diagnosed adnexal mass.

© 2014 Published by Elsevier Ltd. on behalf of Surgical Associates Ltd. This is an open access article under the CC BY-NC-ND license (<http://creativecommons.org/licenses/by-nc-nd/3.0/>).

## 1. Introduction

None of the different diagnostic investigation modalities is alone sufficient to characterize an adnexal mass. History, physical examination, imaging methods and plasma tumor markers have to be used together in the preoperative investigation of an adnexal mass. Appendiceal tumors are first diagnosed as acute appendicitis or may be a chance finding in the course of surgery for unrelated conditions. Mucinous neoplasms with malignant potential are seldom encountered; their course is generally silent and their identification is often by chance finding.

## 2. Case report

An 81-year-old postmenopausal woman admitted with abdominal pain during the last few months. She had an unremarkable history. Physical examination showed tenderness and semi-mobile palpable mass with 10 cm in diameter in the lower right abdominal quadrant. On vaginal examination, subtotal uterine prolapse was

seen and a semi-mobile, semi-solid, smooth bordered mass with 10 cm in diameter was palpated on right adnexal region. She had no fever. Her laboratory tests for renal function, liver function, complete blood count, electrolyte status and blood sugar levels were within normal range. Also, serum tumors markers were within normal limits (Ca125: 13.18 U/mL, Ca19.9: 20.8 U/mL, Ca15.3: 6.7 U/mL and CEA: 1.76 ng/mL). Preoperative ultrasonographic examination was revealed normal uterus and left adnexa, and a 11 cm × 9 cm heteroechoic cystic mass in right adnexal location. A magnetic resonance imaging revealed a 12 cm × 10 cm cystic, heteroechoic lesion that did not exhibit contrast enhancement or solid components (Fig. 1). Then, laparotomy was performed. Inspection of the abdominal cavity revealed an approximately 10 cm mucinous tumoral mass arising in the appendix (Fig. 2a and b). The uterus and ovaries appeared to be normal. An appendectomy and a right hemicolectomy with ileo-transverse anastomosis were performed. A total abdominal hysterectomy and bilateral salpingo-oophorectomy had to be performed before the end of surgery due to the presence of a subtotal uterine prolapse. Histopathological examination was revealed the appendiceal mucinous neoplasm, measuring 12 cm in its largest diameter, disclosed a largely mucocoele-like lining epithelium and acellular mucus, with occasional thicker, columnar-looking epithelial portions (Fig. 3a). No cytological atypia or complexities of the glandular structures were observed. The lesion wall disclosed a rupture and the

\* Corresponding author at: Ege University Medical School, Department of Obstetrics and Gynecology, 35100 Bornova, İzmir, Turkey. Tel.: +90 232 3901700; fax: +90 232 3901741.

E-mail address: [leventakman@gmail.com](mailto:leventakman@gmail.com) (L. Akman).

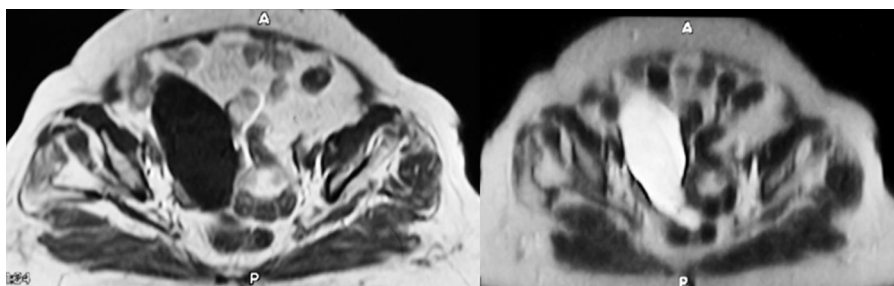


Fig. 1. Appearance of the cystic mass on abdominal MRI.

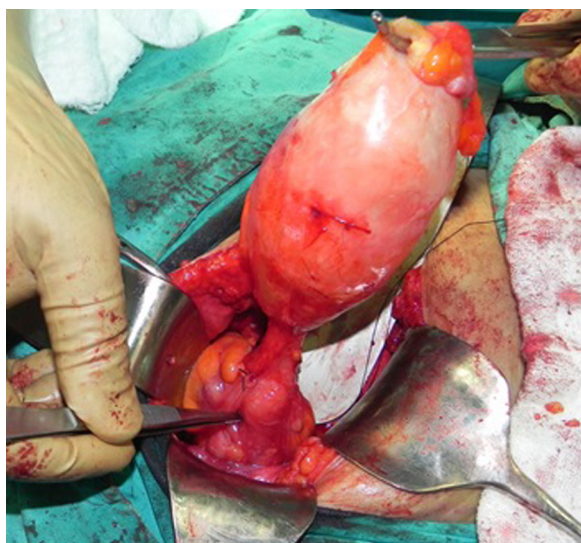

Fig. 2. Mucinous neoplasm growing out of the appendix (intraoperatively).

passage of mucus in the surrounding fat, in an area with occasional calcifications and otherwise minor leakage (Fig. 3b). This area was surrounded by soft tissue reaction. The postoperative period was uneventful. The patient has been followed for one year and there are no clinical or biochemical findings suggesting a recurrence.

### 3. Discussion

Appendiceal tumors constitute less than 0.4% of all gastrointestinal neoplasms. Less than 2% of all appendectomies result in a finding of tumor; approximately 20% of these cases, however, have a perforated appendix.<sup>1,2</sup> Mucinous appendiceal neoplasms with low malignancy potential are rare. Cystadenomas are reported

to be found in approximately 1% of all appendectomies. Mucinous cystadenomas are the most frequent of mucinous appendiceal neoplasms.<sup>3</sup> Appendiceal tumors are safely considered to have low malignant potential; those limited to the appendix itself are generally accepted as being benign.<sup>4</sup> Appendiceal tumors are generally diagnosed as acute appendicitis, or they may be incidental in the course of surgery for unrelated conditions.<sup>5</sup> The clinical importance of such tumors is related to the pseudomyxoma peritonei that may result from mucin leakage in the peritoneal cavity following appendix rupture. This complication negatively affects treatment outcomes as compared to unruptured cases.<sup>6</sup> While 5-year survival of benign mucocele is 100%, that of its malignant variety is only 45%.<sup>4</sup> A mucocele lesion is accepted as neoplasia if its diameter is larger than 2 cm.<sup>7</sup> Recent publications on appendiceal tumors are not uniform as to their diagnostic criteria or treatment recommendations.<sup>8</sup> Surgery is unique therapy for the appendix mucocele. Also, laparoscopic approach must be performed by experienced surgeons because of the risk of rupture. The type of surgical treatment is related to the histopathological features of the mucocele. Appendectomy can be performed for simple mucocele or for cystadenoma, when the appendiceal base is intact. Performing a right colectomy seems to be of particular importance in the case of malignant mucinous tumors and of tumor invasion of the appendiceal base.<sup>9</sup> 11–20% of patients with appendiceal mucinous tumors have associated colonic and ovarian tumors.<sup>10</sup> Therefore, careful exploration of the other abdominal organs, in particular the colon and ovaries, are important during the surgery. Cytoreductive surgery, heated intraoperative intraperitoneal chemotherapy and early postoperative intraperitoneal chemotherapy are recommended for the patients with pseudomyxoma peritonei.<sup>11</sup>

Adnexal masses are seen in women of every age group; at high risk for ovarian malignancy are those, especially postmenopausal patients with a tumor morphologically characterized as solid or complex by ultrasound and with increased CA-125 levels (>35 U/mL). The most important characteristics differentiating benign formations from malignant adnexal masses are thick septa,

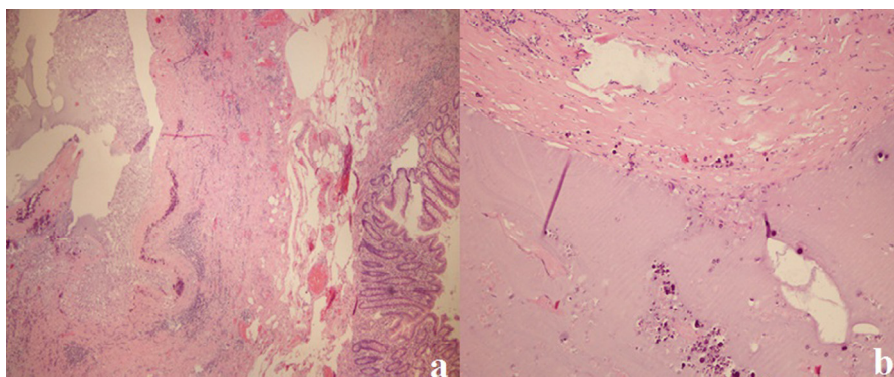


Fig. 3. (a) Acellular mucinous collections in the appendix wall (H&E, 20×). (b) Calcification within the acellular mucin collection and the appendix wall (H&E, 40×).

papillary projections, and the presence of non-hyperechogenic (vascularized) tissue. McDonald et al. evaluated 395 women with adnexal mass preoperatively by transvaginal ultrasonography and serum CA-125 and reported that the combination of these two tests is successful in evaluating malignancy.<sup>12</sup> In a case report by Dragoumis et al., a patient with a CA-125 level of 120 U/mL evaluated as having a right adnexal cyst had a final diagnosis of appendiceal mucocele.<sup>13</sup> Similarly, Yıldız and Abbasoglu presented two cases with a periappendicular abscess and mucocele and the preoperative diagnosis of the cases was an adnexal mass.<sup>14</sup> Balci et al. report identifying a 6 cm × 8 cm appendiceal mucocele during laparotomy in a patient operated on for adnexal mass.<sup>15</sup>

In this presented case, the patient was evaluated preoperatively by ultrasonography, magnetic resonance imaging, physical examination, and serum tumor markers and scheduled for surgery with a tentative diagnosis of adnexal mass. The diagnosis of appendiceal tumor was intra-operative. While a simple appendectomy is sufficient treatment for patients with benign mucocele, mucinous neoplasms additionally require resection of the cecum or a hemicolectomy, as also practiced on our patient. Although the patient have mucinous appendiceal tumor with a diameter of 12 cm × 9 cm, neither acute signs of appendicitis nor pseudomyxoma peritonei were seen.

In conclusion, appendiceal tumors are rare, late-diagnosed neoplasms that may not be differentiated from adnexal masses even by advanced imaging methods and other diagnostic procedures. They may be asymptomatic and remain undiagnosed until surgery. Gastrointestinal tumors such as appendiceal tumors kept in mind in a patient with diagnosed adnexal mass.

#### Conflict of interest

Authors have no conflict of interest to declare.

#### Funding

No commercial support was obtained for this study.

#### Ethical approval

Written informed consent was obtained from the patient for publication of this case report and accompanying images. A copy

of the written consent is available for review by the Editor-in-Chief of this journal on request.

#### Author contributions

All authors were involved in the researching and editing of the manuscript. The surgery was done by LA, BSH, KO and TS. LA, IH and BSH wrote the case report. BDA was the pathologist.

#### References

1. Marudanayagam R, Williams GT, Rees BI. Review of the pathological results of 2,660 appendectomy specimens. *J Gastroenterol* 2006;**41**: 745–9.
2. Lau H, Yuen WK, Loong F, Lee F. Laparoscopic resection of an appendiceal mucocele. *Surg Laparosc Endosc Percutan Tech* 2002;**12**:367–70.
3. Trollope ML, Lindenauer SM. Diverticulosis of the appendix: a collective review. *Dis Col Rect* 1974;**17**:200–18.
4. Navarra G, Asopa V, Basaglia E, Jones M, Jiao LR, Habib NA. Mucous cystadenoma of the appendix: is it safe to remove it by a laparoscopic approach? *Surg Endosc* 2003;**17**:833–4.
5. Bradley RF, Stewart JH, Russell GB, Levine EA, Geisinger KR. Pseudomyxoma peritonei of appendiceal origin: a clinicopathologic analysis of 101 patients uniformly treated at a single institution, with literature review. *Am J Surg Pathol* 2006;**30**:551–9.
6. Lee J, Gardiner KR, Wilson BG. Incidental mucinous cystadenocarcinoma of the appendix. *Postgraduate Med J* 1996;**72**:55–6.
7. Goede AC, Caplin ME, Winslet MC. Carcinoid tumour of the appendix. *Br J Surg* 2003;**90**:1317–22.
8. Carr NJ, Sobin LH. Unusual tumors of the appendix and pseudomyxoma peritonei. *Semin Diagn Pathol* 1996;**13**:314–25.
9. Palanivelu C, Rangarajan M, John SJ, Senthilkumar K, Annapoorni S. Laparoscopic right hemicolectomy for mucocele due to a low-grade appendiceal mucinous neoplasm. *J Soc Laparoendosc Surg* 2008;**12**:194–7.
10. Tirumani HS, Fraser-Hill M, Auer R, Shabana W, Walsh C, Lee F, et al. Mucinous neoplasm of the appendix: a current comprehensive clinicopathologic and imaging review. *Cancer Imaging* 2013;**13**:14–25.
11. Sugerbaker PH. New standard of care of appendiceal epithelial neoplasm and pseudomyxoma peritonei syndrome? *Lancet Oncol* 2006;**7**: 69–76.
12. McDonald J, Doran S, DeSimone C, Ueland FR, DePriest PD, Ware RA, et al. Predicting risk of malignancy in adnexal masses. *Obstet Gynecol* 2010;**114**: 687–94.
13. Dragoumis K, Mikos T, Zafrakas M, Assimakopoulos E, Venizelos I, Demertzidis H, et al. Mucocele of the vermiform appendix with sonographic appearance of an adnexal mass. *Gynecol Obstet Invest* 2005;**59**:162–4.
14. Yıldız BD, Abbasoglu O. Two unusual presentations of appendiceal masses. *Int J Surg* 2008;**6**:9–11.
15. Balci O, Ozdemir S, Mahmoud AS. Appendiceal mucocele mimicking a cystic right adnexal mass. *Taiwan J Obstet Gynecol* 2009;**48**:412–4.

#### Open Access

This article is published Open Access at [sciendo.com](http://sciendo.com). It is distributed under the [IJSCR Supplemental terms and conditions](#), which permits unrestricted non commercial use, distribution, and reproduction in any medium, provided the original authors and source are credited.