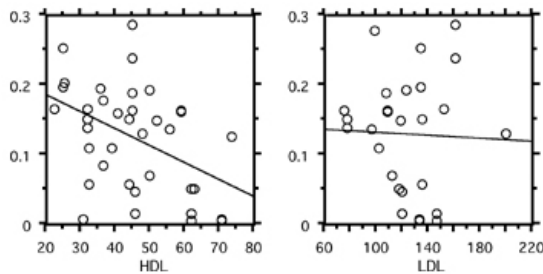


angina vs acute coronary syndrome ( $2.1 \pm 2.8\%$  vs  $0.7 \pm 0.8\%$ ,  $p=0.0331$ ). In diabetic pts, %total segment fibrotic plaque ( $41 \pm 7\%$  vs  $29 \pm 14\%$ ,  $p=0.0286$ ) and %lipid core ( $19 \pm 5\%$  vs  $11 \pm 8\%$ ,  $p=0.0099$ ) were larger vs non-diabetics. Importantly, %total segment lipid core decreased with increasing HDL ( $r=0.44$ ,  $p=0.0063$ ), but there was no correlation with LDL (Figure). Conclusions: VH affords real-time assessment of plaque histopathology (not just grey scale images) that has been correlated to human necropsy specimens. This information will reveal important correlations with clinical disease states.



#### 1006-57 Atherosclerotic Plaque Can Be Quantified Using Multifractal and Wavelet Decomposition Techniques

Liberty O. Yaneza, Robert J. Chilton, Edmund K. Kerut, Dimitrios Charalampidis, Dwight Chrisman, Michael S. Lujan, Carlos Leon Alviar, Thomas D. Giles, Robert A. O'Rourke, University of Texas Health Science Center, San Antonio, TX, State University Health Sciences Center, New Orleans, LA

##### Introduction:

Classification of plaque morphology into soft, fibrocalcific and calcific by intravascular ultrasound (IVUS) is done by comparing plaque intensity to surrounding adventitia. However, this technique is subject to bias and to inherent limitation of IVUS machine. Texture analysis is a form of tissue characterization based on the distribution of ultrasound amplitude signals within a region-of-interest (ROI). Two methods, the wavelet decomposition and multifractal techniques are currently being utilized to quantify image texture.

##### Methodology:

IVUS images performed from year 2000-2002 at the Cardiac Catheterization Laboratory of South Texas Veterans Health Care Systems, San Antonio, Texas were analysed. These images were exported into Desktop computer and analyzed after placing a 16 x 16 ROI box. Mean and standard deviation of pixel intensity values were generated. Quantitation of ROI texture using 2 methods were performed by generation of multifractal exponents, and normalized detail coefficients using wavelet decomposition method.

##### Results:

Seventy three images were analysed. The overall intensity and energy generated by different plaque morphologies were significantly higher in calcific lesions as compared to soft plaque. Furthermore, a significant association is also noted with different plaque morphologies and texture analysis using both multifractal and wavelet decomposition method. The values generated with texture analysis using multifractal exponents are higher in calcific plaques as compared to soft lesions ( $0.539 \pm 0.03$  vs  $0.504 \pm 0.04$ ,  $P=0.001$ ). However, with wavelet decomposition method, the normalized detail coefficients were significantly lower in calcific lesions ( $0.004 \pm 0.01$  vs  $0.008 \pm 0.00$ ,  $P=0.006$ ).

##### Conclusion:

A significant association was noted between plaque morphologies and texture analysis using both wavelet decomposition and multifractal techniques. Using these techniques, standard normalized values may be generated to classify plaques into truly calcific, fibrocalcific and soft lesions. Additionally, these data may create values in further classifying soft plaques into predominantly lipid, thrombus or necrotic degeneration.

#### 1006-58 The Relation Between the Statin's Effects on Coronary Plaque Composition and Plasma Low-Density Lipoprotein Cholesterol Level Evaluated by Intravascular Ultrasound Radiofrequency Signal Analysis

Masaki Yokoyama, Brian K. Courtney, Takashi Nakayama, Susumu Namikawa, Mizuo Nameki, Issei Komuro, Nobuyuki Komiyama, Chiba University Graduate School, Chiba, Japan, Stanford University Medical Center, Palo Alto, CA

**Background:** Many large trials reported that statins could reduce coronary events in primary and secondary prevention as well as plasma low-density lipoprotein cholesterol (LDL) levels. Intravascular ultrasound radio-frequency signal (IVUS-RF) parameters such as integrated backscatter (IB) have been shown to be useful in discriminating histological components in human coronary plaques. We already reported that administration of statin for 6 months could clinically increase IB in human coronary plaques. In this study, we sought to evaluate the relation between the plasma LDL levels and coronary plaque composition in a manner clinically detectable by IVUS-RF analysis.

**Methods:** Consecutive 20 patients undergoing percutaneous coronary intervention (PCI) with plasma total cholesterol (TC) level between 180 and 230 mg/dl were investigated. We searched for echo-lucent plaques in non-PCI-influenced coronary regions using a 40 MHz IVUS catheter after PCI and acquired IVUS-RF signals. The patients began to take atorvastatin 10 mg/day after PCI procedure. At 6-month follow-up, plasma lipid levels were measured in each patient and IVUS-RF signals were sampled at the same plaque sites. Several regions of interest (ROIs) were placed on each plaque. IB was measured in all ROIs blindly to the LDL data. Total of 148 ROIs were analyzed and %LDL change (baseline LDL - follow-up LDL / baseline LDL x 100 (%)) was calculated in each patient.

**Results:** Plasma LDL level was significantly reduced from  $133 \pm 13$  to  $87 \pm 29$  mg/dl ( $p < 0.0001$ ) during the 6-month follow-up. IB was substantially increased from  $-53.8 \pm 4.5$  to  $-51.2 \pm 4.9$  dB ( $p < 0.0001$ ). Increase of IB at the ROIs ( $n=88$ ) in patients with %LDL change  $>= 40\%$  was significantly greater than at the ROIs ( $n=60$ ) in patients with %LDL change  $< 40\%$  ( $3.79 \pm 4.8$  vs.  $0.70 \pm 3.6$  dB;  $p < 0.0001$ ), however, increase of IB was not different between patients with LDL  $< 100$  mg/dl and LDL  $\geq 100$  mg/dl at the follow-up.

**Conclusions:** These results suggest that statin may alter acoustic properties of coronary plaques and the effect of statin on plaque composition may not be related to the value of LDL cholesterol at the end point but the amount of its reduction.

#### 1006-59 Angioscopic Findings in Patients With Non-ST Elevation Acute Coronary Syndromes According to Troponin T Status

Kentarō Okamoto, Kyoichi Mizuno, Shunta Sakai, Fumiyuki Ishibashi, Masamichi Takano, Nippon Medical School, Chiba Hokusoh Hospital, Chiba, Japan

**Background:** It has been reported that troponin T could help improve the effectiveness of such antithrombotic drugs as platelet glycoprotein IIb/IIIa antagonists in patients with non-ST elevation acute coronary syndromes (NSTEMI-ACS). However, the mechanism remains unclear. We therefore investigated the relationship between angioscopic lesion characteristics and the troponin T release in NSTEMI-ACS.

**Methods and Results:** We studied 57 consecutive NSTEMI-ACS patients who underwent angiography. Before catheterization, we obtained blood samples to determine troponin positivity and the patients were classified as a troponin-positive and troponin-negative group (diagnostic threshold; 0.1 ng/ml). With angiography before angioplasty, we examined the presence of coronary thrombus, yellow plaque, and complex plaque. Twenty-two patients were troponin-positive, and 35 patients were troponin-negative. No significant differences were seen in the incidence of yellow plaque (77% vs. 83%), in the incidence of complex plaque (64% vs. 68%) between the two groups. The incidence of coronary thrombus detected with angiography in the troponin-positive group was significantly higher than that in the troponin-negative group (86% vs. 34%;  $P=0.0001$ ). **Conclusions:** Using angiography, the elevated troponin T levels in NSTEMI-ACS were confirmed to be strongly associated with the presence of coronary thrombus, but not the atherosclerotic change of plaque itself. Our finding supports previous studies reported only the antithrombotic drugs can neutralize the heightened risk of troponin-positive patients with NSTEMI-ACS.

#### 1006-60 Coronary Arterial Wall Temperature Heterogeneity in Patients With Acute Coronary Syndrome: An Intracoronary Thermography Study

Dariusz Dudek, Jacek Legutko, Lukasz Rzeszutko, Angela Richter, Marcin Wiziminski, Jacek S. Dubiel, Jagiellonian University, Krakow, Poland

**Background:** Increase of vessel wall temperature in patients with acute coronary syndrome (ACS) has been previously reported. The aim of this study was to assess the safety and accuracy of intracoronary vessel wall temperature measurements in patients with ACS using new catheter based, flow non-limiting thermography system.

**Methods:** We performed intracoronary thermography in 23 patients (pts) (mean age  $54 \pm 10$  years) with ACS (13 pts with acute myocardial infarction within 12 hours of chest pain onset, 10 pts with unstable angina within 48 hours of the last chest pain) with TIMI 3 flow in the culprit artery before the procedure. We used 3.5-F thermography catheter containing a self-expanding basket with 5 arms and a thermocouple on each arm measuring vessel wall temperature, as well as a central thermocouple measuring blood temperature, allowing detection of differences of  $0.05^\circ\text{C}$ . Thermography was performed before PCI of the culprit lesion. In all studied vessels we assessed blood temperature (T<sub>bl</sub>, °C) and the maximum temperature difference between blood and any thermal couple ( $\Delta\text{Tmax}$ , °C) during pullback (0.5 mm/s).

**Results:** There were no device-related adverse effects or system failures. Mean T<sub>bl</sub> was  $36.7 \pm 0.7^\circ\text{C}$  and mean  $\Delta\text{Tmax}$  was  $0.093 \pm 0.032^\circ\text{C}$ . Temperature difference was higher in the culprit segment in comparison to non culprit segment of the vessel ( $\Delta\text{Tmax} = 0.12 \pm 0.03$  vs.  $0.07 \pm 0.008$ ,  $p < 0.001$ ). In one case, a focal  $0.18^\circ\text{C}$  temperature peak was recorded at the culprit lesion. In 6 pts thermography catheter stopped the flow during thermal mapping when catheter was in a severely stenotic lesion. T<sub>bl</sub> increased on average  $0.2 \pm 0.07$  with no flow at culprit segment, but it was paralleled by the increase in the vessel wall temperature, so  $\Delta\text{Tmax}$  remained unchanged.

**Conclusions:** Intracoronary thermography in patients with ACS was safe and able to detect heterogeneous arterial wall temperature within the culprit vessel. Temperature heterogeneity was higher in the culprit that in non culprit segment of the vessel.

#### 1006-61 Coronary Lesion Temperature Measurement During Transient Blood Flow Occlusion Using a Novel Thermal Sensing System

Jorge A. Belardi, Fernando Cura, Lucio Padilla, Oscar Mendiz, Joseph Korotko, William O'Neill, Instituto Cardiovascular de Buenos Aires, Buenos Aires, Argentina

**Background:** Temperature measurement of coronary arteries may provide lesion assessment beyond conventional angiography and ultrasound imaging. It holds the potential to be a predictor of future clinical events. However, studies have shown that blood flow through an artery interferes with the ability to measure lesion temperature.

**Methods:** We performed the first in man application of a novel thermal sensing catheter (Accumed Systems Inc, Ann Harbor, MI) that temporarily occludes flow through the artery to make temperature measurement in patients before undergoing elective percutaneous coronary intervention. On the distal portion of the catheter is an expandable braid that is mounted on a pair of nested plastic tubes with three thermistors attached to the exterior surface of the sleeve. The system takes a baseline reading of blood temperature flowing through the artery and then surface temperature of the lesion while blood flow is