



Contents lists available at ScienceDirect

## Journal of Ginseng Research

journal homepage: <http://www.ginsengres.org>

## Research article

# Ginseng essence, a medicinal and edible herbal formulation, ameliorates carbon tetrachloride-induced oxidative stress and liver injury in rats

Kuan-Hung Lu<sup>1,☆</sup>, Ching-Yi Weng<sup>1,☆</sup>, Wei-Cheng Chen<sup>1</sup>, Lee-Yan Sheen<sup>1,2,3,\*</sup><sup>1</sup> Institute of Food Science and Technology, National Taiwan University, Taipei, Taiwan<sup>2</sup> Center for Food and Biomolecules, National Taiwan University, Taipei, Taiwan<sup>3</sup> National Center for Food Safety Education and Research, National Taiwan University, Taipei, Taiwan

## ARTICLE INFO

## Article history:

Received 3 March 2016

Received in Revised form

20 May 2016

Accepted 18 June 2016

Available online xxx

## Keywords:

carbon tetrachloride

ginseng essence

ginsenoside

hepatoprotection

oxidative stress

## ABSTRACT

**Background:** Ginseng essence (GE) is a formulation comprising four medicinal and edible herbs including ginseng (*Panax ginseng*), American ginseng (*Panax quinquefolius*), lotus seed (*Nelumbo nucifera*), and lily bulb (*Lilium longiflorum*). This study was aimed at investigating the hepatoprotective effect of GE against carbon tetrachloride (CCl<sub>4</sub>)-induced liver injury in rats.

**Methods:** We treated Wistar rats daily with low, medium, and high [0.625 g/kg body weight (bw), 1.25 g/kg bw, and 3.125 g/kg bw, respectively] doses of GE for 9 wk. After the 1<sup>st</sup> wk of treatment, rats were administered 20% CCl<sub>4</sub> (1.5 mL/kg bw) two times a week to induce liver damage until the treatment ended.

**Results:** Serum biochemical analysis indicated that GE ameliorated the elevation of aspartate aminotransferase and alanine aminotransferase and albumin decline in CCl<sub>4</sub>-treated rats. Moreover, CCl<sub>4</sub>-induced accumulation of hepatic total cholesterol and triglyceride was inhibited. The hepatoprotective effects of GE involved enhancing the hepatic antioxidant defense system including glutathione, glutathione peroxidase, glutathione reductase, glutathione S-transferase, superoxide dismutase, and catalase. In addition, histological analysis using hematoxylin and eosin and Masson's trichrome staining showed that GE inhibited CCl<sub>4</sub>-induced hepatic inflammation and fibrosis. Furthermore, immunohistochemical staining of alpha-smooth muscle actin indicated that CCl<sub>4</sub>-triggered activation of hepatic stellate cells was reduced.

**Conclusion:** These findings demonstrate that GE improves CCl<sub>4</sub>-induced liver inflammation and fibrosis by attenuating oxidative stress. Therefore, GE could be a promising hepatoprotective herbal formulation for future development of phytotherapy.

Copyright © 2016, The Korean Society of Ginseng, Published by Elsevier. This is an open access article under the CC BY-NC-ND license (<http://creativecommons.org/licenses/by-nc-nd/4.0/>).

## 1. Introduction

Chronic liver disease and cirrhosis are the leading causes of death in Taiwan and have been responsible for an increasing number of fatalities in recent years [1]. Prevention of liver disease has become an important task for public health authorities in the absence of the discovery of an actual curative therapeutic agent. Numerous studies have demonstrated that oxidative stress is a

mediator of acute and chronic liver injuries [2–4]. In addition, loss of balance between the antioxidant defense system and free radicals in the body can trigger inflammation and may lead to chronic diseases such as liver and cardiovascular diseases as well as diabetes and cancer [5,6]. Therefore, the use of antioxidants from herbal medicines or functional foods is a reasonable treatment strategy for inhibiting inflammation and oxidative damage to reduce the incidences of such diseases.

\* Corresponding author. Institute of Food Science and Technology, National Taiwan University, Number 1, Section 4, Roosevelt Road, Taipei 10617, Taiwan.

E-mail address: [lysheen@ntu.edu.tw](mailto:lysheen@ntu.edu.tw) (L.-Y. Sheen).

☆ K.-H. Lu and C.-Y. Weng contributed equally to this study.

<http://dx.doi.org/10.1016/j.jgr.2016.06.002>

p1226-8453 e2093-4947/\$ – see front matter Copyright © 2016, The Korean Society of Ginseng, Published by Elsevier. This is an open access article under the CC BY-NC-ND license (<http://creativecommons.org/licenses/by-nc-nd/4.0/>).

Please cite this article in press as: Lu K-H, et al., Ginseng essence, a medicinal and edible herbal formulation, ameliorates carbon tetrachloride-induced oxidative stress and liver injury in rats, Journal of Ginseng Research (2016), <http://dx.doi.org/10.1016/j.jgr.2016.06.002>

Medicine food homology (藥食同源 yào shí tong yuán) means that food and traditional Chinese medicine originated at the same time in ancient China. Based on this concept, medicine food homology materials are considered a treasure house of functional factors for current functional foods [7]. Ginseng essence (GE) is an herbal formulation comprising four Chinese Materia Medica (中藥 zhōng yào) plants including ginseng (人參 rén shēn, *Panax ginseng*), American ginseng (西洋參 xī yáng shēn, *Panax quinquefolius*), lotus seed (蓮子 lián zǐ, *Nelumbo nucifera*), and the lily bulb (百合 bǎi hé, *Lilium longiflorum*). They are allowed to be used not only as traditional Chinese medicine but also as food ingredients in Taiwan. Previous studies have indicated that ginseng and American ginseng as well as their main active compounds the ginsenosides have a number of biological benefits including hepatoprotective [8], anti-inflammatory [9], antidiabetic [10], and tumor growth reduction [11]. Lotus seeds have been found to have hepatoprotective [12], blood sugar lowering [13], anti-inflammatory, and antioxidative activities, and the ability to prevent diabetes [14]. In addition, a few studies have shown that lily reduces inflammation [15], prevents cancer [16], inhibits fungal growth [17], and inhibits oxidative reactions [18]. Therefore, we hypothesized that the herbal formulation GE may have therapeutic potential for the prevention of liver injury via free radical scavenging as well as anti-inflammatory activities.

Carbon tetrachloride (CCl<sub>4</sub>) is a well-known hepatotoxin, which is widely used to induce acute toxic liver injury in animals. Numerous studies have shown that CCl<sub>4</sub> is metabolized by the cytochrome P<sub>450</sub> enzyme system to yield reactive metabolic products including trichloromethyl free radicals, which can initiate the process of lipid peroxidation and ultimately result in the overproduction of reactive oxygen species (ROS) and hepatocyte injuries [19,20]. The rat model of CCl<sub>4</sub>-induced liver injury is well established and is one of the methods for the evaluation of hepatoprotective agents recommended by the Ministry of Health and Welfare, Taiwan. In addition, silymarin (*Silybum marianum*) is an herbal product containing a mixture of flavonolignan isomers. Silymarin is used as a positive control in the animal model because numerous studies have shown that it can prevent CCl<sub>4</sub>-induced lipid peroxidation and hepatotoxicity by decreasing the metabolic activation of CCl<sub>4</sub> and acting as a chain-breaking antioxidant [21–23]. Therefore, the aim of this study was to investigate whether GE can protect the rat liver against CCl<sub>4</sub>-induced oxidative damage and inflammation. In this study, male Wistar rats were treated with GE [0.625 g/kg body weight (bw)/d, 1.25 g/kg bw/d, and 3.125 g/kg bw/d] or silymarin (positive control, 0.5 g/kg bw/d) for 9 wk. After the 1<sup>st</sup> wk of treatment, rats were gavaged with 20% CCl<sub>4</sub> at 1.5 mL/kg bw two times/wk to induce liver injury. After treating the animals, serum biochemical and antioxidant enzyme levels were determined, and histopathological observation of hepatic inflammation and fibrosis was performed to assess the hepatoprotective effect of GE against CCl<sub>4</sub>-induced liver injury in rats.

## 2. Materials and methods

### 2.1. Preparation of GE

GE was obtained from Quaker Co., Ltd. (Taoyuan, Taiwan) and contained a mixture of *P. quinquefolius*, *P. ginseng*, *N. nucifera*, and *L. longiflorum* at a ratio of 1.66:1:1:1 (dry weight). The mixture was extracted with steam at 105°C for 30 min, cooled at 8°C for 12 h, and then filtered two times at 50°C. The filtrate was then freeze-dried to a powder, which was used to prepare different doses of GE in 0.5% carboxymethyl cellulose for the animal experiments.

### 2.2. Treatment of animals

Seventy-two male Wistar rats (weight: 240–260 g; age: 7 wk old) were obtained from BioLASCO Co., Ltd. (Yilan, Taiwan). All animals were handled in accordance with the guidelines of the National Taiwan University Animal Care Committee, which approved the study (Approval Number: NTU-99-EL-98). Standard experimental conditions were as follows: temperature, 22 ± 3°C; humidity, 50–70%; and a 12-h light/dark cycle. After 1 wk of acclimatization, the rats were randomly divided into six groups of 12 rats each including the control (normal control); CCl<sub>4</sub> (negative control); CCl<sub>4</sub> with silymarin (CCl<sub>4</sub> + silymarin); and CCl<sub>4</sub> with low-, medium-, and high-dose GE (CCl<sub>4</sub> + LGE, CCl<sub>4</sub> + MGE, and CCl<sub>4</sub> + HGE, respectively). The CCl<sub>4</sub> + silymarin, CCl<sub>4</sub> + LGE, CCl<sub>4</sub> + MGE, and CCl<sub>4</sub> + HGE groups were orally treated with silymarin (0.5 g/kg bw/d), LGE, MGE, and HGE (0.625 g/kg bw/d, 1.25 g/kg bw/d, and 3.125 g/kg bw/d), respectively, whereas the control and CCl<sub>4</sub> groups were orally treated with equal volumes of the vehicle (0.5% carboxymethyl cellulose). After 1 wk of treatment, rats in the CCl<sub>4</sub>, CCl<sub>4</sub> + LGE, CCl<sub>4</sub> + MGE, and CCl<sub>4</sub> + HGE groups were further administered 20% CCl<sub>4</sub> (1.5 mL/kg bw, two times a week) for 8 wk to induce hepatic fibrosis, whereas rats in the control group were administered equal volumes of the vehicle (olive oil). Blood samples were then collected from the inferior vena cava of the rats, and each liver was isolated and stored at –80°C until further analysis. Schematic diagrams are shown in Fig. 1, which presents the design for the control, negative control (CCl<sub>4</sub>), and treatment groups (CCl<sub>4</sub> + silymarin, CCl<sub>4</sub> + LGE, CCl<sub>4</sub> + MGE, and CCl<sub>4</sub> + HGE).

### 2.3. Phytochemical analysis

First, 1 g of freeze-dried GE powder was sonicated in 2 mL of 70% methanol for 1 h to obtain the extract, which was centrifuged at 6,000 rpm at 4°C for 30 min. The supernatant was then collected, filtered using a 0.22-μm syringe filter, and the filtrate was analyzed using high-performance liquid chromatography (HPLC). Qualitative analysis of the major active components (i.e., ginsenosides) in GE was further performed using HPLC (Jasco LC-Net II/ADC and Jasco PU-2089 Plus Quaternary gradient pump, Tokyo, Japan). The HPLC chromatographic conditions were maintained according to previous reports, but with slight

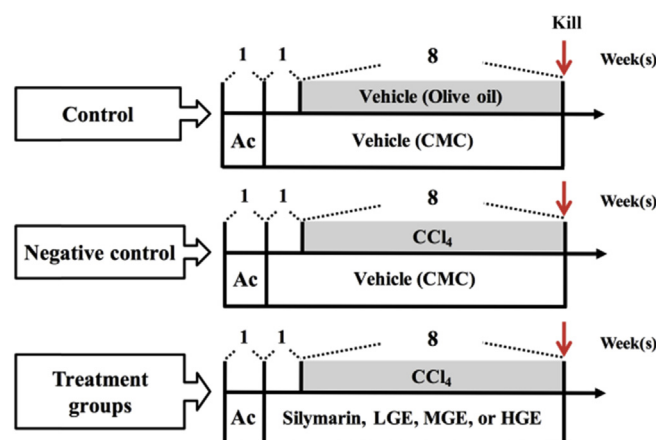


Fig. 1. Schematic diagrams showing the design for studying protective activity of ginseng essence on carbon tetrachloride (CCl<sub>4</sub>)-induced liver injury in rats. Treatments of animals are detailed in the "Materials and Methods" section. Ac, acclimatization; CMC, carboxymethyl cellulose; HGE, high-dose ginseng essence; LGE, low-dose ginseng essence; MGE, medium-dose ginseng essence.

modifications [24,25]. The HPLC procedure was carried out on a Luna C<sub>18</sub> column (5- $\mu$ m pore size, 250  $\times$  4.6 mm inner diameter; Scientific Hightek Co., Taipei, Taiwan) using a gradient solvent system consisting of phosphate buffer (Solvent A, pH 5.82) and acetonitrile (Solvent B). The two-solvent system was run as follows: 20% B (0.01 min), 20.3% B (25 min), 26.8% B (28 min), 26.8% B (38 min), 31% B (48 min), 31% B (58 min), 35.6% B (68 min), 50% B (78 min), 95% B (83 min), 95% (88 min), 20.3% B (90 min), and 20.3% B (95 min). The peaks were recorded using a UV/Visible detector (Jasco UV-2075 Plus) at 202 nm, and the solvent flow rate was maintained at 1.0 mL/min.

#### 2.4. Serum biochemistry

To assess the liver damage in the rats, serum alanine aminotransferase (ALT) and aspartate aminotransferase (AST) activities, and albumin, total cholesterol (TC), and triglyceride (TG) levels were determined using SPOTCHEM EZ reagent strips (Arkray, Inc., Kyoto, Japan).

#### 2.5. Histological analysis

For the histological examination, the anterior portions of the left lateral lobe of the rat livers were sectioned, fixed in 10% neutral-buffered formalin, embedded in paraffin, and sliced into 5- $\mu$ m sections. The sections were then hematoxylin and eosin or Masson's trichrome stained. A blinded histological assessment of the liver sections was then performed by a veterinary pathologist at the Graduate Institute of Veterinary Pathobiology of the National Chung Hsing University, Taiwan. Histological changes were evaluated in nonconsecutive histological fields, randomly chosen at a magnification of 100 $\times$ .

#### 2.6. Hepatic antioxidant enzyme activities and total glutathione content

The frozen liver tissue was homogenized, centrifuged, and collected as previously described [26]. The resulting supernatant was then used to determine total glutathione content and antioxidant enzymatic activities including glutathione peroxidase (GPx), glutathione reductase (GRd), glutathione S-transferase (GST), superoxide dismutase (SOD), and catalase (CAT) using Cayman assay kits (Cayman, MI, USA).

#### 2.7. Immunohistochemistry

Immunohistochemical analysis of the rat livers was performed as previously described with slight modifications [27]. In brief, the rats were killed, and their livers were trimmed into a strip, soaked in 10% formalin, embedded in paraffin, and then sectioned. The liver sections were dewaxed, hydrated, subjected to heat-induced antigen retrieval, blocked in blocking buffer, and then incubated overnight at 4°C with an anti- $\alpha$ -smooth muscle actin ( $\alpha$ -SMA) antibody (1:100; Dako, Denmark, Europe). The sections were then washed and further incubated with Super Enhancer and a poly-horseradish-conjugated reagent. The color was developed by incubating the sections with the 3,3'-diaminobenzidine and substrate reaction mixtures (1:38) as well as with hematoxylin. After washing the sections with water, the specific staining was visualized using light microscopy.

#### 2.8. Statistical analysis

All the experimental data were represented as the mean  $\pm$  standard deviation. The statistically significant differences

in the data were analyzed using a one-way analysis of variance followed by Duncan multiple comparison test using statistical analysis software (SAS) version 9.2 (Cary, NC, USA). Differences were considered significant when *p* values are less than 0.05.

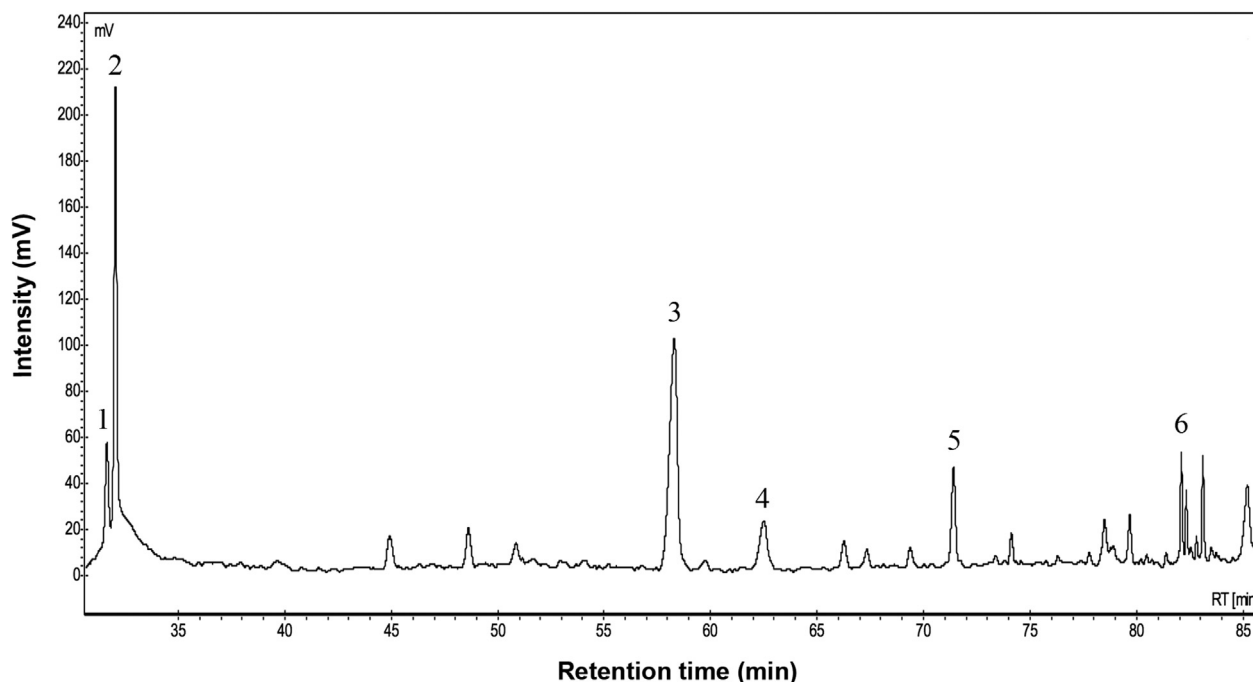
### 3. Results and discussion

#### 3.1. Ginsenoside content of GE

Previous studies have indicated that ginsenosides Rb1 [28], Rg1 [8], and Rg3 [29] are the active components of ginseng with hepatoprotective effect. Therefore, in this study, we performed HPLC analysis to determine the composition of ginsenosides in the GE by comparing its retention time peaks with those of the reference ginsenoside standards (Fig. 2). The quantitative results of the chromatographic analysis revealed that GE contained ginsenosides Rg1, Re, Rb1, Rc, Rd, and Rg3 at levels of 31.74 ppm, 15.57 ppm, 52.79 ppm, 11.24 ppm, 11.69 ppm, and 3.24 ppm, respectively. Therefore, we reasonably presumed that these ginsenosides are the main active ingredients in the GEs that exhibit liver protection.

#### 3.2. Changes in rat body and organ weights

A decrease in body weight is usually regarded as direct evidence of toxic injury in rodents. Administration of CCl<sub>4</sub> induces physiological changes in the body of organisms that may slow body weight gain and even cause a decrease [30]. Table 1 shows that the final body weight of the CCl<sub>4</sub> group was significantly lower than that of the control group. By contrast, the final body weight of the CCl<sub>4</sub> + silymarin, CCl<sub>4</sub> + MGE, and CCl<sub>4</sub> + HGE groups was significantly higher than that of the CCl<sub>4</sub> group (*p* < 0.05). The result indicates that changes in body weight were induced in rats administered CCl<sub>4</sub>. However, supplementation with MGE and HGE inhibited the decrease in body weight, and the result was similar to that of the silymarin group. Therefore, GE might inhibit the weight loss caused by CCl<sub>4</sub> in rats. The results of the organ weight determinations shown in Table 1 revealed that the absolute liver weight of all CCl<sub>4</sub>-treated groups including the CCl<sub>4</sub>, CCl<sub>4</sub> + silymarin, CCl<sub>4</sub> + LGE, CCl<sub>4</sub> + MGE, and CCl<sub>4</sub> + HGE groups was significantly higher than that of the control group (*p* < 0.05). By contrast, the relative liver weight of the CCl<sub>4</sub> + silymarin and CCl<sub>4</sub> + HGE groups was significantly lower than that of the CCl<sub>4</sub> group (*p* < 0.05). There was no significant difference in absolute spleen weight between all six groups, whereas the relative spleen weight of the CCl<sub>4</sub> group was significantly higher than that of the other groups (*p* < 0.05). The absolute kidney weight of all the CCl<sub>4</sub>-treated groups was significantly higher than that of the control group (*p* < 0.05). However, the relative kidney weight of the CCl<sub>4</sub> + silymarin, CCl<sub>4</sub> + LGE, CCl<sub>4</sub> + MGE, and CCl<sub>4</sub> + HGE groups was significantly lower than that of the CCl<sub>4</sub> group (*p* < 0.05). Evidence of change during the assessment of organ weight is often considered an important indicator of organ damage, and therefore can be used to evaluate responses to toxicants [31]. Damage to the liver could cause liver cell microvilli and sinusoidal endothelial cell fenestrae to disappear, alter the structure of the smooth endoplasmic reticulum, inactivate hepatic stellate cells (HSCs) and Kupffer cells, increase collagen content, result in accumulation of fibers in the liver, and then cause changes in liver weight [32]. Liver fibrosis can result in the blockage of blood flow to the liver and increase in portal pressure, which could lead to the retention of blood by the spleen, and thereby cause splenomegaly [33].



**Fig. 2.** The chromatogram of HPLC showing ginsenosides in ginseng essence including (1) ginsenoside Rg1; (2) ginsenoside Re; (3) ginsenoside Rb1; (4) ginsenoside Rc; (5) ginsenoside Rd; (6) ginsenoside Rg3. HPLC chromatographic conditions are detailed in the “Materials and Methods” section.

**Table 1**

Effects of ginseng essence on body and organ weights of rats with carbon tetrachloride-induced liver injury

Group <sup>1)</sup>	Initial weight	Final weight	Liver weight	Relative liver weight	Spleen weight	Relative spleen weight	Kidney weight	Relative kidney weight
Control	291 ± 9 <sup>a</sup>	448 ± 29 <sup>a</sup>	14.43 ± 2.45 <sup>c</sup>	3.27 ± 0.44 <sup>c</sup>	0.93 ± 0.15 <sup>a</sup>	0.22 ± 0.03 <sup>b</sup>	2.62 ± 0.23 <sup>b</sup>	0.59 ± 0.03 <sup>c</sup>
CCl <sub>4</sub>	295 ± 10 <sup>a</sup>	398 ± 7 <sup>c</sup>	17.84 ± 1.82 <sup>a</sup>	4.06 ± 0.33 <sup>a</sup>	1.02 ± 0.14 <sup>a</sup>	0.30 ± 0.04 <sup>a</sup>	2.90 ± 0.19 <sup>a</sup>	0.94 ± 0.11 <sup>a</sup>
CCl <sub>4</sub> + silymarin	287 ± 13 <sup>a</sup>	423 ± 17 <sup>b</sup>	16.42 ± 1.42 <sup>ab</sup>	3.53 ± 0.66 <sup>bc</sup>	1.07 ± 0.25 <sup>a</sup>	0.24 ± 0.03 <sup>b</sup>	2.69 ± 0.42 <sup>ab</sup>	0.68 ± 0.07 <sup>b</sup>
CCl <sub>4</sub> + LGE	286 ± 6 <sup>a</sup>	415 ± 30 <sup>bc</sup>	16.55 ± 1.05 <sup>ab</sup>	3.84 ± 0.26 <sup>ab</sup>	0.98 ± 0.08 <sup>a</sup>	0.24 ± 0.03 <sup>b</sup>	2.74 ± 0.09 <sup>ab</sup>	0.66 ± 0.05 <sup>b</sup>
CCl <sub>4</sub> + MGE	292 ± 7 <sup>a</sup>	424 ± 23 <sup>b</sup>	16.76 ± 1.36 <sup>ab</sup>	3.87 ± 0.37 <sup>ab</sup>	1.07 ± 0.05 <sup>a</sup>	0.24 ± 0.01 <sup>b</sup>	2.79 ± 0.13 <sup>ab</sup>	0.65 ± 0.02 <sup>b</sup>
CCl <sub>4</sub> + HGE	291 ± 6 <sup>a</sup>	416 ± 19 <sup>bc</sup>	15.99 ± 1.08 <sup>b</sup>	3.59 ± 0.24 <sup>bc</sup>	0.96 ± 0.11 <sup>a</sup>	0.22 ± 0.02 <sup>b</sup>	2.69 ± 0.28 <sup>ab</sup>	0.65 ± 0.04 <sup>b</sup>

Data are represented as the mean ± standard deviation ( $n = 12$ ). Values with different superscripts within the same column are significantly different among groups according to a one-way analysis of variance coupled with Duncan multiple test ( $p < 0.05$ ).

<sup>1)</sup> Control, vehicle (0.5% CMC + olive oil); CCl<sub>4</sub>, 20% CCl<sub>4</sub>; CCl<sub>4</sub> + silymarin, 20% CCl<sub>4</sub> + silymarin 0.5 g/kg bw/d; CCl<sub>4</sub> + LGE, 20% CCl<sub>4</sub> + GE 0.625 g/kg bw/d; CCl<sub>4</sub> + MGE, 20% CCl<sub>4</sub> + GE 1.25 g/kg bw/d; CCl<sub>4</sub> + HGE, 20% CCl<sub>4</sub> + GE 3.125 g/kg bw/d. bw, body weight; CMC, carboxymethyl cellulose; CCl<sub>4</sub>, carbon tetrachloride; HGE, high-dose ginseng essence; LGE, low-dose ginseng essence; MGE, medium-dose ginseng essence.

Our study results show that after chronic administration of CCl<sub>4</sub>, the absolute and relative weights of the liver, spleen, and kidney were significantly higher than those of the normal control animals. However, after 8-wk supplementation with GE, the relative liver weight of the high-dose group (CCl<sub>4</sub> + HGE) was significantly lower than that of the negative control group (CCl<sub>4</sub>) and was close to that of the normal control. Furthermore, the relative spleen and kidney weights in all three GE-treated groups (CCl<sub>4</sub> + LGE, CCl<sub>4</sub> + MGE, and CCl<sub>4</sub> + HGE) were significantly lower than those of the negative control group. These results imply that supplementation with GE may significantly improve the swelling and inflammation induced by CCl<sub>4</sub> in the liver, spleen, and kidney of rats.

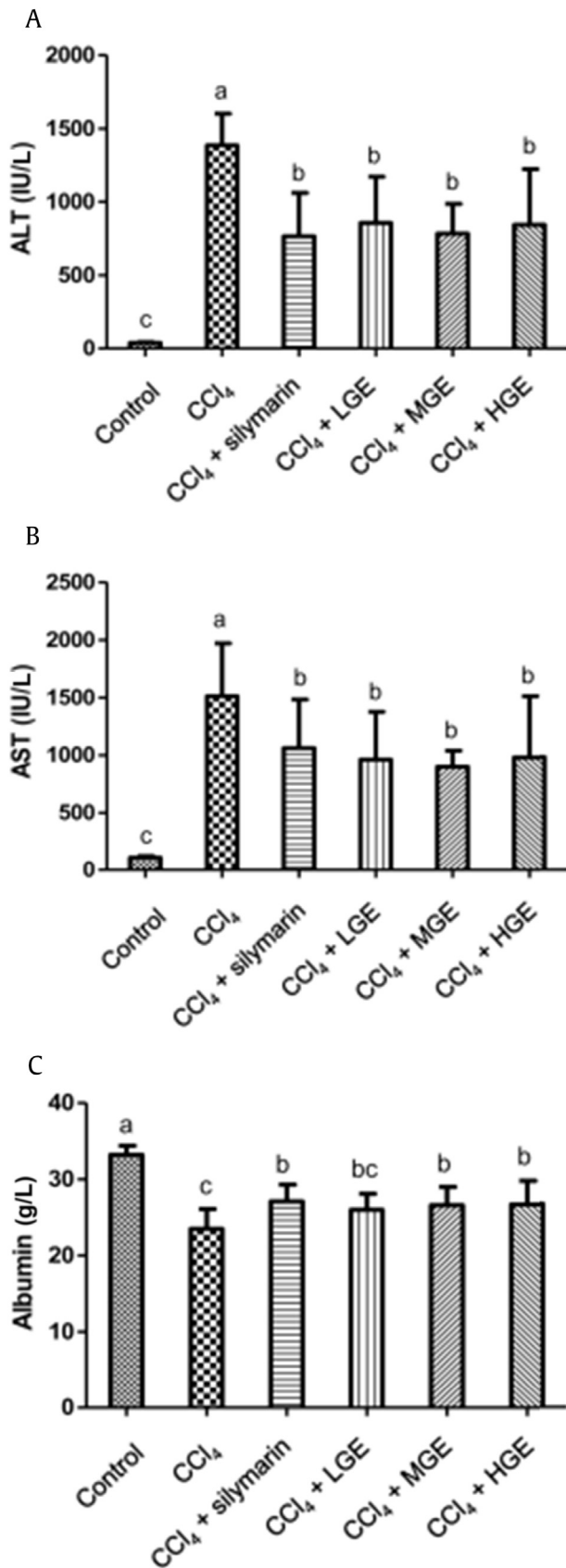
### 3.3. Serum biochemical analysis

Previous studies have demonstrated that once the liver is exposed to CCl<sub>4</sub>, ALT and AST are released and flow into the bloodstream. The notable increase in serum ALT and AST levels is considered an indicator of liver injury [34]. Figs. 3A and 3B show that compared with the control, administration of CCl<sub>4</sub> strongly

elevated both serum ALT and AST levels of rats (control and CCl<sub>4</sub>, 41 ± 5 IU/L and 1,387 ± 216 IU/L, and 110 ± 15 IU/L and 1,511 ± 459 IU/L, respectively). However, the levels of serum ALT and AST of the silymarin- and GE-treated groups were significantly lower than those of the control group (ALT: CCl<sub>4</sub> + silymarin, CCl<sub>4</sub> + LGE, CCl<sub>4</sub> + MGE, and CCl<sub>4</sub> + HGE groups, 766 ± 295 IU/L, 857 ± 314 IU/L, 784 ± 201 IU/L, and 844 ± 379 IU/L, respectively; AST: CCl<sub>4</sub> + silymarin, CCl<sub>4</sub> + LGE, CCl<sub>4</sub> + MGE, and CCl<sub>4</sub> + HGE groups, 1061 ± 421 IU/L, 961 ± 415 IU/L, 899 ± 139 IU/L, and 980 ± 531 IU/L, respectively,  $p < 0.05$ ). Therefore, the results suggest that GE has hepatoprotective effects against CCl<sub>4</sub>-induced liver injury in rats.

In addition, Fig. 3C shows that the serum albumin level of CCl<sub>4</sub>-treated rats obviously decreased compared with that of the controls (23.5 ± 2.6 g/L and 33.2 ± 1.2 g/L, respectively). Furthermore, supplementation with GE induced serum albumin levels in the CCl<sub>4</sub> + MGE and CCl<sub>4</sub> + HGE groups that were close to those of the CCl<sub>4</sub> + silymarin group (26.6 ± 2.4 g/L and 26.7 ± 3.1 g/L vs. 27.1 ± 2.2 g/L, respectively) and significantly higher than those of the CCl<sub>4</sub> group ( $p < 0.05$ ). Previous studies have found that CCl<sub>4</sub> decreased serum total protein and albumin





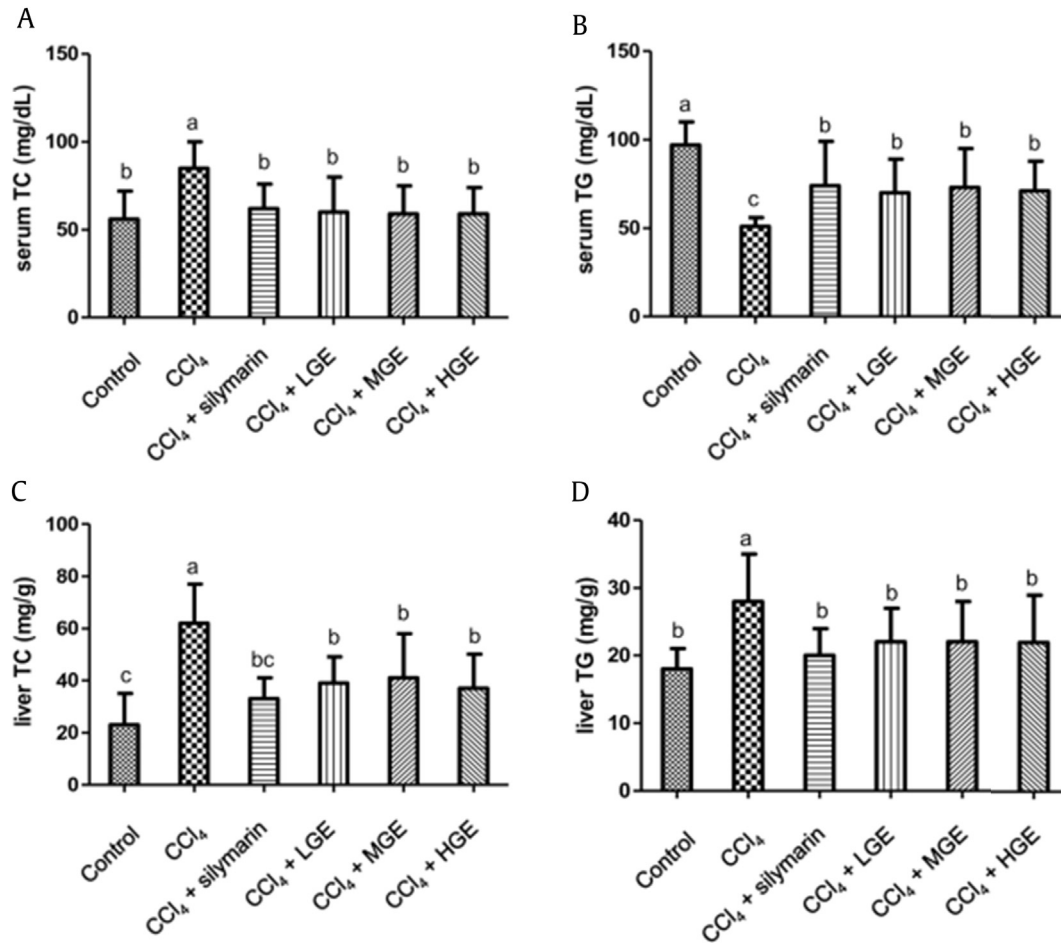
**Fig. 3.** Effects of ginseng essence on serum (A) alanine aminotransferase (ALT), (B) aspartate transferase (AST), and (C) albumin levels of rats with carbon tetrachloride (CCl<sub>4</sub>)-induced liver injury. Data are represented as the mean  $\pm$  standard deviation ( $n = 12$ ). Values with different superscripts are significantly different among groups according to a one-way analysis of variance coupled with Duncan multiple test ( $p < 0.05$ ). HGE, high-dose ginseng essence; LGE, low-dose ginseng essence; MGE, medium-dose ginseng essence.

in carps [35], inhibited protein synthesis, and reduced ribosomal RNA methylation [36]. Administration of CCl<sub>4</sub> could inhibit the synthesis of albumin and other proteins in the liver, and result in significantly lower serum albumin level [37]. Moreover, administration of silymarin (0.5 g/kg bw and 1.0 g/kg bw) in the diet significantly reduced the induction of CCl<sub>4</sub>-induced liver injury, and this effect may be mediated by an increase in ribosome formation and stimulation of DNA and protein synthesis [38,39]. Accordingly, the results shown in Fig. 3 suggest that GE exerted hepatoprotective effects by inhibiting the CCl<sub>4</sub>-induced increase in serum ALT and AST levels and a decrease in serum albumin content.

The effects of GE administration on serum and liver TG and TC levels in CCl<sub>4</sub>-treated rats are shown in Fig. 4. The result shows that the serum TG level of the CCl<sub>4</sub> group ( $51 \pm 5$  mg/dL) was significantly lower than those of the CCl<sub>4</sub> + silymarin, GE-treated CCl<sub>4</sub> + LGE, CCl<sub>4</sub> + MGE, and CCl<sub>4</sub> + HGE groups ( $74 \pm 25$  mg/dL,  $70 \pm 19$  mg/dL,  $73 \pm 22$  mg/dL, and  $71 \pm 17$  mg/dL, respectively,  $p < 0.05$ ). Furthermore, the serum TC and liver TC and TG levels of the CCl<sub>4</sub> group were significantly higher than those of the silymarin- and GE-treated groups (serum TC: CCl<sub>4</sub>, CCl<sub>4</sub> + silymarin, CCl<sub>4</sub> + LGE, CCl<sub>4</sub> + MGE, and CCl<sub>4</sub> + HGE groups,  $85 \pm 15$  mg/dL,  $62 \pm 14$  mg/dL,  $60 \pm 20$  mg/dL,  $59 \pm 16$  mg/dL, and  $59 \pm 15$  mg/dL, respectively; liver TC: CCl<sub>4</sub>, CCl<sub>4</sub> + silymarin, CCl<sub>4</sub> + LGE, CCl<sub>4</sub> + MGE, and CCl<sub>4</sub> + HGE groups,  $62 \pm 15$  mg/dL,  $33 \pm 8$  mg/dL,  $39 \pm 10$  mg/dL,  $41 \pm 17$  mg/dL,  $37 \pm 13$  mg/dL, respectively; liver TG: CCl<sub>4</sub>, CCl<sub>4</sub> + silymarin, CCl<sub>4</sub> + LGE, CCl<sub>4</sub> + MGE, and CCl<sub>4</sub> + HGE groups,  $28 \pm 7$  mg/dL,  $20 \pm 4$  mg/dL,  $22 \pm 5$  mg/dL,  $22 \pm 6$  mg/dL, and  $22 \pm 7$  mg/dL, respectively,  $p < 0.05$ ). These results indicate that CCl<sub>4</sub> inhibited the secretion of TG, and thereby enhanced fat accumulation. CCl<sub>4</sub> induces an increase in hepatic TG levels, which causes its accumulation in the liver, leading to hepatomegaly. Previous studies have proposed various hypotheses to explain the mechanism of fatty liver induction by CCl<sub>4</sub>. Recknagel et al [40] demonstrated that CCl<sub>4</sub> affected liver ribosomal division and protein synthesis, as well as inhibited the secretion of lipoproteins. In addition, CCl<sub>4</sub>-triggered lipid accumulation and inactivation of metabolism-related enzymes have been found to reduce liver cytochrome P<sub>450</sub> content *in vivo* and *in vitro* [41,42]. Administration of CCl<sub>4</sub> in rats for 6 wk increased liver TG but decreased it in the serum [43], and increased cholesterol in the liver and serum [44]. Supplementation with GE inhibits CCl<sub>4</sub>-induced lipid accumulation in the liver, which implies that GE might play an important role in lipoprotein synthesis and lipid transport by attenuating the inactivation of metabolizing enzymes.

### 3.4. *In vivo* antioxidant defense system

All aerobic organisms possess similar inherent and effective *in vivo* antioxidant defense systems, which include the antioxidant enzymes (SOD, GPx, and CAT) and nonenzymatic antioxidants such as glutathione. Antioxidant enzymes play an important role in the prevention of free radical-induced oxidative damage as well as reduction of antioxidant activities and capacity in vulnerable organisms [45]. Administration of CCl<sub>4</sub> is known to lead to the generation of trichloromethyl free radicals and overproduction of ROS, leading to hepatic injuries in rats. The relationship between hepatoprotective effect and antioxidant scavenging activity is highly correlated. Table 2 shows the effects of GE on liver glutathione levels and antioxidant enzyme activities in CCl<sub>4</sub>-treated rats. Supplementation with GE resulted in significantly higher glutathione, GPx, GRd, GST, SOD, and CAT levels in the extract-treated groups than in the CCl<sub>4</sub> group



**Fig. 4.** Effects of ginseng essence on (A) serum total cholesterol (TC), (B) serum triglyceride (TG), (C) liver TC, and (D) liver TG following carbon tetrachloride (CCl<sub>4</sub>)-induced liver injury in rats. Data are represented as the mean  $\pm$  standard deviation ( $n = 12$ ). Values with different superscripts are significantly different among groups according to a one-way analysis of variance coupled with Duncan multiple test ( $p < 0.05$ ). HGE, high-dose ginseng essence; LGE, low-dose ginseng essence; MGE, medium-dose ginseng essence.

**Table 2**

Effects of ginseng essence on liver glutathione and antioxidant enzyme activities of rats with carbon tetrachloride-induced liver injury

Group <sup>1)</sup>	Glutathione (nmol/mg protein)	GPx (nmol/min/mg protein)	GRd (nmol/min/mg protein)	GST (nmol/min/mg protein)	SOD (U/mg protein)	CAT (U/mg protein)
Control	71 $\pm$ 8 <sup>b</sup>	54 $\pm$ 8 <sup>a</sup>	40 $\pm$ 8 <sup>bc</sup>	493 $\pm$ 29 <sup>a</sup>	1,446 $\pm$ 323 <sup>a</sup>	129 $\pm$ 16 <sup>a</sup>
CCl <sub>4</sub>	43 $\pm$ 9 <sup>c</sup>	35 $\pm$ 11 <sup>b</sup>	28 $\pm$ 6 <sup>c</sup>	354 $\pm$ 11 <sup>b</sup>	535 $\pm$ 87 <sup>b</sup>	53 $\pm$ 13 <sup>b</sup>
CCl <sub>4</sub> + silymarin	97 $\pm$ 8 <sup>a</sup>	61 $\pm$ 13 <sup>a</sup>	54 $\pm$ 12 <sup>ab</sup>	524 $\pm$ 18 <sup>a</sup>	1,292 $\pm$ 307 <sup>a</sup>	129 $\pm$ 24 <sup>a</sup>
CCl <sub>4</sub> + LGE	98 $\pm$ 5 <sup>a</sup>	51 $\pm$ 18 <sup>a</sup>	50 $\pm$ 20 <sup>ab</sup>	460 $\pm$ 58 <sup>a</sup>	1,368 $\pm$ 252 <sup>a</sup>	136 $\pm$ 39 <sup>a</sup>
CCl <sub>4</sub> + MGE	102 $\pm$ 14 <sup>a</sup>	52 $\pm$ 8 <sup>a</sup>	64 $\pm$ 27 <sup>a</sup>	528 $\pm$ 50 <sup>a</sup>	1,401 $\pm$ 167 <sup>a</sup>	152 $\pm$ 30 <sup>a</sup>
CCl <sub>4</sub> + HGE	99 $\pm$ 6 <sup>a</sup>	51 $\pm$ 6 <sup>a</sup>	52 $\pm$ 14 <sup>ab</sup>	570 $\pm$ 33 <sup>a</sup>	1,247 $\pm$ 244 <sup>a</sup>	131 $\pm$ 31 <sup>a</sup>

Data are represented as the mean  $\pm$  standard deviation ( $n = 12$ ). Values with different superscripts within the same column are significantly different among groups according to a one-way analysis of variance coupled with Duncan multiple test ( $p < 0.05$ ).

<sup>1)</sup> Control, vehicle (0.5% CMC + olive oil); CCl<sub>4</sub>, 20% CCl<sub>4</sub>; CCl<sub>4</sub> + silymarin, 20% CCl<sub>4</sub> + silymarin 0.5 g/kg bw/d; CCl<sub>4</sub> + LGE, 20% CCl<sub>4</sub> + GE 0.625 g/kg bw/d; CCl<sub>4</sub> + MGE, 20% CCl<sub>4</sub> + GE 1.25 g/kg bw/d; CCl<sub>4</sub> + HGE, 20% CCl<sub>4</sub> + GE 3.125 g/kg bw/d. bw, body weight; CAT, catalase; CCl<sub>4</sub>, carbon tetrachloride; CMC, carboxymethyl cellulose; GPx, glutathione peroxidase; GRd, glutathione reductase; GST, glutathione S-transferase; HGE, high-dose ginseng essence; LGE, low-dose ginseng essence; MGE, medium-dose ginseng essence; SOD, superoxide dismutase.

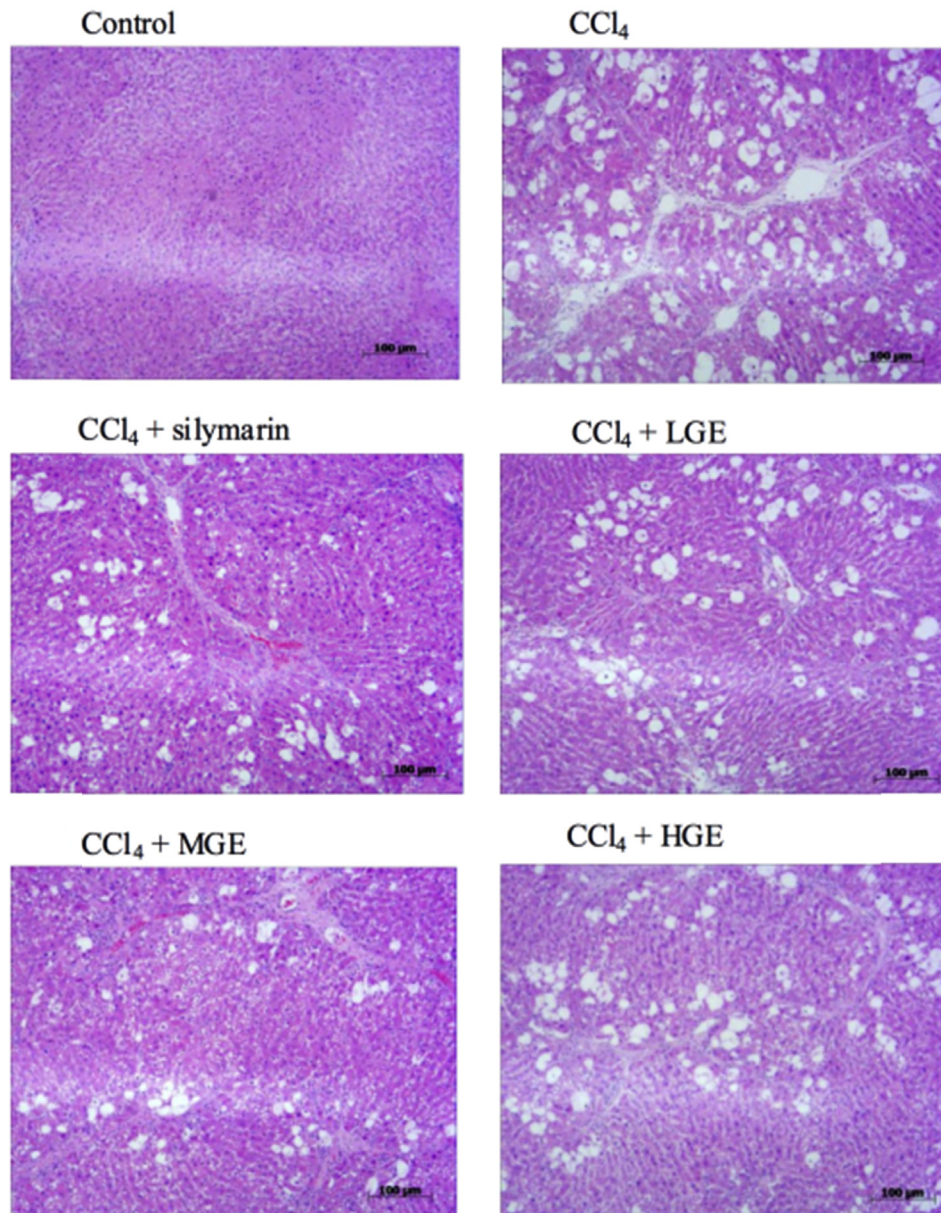
( $p < 0.05$ ). The enzyme levels of the GE-treated groups were close to those of the silymarin-treated group.

In addition, glutathione is the major noncellular enzymatic antioxidant, which directly or indirectly scavenges free radicals effectively via enzymatic reactions. Previous studies have found that acute administration of CCl<sub>4</sub> depletes glutathione contents in mammals. The mechanism of CCl<sub>4</sub>-induced liver injury showed that conjugation with glutathione plays a critical role in reducing the metabolism of toxins [46]. In this study, treatment with GE significantly inhibited the reduction of glutathione levels. These results

indicate that the hepatoprotective effects of GE may be exerted by reducing ROS generation. Furthermore, the attenuation of oxidative stress by GE was similar to that shown by silymarin, which is consistent with previous studies [22,23].

### 3.5. Histopathological analysis

Hepatic inflammation and fibrosis are common outcomes of liver damage. Hematoxylin and eosin staining is performed to observe CCl<sub>4</sub>-induced physiological changes in the rat liver,



**Fig. 5.** Pathological examination of effects of ginseng essence on liver inflammation in rats with carbon tetrachloride (CCl<sub>4</sub>)-induced liver injury after 8-week treatment. Livers were stained with hematoxylin and eosin and visualized at 100× magnification. HGE, high-dose ginseng essence; LGE, low-dose ginseng essence; MGE, medium-dose ginseng essence.

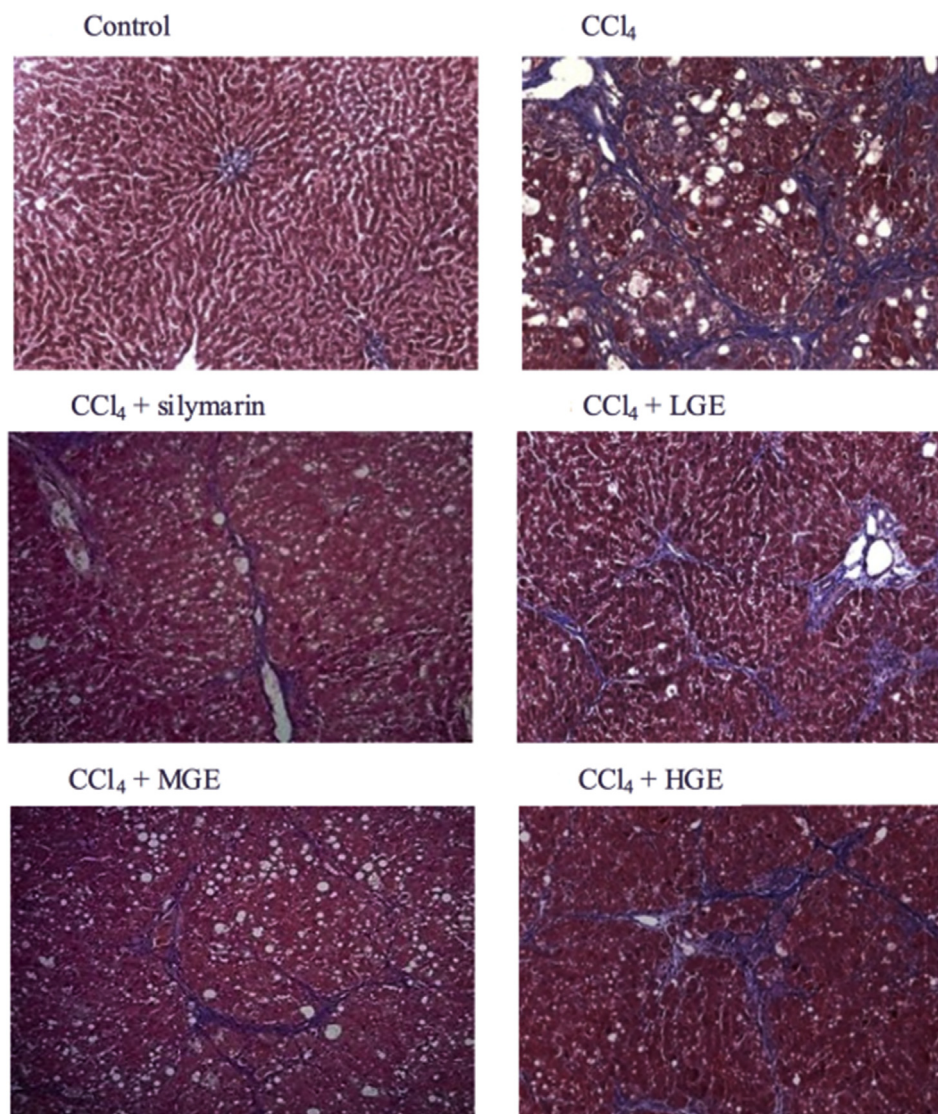
whereas Masson's trichrome staining is a commonly used collagen staining method for liver fibrosis detection [47]. Figs. 5 and 6 show the histological analyses of liver inflammation and fibrosis, respectively. The liver portal peripheral inflammation (vacuoles) and fibrosis were evaluated and scored by a blinded veterinary pathologist. As shown in Table 3, scores of the liver portal peripheral inflammation in the CCl<sub>4</sub> + LGE and CCl<sub>4</sub> + HGE groups ( $2.60 \pm 1.07$  and  $2.40 \pm 0.97$ , respectively) were slightly lower than those of the CCl<sub>4</sub>-treated group. In addition, the CCl<sub>4</sub> + MGE group showed significantly lower scores than the CCl<sub>4</sub> group ( $2.10 \pm 1.29$  and  $3.20 \pm 0.79$ , respectively,  $p < 0.05$ ). The liver fibrosis scores of the GE-treated CCl<sub>4</sub> + LGE, CCl<sub>4</sub> + MGE, and CCl<sub>4</sub> + HGE groups ( $1.70 \pm 0.95$ ,  $1.10 \pm 0.74$ , and  $1.60 \pm 0.84$ , respectively) were close to those of silymarin + CCl<sub>4</sub> and significantly lower than those of the control ( $1.00 \pm 0.82$  and  $2.40 \pm 0.70$ , respectively,  $p < 0.05$ ). Therefore, GE obviously inhibited CCl<sub>4</sub>-induced hepatic inflammation and fibrosis in rats.

### 3.6. Immunohistochemical staining of $\alpha$ -SMA

$\alpha$ -SMA can be used as a specific marker to assess the activation of HSCs, which were stained red when the reaction was positive. As shown in Fig. 7, no visible positive reaction was observed in normal controls, indicating that no HSCs were activated. Compared with the control group, the other CCl<sub>4</sub>-treated group showed a significant increase in the number of activated HSCs. The CCl<sub>4</sub> group showed the highest positive response, indicating that the number of activated HSCs was significantly higher than it was in the GE-treated groups. The results showed that treatment with silymarin as well as LGE, MGE, and HGE reduced the number of HSCs activated by CCl<sub>4</sub>.

Fibrosis and cirrhosis of the liver can be observed following the accumulation of extracellular matrix, which leads to the formation of excessive collagen by activation of cells such as HSCs and fibroblasts [48]. In pathological progress, the activation of HSCs could





**Fig. 6.** Pathological examination of effects of ginseng essence on liver fibrosis in rats with carbon tetrachloride (CCl<sub>4</sub>)-induced liver injury after 8-week treatment. Livers were stained with Masson's trichrome and visualized at 100× magnification. HGE, high-dose ginseng essence; LGE, low-dose ginseng essence; MGE, medium-dose ginseng essence.

**Table 3**

Scoring of the effect of ginseng essence on liver inflammation and fibrosis of carbon tetrachloride-induced liver injury in rats<sup>1)</sup>

Group <sup>2)</sup>	Histopathological score of liver	
	Inflammation score	Fibrosis score
Control	0.00 ± 0.00 <sup>c</sup>	0.00 ± 0.00 <sup>c</sup>
CCl <sub>4</sub>	3.20 ± 0.79 <sup>a</sup>	2.40 ± 0.70 <sup>a</sup>
CCl <sub>4</sub> + silymarin	2.50 ± 0.53 <sup>a</sup>	1.00 ± 0.82 <sup>b</sup>
CCl <sub>4</sub> + LGE	2.60 ± 1.07 <sup>ab</sup>	1.70 ± 0.95 <sup>b</sup>
CCl <sub>4</sub> + MGE	2.10 ± 1.29 <sup>b</sup>	1.10 ± 0.74 <sup>b</sup>
CCl <sub>4</sub> + HGE	2.40 ± 0.97 <sup>ab</sup>	1.60 ± 0.84 <sup>b</sup>

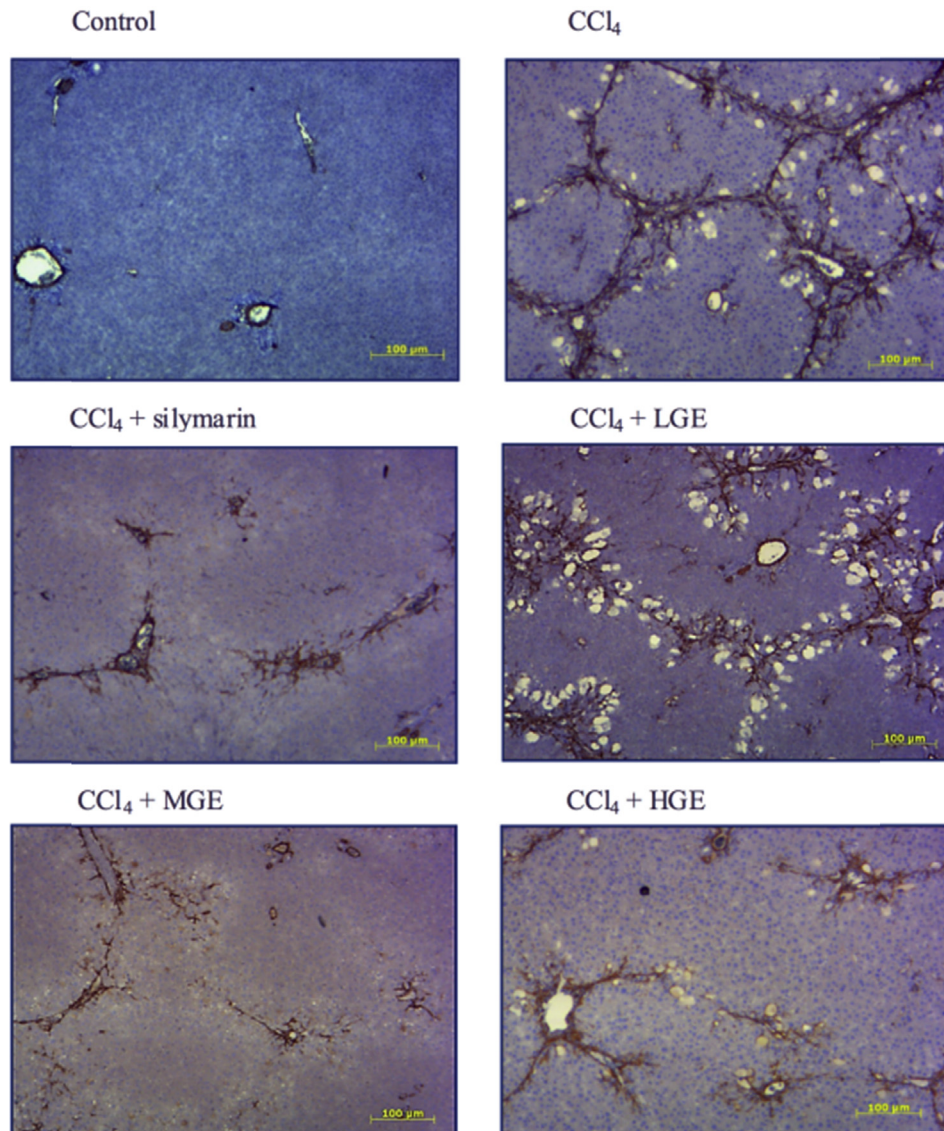
<sup>1)</sup> Histological indices of hepatic vacuolization and necrosis were quantified by a blinded veterinary pathologist based on numerical scoring of liver biopsy specimens. Liver damage was graded on a scale of 0–4 as follows: 0 = none, 1 = slight, 2 = mild, 3 = moderate, and 4 = remarkable. Data are represented as the mean ± standard deviation ( $n = 12$ ). Values with different superscripts within the same column are significantly different among groups according to a one-way analysis of variance coupled with Duncan multiple test ( $p < 0.05$ ).

<sup>2)</sup> Control, vehicle (0.5% CMC + olive oil); CCl<sub>4</sub>, 20% CCl<sub>4</sub>; CCl<sub>4</sub> + silymarin, 20% CCl<sub>4</sub> + silymarin 0.5 g/kg bw/d; CCl<sub>4</sub> + LGE, 20% CCl<sub>4</sub> + GE 0.625 g/kg bw/d; CCl<sub>4</sub> + MGE, 20% CCl<sub>4</sub> + GE 1.25 g/kg bw/d; CCl<sub>4</sub> + HGE, 20% CCl<sub>4</sub> + GE 3.125 g/kg bw/d. bw, body weight; CMC, carboxymethyl cellulose; CCl<sub>4</sub>, carbon tetrachloride; HGE, high-dose ginseng essence; LGE, low-dose ginseng essence; MGE, medium-dose ginseng essence.

increase the synthesis of extracellular matrix proteins, which changes the structure of liver sinusoid endothelial cells causing necrosis [49]. Although the mechanism mediating hepatic fibrosis is still not fully understood, maintaining the shape of HSCs may prevent or mitigate the development of liver fibrosis. It has been shown that treatment of rats with CCl<sub>4</sub> can cause collagen accumulation in the liver and increase the expression of  $\alpha$ -SMA, which implies that HSCs have a tendency to induce liver fibrosis. Therefore, a decrease in the positive reaction of  $\alpha$ -SMA could indicate the inactivation of HSCs and mitigation of fibrosis. In summary, the results showed that GE might have effectively inhibited liver fibrosis by reducing the activation of HSCs in CCl<sub>4</sub>-treated rats.

In conclusion, we found that GE contains ginsenosides including Rg1, Re, Rb1, Rc, Rd, and Rg3, which could exert hepatoprotective effects. Furthermore, the results of the animal experiments demonstrate that GE significantly reduced the liver injury induced by CCl<sub>4</sub> in rats by ameliorating the oxidative stress, reducing inflammation, and inhibiting the activation of HSCs. Therefore, GE could be a promising hepatoprotective herbal formulation for future development of phytotherapy.





**Fig. 7.** Effects of ginseng essence on activation of hepatic stellate cells of rats with carbon tetrachloride (CCl<sub>4</sub>)-induced liver injury after 8-week treatment. Immunohistochemical staining of alpha-smooth muscle actin was performed on liver sections and visualized at 100× magnification. HGE, high-dose ginseng essence; LGE, low-dose ginseng essence; MGE, medium-dose ginseng essence.

### Conflicts of interest

All authors have no conflicts of interest to declare.

### Acknowledgments

This study was supported in part by grants from the Ministry of Science and Technology (NSC 100-2321-B-002-004, NSC 100-2313-B-002-036, NSC 101-2313-B-002-061-MY2, and NSC 102-2628-B-002-010-MY2), the National Taiwan University (Aim for Top University Program 102R-7620), and the Council of Agriculture, Executive Yuan (104A-3053), Taiwan.

### References

- [1] Ministry of Health and Welfare. 2014 Statistics of causes of death. Taipei, Taiwan: Department of Statistics; 2015.
- [2] Dey A, Lakshmanan J. The role of antioxidants and other agents in alleviating hyperglycemia mediated oxidative stress and injury in liver. *Food Funct* 2013;4:1148–84.
- [3] Chowdhury MR, Sagor MA, Tabassum N, Potoi MA, Hossain H, Alam MA. Supplementation of *Citrus maxima* peel powder prevented oxidative stress, fibrosis, and hepatic damage in carbon tetrachloride (CCl<sub>4</sub>) treated rats. *Evid Based Complement Alternat Med* 2015;2015:598179.
- [4] Ucar F, Sezer S, Erdogan S, Akyol S, Armutcu F, Akyol O. The relationship between oxidative stress and nonalcoholic fatty liver disease: its effects on the development of nonalcoholic steatohepatitis. *Redox Rep* 2013;18:127–33.
- [5] Valko M, Leibfritz D, Moncol J, Cronin MT, Mazur M, Telsler J. Free radicals and antioxidants in normal physiological functions and human disease. *Int J Biochem Cell Biol* 2007;39:44–84.
- [6] Mangge H, Becker K, Fuchs D, Gostner JM. Antioxidants, inflammation and cardiovascular disease. *World J Cardiol* 2014;6:462–77.
- [7] Hou Y, Jiang JG. Origin and concept of medicine food homology and its application in modern functional foods. *Food Funct* 2013;4:1727–41.
- [8] Korivi M, Hou CW, Huang CY, Lee SD, Hsu MF, Yu SH, Chen CY, Liu YY, Kuo CH. Ginsenoside-Rg1 protects the liver against exhaustive exercise-induced oxidative stress in rats. *Evid Based Complement Alternat Med* 2012;2012:932165.
- [9] Smolinski AT, Pestka JJ. Modulation of lipopolysaccharide-induced proinflammatory cytokine production *in vitro* and *in vivo* by the herbal constituents apigenin (chamomile), ginsenoside Rb(1) (ginseng) and parthenolide (feverfew). *Food Chem Toxicol* 2003;41:1381–90.
- [10] Attele AS, Zhou YP, Xie JT, Wu JA, Zhang L, Dey L, Pugh W, Rue PA, Polonsky KS, Yuan CS. Antidiabetic effects of *Panax ginseng* berry extract and the identification of an effective component. *Diabetes* 2002;51:1851–8.

- [11] Chang YS, Seo EK, Gyllenhaal C, Block KI. Panax ginseng: a role in cancer therapy? *Integr Cancer Ther* 2003;2:13–33.
- [12] Sohn DH, Kim YC, Oh SH, Park EJ, Li X, Lee BH. Hepatoprotective and free radical scavenging effects of *Nelumbo nucifera*. *Phytomedicine* 2003;10:165–9.
- [13] Mukherjee PK, Saha K, Pal M, Saha BP. Effect of *Nelumbo nucifera* rhizome extract on blood sugar level in rats. *J Ethnopharmacol* 1997;58:207–13.
- [14] Ono Y, Hattori E, Fukaya Y, Imai S, Ohizumi Y. Anti-obesity effect of *Nelumbo nucifera* leaves extract in mice and rats. *J Ethnopharmacol* 2006;106:238–44.
- [15] Francis JA, Rumbelha W, Nair MG. Constituents in Easter lily flowers with medicinal activity. *Life Sci* 2004;76:671–83.
- [16] Mimaki Y, Nakamura O, Sashida Y, Satomi Y, Nishino A, Nishino H. Steroidal saponins from the bulbs of *Lilium longiflorum* and their antitumor-promoter activity. *Phytochemistry* 1994;37:227–32.
- [17] Munafo Jr JP, Gianfagna TJ. Antifungal activity and fungal metabolism of steroidal glycosides of Easter lily (*Lilium longiflorum* Thunb.) by the plant pathogenic fungus, *Botrytis cinerea*. *J Agric Food Chem* 2011;59:5945–54.
- [18] Jin L, Zhang Y, Yan L, Guo Y, Niu L. Phenolic compounds and antioxidant activity of bulb extracts of six *Lilium* species native to China. *Molecules* 2012;17:9361–78.
- [19] Kodai S, Takemura S, Minamiyama Y, Hai S, Yamamoto S, Kubo S, Yoshida Y, Niki E, Okada S, Hirohashi K, et al. S-allyl cysteine prevents CCl<sub>4</sub>-induced acute liver injury in rats. *Free Radic Res* 2007;41:489–97.
- [20] Recknagel RO, Glende Jr EA, Dolak JA, Waller RL. Mechanisms of carbon tetrachloride toxicity. *Pharmacol Ther* 1989;43:139–54.
- [21] Lettéron P, Labbe G, Degott C, Berson A, Fromenty B, Delaforge M, Larrey D, Pessayre D. Mechanism for the protective effects of silymarin against carbon tetrachloride-induced lipid peroxidation and hepatotoxicity in mice. Evidence that silymarin acts both as an inhibitor of metabolic activation and as a chain-breaking antioxidant. *Biochem Pharmacol* 1990;39:2027–34.
- [22] Shaker E, Mahmoud H, Mnaa S. Silymarin, the antioxidant component and *Silybum marianum* extracts prevent liver damage. *Food Chem Toxicol* 2010;48:803–6.
- [23] Rasool M, Iqbal J, Malik A, Ramzan HS, Qureshi MS, Asif M, Qazi MH, Kamal MA, Chaudhary AG, Al-Qahtani MH, et al. Hepatoprotective effects of *Silybum marianum* (silymarin) and *Glycyrrhiza glabra* (glycyrrhizin) in combination: a possible synergy. *Evid Based Complement Alternat Med* 2014;2014:641597.
- [24] Xie JT, Wang CZ, Zhang B, Mehendale SR, Li XL, Sun S, Han AH, Du W, He TC, Yuan CS. *In vitro* and *in vivo* anticancer effects of American ginseng berry: exploring representative compounds. *Biol Pharm Bull* 2009;32:1552–8.
- [25] Ren G, Chen F. Simultaneous quantification of ginsenosides in American ginseng (*Panax quinquefolium*) root powder by visible/near-infrared reflectance spectroscopy. *J Agric Food Chem* 1999;47:2771–5.
- [26] Lu KH, Tseng HC, Liu CT, Huang CJ, Chyuan JH, Sheen LY. Wild bitter gourd protects against alcoholic fatty liver in mice by attenuating oxidative stress and inflammatory responses. *Food Funct* 2014;5:1027–37.
- [27] Yao QY, Xu BL, Wang JY, Liu HC, Zhang SC, Tu CT. Inhibition by curcumin of multiple sites of the transforming growth factor-beta1 signalling pathway ameliorates the progression of liver fibrosis induced by carbon tetrachloride in rats. *BMC Complement Altern Med* 2012;12:156.
- [28] Lee HU, Bae EA, Han MJ, Kim NJ, Kim DH. Hepatoprotective effect of ginsenoside Rb1 and compound K on tert-butyl hydroperoxide-induced liver injury. *Liver Int* 2005;25:1069–73.
- [29] Lee HU, Bae EA, Han MJ, Kim DH. Hepatoprotective effect of 20(S)-ginsenosides Rg3 and its metabolite 20(S)-ginsenoside Rh2 on tert-butyl hydroperoxide-induced liver injury. *Biol Pharm Bull* 2005;28:1992–4.
- [30] Ramkumar KM, Rajesh R, Anuradha CV. Food restriction attenuates blood lipid peroxidation in carbon tetrachloride-intoxicated rats. *Nutrition* 2003;19:358–62.
- [31] De la Iglesia F, Sturgess JM, Feuer G. New approaches for assessment of hepatotoxicity by means of quantitative functional-morphological interrelationship in toxicity of liver. New York: Raven Press; 1982. p. 23–8.
- [32] Braet F, Wisse E. Structural and functional aspects of liver sinusoidal endothelial cell fenestrae: a review. *Comp Hepatol* 2002;1:1.
- [33] Iredale JP. Models of liver fibrosis: exploring the dynamic nature of inflammation and repair in a solid organ. *J Clin Invest* 2007;117:539–48.
- [34] Sturgill MG, Lambert GH. Xenobiotic-induced hepatotoxicity: mechanisms of liver injury and methods of monitoring hepatic function. *Clin Chem* 1997;43:1512–26.
- [35] Pfeifer KF, Weber LJ. The effect of carbon tetrachloride treatment on urine flow rate of the rainbow trout, *Salmo gairdneri*. *Toxicol Appl Pharmacol* 1980;52:347–50.
- [36] Clawson GA, MacDonald JR, Woo CH. Early hypomethylation of 2'-O-ribose moieties in hepatocyte cytoplasmic ribosomal RNA underlies the protein synthetic defect produced by CCl<sub>4</sub>. *J Cell Biol* 1987;105:705–11.
- [37] Krithika R, Verma RJ. Ameliorative potential of *Phyllanthus amarus* against carbon tetrachloride-induced hepatotoxicity. *Acta Pol Pharm* 2009;66:579–83.
- [38] El-Kamary SS, Shardell MD, Abdel-Hamid M, Ismail S, El-Ateek M, Metwally M, Mikhail N, Hashem M, Mousa A, Aboul-Fotouh A, et al. A randomized controlled trial to assess the safety and efficacy of silymarin on symptoms, signs and biomarkers of acute hepatitis. *Phytomedicine* 2009;16:391–400.
- [39] Banaee M, Sureda A, Mirvaghefi AR, Rafei GR. Effects of long-term silymarin oral supplementation on the blood biochemical profile of rainbow trout (*Oncorhynchus mykiss*). *Fish Physiol Biochem* 2011;37:885–96.
- [40] Recknagel RO, Lombardi B, Schotz MC. A new insight into pathogenesis of carbon tetrachloride fat infiltration. *Proc Soc Exp Biol Med* 1960;104:608–10.
- [41] Rao KS, Recknagel RO. Early onset of lipoperoxidation in rat liver after carbon tetrachloride administration. *Exp Mol Pathol* 1968;9:271–8.
- [42] Glende Jr EA, Recknagel RO. Biochemical basis for the *in vitro* pro-oxidant action of carbon tetrachloride. *Exp Mol Pathol* 1969;11:172–85.
- [43] Halim AB, el-Ahmady O, Hassab-Allah S, Abdel-Galil F, Hafez Y, Darwish A. Biochemical effect of antioxidants on lipids and liver function in experimentally-induced liver damage. *Ann Clin Biochem* 1997;34:656–63.
- [44] Chan DC, Barrett PH, Watts GF. Lipoprotein transport in the metabolic syndrome: pathophysiological and interventional studies employing stable isotope and modelling methods. *Clin Sci (Lond)* 2004;107:233–49.
- [45] Ozden S, Catalgol B, Gezginci-Oktayoglu S, Arda-Pirincci P, Bolkent S, Alpertunga B. Methiocarb-induced oxidative damage following subacute exposure and the protective effects of vitamin E and taurine in rats. *Food Chem Toxicol* 2009;47:1676–84.
- [46] Maellaro E, Casini AF, Del Bello B, Comporti M. Lipid peroxidation and antioxidant systems in the liver injury produced by glutathione depleting agents. *Biochem Pharmacol* 1990;39:1513–21.
- [47] Amer J, Grifal R, Doron S, Abu-Tair L, Mruwat R, El-Khatib A, Safadi R. The pro-fibrotic effects of pregnancy in a carbon-tetrachloride-induced liver injury in mouse model. *Liver Int* 2014;34:1232–40.
- [48] Guyot C, Lepreux S, Combe C, Doudnikoff E, Bioulac-Sage P, Balabaud C, Desmoulière A. Hepatic fibrosis and cirrhosis: the (myo)fibroblastic cell sub-populations involved. *Int J Biochem Cell Biol* 2006;38:135–51.
- [49] Jin YL, Enzan H, Kuroda N, Hayashi Y, Nakayama H, Zhang YH, Toi M, Miyazaki E, Hiroi M, Guo LM, et al. Tissue remodeling following submassive hemorrhagic necrosis in rat livers induced by an intraperitoneal injection of dimethylnitrosamine. *Virchows Arch* 2003;442:39–47.