



Cushing's like syndrome in typical bronchial carcinoid a case report and review of the literature



Ilaria Pedicelli^a, Giuseppina Patriciello^b, Giovanni Scala^a, Antonietta Sorrentino^a, Gennaro Gravino^a, Pasquale Patriciello^a, Pio Zeppa^c, Vincenzo Di Crescenzo^c, Alessandro Vatrella^{c,*}

^a Division of Respiratory Disease, Ospedali Riuniti Area Nolana, Italy

^b Department of Psychiatry, Second University of Naples, Italy

^c Department of Medicine and Surgery, University of Salerno, Italy

ARTICLE INFO

Article history:

Available online 4 February 2016

Keywords:

Cushing's syndrome
Bronchial carcinoid
Bronchoscopy

ABSTRACT

Cushing's syndrome occurred in 1–5% of cases of bronchial carcinoids. In this paper we describe a case of typical bronchial carcinoid in a nonsmoker young male with clinical manifestations mimicking a Cushing's syndrome. The patient performed chest radiograph and computed tomography. Fiberoptic bronchoscopy revealed the presence of an endobronchial mass occluding the bronchus intermedius. A rigid bronchoscopy was necessary for the conclusive diagnosis and for partial resection of the intraluminal tumor. Despite the presence of Cushingoid features, the normal blood levels of ACTH and cortisol excluded the coexistence of a Cushing's syndrome.

© 2016 The Authors. Published by Elsevier Ltd. on behalf of IJS Publishing Group Ltd. This is an open access article under the CC BY-NC-ND license (<http://creativecommons.org/licenses/by-nc-nd/4.0/>).

1. Introduction

Bronchial carcinoids represent a small portion of all pulmonary tumors and about 1–5% of them are associated with ectopic ACTH secretion, which represents 1–10% of Cushing's syndrome cases [1–3]. Cushing's syndrome (CS) is the result of chronic exposure to increased concentration of cortisol hormone exogenous or endogenous, and it is generally associated with central obesity, metabolic syndrome, hypertension. Neuropsychological disturbances are also frequently observed, including depression, emotional irritability, sleep disturbance and cognitive deficits that can be the first manifestation perceived by family members of patients affected by CS. Treatment is based on decreasing of cortisol levels in blood, through medical or surgical approaches. Surgery is considered the main treatment for ectopic ACTH-secreting tumors. We describe a case of typical bronchial carcinoid associated with a Cushing's like syndrome.

2. Case report

A 26 year-old severe obese male with an history of anxiety over the last 5 years was admitted to our department of Respiratory Medicine referring poorly cough, fever (39°C), sputum and shortness of breath. He was a nonsmoker and his weight, height and body mass index were 163 kg, 1.90 m and 45.15 kg × m², respectively. A physical exam revealed round facies, extensive purple striae on his abdomen and marked central obesity, mimicking Cushingoid features. Auscultation of the chest revealed hypophonesis and reduction of breath sound of the basal right hemithorax. Pulse was regular and blood pressure normal; the haemoglobin oxygen saturation was 91% in room air. Laboratory data showed an increase of neutrophilic count and hypertriglyceridemia. A chest radiograph showed a lift of right hemidiaphragm with ipsilateral scanty pleural effusion (Fig. 1). The clinical and radiological data suggested the diagnosis of pneumonia and the patient was treated with ciprofloxacin 400 mg iv bid and systemic steroids for 10 days. The treatment determined a substantial improvement of clinical condition, but did not modify significantly chest imagines. Subsequently the patient performed a computed tomography that revealed the presence of a solid mass in the bronchus intermedius associated with a complete atelectasis of middle and lower right lobe (Fig. 2a,b). Fiberoptic bronchoscopy revealed a pale tissue with irregular margins measuring approximately 1 cm in diameter and obliterating completely the bronchus intermedius (Fig. 3). The endobronchial biopsies showed fibrinoid material and microcalcifications in the contest of a nonspecific granulation tissue but

* Corresponding author at: Department of Medicine and Surgery, University of Salerno, Baronissi Campus, Via S. Allende, 84081 Baronissi, Salerno, Italy. Fax: +39 0 089 955026.

E-mail addresses: ilaria.pedicelli@libero.it (I. Pedicelli), pleplo@libero.it (G. Patriciello), giovanniscala@tin.it (G. Scala), nappoerminia@alice.it (A. Sorrentino), gg62@live.it (G. Gravino), or.areanolana.pneumologia@aslnapoli3sud.it (P. Patriciello), pzeppa@unisa.it (P. Zeppa), vdicrescenzo@unisa.it (V. Di Crescenzo), avatrella@unisa.it (A. Vatrella).

<http://dx.doi.org/10.1016/j.ijscr.2016.02.006>

2210-2612/© 2016 The Authors. Published by Elsevier Ltd. on behalf of IJS Publishing Group Ltd. This is an open access article under the CC BY-NC-ND license (<http://creativecommons.org/licenses/by-nc-nd/4.0/>).

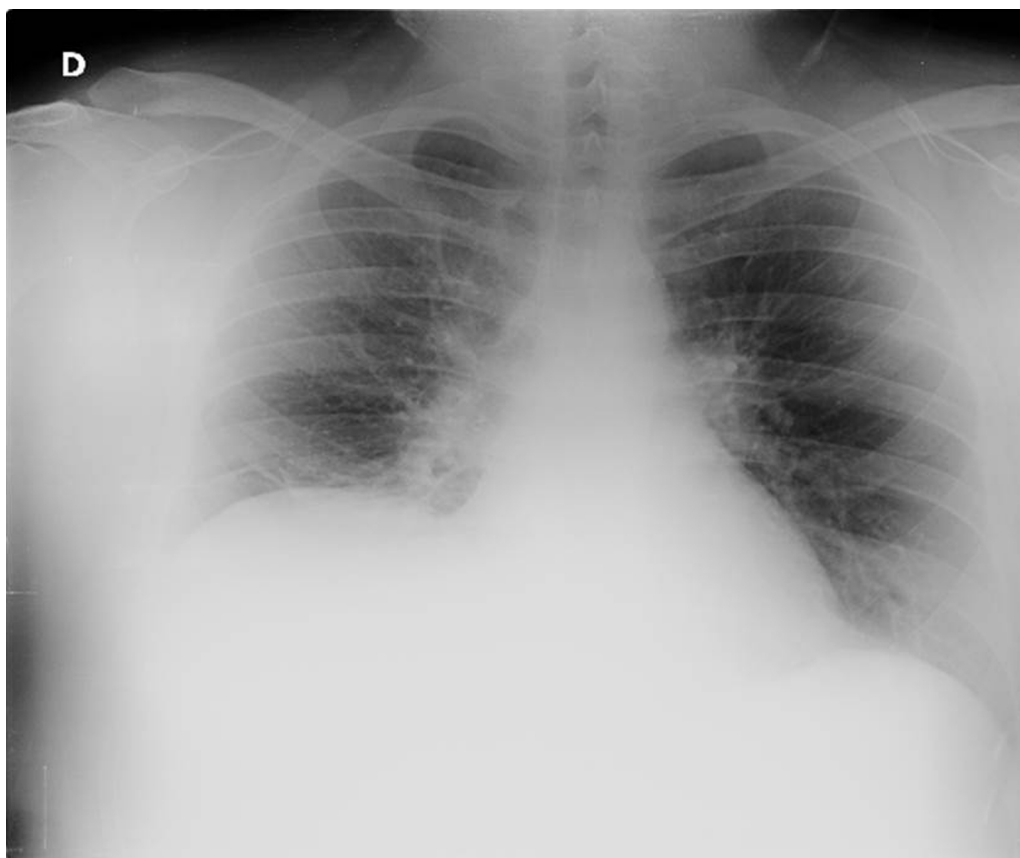


Fig. 1. Chest radiograph showing a lift of right hemidiaphragm with ipsilateral scanty pleural effusion.

were not conclusive for a diagnosis. The patient underwent a rigid bronchoscopy for diagnostic purpose and for partial resection of the intraluminal mass.

Histopathological examination of endobronchial removed samples showed a typical carcinoid tumor with a trabecular pattern and without areas of necrosis, <2 mitoses per 2 mm^2 detected by ki67 immunostaining, high CD56 and high chromogranin expression indicating neuroendocrine differentiation. On the basis of diagnosis of neuroendocrine tumor and Cushingoids features a blood test was carried out which demonstrated normal levels of ACTH and cortisol. The determination of a twenty four hour urinary free cortisol resulted normal and a high-dose dexamethasone suppression test (2 mg every 6 h for eight doses) induced a partially suppression of

ACTH secretion. Moreover, the patient underwent a brain MRI that excluded the presence of a pituitary microadenoma.

A flexible bronchoscopy performed two months later showed a complete recanalization of bronchus intermedius, with a partial unblocking of middle and lower bronchi (Fig. 4). Surgical resection was considered as therapy of choice, but bilobectomy was not performed because of elevated intraoperative risk associated to the severe obesity and respiratory failure. The patient was advised a dietary treatment and a conservative initial bronchoscopic treatment for tumor eradication.

Despite of prescription the patient was not able to lose weight (just 10 kg in one year), he still presents persistent psychiatric disorders and severe obesity. Two rigid bronchoscopies were performed during the year to avoid the local growth of the tumor and

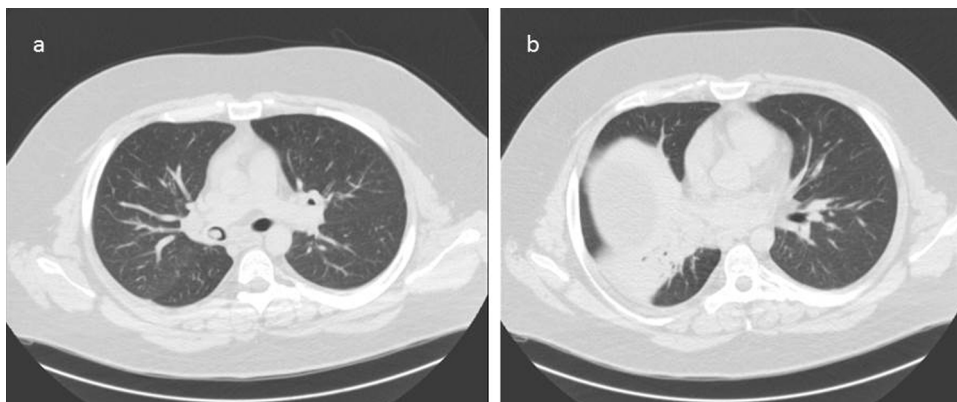


Fig. 2. Computed tomography: (a) presence of a solid mass in the bronchus intermedius; (b) atelectasis of middle and lower right lobe.

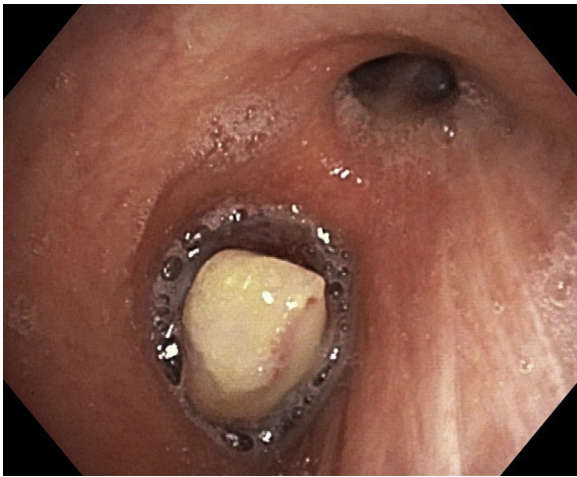


Fig. 3. Flexible bronchoscopy reveals a solid mass obliterating completely the bronchus intermedius.

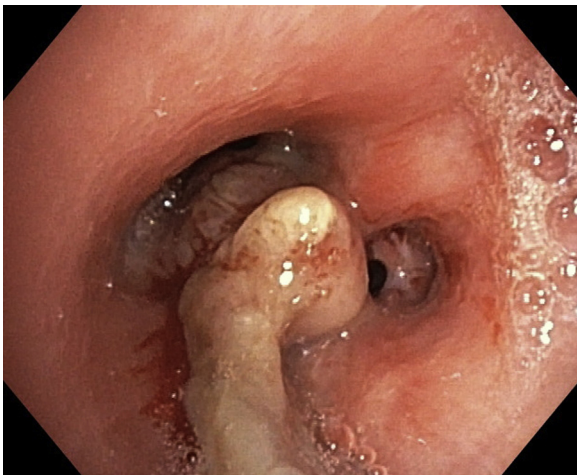


Fig. 4. Flexible bronchoscopy performed after partial resection of the neoplasm. In the figure are visible residual neoplastic tissue and the origins of the middle and lower bronchi.

control the possible differentiation of typical (TC) versus atypical (AC) histological type of pulmonary carcinoid. Anyway, the surgical resection represents the subsequently appropriate step.

3. Discussion

Carcinoids account for 1–2% of all pulmonary neoplasms in adults and approximately 25–30% of all carcinoid tumors [4–19]. They are considered to be a low grade malignancy belonging to the spectrum of neuroendocrine tumors. In 2004, the WHO devised a new classification for bronchopulmonary carcinoids based upon a spectrum of clinicopathological entities ranging from hyperplastic neuroendocrine cell lesions (carcinoid tumorlets, diffuse idiopathic pulmonary neuroendocrine cell hyperplasia) to high grade neuroendocrine tumors (small cell carcinoma and large cell neuroendocrine carcinoma). The initial presentation can be in the parenchyma or mainly in the airways and are described as bronchial carcinoids. Approximately 10–20% of pulmonary carcinoids are atypical carcinoids (AC), 80–90% are typical carcinoids (TC). Typical carcinoids are well differentiated, can exhibit distinct recognized histologic pattern (insular, trabecular, glandular, mixed or undifferentiated) and rare mitoses. They usually present as perihilar masses and are generally asymptomatic; however some patients may

present recurrent pneumonia, cough, hemoptysis and chest pain. Ectopic secretion of biologically active hormones is not uncommon, in particular corticotrophin and growth hormone and it occurs in fewer of 5% of patients with these tumors. Conversely, atypical carcinoids represent an intermediate grade neuroendocrine tumors; they may exhibit increased nuclear atypia, focal necrosis or high mitotic indices and their clinical course is aggressive with an high incidence of mediastinal lymphnode metastases and a 5-year survival rate of 40–75% [20]. Surgical resection is the preferred treatment of bronchopulmonary carcinoid tumors, anyway the improvement of diagnostic and therapeutic techniques and further understanding of tumor biology are driving new minimally invasive approaches to diagnosis and therapy of these tumors. Recent literature reports that the initial bronchoscopic treatment seems to be a justifiable approach for bronchial carcinoids instead of immediate surgical exploration and resection, because of an excellent long term outcome [21]. These studies justified our treatment approach in the reported case. Surgery could be associated to an elevate intraoperative risk, the choice of treating with rigid bronchoscopy can reduce the risk and improve the quality of life of the patient, although it does not produce a radical resolution.

Cushing's syndrome can be caused by an excess ACTH production by a pituitary corticotroph adenoma, an extrapituitary tumor (ectopic ACTH syndrome) or, very rarely, by a tumor secreting CRH (ectopic CRH syndrome). Ectopic ACTH secretion occurs in 15–20% of patients with ACTH dependent Cushing's syndrome with the lung being the origin of over 45% of ACTH-producing tumors (ectopic), followed by thymus (11%) and pancreas (8%). Cushing's syndrome is characterized by presence of central obesity, associated with systemic arterial hypertension, hyperlipidemia, impaired glucose tolerance or diabetes and hypercoagulability [22]. An elevated number of psychiatric and psychological disorders can be associated with Cushing syndrome. A percentage between 50 and 80% of Cushing syndrome patients meet "Diagnostic and Statistical Manual of Mental Disorders IV criteria of major depression", while a minority of them have other psychopathological manifestations including mania, anxiety and cognitive dysfunction. Has been also reported suicidal tendency in patients with CS and the presence of depressive symptoms can be an early manifestation of CS [23]. Psychological and psychiatric symptoms improve with the normalization of cortisol levels in blood, obtained with surgical approach [24–30].

In conclusion the evidence of central obesity, purple striae on the abdomen, prominent eyes, round facies, skin hyperpigmentation and the concomitant and early appearance of psychological disorder, in a patient affected by typical bronchial carcinoid, was strongly suggestive of Cushing's syndrome, but the diagnosis was not confirmed by laboratory findings, although it is not possible completely to exclude the periodic secretion of ectopic cortisol ACTH/CRH correlated.

Conflict of interest

The authors have no conflict of interest or any financial support.

References

- [1] G. Boddaert, B. Grand, F. Le Pimpec-Barthes, A. Cazes, X. Bertagna, M. Riquet, Bronchial carcinoid tumors causing Cushing's syndrome: more aggressive behavior and the need for early diagnosis, *Ann. Thorac. Surg.* 94 (2012) 1823–1829.
- [2] S.J. Deb, F.C. Nichols, M.S. Allen, C. Deschamps, S.D. Cassivi, P.C. Pairolero, Pulmonary carcinoid tumors with Cushing's syndrome: an aggressive variant or not? *Ann. Thorac. Surg.* 79 (2005) 1132–1136.
- [3] B.L. Riggs Jr., R.G. Sprague, Association of Cushing's syndrome and neoplastic disease: observations in 232 cases of Cushing's syndrome and review of the literature, *Arch. Intern. Med.* 108 (1961) 841–849.

- [4] P. Zeppa, M. Vitale, Fine-needle cytology of Hürthle cell tumors and morphometry, *Cancer Cytopathol.* 122 (2014) 553.
- [5] P. Zeppa, M. Vitale, Fine needle cytology and flow cytometry in Hashimoto thyroiditis and primary thyroid lymphoma, *Acta Cytol.* 58 (2014) 318.
- [6] A. Puzziello, M. Carrano, E. Angrisani, V. Marotta, A. Faggiano, P. Zeppa, M. Vitale, Evolution of benign thyroid nodules under levothyroxine non-suppressive therapy, *J. Endocrinol. Invest.* (July) (2014) [Epub ahead of print].
- [7] A. Caleo, E. Vigliar, M. Vitale, V. Di Crescenzo, M. Cinelli, C. Carlomagno, A. Garzi, P. Zeppa, Cytological diagnosis of thyroid nodules in Hashimoto thyroiditis in elderly patients, *BMC Surg.* 13 (Suppl. 2) (2013) S41.
- [8] A. Guerra, V. Di Stasi, P. Zeppa, A. Faggiano, V. Marotta, M. Vitale, BRAF(V600E) assessment by pyrosequencing in fine needle aspirates of thyroid nodules with concurrent Hashimoto's thyroiditis is a reliable assay, *Endocrine* 45 (2014) 249–255.
- [9] P. Zeppa, I. Cozzolino, A.L. Peluso, G. Troncone, A. Lucariello, M. Picardi, C. Carella, F. Pane, A. Vetrani, L. Palombini, Cytologic, flow cytometry, and molecular assessment of lymphoid infiltrate in fine-needle cytology samples of Hashimoto thyroiditis, *Cancer* 117 (2009) 174–184.
- [10] P. Zeppa, G. Marino, M. Lepore, G. Troncone, G.A. Lupoli, B. Biondi, M. Picardi, F. Pane, A. Vetrani, L. Palombini, Flow cytometry phenotypization of thyroidal lymphoid infiltrate and functional status in Hashimoto's thyroiditis, *Anal. Quant. Cytol. Histol.* 28 (2006) 148–156.
- [11] A. Caleo, E. Vigliar, M. Vitale, V. Di Crescenzo, M. Cinelli, C. Carlomagno, A. Garzi, P. Zeppa, Cytological diagnosis of thyroid nodules in Hashimoto thyroiditis in elderly patients, *BMC Surg.* 13 (Suppl. 2) (2013) S41.
- [12] A. Guerra, M. Carrano, E. Angrisani, A. Puzziello, G. Izzo, V. Di Crescenzo, A. Vatrella, M. Vitale, Detection of RAS mutation by pyrosequencing in thyroid cytology samples, *Int. J. Surg.* 12 (Suppl. 1) (2014) 91–94.
- [13] A. Guerra, V. Di Crescenzo, A. Garzi, M. Cinelli, C. Carlomagno, S. Pepe, P. Zeppa, M. Tonacchera, M. Vitale, Diagnostic utility of BRAFV600E mutation testing in thyroid nodules in elderly patients, *BMC Surg.* 13 (Suppl. 2) (2013) S37.
- [14] A. Guerra, V. Di Crescenzo, A. Garzi, M. Cinelli, C. Carlomagno, M. Tonacchera, P. Zeppa, M. Vitale, Genetic mutations in the treatment of anaplastic thyroid cancer: a systematic review, *BMC Surg.* 13 (Suppl. 2) (2013) S44.
- [15] V. Di Crescenzo, P. Laperuta, F. Napolitano, C. Carlomagno, M. Danzi, B. Amato, A. Garzi, M. Vitale, Unusual case of exacerbation of sub-acute descending necrotizing mediastinitis, *BMC Surg.* 13 (Suppl. 2) (2013) S31.
- [16] P. Laperuta, F. Napolitano, A. Garzi, B. Amato, A. Vatrella, V. Di Crescenzo, Extrathoracic recurrence of type A thymoma, *Int. J. Surg.* 12 (Suppl. 1) (2014) S16–S18.
- [17] T. Di Matola, P. Zeppa, M. Gasperi, M. Vitale, Thyroid dysfunction following a kelp-containing marketed diet, *BMJ Case Rep.* (October) (2014).
- [18] V. Di Crescenzo, A. Garzi, F. Petruzzello, M. Cinelli, L. Catalano, P. Zeppa, M. Vitale, Nodular goiter with amyloid deposition in an elderly patient: fine-needle cytology diagnosis and review of the literature, *BMC Surg.* 13 (Suppl. 2) (2013) S43.
- [19] P. Zeppa, I. Cozzolino, A.L. Peluso, G. Troncone, A. Lucariello, M. Picardi, C. Carella, F. Pane, A. Vetrani, L. Palombini, Cytologic, flow cytometry, and molecular assessment of lymphoid infiltrate in fine-needle cytology samples of Hashimoto thyroiditis, *Cancer* 117 (2009) 174–184.
- [20] I. Nenekidis, G.T. Stathopoulos, V. Anagnostakou, et al., Atypical pulmonary carcinoid tumour in a 28-year-old nonsmoker with Prader–Willi syndrome, *Eur. Respir. J.* 38 (November 5) (2011) 1230–1233.
- [21] H.A. Brokx, M.A. Paul, P.E. Postmus, et al., Long term follow-up after first line bronchoscopic therapy in patients with bronchial carcinoids, *Thorax* 70 (2015) 468–472.
- [22] G. Arnaldi, A. Angeli, A.B. Atkinson, et al., Diagnosis and complications of Cushing's syndrome: a consensus statement, *J. Clin. Endocrinol. Metab.* 88 (2003) 5593–5602.
- [23] R. Pivonello, C. Simeoli, M.C. De Martino, et al., Neuropsychiatric disorders in Cushing's syndrome, *Front. Neurosci.* 9 (April) (2015) 129.
- [24] M. Baba, D. Ray, Severe psychosis due to Cushing's syndrome in a patient with carcinoid tumor in the lung: a case report and review of the current management, *World J. Surg. Oncol.* 13 (2015) 165.
- [25] G. Pelaia, A. Vatrella, M.T. Busceti, L. Gallelli, C. Calabrese, R. Terracciano, R. Maselli, Cellular mechanisms underlying eosinophilic and neutrophilic airway inflammation in asthma, *Mediators Inflamm.* 2015 (March) (2015) 879783, Epub 2015, Review.
- [26] G. D'Amato, A. Stanziola, A. Sanduzzi, G. Liccardi, A. Salzillo, C. Vitale, A. Molino, A. Vatrella, M. D'Amato, Treating severe allergic asthma with anti-IgE monoclonal antibody (omalizumab): a review, *Multidiscip. Respir. Med.* 9 (2014) 23.
- [27] L. Gallelli, M.T. Busceti, A. Vatrella, R. Maselli, G. Pelaia, Update on anticytokine treatment for asthma, *Biomed. Res. Int.* 2013 (2013) 104315.
- [28] G. Pelaia, T. Renda, L. Gallelli, A. Vatrella, M.T. Busceti, S. Agati, M. Caputi, M. Cazzola, R. Maselli, S.A. Marsico, Molecular mechanisms underlying airway smooth muscle contraction and proliferation: implications for asthma, *Respir. Med.* 102 (2008) 1173–1181, Review.
- [29] G. Pelaia, R. Terracciano, A. Vatrella, L. Gallelli, M.T. Busceti, C. Calabrese, C. Stellato, R. Savino, R. Maselli, Application of proteomics and peptidomics to COPD, *Biomed. Res. Int.* 2014 (2014) 764581.
- [30] G. Pelaia, A. Vatrella, M.T. Busceti, L. Gallelli, R. Terracciano, R. Maselli, Anti-IgE therapy with omalizumab for severe asthma: current concepts and potential developments, *Curr. Drug Targets* 16 (2015) 171–178.

Open Access

This article is published Open Access at sciedirect.com. It is distributed under the [IJSCR Supplemental terms and conditions](#), which permits unrestricted non commercial use, distribution, and reproduction in any medium, provided the original authors and source are credited.