Kaohsiung Journal of Medical Sciences (2014) 30, 587–588

Available online at www.sciencedirect.com

ScienceDirect

journal homepage: http://www.kjms-online.com

LETTER TO THE EDITOR

Primary cutaneous mucinous carcinoma of the breast

To the Editor,

Primary mucinous carcinoma of the skin (PMCS) is a rare form of malignant neoplasm, occurring in approximately one case in every 150,000 specimens of cutaneous lesions [1]. Here, we present a case of PMCS of the breast.

A 63-year-old woman suffered from an indurated nodule of less than 1 cm in size on her left breast. Ultrasonography and mammography revealed nonspecific findings. She underwent left partial mastectomy and sentinel lymph node dissection. Pathology revealed an unencapsulated asymmetric dermal tumor composed of lakes of mucus separated by fibrous septa and floating clusters of neoplastic epithelial cells in the mucus lakes, which is consistent with cutaneous mucinous carcinoma (pT1N0) (Fig. 1). Thorough clinical investigation, sentinel nodes dissection, and imaging studies demonstrated the absence of regional lymph nodes or distant metastases and ruled out a primary cancer at any other site, and it was concluded that the tumor was primary. Neither relapse nor distal metastases were noted at 1 year and 6 months follow-up.

PMCS is a rare form of malignant neoplasm deriving from the sweat glands or their germinal structures, and it affects men more than women. It tends to occur in the middle-aged or elderly (average 62.6 years, range 8–87 years). This tumor commonly arises in the head or neck (72%), followed by axilla (9%), vulva (4%), chest/abdominal wall (7%), neck (2%), extremity (2%), canthus (2%), groin (1%), and ear (1%) [2].

PMCS usually appears as a solitary, asymptomatic, slow-growing subcutaneous or cutaneous nodule [2]. The color of the lesion may be tan, gray, blue, or brown [3]. The surface may be smooth, ulcerated, or crusted [2]. Our case showed no skin change. The histopathological appearance of PMCS is highly characteristic, notable for dermal islands of tumor cells with mildly pleomorphic nuclei floating in a pale-staining lake of mucin separated by strands of fibrous tissue [4]. However, PMCS is morphologically indistinguishable from mucinous tumors metastatic to the skin, although an *in situ* component of confluent myoepithelial cells around tumor lobules has been mentioned to support the diagnosis of primary mucinous carcinoma [5]. To date, no immunohistochemical panel has been identified to consistently differentiate primary from metastatic mucinous carcinoma. A variety of stains have been reported to be helpful in the differential diagnosis of primary versus metastatic mucinous adenocarcinoma of skin, including p63, CK5/6, and D2-40 [5]. However, final diagnosis can be made after thorough clinical investigation, which excludes the presence of a more common primary mucinous carcinoma of breast, lung, gastrointestinal tract, gall bladder, prostate, or ovary [1].

The treatment of choice for PMCS is a wide surgical excision including dissection of the regional lymph nodes. Mohs surgery may be an alternative method if wide excision is impossible [1]. PMCS is unresponsive to radiation therapy or chemotherapeutic agents [2]. Local recurrence is common (20–30%). Distant metastases are less common (9.6%) [2]. Long-term follow-up with regular clinical investigation to detect tumor recurrence and metastasis is mandatory.

References

[1] Breiting L, Christensen L, Dahlstrom K, Breiting V, Winther JF. Primary mucinous carcinoma of the skin: a population-based study. Int J Dermatol 2008;47:242–5.

[2] Scilletta A, Soma PF, Grasso G, Scilletta R, Pompili G, Tarico MS, et al. Primary cutaneous mucinous carcinoma of the cheek. Case report. G Chir 2011;32:323–5.

[3] Zhang Q, Wojno TH, Fitch SD, Grossniklaus HE. Mucinous eccrine adenocarcinoma of the eyelid: report of 6 cases. Can J Ophthalmol 2010;45:76–8.

Conflicts of interest: All authors declare no conflicts of interest.

http://dx.doi.org/10.1016/j.kjms.2014.02.002

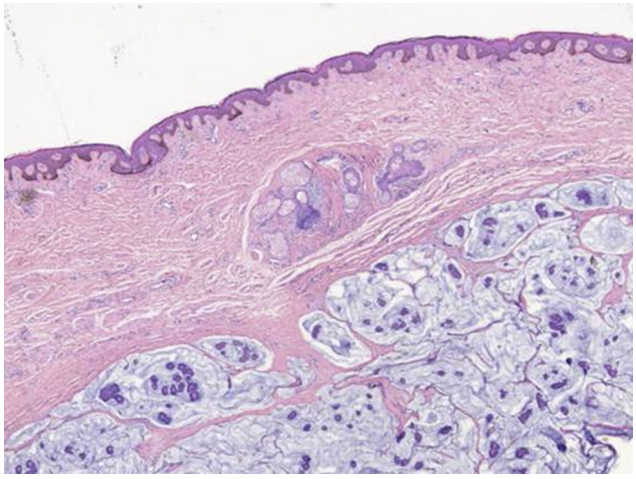

Figure 1. Microscopy shows asymmetric dermal tumor with large pools of mucin and floating clusters of neoplastic epithelial cells (hematoxylin and eosin stain, original magnification, 40×).

[4] McLeod MP, Choudhary S, Nouri K. A case of mucinous eccrine carcinoma. Dermatol Surg 2011;37:1192—3.
[5] Levy G, Finkelstein A, McNiff JM. Immunohistochemical techniques to compare primary vs. metastatic mucinous carcinoma of the skin. J Cutan Pathol 2010;37:411—5.

Han-Sheng Chen
Department of Medical Imaging, Kaohsiung Medical University Hospital, Kaohsiung, Taiwan

Fang-Ming Chen
Department of Surgery, Faculty of Medicine, College of Medicine, Kaohsiung Medical University, Kaohsiung, Taiwan

Department of Surgery, Kaohsiung Municipal Ta-Tung Hospital, Kaohsiung, Taiwan

Sheau-Fang Yang
Department of Pathology, Kaohsiung Municipal Ta-Tung Hospital, Kaohsiung, Taiwan

Department of Pathology, School of Medicine, College of Medicine, Kaohsiung Medical University, Kaohsiung, Taiwan

Jui-Sheng Hsu*
Department of Medical Imaging, Kaohsiung Medical University Hospital, Kaohsiung, Taiwan

Department of Radiology, Faculty of Medicine, College of Medicine, Kaohsiung Medical University, Kaohsiung, Taiwan

*Corresponding author. Department of Medical Imaging, Kaohsiung Medical University Hospital, Number 100, Tzyou First Road, Kaohsiung 807, Taiwan.
E-mail address: e3124@ms16.hinet.net