



Laparoscopic resection of intra-abdominal metastasis from intracranial hemangiopericytoma

Terry P. Nickerson^a, Aodhnait S. Fahy^a, Juliane Bingener^{b,*}^a Department of Surgery, Mayo Clinic, Rochester, MN, United States^b Department of Surgery and Division of Gastroenterology and Hepatology, Mayo Clinic, Rochester, MN, United States

ARTICLE INFO

Article history:

Received 9 January 2015

Received in revised form 24 July 2015

Accepted 26 July 2015

Available online 31 July 2015

Keywords:

Hemangiopericytoma

Intra-abdominal solid tumor metastasis

Intraperitoneal metastasis

Laparoscopy

Mesenchymal tumor

ABSTRACT

INTRODUCTION: Hemangiopericytoma (HPC) is a rare mesenchymal tumor derived from capillary and postcapillary pericytes that often has an indolent course and occasionally presents with abdominal metastasis.

PRESENTATION OF CASE: Twenty-three years after the initial resection of an intracranial HPC located in the right frontoparietal region and left lateral ventricle, a 63-year-old man experienced dull abdominal pain and early satiety and had a palpable epigastric mass. Computed tomography indicated a suspected metastasis of HPC to the left upper abdomen. On laparoscopic exploration, the tumor was found in the falciform ligament and was excised laparoscopically per request of the patient. He had a fast recovery and experienced good relief of his pain and satiety. The patient had 2 additional metastases at his 12-month follow-up, both in the right retroperitoneum, and he again underwent laparoscopic resection. At his next annual follow-up, new metastases were identified in his liver, small-bowel mesentery, and peritoneal surface, prompting a trial of systemic chemotherapy. Because of progress of a left lower abdominal preperitoneal metastasis on follow-up at 3 years, the patient underwent a further successful laparoscopic exploration. Postoperatively, systemic chemotherapy was maintained.

DISCUSSION: We report the recurrent laparoscopic resection of peritoneal metastases of primary intracranial HPC with good symptom control and fast recovery. Both the patient and the referring physician requested a minimally invasive surgical approach.

CONCLUSION: Laparoscopic resection is a feasible treatment strategy for intraperitoneal metastases and is effective in symptom palliation.

© 2015 The Authors. Published by Elsevier Ltd. on behalf of Surgical Associates Ltd. This is an open access article under the CC BY-NC-ND license (<http://creativecommons.org/licenses/by-nc-nd/4.0/>).

1. Introduction

Originally described in 1942 by Stout and Murray [1], hemangiopericytoma (HPC) is a rare mesenchymal tumor derived from pericytes, the cells of capillary walls and postcapillary venule walls [2]. This tumor type accounts for less than 1% of all sarcomas and can occur at any location in the body, including intra-abdominally [3]. Although most HPC has an indolent course usually, poorly differentiated HPC frequently can have an aggressive tumor biology and a poor prognosis [4–6]. Intracranial HPC is rare, estimated to account for 0.4% of primary intracranial neoplasms; the ideal treatment regimen has yet to be delineated [1,6,7]. Gross total resection

is the only therapy with a proven survival benefit for central nervous system HPC [8–10], though adjuvant radiation therapy leads to longer tumor-free survival [6,11] and multimodal therapy has become the standard of care [12].

Recurrence rates have been reported as high as 42–90%, with time of recurrence at a median of 5 years after initial resection but as late as 27 years [6,9,13]. Extracranial metastases occur in 20% of cases, through both hematogenous and lymphatic routes [6,7,14]. Commonly reported areas of extracranial metastases include bone, liver, lung, and skin [1,6,14].

We report the case of a patient with primary intracranial HPC that metastasized to the peritoneal cavity.

2. Presentation of case

A laparoscopic resection found metastatic HPC in a 63-year-old man. He had received a diagnosis of primary intracranial HPC at age 40 years. Initially, 2 lesions were found: a 3-cm mass in the base

Abbreviations: CT, computed tomography; HPC, hemangiopericytoma; WHO, World Health Organization.

* Corresponding author at: Department of Surgery, Mayo Clinic, 200 First St SW, Rochester, MN 55905, United States. Fax: +1 507 284 5196.

E-mail address: bingenercasey.juliane@mayo.edu (J. Bingener).

<http://dx.doi.org/10.1016/j.ijscr.2015.07.024>

2210-2612/© 2015 The Authors. Published by Elsevier Ltd. on behalf of Surgical Associates Ltd. This is an open access article under the CC BY-NC-ND license (<http://creativecommons.org/licenses/by-nc-nd/4.0/>).

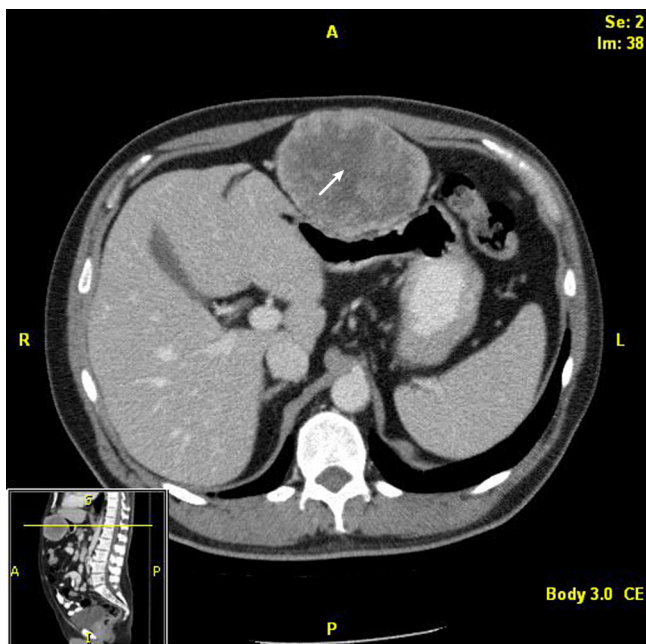


Fig. 1. Computed tomographic scan showing large metastasis in the falciform ligament. The arrow indicates the metastasis.

of the right frontoparietal region and a 1-cm mass in the left lateral ventricle. Pathologic analysis indicated the lesions were World Health Organization (WHO) grade II. Fourteen years after his initial surgery, the patient had a new lesion in the right frontal lobe, which was resected and identified as a WHO grade III recurrent HPC. After this second operation, he underwent adjuvant external beam radiation therapy.

Five years later, a pathologic fracture of his right femur occurred, and imaging showed a likely metastatic HPC. The HPC was treated with surgical resection and fixation, and pathologic evaluation confirmed WHO grade III metastatic HPC. In addition, a metastatic work-up consisting of computed tomography (CT) of the chest, abdomen, and pelvis showed 2 additional intra-abdominal lesions: a 6-cm lesion in the epigastric area and a 2-cm lesion in the right retroperitoneum. At that time, the patient was asymptomatic, and thus, the lesions were observed.

After 4 more years and at 23 years after his initial tumor resection, the patient presented with dull abdominal pain, early satiety, and a palpable epigastric mass. CT showed a considerable increase in size of the epigastric lesion to 10 cm in maximum diameter (Fig. 1). He was taken to the operating room for laparoscopic resection. The tumor was identified in the peritoneal space attached to the falciform ligament. This mass was removed successfully with ultrasonic dissection. The patient did well and was discharged 2 days after the operation without complication.

At his 12-month follow-up, 2 additional asymptomatic lesions were noted on CT. The right retroperitoneal mass had substantially increased in size since previous scans, measuring 10 cm in maximum diameter, and the patient had a new 1-cm metastasis in the retroperitoneal attachments of the hepatic flexure of the right colon (Fig. 2). He again underwent a laparoscopic resection of his tumor recurrences. The smaller mass was removed easily. The right colon then was mobilized, allowing visualization and subsequent dissection of the right retrorenal mass with an ultrasonic dissection (Fig. 3). The patient tolerated the procedure well and

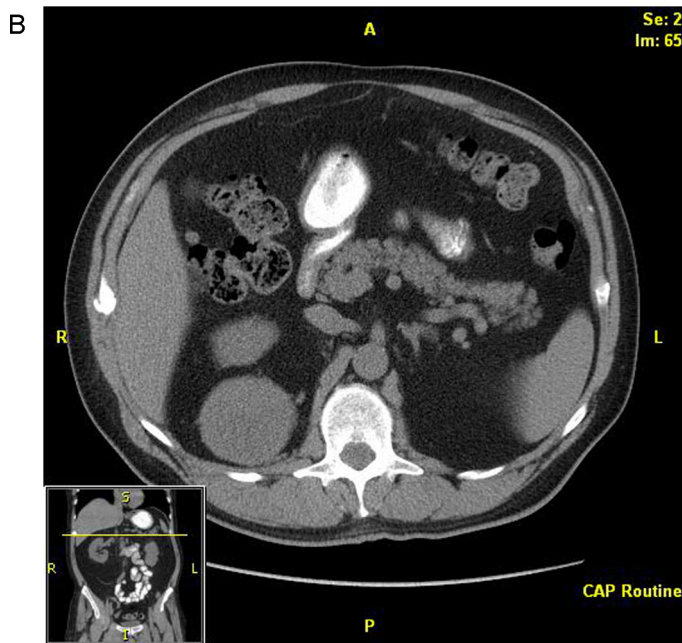
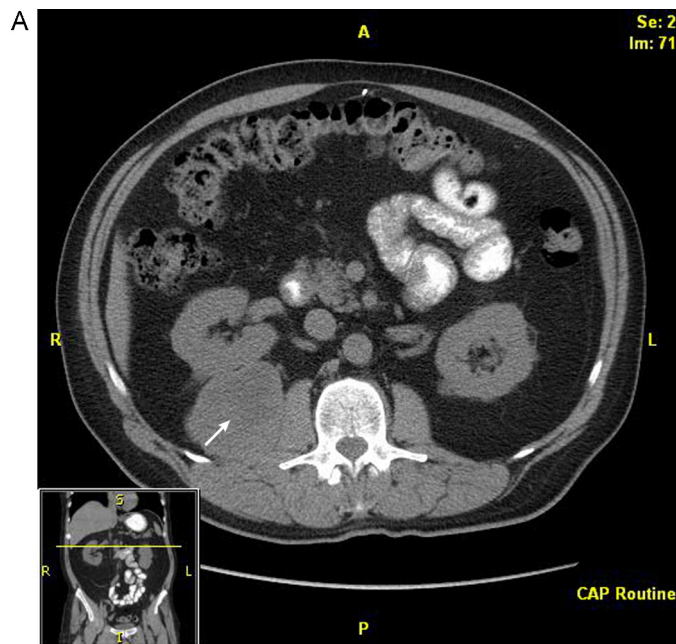


Fig. 2. Computed tomographic scan showing metastases in the (A) right retrorenal retroperitoneum and (B) hepatic flexure attachments of the right colon. The arrow indicates the retrorenal metastasis.

was discharged 3 days after the operation. However, subsequent annual follow-up showed new metastases to the liver, small-bowel mesentery, and several peritoneal nodules on CT (Fig. 4). Given his advanced intra-abdominal disease, the patient underwent a trial of chemotherapy. This treatment was partially successful at slowing his disease; however, 3 years later, left lower abdominal preperitoneal metastases became progressively symptomatic, and the patient underwent further laparoscopic exploration and resection. In this interval, he also had pathologic fractures in the right femur and left humerus secondary to metastatic disease, which were treated by curettage and fixation, as well as an L1 vertebral metastasis that was treated with radioablation and verte-

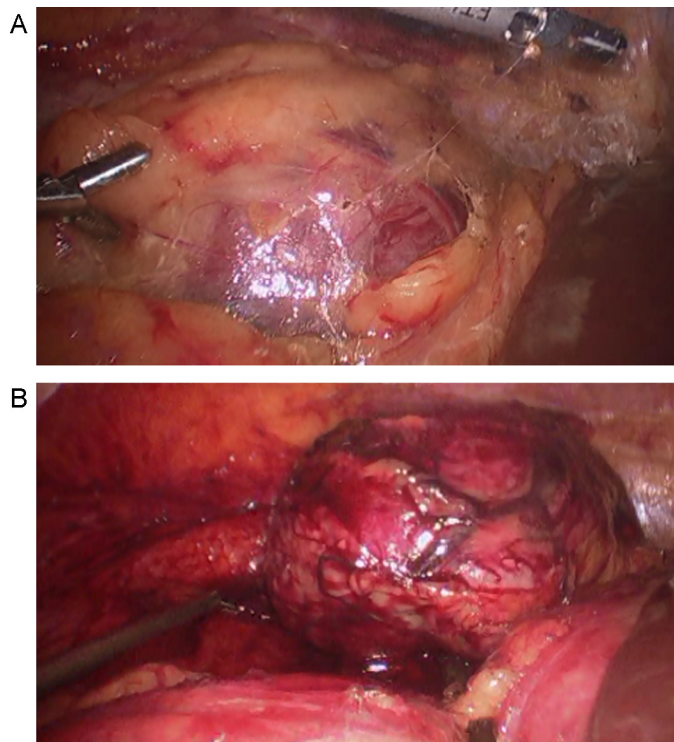


Fig. 3. Laparoscopic resection using ultrasonic dissection. (A) Tumor is visible in tissue. (B) Tumor after it was dissected free.

broplasty. His treatment continued as varying regimens of systemic chemotherapy, including temozolomide, bevacizumab, pazopanib, gemcitabine, and doxorubicin in the intervals.

3. Discussion

Our case report confirms the potentially aggressive nature and metastatic potential of malignant HPC. Late recurrences have been reported in the literature as long as 27 years after the initial surgical resection [2,13]. Little is known about the course of HPC metastatic disease. The current best treatment is surgical resection of all known disease; an optimal management strategy for recurrent and metastatic disease has yet to be fully elucidated [1,12].

The patient in this case presented with local recurrence and delayed bony metastasis, a commonly reported development in HPC. However, he subsequently had additional metastases that presented in a delayed manner and occurred in the peritoneal cavity and retroperitoneum. His peritoneal and retroperitoneal disease was treated using a laparoscopic technique in accordance with the patient’s request, and the benefits of laparoscopic resection can be seen in his uneventful postoperative course.

Though initially resected to negative margins, the patient’s metastatic disease eventually progressed beyond what could be treated surgically.

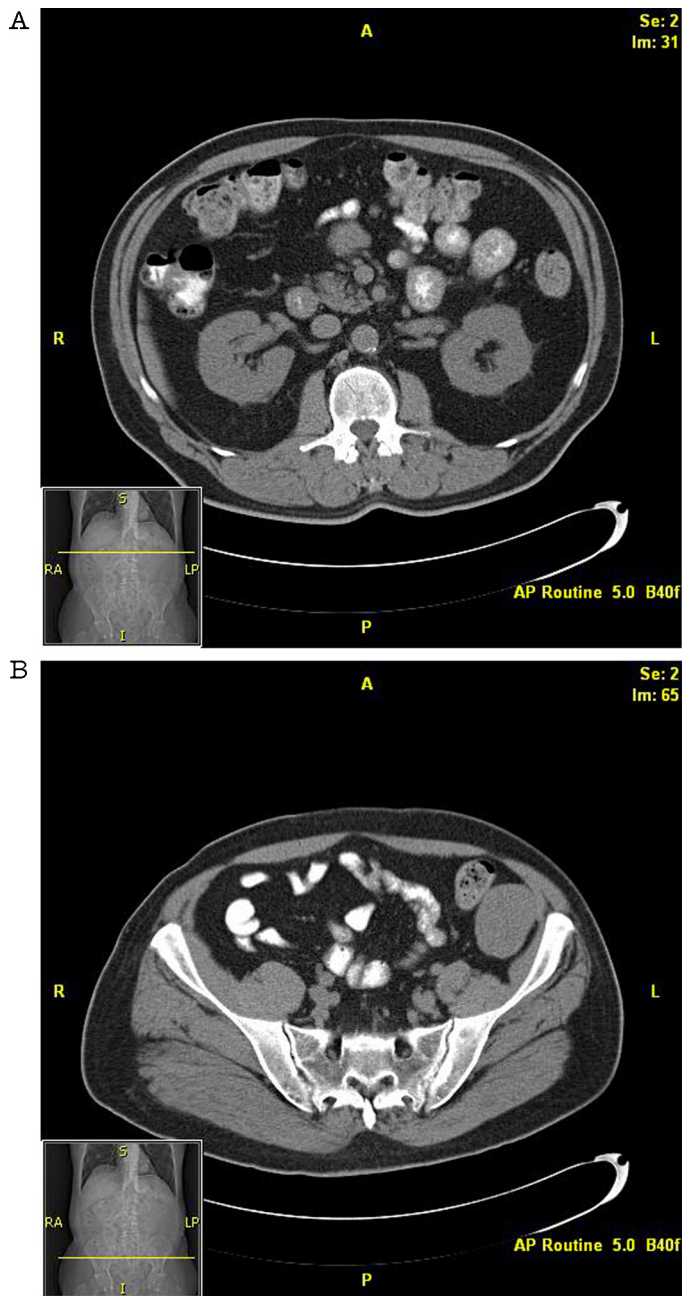


Fig. 4. Computed tomographic scans (A and B) show metastases to small-bowel mesentery.

4. Conclusion

Laparoscopic resection of symptomatic HPC metastases is feasible and effective in relieving symptoms. Repeat resections can be safely performed laparoscopically.

Conflict of interest

The authors have no conflicts of interest to report.

Funding

Dr Bingener’s time in this research was supported in part by NIDDK K23 DK093553. This study had no funding sources. The

investigators' sponsors (for other projects) had no role in collection, analysis, or interpretation of data; the writing of the manuscript; or the decision to submit this manuscript for publication.

Consent

Written informed consent was obtained from the patient for publication of this case report and accompanying images. A copy of the written consent is available for review by the Editor-in-Chief of this journal on request.

References

- [1] A.P. Stout, M.R. Murray, Hemangiopericytoma: a vascular tumor featuring Zimmermann's pericytes, *Ann Surg.* 116 (July (1)) (1942) 26–33.
- [2] M.J. Rutkowski, B.J. Jian, O. Bloch, C. Chen, M.E. Sughrue, T. Tihan, et al., Intracranial hemangiopericytoma: clinical experience and treatment considerations in a modern series of 40 adult patients, *Cancer* 118 (March (6)) (2012) 1628–1636, Epub 2011 Aug 11.
- [3] L.R. Slattery, S.G. Aronson, E.W. Lowman, Hemangiopericytoma review of abdominal cases, *Am. J. Surg.* 91 (June (6)) (1956) 985–990.
- [4] C. Leowardi, U. Hinz, Y. Hormann, M.N. Wentz, G. Mechttersheimer, F. Willeke, et al., Malignant vascular tumors: clinical presentation, surgical therapy, and long-term prognosis, *Ann. Surg. Oncol.* 12 (December (12)) (2005) 1090–1101, Epub 2005 Nov 1.
- [5] A. Wushou, X.C. Miao, Z.M. Shao, Treatment outcome and prognostic factors of head and neck hemangiopericytoma: meta-analysis, *Head Neck* (June) (2014) [Epub ahead of print].
- [6] A.G. Melone, A. D'Elia, F. Santoro, M. Salvati, R. Delfini, G. Cantore, et al., Intracranial hemangiopericytoma: our experience in 30 years: a series of 43 cases and review of the literature, *World Neurosurg.* 81 (March–April (3–4)) (2014) 556–562, Epub 2013 Nov 13.
- [7] O. Damodaran, P. Robbins, N. Knuckey, M. Bynevelt, G. Wong, G. Lee, Primary intracranial haemangiopericytoma: comparison of survival outcomes and metastatic potential in WHO grade II and III variants, *J. Clin. Neurosci.* 21 (August (8)) (2014) 1310–1314, Epub 2014 Apr 13.
- [8] M.J. Rutkowski, M.E. Sughrue, A.J. Kane, D. Aranda, S.A. Mills, I.J. Barani, et al., Predictors of mortality following treatment of intracranial hemangiopericytoma, *J. Neurosurg.* 113 (August (2)) (2010) 333–339.
- [9] C. Leowardi, U. Hinz, Y. Hormann, M.N. Wentz, G. Mechttersheimer, F. Willeke, et al., Malignant vascular tumors: clinical presentation, surgical therapy, and long-term prognosis, *Ann. Surg. Oncol.* 12 (December (12)) (2005) 1090–1101, Epub 2005 Nov 1.
- [10] R. Ramakrishna, R. Rostomily, L. Sekhar, J. Rockhill, M. Ferreira, Hemangiopericytoma: radical resection remains the cornerstone of therapy, *J. Clin. Neurosci.* 21 (April (4)) (2014) 612–615, Epub 2013 Aug 27.
- [11] C. Olson, C.P. Yen, D. Schlesinger, J. Sheehan, Radiosurgery for intracranial hemangiopericytomas: outcomes after initial and repeat gamma knife surgery, *J. Neurosurg.* 112 (January (1)) (2010) 133–139.
- [12] L.F. Chen, Y. Yang, X.G. Yu, Q.P. Gui, B.N. Xu, D.B. Zhou, Multimodal treatment and management strategies for intracranial hemangiopericytoma, *J. Clin. Neurosci.* 22 (April (4)) (2015) 718–725, Epub 2015 Mar 3.
- [13] M. Schiariti, P. Goetz, H. El-Maghraby, J. Tailor, N. Kitchen, Hemangiopericytoma long-term outcome revisited: clinical article, *J. Neurosurg.* 114 (March (3)) (2011) 747–755, Epub 2010 Jul 30.
- [14] N. Kumar, R. Kumar, R. Kapoor, S. Ghoshal, P. Kumar, P.S. Salunke, et al., Intracranial meningeal hemangiopericytoma: 10 years experience of a tertiary care Institute, *Acta Neurochir. (Wien)* 154 (September (9)) (2012) 1647–1651, Epub 2012 Jul 12.

Open Access

This article is published Open Access at sciendoirect.com. It is distributed under the [IJSCR Supplemental terms and conditions](#), which permits unrestricted non commercial use, distribution, and reproduction in any medium, provided the original authors and source are credited.