

Contents lists available at ScienceDirect

Case Reports in Women's Health

journal homepage: www.elsevier.com/locate/crwh

Vaginal evisceration as rare but a serious obstetric complication: A case series



Anadeep Chandi ^{a,*}, Shaveta Jain ^a, Sakshi Yadav ^a, Jaiprakash Gurawalia ^b

^a Department of Obstetric and Gynaecology, Pt. B. D. Sharma, PGIMS, Rohtak, Haryana, India

^b Department of General Surgery, Pt. B. D. Sharma, PGIMS, Rohtak, Haryana, India

ARTICLE INFO

Article history:

Received 20 March 2016

Accepted 17 May 2016

Available online 20 May 2016

Keywords:

Gut prolapse

Vaginal evisceration

Untrained professionals

Surgical abortion

Dilatation and evacuation

ABSTRACT

Introduction: Gut prolapse through vagina is rare complication with only few cases reported in the literature. This article highlights untrained professionals induced obstetrical trauma as a cause of vaginal evisceration leading to serious but preventable complications.

Presentation of Case: Case 1: A 27 years old female, P₂L₀, had full term vaginal delivery of an IUD baby and presented 4 days later with small bowel evisceration through posterior vaginal wall. Case 2: A 24 years old female, P₁A₁ had underwent unsafe abortion and presented in shock, with small bowel evisceration through anterior uterine wall. Case 3: A 26 years female, P₂A₁, underwent evacuation for incomplete abortion and presented with omental prolapse through anterior uterine wall.

Discussion: Obstetrical trauma with associated evisceration of intraabdominal contents is a potentially serious complication that requires surgical intervention. General awareness may decrease these unsafe practices and thus would have impact in reducing maternal morbidity and mortality.

© 2016 Published by Elsevier B.V. This is an open access article under the CC BY-NC-ND license (<http://creativecommons.org/licenses/by-nc-nd/4.0/>).

1. Introduction

Evisceration of abdominal contents through female genital organs is a rare complication worldwide. Inexperienced physicians have been reported to perforate the uterus more frequently than experienced physicians [1]. An illegal abortion by unqualified inexperienced hands (Dai handled) without or with minimal medical knowledge in rural society of developing countries is not uncommon. Complications can endanger the life of mother if proper medical or surgical intervention is not offered in time.

Here, we report three cases of transvaginal evisceration resulting from obstetric trauma each requiring emergency laparotomy, leading to increased maternal morbidity.

1.1. Case Reporting

1.1.1. Case 1

A 27 years old female, with obstetrical score of P₂L₀, with history of delivery of an IUD baby 4 days back, presented to us with complaint of pain lower abdomen for 1 day, diarrhoea for 1 day, and a mass protruding through her vagina since 1 day.

* Corresponding author at: Hno: 957, Sector 25, Panchkula, Haryana Pin code: 134109, India.

E-mail addresses: ana.chandi@gmail.com (A. Chandi), dr_sangwan@yahoo.com (S. Jain), sakshi651@yahoo.com (S. Yadav), jaigurawalia@yahoo.com (J. Gurawalia).

Patient gave history of aggressive fundal pressure being given during the time of delivery, however she denied of any instrumentation being done at the time of delivery.

General physical examination revealed a female with normal built and weight. She was febrile to touch with temperature of 100 °F and had pulse rate of 120 beats/min with blood pressure of 110/64 mm Hg and respiratory rate of 18/min. CNS, CVS and respiratory system examinations were within normal limit.

On per abdomen examination, abdomen was tender, soft distension was present. However bowel sounds were present. All hernial sites were clear.

On local examination

On inspection: about 10 cm of large gut was protruding through the vagina with partially formed stools impacted in it (Fig. 1).

On palpation: multiple perforations were present in the prolapsed portion of the gut. Investigations showed Hb - 10.0 g%, bleeding time (BT) - 2'28", clotting time (CT) - 4'26", with blood group B +, blood urea (BU) - 27 mg/dl, S. Na + -143 meq/dl, S. K + - 4.8 meq/dl and urine tests were normal.

After resuscitation, the patient was taken up for surgery under broad-spectrum antibiotic cover. An infra-umbilical midline incision was given and abdomen was opened in layers.

Intraoperative findings

1. Tear of size 4 cm was present in right posterior-lateral wall of vagina.

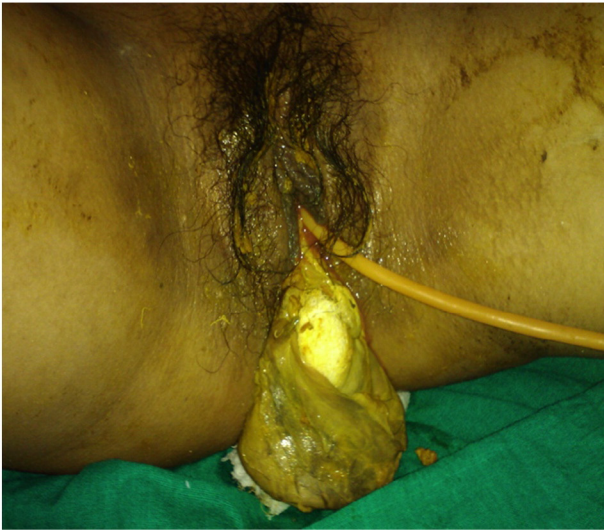

Fig. 1. Large gut about 10 cm with multiple perforations with impacted partially formed stools

2. Prolapse of sigmoid colon through the tear that was perforated and gangrenous.
3. Rest of the gut was healthy.

About 10 cm of the distal part of sigmoid colon was excised. Distal stump was closed and proximal stump was taken out as end colostomy. Vaginal wall tear was stitched with continuous chromic sutures. Peritoneal lavage was done and abdomen was closed in layers. Postoperative period was uneventful and patient was discharged on 9th post-operative day. Colostomy closure was conducted after 6 weeks and the patient was followed up in surgery OPD.

1.1.2. Case 2

A 24 years female with obstetrical score of P1L1A1, came to us on Day 0, with complaint of intestinal loops coming out of vagina after Dai handling following spontaneous incomplete abortion (Fig. 2A). On detailed history, it was revealed that Dai confused the gut loops with placental cord. There was history of fall from bullock cart 2 days back.

On general physical examination, her general condition was poor, pallor was present, she was afebrile to touch, PR - 162/min, BP - 94/46 mm Hg, RR - 24/min. CNS, CVS and respiratory system examinations were within normal limit.

On P/A examination, tenderness was present. Bowel sounds were absent and all hernia sites were clear.

On L/E, small gut along with its omentum was coming out of the introitus (Fig. 2B).

Investigations:

Hb - 6.8 g/dl, BT - 1'20", CT - 3'40", blood group - O +, blood urea - 16 mg/dl, blood sugar - 100 mg/dl, S. Na + - 145 meq/dl, S. K + - 3.5 meq/dl.

Resuscitation was performed, dopamine drip was started and broad spectrum antibiotics were given.

Exploratory laparotomy was done.

Per operative findings (Fig. 2B)

1. A rent of 7 × 3 cm was present in the anterior wall of uterus in the lower uterine segment.
2. Distal ileum about 10 cm was prolapsed through the rent passing through the vagina.
3. Ileocaecal junction disruption was present.
4. Hemoperitoneum of 200 cm³ was present in the peritoneum.

Resection of the 20 cm of ileum and caecum was done and ileo-ascending colon end to end anastomosis was performed. Uterus was repaired with vicryl no. 1 RBN. Peritoneal lavage was done and abdomen was closed in layers. Two units of whole blood and 1 unit of FFP were transfused intraoperatively, 2 units FFP post-operatively. Postoperative period was uneventful and patient was discharged on 6th post operative day.

1.1.3. Case 3

A 26 years old female, P₂L₂A₁, with history of dilatation and evacuation 7 h back for about 3 month of period of gestation, presented to us with complaint of pain lower abdomen and bleeding per vaginum. Patient conceived in lactational amenorrhoea. There was no history of trauma.

General physical examination revealed a female with normal built and weight. She was afebrile to touch and had pulse rate of 92 beats/min with blood pressure of 90/60 mm Hg and respiratory rate of 18/min and pallor was present.

On per abdomen examination: abdomen was soft and uterus corresponded to 14 weeks size.

On per speculum examination: a small vaginal pack was seen and same was removed. Omentum was seen coming out through the os (Fig. 3A).

Investigations:

Hb - 8 g/dl, BT - 1'30", CT - 3'20", blood group - B +, blood urea - 23 mg/dl, blood sugar - 86 mg/dl, S. Na + - 144 meq/dl, S. K + - 3.5 meq/dl.

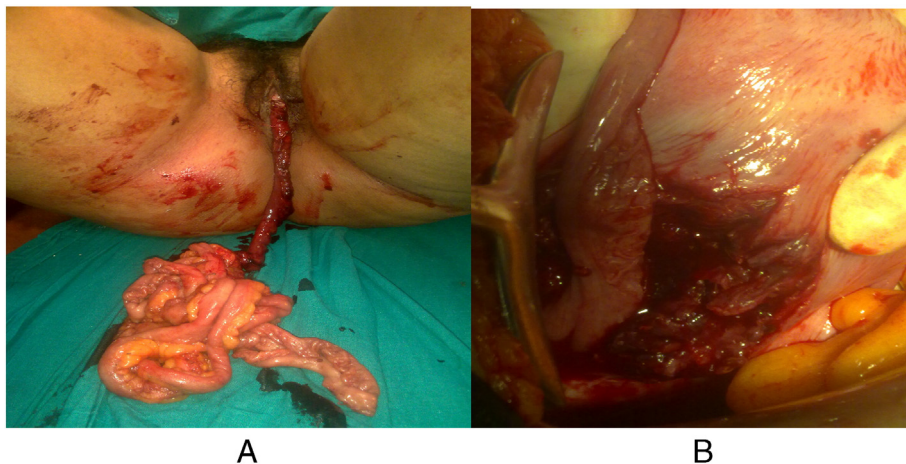


Fig. 2. A: Small gut along with omentum coming out of introitus. B: Showing small gut prolapsing through anterior uterine wall.

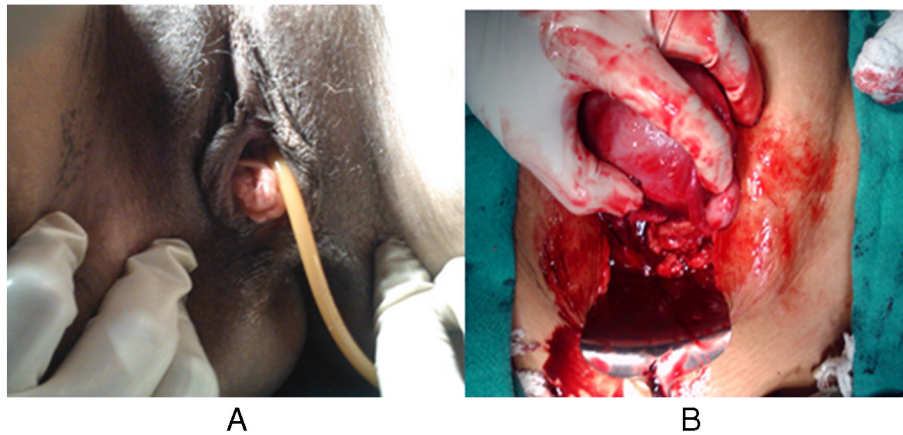


Fig. 3. A: The omentum prolapsing into the vagina. B: A rent in the anterior lower uterine segment.

Resuscitation was done and exploratory laparotomy was performed. Intraoperative findings (Fig. 3B)

1. Hemoperitoneum of 200 cm³.
2. A rent of 5 cm was present in the anterior uterine wall in the lower uterine segment extending to left laterally and downwards to the vagina.
3. Utero-vesical pouch was already breeched, however bladder wall was intact.
4. Fetal skull was removed from UV pouch.
5. B/L tubes and ovaries were normal. Gut and bladder was normal.

The uterine rent was repaired with vicryl no. 1 RBN and peritoneal lavage was done. Postoperative period was uneventful and patient was discharged on 8th post-operative day.

2. Discussion

Incidence of uterine perforation varies from 0.4 to 15 per 1000 abortions as reported by different studies [2]. Majority of them occurs in the hands of untrained and unqualified health professionals. In developing country like India, where the ever-increasing population is out of reach to the specialized health care, only 47% of the deliveries were conducted at institution level (NFHS - 3). More than one-third of births (37%) were assisted by a traditional birth attendant, and 16% were assisted by only friends, relatives, or other [3]. So, it becomes all-important to know and understand the peripheral health care system which provide medical health services at rural level. Traditional birth attendant known and famous as 'Dai' conduct deliveries and abortions at this level. These untrained females are illiterate or if literate are generally up to 10th standard. General public unawareness, poverty, lack of transport facilities and lack of expert health care services, leads to such unsafe obstetric procedures and its related complications leading to increasing incidences of gut evisceration.

Recently, Augustin et al. reviewed the D&C-related bowel injury (not confined to intestinal prolapse). According to them, during the past 50 years, 10 case reports described 12 abortion-related intestinal prolapses. The site of perforation was the uterine fundus (6 cases), posterior (2 cases), fundal anterior (1 case), or not described (3 cases). [4].

Dilatation and evacuation after abortion or delivery can lead to rare but serious surgical complication of gut prolapse through genital tract and requires emergency laparotomy. Vaginal evisceration is a potentially life threatening, rare and distressing complication. It eventually leads to gut injury and gangrene, which requires emergency laparotomy and gut resection. It leads to not only physical debility but also mental disturbance and sense of social discomfort. In our case series, the underlying cause of the evisceration was trauma induced by untrained health

faculties leading to rupture of uterus or vaginal wall. Two of these were preceded by post-abortion evacuation and one followed labour. Exploratory laparotomy was necessary to access the defect, reduce the bowel into the abdomen, and resect any nonviable bowel. Two cases had anterior uterine wall tear in lower uterine segment, however in one case the tear was found at right posterior-lateral wall of vagina. The size of the rent ranged from 4 cm to 7 cm. To date, all the reported cases that have required bowel resection have been managed with exploratory laparotomy followed by repair of the uterine/vaginal defect [5].

In developing countries like India, where still a large number of obstetrical care is provided by local untrained personnel, strong measures should be taken to bring awareness among general public so that they seek medical care from trained medical faculty. General awareness and education, with promotion of institutional delivery and managing abortion procedures in safe hands can decrease its incidence. Peripheral health workers should be trained in conducting safe deliveries and abortions. Time to time training programs should be organized, to make them identify high risk and difficult cases. A proper and strong referral system should be established to timely refer such complicated and difficult cases to higher centers. This will not only reduce maternal morbidity and mortality but also decrease burden on the economy of the country.

Disclosure Statement

This study does not violate the policies and/or procedures established by journal and do not have any conflict of interest.

Acknowledgement

All the authors have contributed into the study and approved this manuscript. Chandi A collected the patient's details and framed the manuscript. Jain S, Gurawalia J and Chandi A were the surgeons who operated the case. Yadav S collected the reference details and edited the manuscript.

References

- [1] Grimes DA, Schulz KF, Cates WJ. Prevention of uterine perforation during curettage abortion. *JAMA* 1984;251(16):2108–11.
- [2] Nathan BN. Management of uterine perforations suffered at elective abortion. *Am J Obstet Gynecol* 1972;114(8):1054–9.
- [3] NATIONAL. Family health survey (nfhs-3) India. http://rchiips.org/nfhs/NFHS-3%20Data/VOL-1/India_volume_1_corrected_17oct08.pdf; 2005-06.
- [4] Augustin G, Majerovic M, Luetić T. Uterine perforation as a complication of surgical abortion causing small bowel obstruction: a review. *Arch Gynecol Obstet* 2013; 288(2):311–23.
- [5] Ho PW, Lee CW. Transvaginal small bowel evisceration and strangulation. *ANZ J Surg* 2008;78:726–7.