



CONTINUING EDUCATION PROGRAM: FOCUS...

Imaging in lower urinary tract infections

A. Schull^{a,*}, Q. Monzani^a, L. Bour^a,
N. Barry-Delongchamps^b, F. Beuvon^c, P. Legmann^a,
F. Cornud^a

^a Radiology Department, Paris Centre University Hospitals, site Cochin, 27, rue du Faubourg Saint-Jacques, 75014 Paris, France

^b Urology Department, Paris Centre University Hospitals, site Cochin, 27, rue du Faubourg Saint-Jacques, 75014 Paris, France

^c Pathological Anatomy Department, Paris Centre University Hospitals, site Cochin, 27, rue du Faubourg Saint-Jacques 75014 Paris, France

KEYWORDS

Male genital system;
Infection;
Prostate;
Bladder;
Testes

Abstract In epididymo-orchitis, a sonogram shows a non-homogenous and hypertrophied epididymis and testis, with increased vascularisation seen on a Doppler sonogram. Abscesses must be investigated using sonography so that a necrotic tumour is not misdiagnosed. In prostatitis, sonography is indicated to investigate urine retention and where treatment has failed (to look for a blockage, an abscess, or pyelonephritis). Endorectal sonography is the best imaging modality for analysing the parenchyma, but otherwise has limited value. Chronic prostatitis is the main differential diagnosis from prostate cancer; the two may be distinguished using diffusion MRI. In cases of cystitis, imaging is indicated when a patient has recurrent cystitis (to investigate what the causative factors might be), or an infection with a less common bacterium (to look for calcifications, emphysema, any involvement of the upper urinary tract), and in cases of cystitis with pseudotumour.

© 2012 Éditions françaises de radiologie. Published by Elsevier Masson SAS. All rights reserved.

Epididymo-orchitis

General points

Epididymo-orchitis is an inflammation of the testis and epididymis, either at the same time or separately. There are three possible routes of contamination [1]:

* Corresponding author.

E-mail address: alexschull@yahoo.com (A. Schull).

- the most common by far is infection via the urethra: the infection spreads from the urethra to the tubes of the epididymis during venereal or urine infections, or when the patient has a urinary catheter in situ. This explains the risk of simultaneous infection of the whole genital tract and this should routinely be investigated by physical examination or while history taking;
- it is possible for infection to spread directly from an adjacent organ, and the starting point for investigation should be the prostate or seminal vesicles;
- haematogenous infection is much less common.

Three types of causal agent can be distinguished:

- in young patients and children, the predominant causes are sexually transmitted bacteria (gonococcus, chlamydiae, mycoplasma) and the mumps virus;
- in adults and older patients, the bacteria responsible are the same as in other urine infections: *Escherichia coli* in community-acquired infections, while a wider range of bacteria are implicated in nosocomial infections;
- much more rarely, the bacterium responsible is *Mycobacterium tuberculosis* or brucella.

Clinically, signs of infection are combined with scrotal pain relieved by suspending the scrotum and local signs varying in intensity.

Among the possible complications are abscess of the epididymis or testis, ischaemia, purulent discharge from the testis and secondary infertility.

The main differential diagnostic is acute torsion, but the circumstances of onset and the increased pain on suspension generally allow clinicians to come to the correct diagnosis. A testicular tumour undergoing necrosis can also mimic epididymo-orchitis.

Imaging [2,3]

Doppler sonography is routinely carried out where there is clinical suspicion of epididymo-orchitis. The aim is both to confirm the diagnosis and to eliminate differential diagnoses (torsion, necrotic tumour) and complications (abscess, vascular abnormality). Cases of epididymo-orchitis caused by particular bacteria can have a specific appearance, meaning that the diagnosis can move towards pinpointing the agent causing the infection. Signs on sonography may involve the epididymis, the testis, or both.

Orchitis

Less commonly, only the testis is affected and the infection usually spreads to the whole of the testicular parenchyma. In B-mode sonography the testis appears hypertrophied and protruding. It is usually homogenous and hypoechoic on early phase studies but quickly becomes non-homogenous (Fig. 1). On Doppler sonography hyperaemia can be seen in the affected testis (Fig. 2). Resistance indices can be compared to those of the healthy side for a more objective evaluation, but this is rarely necessary in practice.

Epididymitis

On B-mode sonography the epididymis is enlarged, and this may affect the whole structure or be localised. This increase in size can be quantified: if the diameter of the epididymal

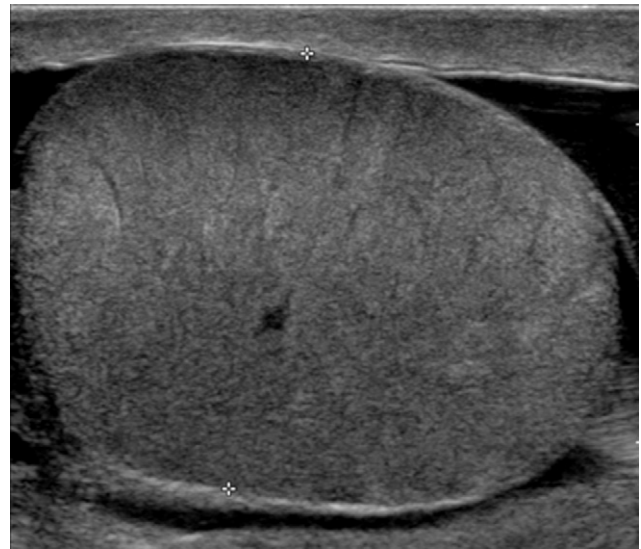


Figure 1. Epididymo-orchitis. B-mode sonography: hypertrophied testis with homogenous parenchyma, fine striations.

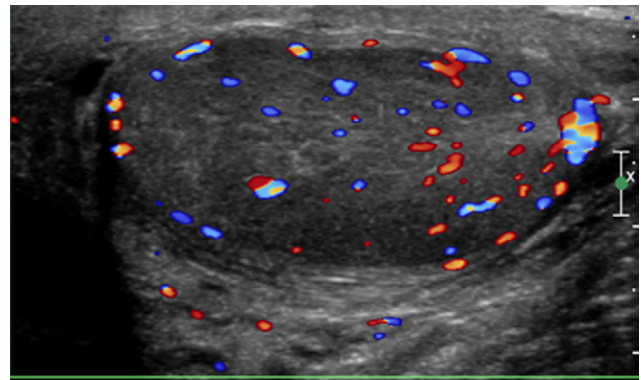


Figure 2. Epididymo-orchitis. Colour Doppler sonography: hyperaemia throughout the testicular parenchyma.

head exceeds 1 cm, then the diameter of the tail exceeds 6 mm (Fig. 3). The simple presence of enlargement compared to the healthy side is, however, the most reliable parameter and it is usually superfluous to take measurements. The echogenicity of the epididymis is highly variable. On power Doppler, frank hypervascularisation of the epididymal parenchyma and spermatic cord can be seen in comparison with the opposite side (Fig. 4). It is not necessary to measure resistance indices.

Associated signs

A hydrocele of variable volume is often present and it is generally anechoic. When it contains septations or internal echoes, this means that the hydrocele is infected. In this case it can also be termed a pyocele (Fig. 5). Other signs are often present: cord oedema and thickening of the membranes.

Differential diagnosis

Distinguishing between orchitis and an infiltrating tumour is essential when the clinical picture is atypical. In contrast to tumour infiltration, in the acute phase of epididymo-orchitis

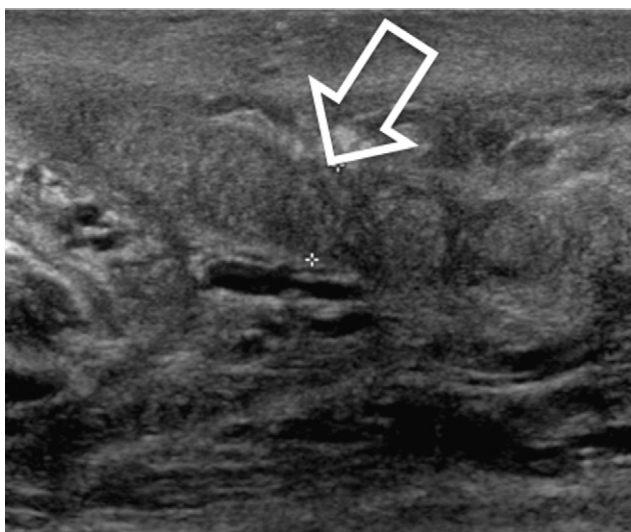


Figure 3. Epididymitis. B-mode sonography: thickening of the body of the epididymis (arrow).

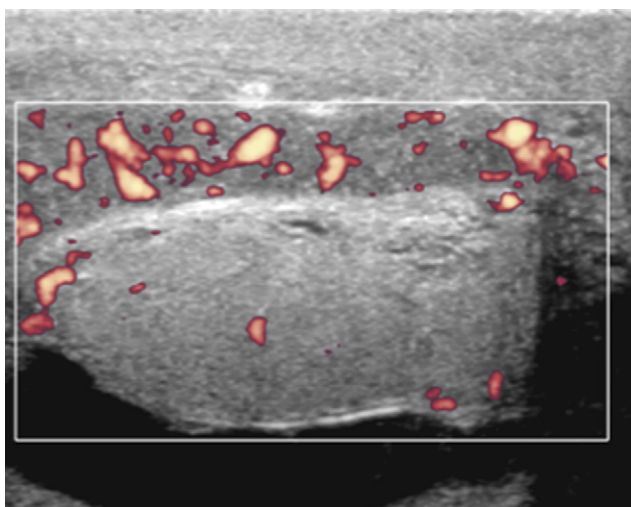


Figure 4. Epididymitis. Power Doppler sonography: isolated hyperaemia in the epididymis and the testicular parenchyma presents normal vascularisation.

the edges of the testis remain distinct and the echostructure of the parenchyma is non-homogenous, but it remains undisturbed overall. Calcifications are not present, and any hypertrophied vessels do not deviate from their usual trajectory. If there is the slightest doubt, soonest sonogram monitoring is indicated.

Complications

An abscess can be recognised easily, as it appears as a strictly avascular mass that is highly hypoechoic, and may contain fine sloping echoes; a thick and hypervascular capsule may be seen (Fig. 6). Sonography must be used to investigate an abscess in order to ensure that it is not a misdiagnosed underlying tumour undergoing necrosis. Infarction of testicular veins secondary to epididymitis can mimic orchitis in its initial stage, appearing as testicular hypertrophy combined with moderately increased vascularisation. In

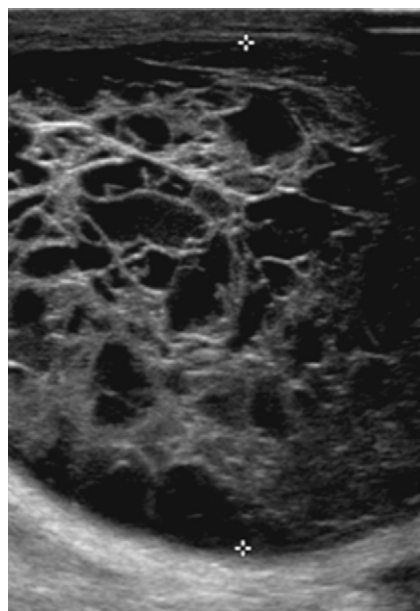


Figure 5. Pyocele. B-mode sonography: multiple septations within the hydrocele pointing to infection.

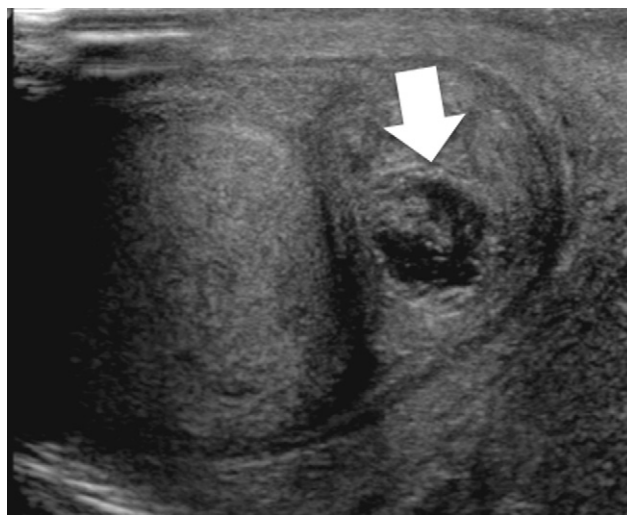


Figure 6. Abscess of the tail of the epididymis. B-mode sonography: highly hypoechoic collection with internal echoes (arrow).

later stages, the testis seems to be totally avascular, while the epididymis is hypervascular. It is possible to confuse this picture with testicular torsion, but this would not have any major consequences in practice because the ischaemic process of a venous infarct is not reversible and the treatment is the same as it is for torsion. Purulent discharge from the testis is secondary to total devascularisation of the testicular parenchyma. Sonography findings can give rise to confusion with torsion, but the absence of spiralling vascular structures in a hypervascular and hypertrophied spermatic cord, together with the clinical history, should enable clinicians to make the correct diagnosis.

Bacterial variations

When tuberculosis is involved [4,5], there are several specific characteristics that point to this diagnosis: onset begins

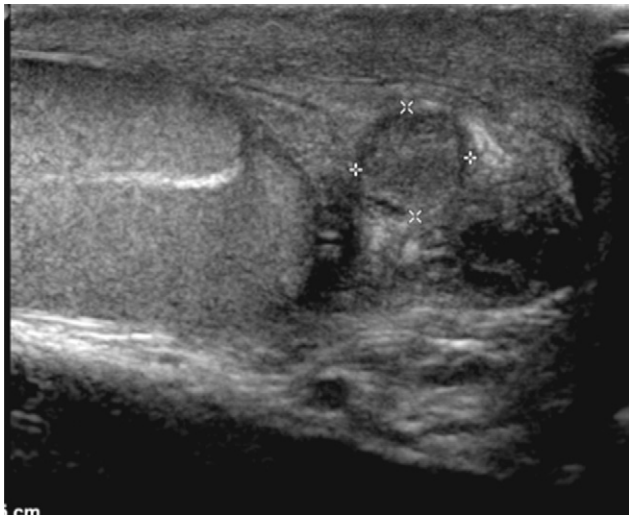

Figure 7. Tuberculous epididymitis. B-mode sonography: nodule of the tail of the epididymis.

readily in the tail of the epididymis and subsequently reaches the epididymal body. Testicular involvement may take the form of a single tuberculoma nodule, or it may be more widespread throughout the testis in ‘‘miliary tuberculosis’’ (Fig. 7). Its progression is subacute and the presence of a fistula to the skin is highly suggestive of this diagnosis (Fig. 8). There are no particular findings on sonography that are suggestive of brucellosis infection.

Follow-up

There is no indication for repeat sonography except in cases that do not respond or only partly respond to the correct medical treatment. In these cases, imaging could investigate whether there are local complications, or perhaps eliminate a testicular tumour where doubt persisted after the initial sonogram. Testicular atrophy can be a sequela of orchitis and this may appear with conserved non-homogeneity, with the presence of striated bands or areas appearing like contours on a map. A non-homogenous nodule may be mistaken for a tumour but this confusion can be avoided by using a colour Doppler scan, which will show an absence of vascularisation in these sequellar nodules.

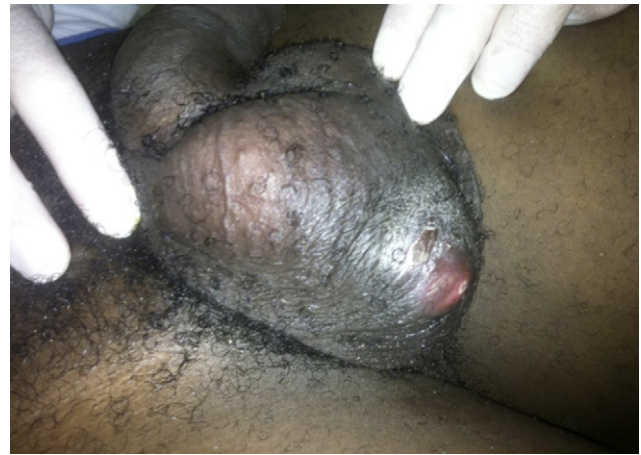


Figure 8. Tuberculous epididymitis. Scrotal fistula (same patient as fig. 7).

Prostatitis

Prostatitis has a prevalence of 9% across the adult male population. However, there are different types, depending on whether it is acute, chronic or even asymptomatic. The route of contamination is usually ascending. The National Institute of Health [6] classification is the most widely used and it distinguishes between four categories of prostatitis (Table 1).

Bacterial prostatitis (types I and II) only accounts for 5 to 10% of all cases of prostatitis.

Acute bacterial prostatitis

Clinical signs

Faced with the clinical picture of a urine infection and fever in men, the diagnosis of acute prostatitis should be the first to suggest itself. Rectal examination is painful and there are signs of irritation, but diagnosis may be less obvious in atypical forms with signs of infection or isolated pelvic pain. The first-line investigation should be urinalysis, which is nearly always positive: in 80% of cases for *E. coli*, and the next most common finding is other enterobacteriaceae.

Table 1 National Institute of Health classification and definition of the categories of prostatitis.

Category	Definition	Description
I	Acute bacterial prostatitis	Acute prostate infection
II	Chronic bacterial prostatitis	Recurrent prostate infection
III	Chronic non-bacterial prostatitis	Inflammatory (IIIa) Leukocytes present in prostatic secretions, in postprostate massage urine or in semen
		Non-inflammatory (IIIb) Absence of leukocytes prostatic secretions, in postprostate massage urine or in semen
IV	Asymptomatic inflammatory prostatitis	Diagnosed during prostate biopsy or due to leukocytes present in semen

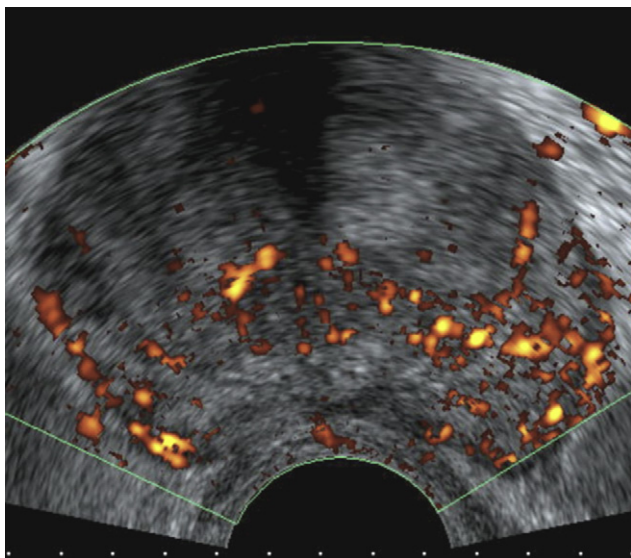


Figure 9. Acute prostatitis. Endorectal power Doppler sonogram of the prostate (examination not indicated in the first 24 hours or in patients who respond well to treatment): hypervascular focal point in the left posterior peripheral zone.

Imaging

The only imaging examination that should routinely be carried out in the first 24 hours is measuring post-void urinary residue, whether by sonography or by using equipment specifically for that purpose (Bladder-Scan). If the amount is significant, urinary drainage via a suprapubic catheter is indicated.

True radiological investigations are only indicated where there is suspicion of possible pyelonephritis or in persistent cases, or indeed in patients who deteriorate and develop sepsis within 72 hours, to investigate possible complications.

Some authors recommend that suprapubic pelvic sonography should be carried out in view of the pain that patients present and the risk of bacteraemia [7]. In 80% of cases, this would allow detection of one or several abnormalities: increased size, enlarged venous plexus, hypoechoic site of inflammation with focal or diffuse increased vascularisation visualised on Doppler scanning (Fig. 9). However, the real aim of sonography is to check whether there is a prostatic abscess: this is visualised as a non-homogenous and moderately hypoechoic rounded lesion, with septations and thick walls, and with increased vascularisation on Doppler

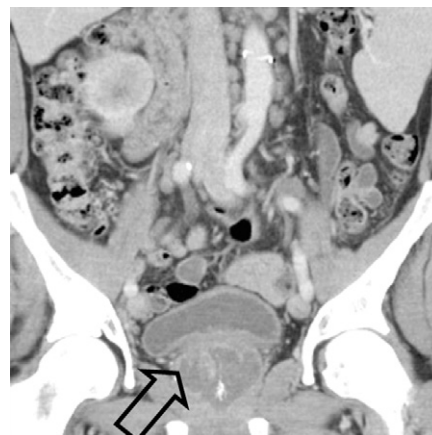

Figure 10. Prostate abscess. Contrast-enhanced CT scan, coronal view: intraprostatic collection (arrow) with no sign of perineal diffusion.

scanning, although the centre is avascular. It is then also possible to puncture and drain the abscess under transperineal or transrectal ultrasound-guidance. An examination of the whole genitourinary system is indicated in order to check for signs of orchitis, epididymitis or complicated pyelonephritis. A computed tomography (CT) or MRI scan can be carried out in order to define the borders of the abscess (Fig. 10), to eliminate spread of the infection to the perineum or pelvis, to look for causative factors, and to choose the appropriate surgical drainage technique.

Chronic prostatitis [8]

Clinical signs

Patients with chronic prostatitis present a wide range of symptoms of which perineal pain, signs of urinary obstruction and difficulties ejaculating are the most commonly reported. Rectal examination is usually normal. Sperm, prostate secretions and urine can all be used to check for the presence of leukocytes and to identify the bacterium. PSA is usually raised or fluctuating and it should be checked after treatment with antibiotics, in order to ensure that an underlying cancer has not been misdiagnosed.

Imaging

Sonography may be normal and reveal totally non-specific abnormalities, which may be seen in the absence of

Table 2 Typical MRI findings in prostatitis and prostate carcinoma.

	Prostatitis	Carcinoma
T2-weighted sequence	Low signal intensity in striated bands, not nodular, readily diffuse, with no capsule abnormalities	Focal or growing nodular lesion, able to deform the contours of the gland or invade the capsule
T1-weighted sequence with contrast injection	Enhancement of variable intensity, in a plateauing or progressive pattern Gadolinium has pseudotumoural kinetics	Enhancement with a significant trough and peak, washout exceeding 20%
Diffusion	Little or no restriction	Restriction, high signal intensity persisting on high gradients

symptoms: numerous calcifications often accumulate in the posterolateral regions of the peripheral prostate; increased vascularisation is not detectable on current sonography equipment; the echostructure of the prostatic parenchyma is non-homogenous, alternating between non-systematised hyperechoic strips and hypoechoic zones that sometimes contain pseudonodules and dilated ducts [9]. Faced with a hypoechoic strip in the peripheral zone, differential diagnosis from an underlying neoplasm is impossible and an ultrasound-guided biopsy is required depending on the context. MRI is not indicated for the positive diagnosis of chronic prostatitis, but when it is used to guide a prostate biopsy in a patient with raised PSA levels or to assess disease spread in a known cancer, it usually allows cancer to be distinguished from chronic prostatitis (Table 2).

Specific forms

Tuberculous prostatitis usually develops following an upper urinary tract infection. The most commonly reported signs are cystic dilation of the ducts, secondary to stenosis of the ejaculatory ducts, and these can meet with the urethra taking on an appearance of cavitation. It is generally combined with macro calcifications [4,5,10]. Granulomatous prostatitis may be seen after BCG therapy to treat a vesical neoplasm, and also out of this context: these cases are referred to as "non-specific". Sonography demonstrates single or multiple hypoechoic nodules, localised to the peripheral zone. However, this imaging presentation is still not specific, as it could also be suggestive of neoplasm and so biopsy is required.

Cystitis [11]

Infectious cystitis may be caused by a bacterium, a parasite, or mycosis. It can be isolated or combined with involvement of the whole urinary system or adjacent organs.

Acute generalised non-specific cystitis

General points

Acute bacterial cystitis is an infection that is mainly caused by *E. coli* although other bacteria can be responsible, usually enterobacteriaceae (*Enterobacter*, *Proteus mirabilis*, *Streptococcus*, *Klebsiella*, etc.). Infection is usually via the ascending route but it can, in a small number of cases, be descending, haematogenous, or contiguous.

In young women, faecal bacteria colonise the vulva and then are able to reach the bladder via the urethra, since it is short in length. In men, cystitis is much less common because the urethra is longer. The clinical signs of bacterial cystitis include a combination of suprapubic pain, dysuria and a burning sensation on urination. The presence of fever must lead the clinician to suspect an upper urinary tract infection. Leukocytes and bacteria are present in the urine and can be shown using a urine dipstick.

Imaging

There are no examinations indicated in simple cases of acute community-acquired cystitis. Radiological exploration

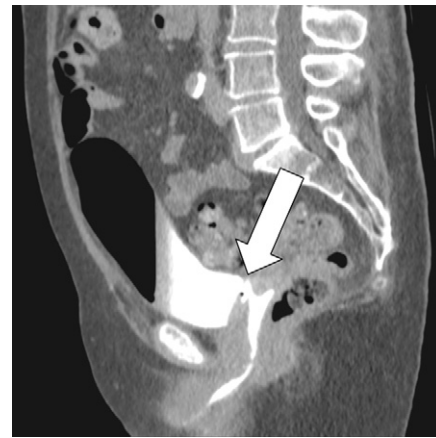

Figure 11. Vesicovaginal fistula. Contrast-enhanced CT scan, delayed phase acquisition: passage made visible due to the intravaginal presence of the contrast medium (arrow).

of cystitis is indicated in male patients and to check for complications or causative factors. Sonography findings are unreliable:

- fine nodule-shaped echoes within the bladder are visible, corresponding to pyuria, but this finding can also be seen with haematuria or totally asymptomatic raised protein levels in the urine;
- overall thickening of the bladder wall is only visible at the later stage; sometimes focal, protruding pseudotumours are reported.

If the patient deteriorates, CT may be indicated to investigate whether the upper urinary tract is affected or whether there is a pelvic abscess. Radiological investigation of recurrent cystitis is indicated using sonography, or better still by CT urography, to check for bladder diverticula, a tumour, or a foreign body. A delayed phase acquisition must then be included to check for fistulae between the bladder and gastrointestinal or genital system (Fig. 11). Pneumaturia must lead to suspicion of acute emphysematous cystitis, especially in diabetic patients with bladder neuropathy [12].

Urinary bilharziasis [13]

General points

This is the most common parasitic infection throughout the world. The disease is endemic, principally to sub-Saharan Africa. It is caused by *Schistosoma haematobium*. Humans are the definitive host in the parasite's life cycle. The infection enters through the skin and subsequently, after passing through the lungs, the systemic circulation, and the portal venous system, the parasite reaches the bladder. The parasite produces a large number of ova into the urine. These ova are either eliminated or they remain embedded in the bladder mucosa where they die, producing a granulomatous reaction with secondary calcification.

In the majority of cases the calcifications only affect the bladder mucosa, but in the most serious cases they reach the muscularis and the tunica adventitia, which leads to fibrosis of the whole bladder, causing bladder deformity and retraction. If several granulomas merge this can cause a bilharzioma, which takes on the appearance of a

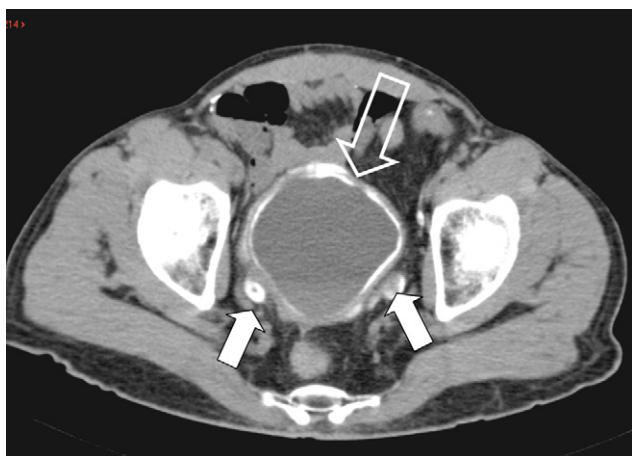


Figure 12. Bilharziasis. Axial view CT scan without injection of contrast medium: calcifications of the entire bladder urothelium (arrow outline) and of the distal portion of two ureters (solid arrows).

pseudotumour. Lesions are predominantly present in the vesical triangle, the posterior surface of the bladder and around the bladder neck. Secondary to these, in later stages of the disease, the distal ureters may be affected; kidney involvement comes later, secondary to vesico-ureteric reflux or to episodes of ascending pyelonephritis. Urinary bilharziasis causes a specific histologic form of bladder cancer, squamous cell carcinoma.

Imaging [14]

Bladder calcifications are visible on plain film radiography in 30 to 50% of cases. They are situated in the base of the bladder, usually running continuously and parallel to the upper edge of the pubic symphysis. They may involve the whole of the bladder in later stage disease, in which it is not uncommon to visualise ureteric calcifications. When intravenous urography is carried out it highlights irregularities of the walls and filling defects. In a still later stage, the bladder is of decreased volume, and deformed or rounded. Signs of a hypertonic bladder are possible. When the pelvic ureters are affected, the intramural

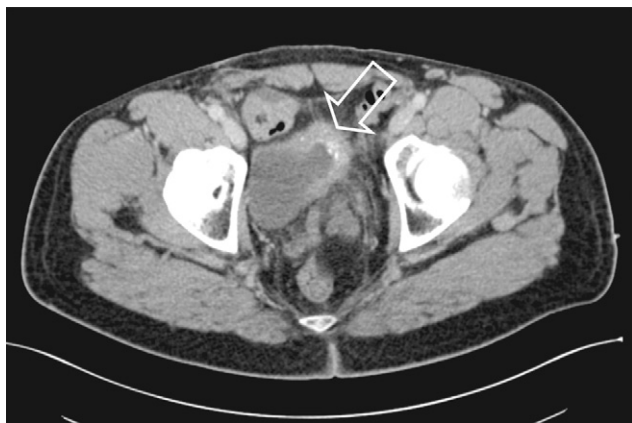

Figure 13. Urinary bilharziasis. Axial view contrast-enhanced CT scan: retraction, thickening and calcifications of the anterior wall of the bladder (arrow).

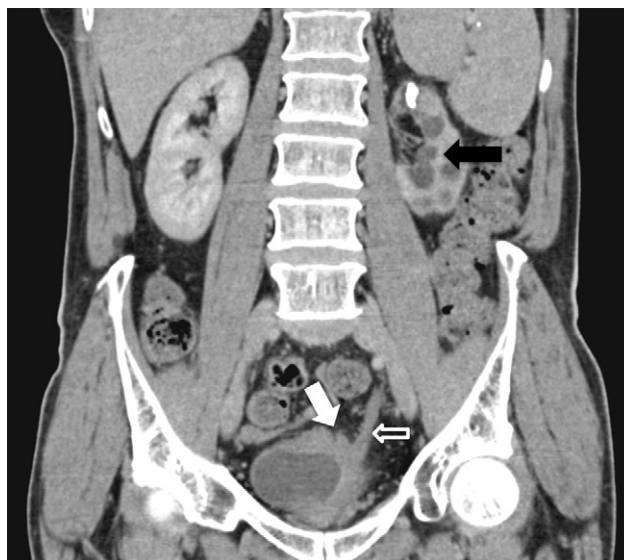


Figure 14. Urinary tuberculosis. Oblique coronal view contrast-enhanced CT scan: the bladder wall is thickened, calcified and retracted (white arrow), there is dilation of the ureter (arrow outline) and sequellar changes to the renal parenchyma, with calyx stenosis and calcification of the parenchyma (black arrow).

or supravvesical part of the ureter maybe stenosed, or they may be the site of reflux and also filling defects. Sonography demonstrates thickening of the bladder wall, which may be widespread, although it can be focal in the case of bilharzioma, and this takes on the appearance of a pseudotumoural mass [15]; this thickening predominates in the vesical triangle. CT scanning is the investigation of choice: it detects calcifications of the bladder wall without missing the mucosa, assesses involvement of the upper urinary tract (Fig. 12), demonstrates deformities (Fig. 13), and can investigate whether a cancer is developing.

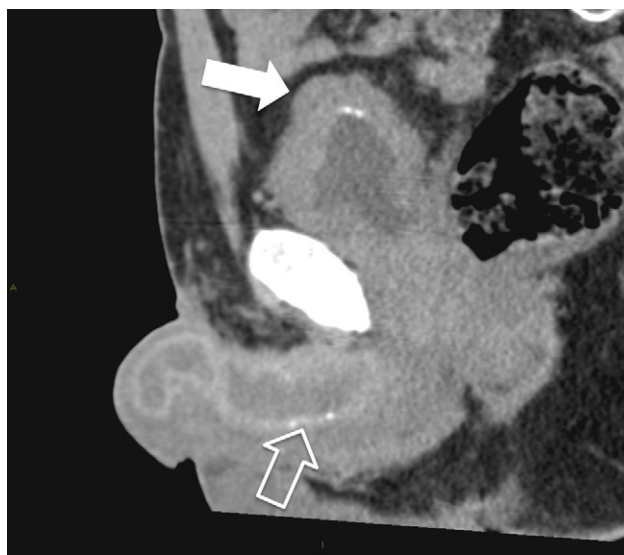


Figure 15. Tuberculosis. Sagittal view CT scan without injection of contrast medium: calcifications of the bladder (solid arrow) and the corpus cavernosum penis (arrow outline).

Tuberculous cystitis [4,5,10]

In urinary tuberculosis, the bladder is normally affected in later stage disease after involvement of the kidneys and via the descending route. An oedema of the mucosa is seen followed by thickening of the bladder wall, and a reduction in bladder volume predisposing the patient to vesico-ureteric reflux. At a still later stage, calcifications affect the walls: they generally spare the bladder mucosa, are mass-like and systematically combined with calcifications of the kidneys (Fig. 14), ureters and genital tracts (Fig. 15).

TAKE-HOME MESSAGES

- Doppler sonography of the scrotum is routine in epididymo-orchitis. It can investigate whether there are complications (abscess, ischaemia) and, in clinically atypical forms, it allows differential diagnosis from testicular cancer to be made. An abscess must be investigated using sonography, in order to ensure that it is not a misdiagnosed underlying necrotic tumour.
- Imaging is indicated in treatment-resistant prostatitis, in order to investigate whether there is an obstruction, an abscess or pyelonephritis.
- Chronic prostatitis can mimic cancer; the two may be distinguished using diffusion MRI (diffusion is restricted in carcinomas).
- Imaging is indicated in recurrent cystitis to look for causative factors, in cystitis caused by less common bacteria, in order to look for calcifications, emphysema and involvement of the upper urinary tract.

Clinical case study

A 29-year-old male of Sub-Saharan origin complained of pain and a scrotal tumefaction of subacute progression. He was afebrile. His urinalysis was negative.

Here is his sonogram (Figs. 16 and 17).

Questions

1. Count the symptomatological abnormalities on this sonogram.
2. What other signs on the sonogram would you look for locally?
3. Clinically there is a fistula to the right scrotal skin. What diagnosis would you propose?
4. What signs of this condition do you know of at the stage of bladder involvement?

Answers

1. Hypertrophy of the epididymis, predominating in the tail, with increased vascularisation on Doppler sonography; hydrocele; no nodule, no abnormality of the testis or tunicas.

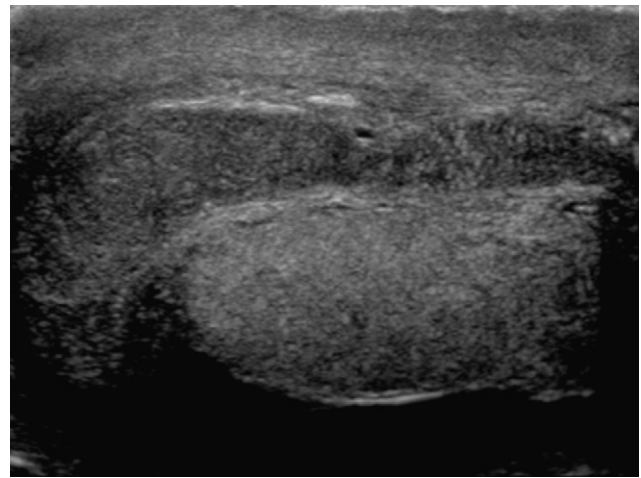


Figure 16. B-mode sonogram view along the axis of the right epididymis, passing through the tail.

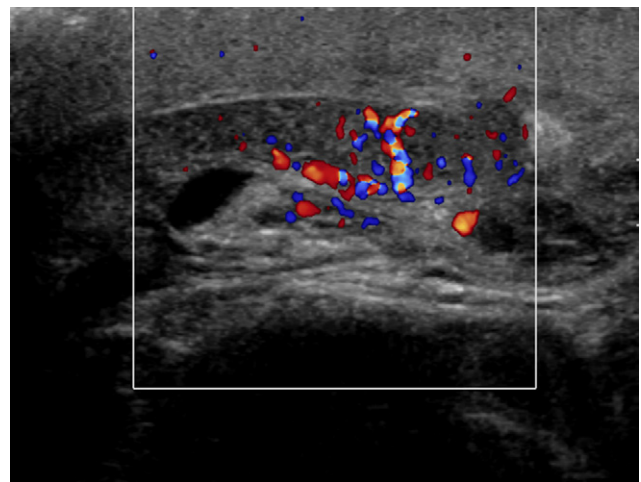


Figure 17. Colour Doppler sonogram along the axis of the right epididymis.

2. Eliminate the differential diagnoses: torsion, necrotic tumour. Investigate the possible complications: abscess, vascular abnormality.
3. Tuberculous epididymitis.
4. Wall thickening; calcifications of the walls sparing the mucosa; vesico-ureteric reflux.

Disclosure of interest

The authors declare that they have no conflicts of interest concerning this article.

References

- [1] Pilly E. Pilly 2008. Vivactis Plus; 2007.
- [2] Pavlica P, Barozzi L. Imaging of the acute scrotum. *Eur Radiol* 2001;11(2):220–8.
- [3] Farriol VG, Comella XP, Agromayor EG, Crèixams XS, Martínez de la Torre IB. Gray-scale and power Doppler sonographic

- appearances of acute inflammatory diseases of the scrotum. *J Clin Ultrasound* 2000;28(2):67–72.
- [4] Matos MJ, Bacelar MT, Pinto P, Ramos I. Genitourinary tuberculosis. *Eur J Radiol* 2005;55(2):181–7.
- [5] Jung YY, Kim JK, Cho K-S. Genitourinary tuberculosis: comprehensive cross-sectional imaging. *AJR Am J Roentgenol* 2005;184(1):143–50.
- [6] Krieger JN, Nyberg L, Nickel JC. NIH consensus definition and classification of prostatitis. *JAMA* 1999;282(3):236–7.
- [7] Roy C. *Imagerie de la prostate*. Paris: Elsevier Masson; 2005.
- [8] Cornud F. *Imagerie de la prostate*. Paris: Sauramps Médical; 2004.
- [9] Ludwig M, Weidner W, Schroeder-Printzen I, Zimmermann O, Ringert Rh. Transrectal prostatic sonography as a useful diagnostic means for patients with chronic prostatitis or prostatodynia. *BJU* 1994;73(6):664–8.
- [10] Wang LJ, Wu CF, Wong YC, Chuang CK, Chu SH, Chen CJ. Imaging findings of urinary tuberculosis on excretory urography and computerized tomography. *J Urol* 2003;169(2):524–8.
- [11] Hélénon O, Bellin M.F., Claudon M, Cornud F, Collectif. *Imagerie de l'appareil génito-urinaire: appareil urinaire, appareil génital masculin*. Paris: Flammarion médecine-sciences; 2005.
- [12] Thomas AA, Lane BR, Thomas AZ, Remer EM, Campbell SC, Shoskes DA. Emphysematous cystitis: a review of 135 cases. *BJU Int* 2007;100(1):17–20.
- [13] Gryseels B, Polman K, Clerinx J, Kestens L. Human schistosomiasis. *Lancet* 2006;368(9541):1106–18.
- [14] Petri WA. Imaging of parasitic diseases. *JAMA* 2008;299(22):2691–2.
- [15] Wong-You–Cheong JJ, Woodward PJ, Manning MA, Davis CJ. Inflammatory and nonneoplastic bladder masses: radiologic-pathologic correlation1. *Radiographics* 2006;26(6):1847–68.