

# Microvascular Arteriovenous Shunting is a Probable Pathogenetic Mechanism in Erythromelalgia

Cato Mørk, Claes L. Asker,\* E. Göran Salerud,\* and Knut Kvernebo†

National Hospital, Department of Dermatology, Oslo, Norway; \*Department of Biomedical Engineering, Linköping University, Sweden;

†Ullevaal Hospital, Department of Cardiothoracic Surgery, University of Oslo, Norway

**Erythromelalgia is a condition consisting of red, warm, and burning painful extremities. Symptoms are relieved by cold and aggravated by heat. A wide variety of etiologic conditions can cause erythromelalgia, but one common pathogenetic mechanism, microvascular arteriovenous shunting, has been hypothesized. The aim of this study was to test this hypothesis. Quantification of skin microvascular perfusion using laser Doppler perfusion imaging and skin temperature at rest and after central body heating was performed in 14 patients with erythromelalgia and 11 controls. Attacks of erythromelalgia were induced in eight patients after heat provocation. In the plantar region of the foot, the location of**

**numerous anatomical arteriovenous shunts, these patients significantly increased the skin perfusion as compared with asymptomatic patients with erythromelalgia and controls. In the dorsal region with few arteriovenous shunts no significant differences between the groups were demonstrated. The results show a relation between clinical symptoms and increased perfusion in the region of numerous anatomical arteriovenous shunts, and support the hypothesis of increased thermoregulatory arteriovenous shunt flow during attacks in primary erythromelalgia. Key words: erythromelalgia/laser Doppler perfusion imaging/skin thermoregulatory perfusion. J Invest Dermatol 114:643–646, 2000**

**E**rythromelalgia (EM) (erythro = red, melos = limb, algos = pain) is a rare disorder of unknown etiology characterized by intense burning extremity pain associated with erythema and increased skin temperature. Warmth intensifies the discomfort whereas cold provides relief (Thompson *et al*, 1979). Most patients have intermittent distress and the intensity of the involvement varies from mild discomfort to very severe pain (Kalgard *et al*, 1997). No diagnostic laboratory criteria have so far been described.

Most textbooks consider EM as a disease entity, and the condition has like its antithesis, Raynaud's disease, been classified into a primary and a secondary group (Smith and Allen, 1938). Others claim that EM is a condition caused by a specific pathophysiologic response, skin microvascular shunting, which can be induced by a number of diseases (Kvernebo, 1998). This view is analogous to the recognized fact that inflammation is not a specific disease, but a physiologic response to stimuli such as infection, trauma, or tumor. According to the shunting hypothesis symptoms are caused by tissue hypoxia, induced by a maldistribution of skin microvascular blood flow with increased thermoregulatory flow through arteriovenous (AV) shunts and an inadequate nutritive perfusion. If available blood is shunted away from normal skin capillaries, the skin will be hypoxic. Anatomical AV anastomoses normally present in the hands and feet (primary EM), capillaries with a pathologic blood tissue diffusion barrier (EM secondary to diabetes mellitus and vasculitis) and capillaries with increased blood flow velocity (EM secondary to myelo-

proliferative disorders) because of reduced capillary density, can serve as shunting vessels. Pathologic microvascular angiogenesis (hereditary EM) can also create shunts.

Anatomical AV anastomoses are located in acral areas, mainly plantar and palmar aspects of feet and hands. By relating the perfusion increase in plantar and dorsal aspects of the feet in EM patients and controls during central body heating with the occurrence of EM symptoms, we wanted to test the hypothesis of AV shunting.

## MATERIALS AND METHODS

**Subject selection** Over a period of 15 y we have collected and have complete follow up of a material of 124 EM patients fulfilling the above-mentioned clinical criteria (Kalgard *et al*, 1997). In this study we evaluated a subset of 14 patients and compared them with 11 healthy age- and sex-matched controls (**Table I**). Previously we have introduced a new clinical classification of EM patients (Kvernebo, 1998). The condition is regarded primary when no underlying disease is known. The symptoms can be classified into severity groups; one means minimal and eight maximal pain (Kalgard *et al*, 1997). The following inclusion criteria were chosen: primary EM, severity group 2–3, age 18–75 y, good physical and mental health. All subjects signed a written consent form. EM symptoms recorded as severity group 2 means that the patient was feeling uncomfortably warm in periods and cooled the feet by walking barefoot on cold floors, etc. Group 3 indicated periods of burning pain and the patient immersed the feet in cold water < 1 h per d. Patients were excluded if they had a history of any disease or condition that, in the opinion of the investigator, might confound the results of the study, concurrent use of vasoactive drugs, treatment with any other investigational drug during the previous 3 mo and drug or alcohol abuse. None of the control subjects had a history of cardiovascular or other serious disease.

## Laser Doppler perfusion imaging and temperature measurements

The principles governing measurements of microvascular perfusion by laser Doppler flowmetry have been described in detail elsewhere (Nilsson *et al*,

Manuscript received July 2, 1999; revised December 10, 1999; accepted for publication January 14, 2000.

Reprint requests to: Dr. Cato Mørk, National Hospital, Department of Dermatology, Oslo, Norway. Email: [cato.mork@rh.uio.no](mailto:cato.mork@rh.uio.no)

Abbreviations: AV, arteriovenous; EM, erythromelalgia.

**Table I. Subject characteristics**

	Symptomatic EM	Asymptomatic EM	Healthy controls
No	8	6	11
Male/female	2/6	1/5	3/8
No of smokers	4	1	1
Age <sup>a</sup>	32.0 (19.4–61.6) <sup>c</sup>	60.8 (28.3–71.1)	38.3 (24.3–65.3)
Age of EM onset <sup>d</sup>	21.8 (10.1–49.2) <sup>c</sup>	49.6 (26.0–59.3)	
Duration of EM <sup>d</sup>	9.3 (6.5–16.0)	10.8 (2.3–21.1)	
EM severity group <sup>b</sup>	2.5 (2–3)	2.8 (2–3)	

<sup>a</sup>Years, median with total range.

<sup>b</sup>Severity described in a scale from one (minimal symptoms) to eight (maximal symptoms), median with total range.

<sup>c</sup> $p < 0.05$  as compared with asymptomatic EM.

**Table II. Skin temperature and increase in skin temperature is higher in symptomatic EM patients as compared with asymptomatic patients and controls**

	Symptomatic EM	Asymptomatic EM	Healthy controls
Time <sup>a</sup>	77 (50–100)	73 (60–100)	81 (36–100)
Temp <sub>1</sub> <sup>b</sup>	23.9 (20.3–28.5)	23.8 (20.3–28.9)	23.7 (21.4–31.8)
Temp <sub>2</sub> <sup>c</sup>	34.2 (33.2–35.8) <sup>e</sup>	33.0 (23.8–34.2)	32.3 (25.2–35.2)
$\Delta$ Temp <sup>d</sup>	11.8 (4.7–13.3) <sup>e</sup>	7.0 (2.7–9.9)	4.6 (1.0–12.1)

<sup>a</sup>Time for heat provocation (minutes), median with total range.

<sup>b</sup>Skin temperature at baseline (°C), median with total range.

<sup>c</sup>Skin temperature after central body heating (°C), median with total range.

<sup>d</sup>Change in skin temperature (°C), median with total range.

<sup>e</sup> $p < 0.05$  as compared with asymptomatic EM and  $p < 0.01$  as compared with healthy controls.

1980a, b; Gush *et al*, 1984). In our study the skin microcirculation was examined with laser Doppler perfusion imaging (PIM 1.0 Lisca Development AB, Sweden), a technique employing multiple point recording for visualization of skin blood perfusion in terms of two-dimensional flow maps (Wårdell and Nilsson, 1995). Laser Doppler perfusion imaging offers a system for noninvasive, nontouch imaging of superficial microvascular blood perfusion and therefore prevents external mechanical sensory stimuli that may influence perfusion in the microvascular network under study. The complete system consists of a computer-controlled mechanical laser scanner, a PC, and special software. The perfusion values are mapped in a two-dimensional fashion on to the system console screen and later stored to the hard disk drive. The low-power He–Ne laser beam is sequentially moved over the tissue surface. The light illuminates the tissue under study in a stochastic manner. The main proportion of the Doppler signal originates from the upper 200–300  $\mu$ m of the skin (Jakobsson and Nilsson, 1993). The laser Doppler technique gives a semiquantitative estimate of the perfusion. Data are expressed as flux, defined as the product of the number and mean velocity of the erythrocytes in the measuring volume. The output signal of the processor (within the range 0–10 V) is linearly proportional to tissue blood perfusion. The processor output signal is sampled and stored on to the PC hard disk. From the captured perfusion values a color-coded image is generated and presented on a monitor and stored to file for further data and image analysis. A special software (LDISOFT, Lisca, Sweden) was used to analyze data.

As the affection of EM was symmetrical in all patients, the skin temperature of the plantar region of the first left toe was evaluated not to disturb the microcirculation in the area of interest for perfusion measurements using Anritsu HFT-80 Digital Handheld Thermometer (Anritsu Meter, Japan) with a 5 mm flat leaf probe model 540E/540K.

**Laboratory procedures** The subjects had been instructed not to eat, drink coffee/tea, or smoke for 3 h before measurements. They rested in a supine position with the test foot stabilized with pillows of sand to avoid gross movement artefacts. Prior to measurements they were recumbent for 20 min in a room with an ambient temperature of  $23 \pm 1^\circ\text{C}$ , protected from physical and psychologic stress. To induce central body heating, the subjects were covered with multiple duvets except for the left foot and head. A perfusion assessment protocol with two test sites were chosen; the dorsal region of the left foot (proximal to the interstitium of the first and second toes), known to contain no or few AV anastomoses, and in the anterior section of the foot arch at the left foot, with numerous AV anastomoses (Grant and Bland, 1931; Sherman, 1963). Pain intensity was rated before and after heating with a visual analog scale (VAS 0–100) (Scott and Huskisson, 1976). Whole body heating was terminated when patients got EM symptoms (VAS score  $\geq 50$ ), reached a toe temperature  $> 32^\circ\text{C}$  or at 100 min. Skin temperature and mean skin perfusion levels were recorded at baseline and after whole body heating. The experiments were performed during winter, normally the best period of the year for these patients. The mean outdoor temperature during the test period measured  $-6.2^\circ\text{C}$  (personal communication, Norwegian Meteorological Institute).

The scanner head of the perfusion imager was positioned parallel to the skin surface of interest to reduce the geometrical distortion of the image. The distance between the scanner head and the skin was set to 10 cm in all measurements. The extension of the tissue area to be imaged was marked using black ink and tape. Image format was set to  $20 \times 20$  pixels, resolution

was set to “high” giving a morphologic resolution level of approximately 0.4 mm. Measurements were performed in a dark room, as ambient light may bias the recordings.

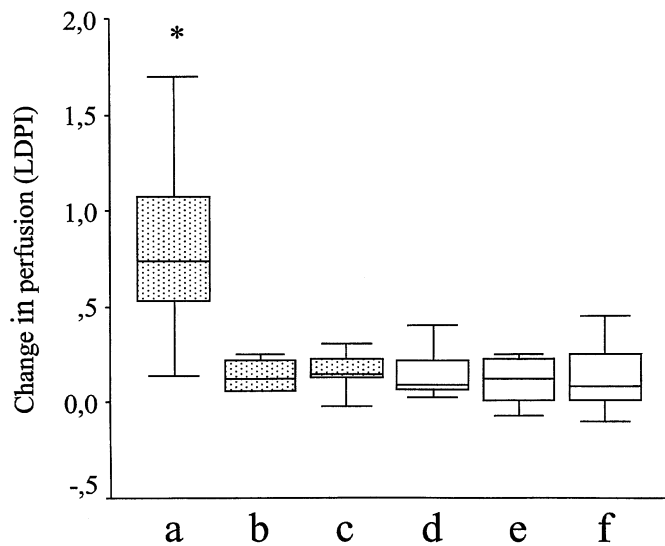
**Statistical analysis** All results are expressed as medians with total range. For comparison between groups the Kruskal–Wallis test (more than two groups), Mann–Whitney test (two groups), and Fisher’s exact test were used, and for changes within groups the Wilcoxon signed–rank test was used. Differences were considered to be significant when the  $p$ -values were less or equal to 5%. Sample sizes were calculated using the program nQuery Advisor 2.0. (Statistical Solutions, Cork, Ireland).

## RESULTS

No EM patient had symptoms at baseline. EM attacks were induced in eight of the 14 patients after whole body heating whereas no discomfort was experienced in the control group. Before analysis the patients were subdivided into two groups, those with and without EM symptoms during the study. The age of the asymptomatic group was significantly higher in comparison both with the symptomatic patients and controls ( $p < 0.05$ , **Table I**). A significantly higher median age at the onset of EM was also found for the asymptomatic subjects. There were no statistical differences between the patient groups in terms of gender, number of smokers, duration, and prestudy severity of EM. Maximal symptoms during the study in symptomatic EM patients were pain VAS score of 65 (50–100). The heat provocation time was not different between the groups (**Table II**). All three groups significantly increased the toe temperature during whole body heating (**Table II**). Symptomatic EM patients reached significantly higher skin temperature after heat provocation compared with asymptomatic EM and controls whereas no differences could be found at baseline. Linear regression analysis did not show significant correlation between flux increase and heating time in any of the three groups or sites chosen (best  $r^2 = 0.356$ , significance level  $> 20\%$ ). Symptomatic EM patients and controls significantly increased the perfusion at the dorsal and plantar region compared with baseline in response to central body heating ( $p < 0.05$ ). Asymptomatic EM showed significant increase at plantar aspect ( $p < 0.05$ ), but only borderline increase at dorsum ( $p = 0.07$ ) (**Fig 1**). In symptomatic EM the perfusion in the plantar aspect of the foot, the region containing numerous AV anastomoses, revealed the highest absolute perfusion values (**Table III**) as well as the highest increase in perfusion (**Fig 1**,  $p < 0.01$ ). In the dorsal aspect of the foot, the region with few AV anastomoses, no group difference could be demonstrated.

## DISCUSSION

Skin perfusion serves nutritional and body thermoregulatory purposes. At rest, in a comfort temperature environment, a minimal part of the perfusion supplies nutritional needs, whereas a larger part serves a thermoregulatory function (Fagrell, 1984). In



**Figure 1. Increased skin perfusion in areas of AV shunts during EM symptoms.** Symptomatic EM patients increased perfusion in the plantar aspects of the foot (■) significantly more than asymptomatic EM patients and controls. In the dorsal aspect of the foot (□), no differences were observed. Distribution of data is illustrated as box plots, where the boxes show the median, quartiles, and extreme values. \* $p < 0.01$  compared with all other values. (a) Symptomatic EM planta pedis; (b) asymptomatic EM planta pedis; (c) control planta pedis; (d) symptomatic EM dorsum pedis; (e) asymptomatic EM dorsum pedis; and (f) control dorsum pedis. LDPI, Laser Doppler perfusion imaging.

acral areas numerous AV anastomoses, innervated by sympathetic nerves, regulate the level of the thermoregulatory flow. In the foot these anatomical AV anastomoses are mainly located in the plantar aspect of the feet (Grant and Bland, 1931; Sherman, 1963). Our hypothesis for the development of EM symptoms was maldistribution of available perfusion in favor of AV anastomoses, resulting in skin warming, followed by increased metabolism, and a relative deficit in the nutritional perfusion and development of EM symptoms (Kvernebo, 1998). To test the hypothesis of increased shunt flow during symptoms we examined patients and controls before and after central body heating with laser Doppler perfusion imaging, a method known to assess both nutritional and thermoregulatory flow (Kvernebo *et al*, 1988). Measurements of the oxygen tension in human tissue can be performed transcutaneously and through implanted probes. The first technique average values from a relatively large area, and the second technique creates a trauma reaction with the possibility of local bleeding. We believe that the tissue oxygen tension varies considerably in patients with symptomatic primary EM, with high values near the perfused vessels and low values in other areas. Currently a study is underway, assessing capillary distribution and density in the skin of EM patients and controls, using a newly developed computer based microscopy technique (Zhong *et al*, 2000).

The finding of increased skin flow in areas of AV shunts during EM attacks supports the shunting hypothesis. The increase in temperature is secondary to the increase in perfusion, and the temperature measurements were in accordance with the results of the perfusion studies.

In this study we used central body heating, because central thermal stimulation increases skin blood flux through reduced sympathetic neural action on AV shunts, whereas increase in blood flux evoked by local heating take place mainly through capillary beds, independent of sympathetic nervous activity (Hales *et al*, 1978a, b, 1985).

EM represents a heterogeneous group of patients. In this study we wanted to minimize this problem by predefining inclusion and exclusion criteria. In our database of 124 patients, 37 patients were

**Table III. Absolute perfusion in the plantar aspect of the foot is significantly higher in symptomatic EM patients after whole body heating as compared with asymptomatic EM patients**

	Flux <sub>1</sub> <sup>a</sup>	Flux <sub>2</sub> <sup>b</sup>
Symptomatic EM		
Dorsum <sup>c</sup>	0.54 (0.41–0.69)	0.71 (0.55–0.96)
Planta <sup>d</sup>	0.56 (0.34–0.91)	1.19 (0.61–2.61) <sup>e</sup>
Asymptomatic EM		
Dorsum	0.51 (0.38–0.83)	0.53 (0.46–1.06)
Planta	0.45 (0.31–0.88)	0.54 (0.48–0.94)
Healthy controls		
Dorsum	0.51 (0.35–0.90)	0.77 (0.45–1.15)
Planta	0.69 (0.34–1.45)	0.80 (0.41–1.61)

<sup>a</sup>Flux at baseline.

<sup>b</sup>Flux after heat provocation.

<sup>c</sup>Dorsal aspect of the foot.

<sup>d</sup>Plantar aspect of the foot.

<sup>e</sup> $p < 0.05$  as compared with asymptomatic EM.

alive with primary EM and with moderate severity and aged between 18 and 75 y. Of these, 14 fulfilled the other selection criteria and were willing to participate in the study. It is a possibility that symptomatic and asymptomatic patients in this study may represent different pathogenetic subgroups, but EM patients are known to have fluctuating symptoms and variable tolerance to heat provocation with time (Kvernebo, 1998). Our experience is that patients who have been exposed to our standardized heat provocation test several times sometimes respond with symptoms of EM and other times are asymptomatic. The different responses occur in spite of nearly the same skin temperature within the so-called critical skin temperature range of 32–36°C that has been described in association with EM symptoms (Brown, 1932; Allen *et al*, 1984; Babb *et al*, 1964; Thompson *et al*, 1979). In our study skin temperatures within the critical range failed to produce symptoms in six of 14 patients. We could not detect any clinical features that separated the two patient groups, and probably both biologic and psychologic factors determine the effect of heat provocation.

Few physiologic studies of the pathophysiology of EM have been published and available results are often based on case reports or studies on a small number of asymptomatic EM patients. The results often seem to be contradictory. In the literature hypotheses of both vascular and neural dysfunction have been proposed. The hypothesis of AV blood shunting in the skin of EM patients as a primary event, leading to hypoxia is strengthened by the results of this study. Are other findings in the literature compatible with this hypothesis? Histologic examinations indicate an actual reduction in sympathetic innervation in EM patients with deficient sympathetic regulation (Uno and Parker, 1983; Vendrell *et al*, 1988; Staub *et al*, 1992). These findings may be secondary to nerve injury caused by hypoxia, and may therefore be explained by the AV shunting hypothesis. Denervated parts of the vasculature are known to develop receptor supersensitivity, amplifying the response to circulating vasoactive agents. In EM patients the cutaneous microvessels have been shown to have a paradoxical vasoconstrictor tendency in between attacks of EM (Littleford *et al*, 1999a, b). This observation can also be the end result of a hypoxic injury to parts of the skin microvasculature caused by AV shunting with a corresponding tissue hypoxia. Thickened blood vessel basement membranes, perivascular edema, and endothelial swelling have been observed in affected skin of EM patients (Kvernebo, 1998). During these conditions O<sub>2</sub> diffusion between blood and tissue is hampered. The blood flow through these vessels does not reach equilibrium of O<sub>2</sub> tension with the surrounding tissue, and a “physiologic” AV shunt is created. Arteriolar inflammation,

fibromuscular intimal proliferation and thrombotic occlusions are typical findings in skin biopsies from EM patients secondary to myeloproliferative disorders (Michiels *et al*, 1985). van Genderen and Michiels (1997) have proposed that myeloproliferative disorders are always present in EM cases. Thrombosis of microvessels will cause a reduced capillary density with the possibility of patchy hypoxia because of long oxygen diffusion distances in the tissue. Arteriolar inflammation and the corresponding endothelial swelling probably causes endothelial dysfunction, and probably leads to an imbalance in the production of vasodilators (e.g., nitric oxide, prostaglandins) and vasoconstrictors (e.g., endothelin, thromboxane A<sub>2</sub>).

The present findings support the hypothesis of increased AV shunting during EM attacks. The laser Doppler perfusion imaging technique evaluates both nutritional and thermoregulatory shunt flow. We believe that the increase in total flow, with a corresponding increase in skin temperature and metabolic demands, does not supply nutritive perfusion sufficient to maintain adequate tissue oxygen tension. At the dorsal aspect of the foot there is a moderate hyperaemia, but no anatomical arteriovenous shunts are located in this region, and therefore nutritional perfusion is increased sufficient to maintain tissue oxygen tension. In the plantar region we hypothesize that the tissue hypoxia leads to a compensatory arteriolar dilatation with increased skin perfusion and temperature. As the increased flow is again maldistributed in favor of AV shunts and the increased temperature increases the metabolic rate, hypoxia is maintained and a vicious cycle is created. The etiology of this pathogenetic mechanism can probably be of both neural and local vasoactive origin. The hypothesis can explain that all EM patients benefit from the cooling of affected skin, because a reduced temperature will decrease metabolic rate and tissue oxygen consumption. Vasodilator treatment has been shown to be effective in some cases (Özsoylu *et al*, 1979; Özsoylu and Cocksun, 1984; Kvernebo, 1998). Vasodilatory drugs may enhance nutritional capillary perfusion, and thereby tissue oxygen tension in contrast to vasoconstrictory drugs and sympathectomy that may deteriorate EM symptoms and capillary perfusion (Smith and Allen, 1938; Teleford and Simmons, 1940; Cross, 1962; Bada, 1977; Mandell *et al*, 1977; Serratrice *et al*, 1977; Lazareth and Priollet, 1990; Kvernebo, 1998).

---

*We would like to thank Thore Egeland PhD, Center of Epidemiology, The National Hospital, Oslo for assistance in statistical analysis.*

---

## REFERENCES

- Allen IA, Finlay RI, Roddie IC: The effect of local temperature on the response of an extremity to indirect heating in man. *Clin Sci (Colch)* 66:27–32, 1984
- Babb RR, Alarcon-Segovia D, Fairbairn II JF: Erythralgia. *Circulation* 19:136–141, 1964
- Bada JL: Treatment of erythromelalgia with propranolol. *Lancet* ii:412, 1977
- Brown GE: Erythromelalgia and other disturbances of the extremities accompanied by vasodilatation and burning. *Am J Med Sci* 183:468485, 1932
- Cross EG: The familial occurrence of erythromelalgia and nephritis. *Can Med Assoc* 87:14, 1962
- Fagrell B. Microcirculation of the skin. In: Fagrell: eds. *The Physiology and Pharmacology of the Microcirculation*. London: Academic Press, 1984, 2, pp 133–180
- Grant RT, Bland EF: Observations on arteriovenous anastomoses in human skin and in the bird's foot with special reference to the reaction to cold. *Heart* 15:385407, 1931
- Gush RJ, King TA, Jayson MIV: Aspects of laser light scattering from skin tissue with application to laser Doppler blood flow measurement. *Physic Med Biology* 29:14631476, 1984
- Hales IRS, Iriki M, Tsuchiya K, Kozawa E: Thermally induced cutaneous sympathetic activity related to blood flow through capillaries and arteriovenous anastomoses. *Pflugers Arch* 375:1724, 1978a
- Hales IRS, Fawcett AA, Bennet JW, Needham AD: Thermal control of blood now through capillaries and arteriovenous anastomoses in skin of sheep. *Pflugers Arch* 378:5563, 1978b
- Hales JRS, Jessen C, Fawcett AA, King RB: Skin AVA and capillary dilatation and constriction induced by local skin heating. *Pflugers Arch* 404:203–207, 1985
- Jakobsson A, Nilsson GE: Prediction of sampling depth and photon pathlength in laser Doppler flowmetry. *Med Biol Eng Comput* 31:301–307, 1993
- Kalgaard OM, Seem E, Kvernebo K: Erythromelalgia: a clinical study of 87 cases. *J Intern Med* 242:191–197, 1997
- Kvernebo K: Erythromelalgia—A disease caused by microvascular shunting. *VASA* 1:1–39, 1998
- Kvernebo K, Slagsvold CE, Stranden E, Kroese A, Larsen S: Laser Doppler flowmetry in evaluation of lower limb resting skin circulation. A study in healthy controls and atherosclerotic patients. *Scand J Clin Lab Invest* 48:621–626, 1988
- Lazareth I, Priollet P: Coexistence of Raynaud's syndrome and erythromelalgia. *Lancet* 335:1286, 1990
- Littleford RC, Khan F, Belch JJ: Impaired skin vasomotor reflexes in patients with erythromelalgia. *Clin Sci (Colch)* 96:507–512, 1999a
- Littleford RC, Khan F, Belch JJ: Skin perfusion in patients with erythromelalgia. *Eur J Clin Invest* 29:588–593, 1999b
- Mandell F, Folkman J, Matsumoto S: Erythromelalgia. *Pediatrics* 59:45–48, 1977
- Michiels JJ, Abels J, Steketee J, Van Vliet HHDM, Vuzevski VD: Erythromelalgia caused by platelet-mediated arteriolar inflammation and thrombosis in thrombocytopenia. *Ann Intern Med* 102:466–471, 1985
- Nilsson GE, Tenland T, Oberg PA: Evaluation of a laser Doppler flowmeter for measurement of tissue blood flow. *IEEE Trans Biomed Eng* 27:597604, 1980a
- Nilsson GE, Tenland T, Oberg PA: A new instrument for continuous measurements of tissue blood flow by light beating spectroscopy. *IEEE Trans Biomed Eng* 27:1219, 1980b
- Scott J, Huskisson EC: Graphic representation of pain. *Pain* 2:175–184, 1976
- Serratrice G, Godde JL, Schiano A: Treatment of erythromelalgia with beta-blocking agents. *Nouv Presse Med* 6:3973, 1977
- Sherman JL: Normal arteriovenous anastomoses. *Medicine (Baltimore)* 42:247267, 1963
- Smith LA, Allen EV: Erythromelalgia (erythromelalgia) of the extremities. A syndrome characterised by redness, heat and pain. *Am Heart J* 16:175–188, 1938
- Staub DB, Munger BL, Uno H, Dent C, Davis JS: Erythromelalgia as a form of neuropathy. *Arch Dermatol* 128:1654–1655, 1992
- Teleford ED, Simmons HT: Erythromelalgia. *Br Med J* 2:782–783, 1940
- Thompson GH, Hahn G, Rang M: Erythromelalgia. *Clin Orthop* 144:249254, 1979
- Uno M, Parker F: Autonomic innervation of the skin in primary erythromelalgia. *Arch Dermatol* 119:65–71, 1983
- van Genderen PJ, Michiels JJ: Erythromelalgia: a pathognomonic microvascular thrombotic complication in essential thrombocythemia and polycythemia vera. *Semin Thromb Hemost* 23:357–363, 1997
- Vendrell J, Nubiola A, Goday A, Bosch X, Esmatjes E, Gomis R, Vilardell E: Erythromelalgia associated with acute diabetic neuropathy: an unusual condition. *Diabetes Res* 7:149–151, 1988
- Zhong J, Asker CL, Salerud EG: Imaging, image processing and pattern analysis of skin capillary ensembles. *Skin Res Technical* in press, 2000
- Wårdell K, Nilsson GE: Laser Doppler imaging of skin. In Serup J, Jemec GBE (eds). *Handbook of Non-Invasive Methods and the Skin*. Boca Raton: CRC Press Inc., 1995, pp 421–428
- Özsoylu S, Caner H, Göklap A: Successful treatment of erythromelalgia with sodium nitroprusside. *J Pediatr* 94:619–621, 1979
- Özsoylu S, Cocksun T: Sodium nitroprusside treatment in erythromelalgia. *Eur J Pediatr* 141:185–187, 1984