



Atherosclerosis

journal homepage: www.elsevier.com/locate/atherosclerosis

Final results of the HEALING IIB trial to evaluate a bio-engineered CD34 antibody coated stent (GenousTM Stent) designed to promote vascular healing by capture of circulating endothelial progenitor cells in CAD patients^{☆,☆☆}

Wijnand K. den Dekker^a, Jaco H. Houtgraaf^a, Yoshinobu Onuma^a, Edouard Benit^b, Robbert J. de Winter^c, William Wijns^d, Manfred Grisold^e, Stephan Verheye^f, Sigmund Silber^g, Emmanuel Teiger^h, Stephen M. Rowlandⁱ, Erik Ligtenbergⁱ, Jonathan Hill^j, Marcus Wiemer^k, Peter den Heijer^l, Benno J. Rensing^m, Keith M. Channonⁿ, Patrick W.J.C. Serruys^a, Henricus J. Duckers^{a,*}

^a Thoraxcenter Rotterdam, Erasmus University Medical Center, Rotterdam, The Netherlands

^b Virga Jesse Ziekenhuis, Hasselt, Belgium

^c Academisch Medisch Centrum, Amsterdam, The Netherlands

^d Onze Lieve Vrouwe Gasthuis, Aalst, Belgium

^e Med. Univ. Klinik Graz, Graz, Austria

^f Middelheim Ziekenhuis, Antwerp, Belgium

^g Kardiologische Klinik Dr. Müller, München, Germany

^h Hôpital Henri Mondor, Creteil, France

ⁱ OrbusNeich, Fort Lauderdale, USA

^j King's College Hospital, London, United Kingdom

^k Herz- und Diabeteszentrum Nordrhein Westfalen, Bad Oeynhausen, Germany

^l Amphia Ziekenhuis, Breda, The Netherlands

^m Sint Antonius Ziekenhuis, Nieuwegein, The Netherlands

ⁿ Radcliffe Hospital, Oxford, United Kingdom

ARTICLE INFO

Article history:

Received 21 March 2011

Received in revised form 15 June 2011

Accepted 17 June 2011

Available online 25 June 2011

Keywords:

Endothelial progenitor cell

Restenosis

Arterial healing

Re-endothelialization

Stent

Neo-intima hyperplasia

ABSTRACT

Objective: To assess the safety and efficacy of the GenousTM endothelial progenitor cell (EPC) capturing stent in conjunction with HmG-CoA-reductase inhibitors (statins) to stimulate EPC recruitment, in the treatment of patients with de novo coronary artery lesions.

Methods and results: The HEALING IIB study was a multi-center, prospective trial, including 100 patients. The primary efficacy endpoint was late luminal loss by QCA at 6-month follow-up (FU). Although statin therapy increased relative EPC levels by 5.6-fold, the angiographic outcome at 6 month FU was not improved in patients with an overall in-stent late luminal loss of 0.76 ± 0.50 mm. The composite major adverse cardiac events (MACE) rate was 9.4%, whereas 6.3% clinically justified target lesion revascularizations (TLRs) were observed. 2 Patients died within the first 30 days after stent implantation due to angiographically verified in-stent thrombosis. At 12 month FU, MACE and TLR increased to 15.6% and 11.5% respectively and stabilized until 24 month FU. 18 Month angiographic FU showed a significant decrease in late luminal loss (0.67 ± 0.54 , 11.8% reduction or 10% by matched serial analysis, $P = 0.001$). **Conclusion:** The HEALING IIB study suggests that statin therapy in combination with the EPC capture stent does not contribute to a reduction of in-stent restenosis formation for the treatment of de novo coronary artery disease. Although concomitant statin therapy was able to stimulate EPC recruitment, it did not improve the angiographic outcome of the bio-engineered EPC capture stent. Remarkably, angiographic late loss was significantly reduced between 6 and 18 months.

© 2011 Elsevier Ireland Ltd. Open access under the [Elsevier OA license](http://www.elsevier.com/locate/elsevier-ol).

[☆] Independent Imaging Core lab (QCA/QCU) and data monitoring by Cardialysis bv, Rotterdam, The Netherlands.

^{☆☆} ClinicalTrial.gov number NCT00349895.

* Corresponding author at: Erasmus University Medical Center, PO Box 2040, 3000 CA Rotterdam, The Netherlands. Tel.: +31 10 703 2300; fax: +31 10 463 2857.

E-mail address: h.duckers@erasmusmc.nl (H.J. Duckers).

1. Introduction

Drug eluting stents (DES) have emerged as an effective means of attenuating stent-related restenosis formation and has enabled the field of percutaneous coronary intervention to move forward to complex coronary angioplasty, with an efficacy equivalent to surgical intervention in the short and long term [1]. The mainstay of drugs eluted from the stent polymer comprise cytostatic

or cytotoxic compounds to impede neointimal formation that arise from vascular smooth muscle cell (VSMC) activation and proliferation. Lately, DES have been associated with late in-stent thrombosis, presumably based on a concomitant impeded arterial repair response characterized by incomplete endothelial coverage of the stent struts, persistent fibrin deposition and inflammation beyond 24-month post implantation [2]. Therefore, prolonged (6–12 months) dual anti-platelet therapy has been recommended in conjunction with DES in order to mitigate the risk of stent thrombosis that is associated with incomplete healing. In addition, the polymer coating of the DES, which ensures prolonged release of the anti-proliferative compounds, inherently invokes inflammation and cytotoxicity with delayed stent coverage. Furthermore, non-erodable polymers were associated with granulomatous and hypersensitivity reactions in relevant animal models. Finally, DES have been shown to interfere with proper endothelial function in arterial segments adjacent to the implanted stent, as suggested by an impaired or paradoxical vasomotor response, which could pose the segment at risk for ischemia and coronary occlusion [3].

Alternatively, therapeutic interventions aimed to facilitate the vascular repair response following coronary intervention could reinstate endothelial integrity and maintain vascular senescence to prevent VSMC proliferation, local inflammation and vascular platelet activation, while maintaining local vasomotor function to ensure short and long-term success of the treated arterial segment. The underlying strategy of accelerated endothelialization aims to provide a non-thrombogenic coating of exposed stent surfaces to reduce in-stent thrombosis and potentially decrease neointimal hyperplasia. Reinstatement of the endothelial integrity can be augmented by local delivery of endothelial mitogenic compounds, including VEGF [4], or facilitation of attachment of circulating endothelial progenitor cells (EPCs) to the strut surface.

In 2003, development was begun of a bio-engineered stent with a proprietary coating containing an anti-human CD34 antibody (Genous™ Bio-engineered R stent, OrbusNeich) that sequesters circulating CD34+ haematopoietic cells to the stent strut surface, facilitates strut coverage and initiates the arterial repair response. Moreover, the combination of this CD34 antibody-coating with conventional sirolimus-eluting stents appeared to overcome the delayed endothelial coverage in stented porcine coronary arteries [5].

The first clinical experience with the EPC capturing Genous Stent was obtained in 16 patients in the HEALING-FIM study. The healing technology approach was deemed safe and feasible with an in-stent late luminal loss of 0.63 ± 0.21 mm at the 6 month angiographic follow-up (FU) [6]. The original design of this stent platform was adapted before proceeding to the phase I/II study, including modification of monoclonal antibody with a higher affinity and transfer from a wet to a dry lyophilized preparation CD34-antibody coated stent premounted on an Evolution2™ PTCA balloon catheter. In the HEALING II study, treatment with the Genous Stent of 63 elective patients with a de-novo lesion resulted in a 6-month angiographic late loss of 0.78 ± 0.39 mm and percent in-stent volume obstruction of $22.9 \pm 13.7\%$ [7,8]. A sub-analysis of the individual patients suggested that specifically patients with a EPC titer responded relatively poorly to the EPC capture technology compared to patients with a normal low EPC titer, with more prominent late loss and higher incidence of revascularization events. Low EPC titer concurred with a lack of HMG-CoA-reductase inhibitors (statins) in the pharmacotherapy of these CAD patients.

As statins have been shown to augment EPC titer, survival, and activity in vitro and in vivo, we hypothesized that concomitant treatment of CAD with statin therapy could stimulate the EPC titer and efficacy in these patients and therefore the overall response to the EPC capture technology. This led to the design of the HEALING IIB study that aimed to assess the safety and efficacy of the Genous

Table 1
Patient demographics and clinical characteristics.

Patient parameter	HEALING II (n = 63)	HEALING IIB (n = 96)
Age (years)		
Mean SD	60.8 ± 10.2	63.7 ± 9.8
Min–max	43–78	43–78
Body mass index (kg/m ²)		
Mean SD	26.8 ± 3.7	27.3 ± 4.5
Min–max	18.7–38.1	17.1–41.9
Male	66.7% (42/63)	73.7% (71/96)
Diabetes mellitus	12.7% (8/63)	19.8% (19/96)
Hypertension	46.0% (29/63)	66.7% (64/96) ^a
Hypercholesterolemia	66.7% (42/63)	84.4% (81/96) ^a
Previous stroke	3.2% (2/63)	3.1% (3/96)
Congestive heart failure	0.0% (0/63)	3.0% (3/96)
Family history of MI	52.4% (33/63)	55.2% (53/96)
Peripheral vascular disease	3.2% (2/63)	9.4% (9/96)
Previous MI	23.8% (15/63)	26% (25/96)
Previous CABG	3.2% (2/63)	2.01 (2/96)
Previous PTCA	9.5% (6/63)	18.8% (18/96)
Smoking history		
Previous	2.2% (14/63)	42.7% (41/96) ^b
Current	41.3% (26/63)	20.8% (20/96) ^b
Unstable angina	27.0% (17/63)	8.3% (8/96) ^b
Braunwald I	9.5% (6/63)	1.0% (1/96)
Braunwald II	1.2% (8/63)	5.2% (5/96)
Braunwald III	4.8% (3/63)	2.1% (2/96)
Stable angina	60.3% (38/63)	80.2% (77/96) ^b
CCS I	7.9% (5/63)	11.5% (11/96)
CCS II	28.6% (18/63)	56.3% (54/96)
CCS III	20.6% (13/63)	10.4% (10/96)
CCS IV	3.2% (2/63)	2.1% (2/96)
Silent ischemia	12.7% (8/63)	11.5% (11/96)

Numbers are % (counts/available field sample size) or mean ± 1 standard deviation. SD, standard deviation; MI, myocardial infarction; CABG, coronary artery bypass graft; PTCA, percutaneous transluminal coronary angioplasty; Braunwald, Braunwald classification; CCS, Canadian Cardiovascular Society Classification.

^a $P < 0.05$

^b $P < 0.01$

Stent in conjunction with optimal statin therapy to stimulate EPC recruitment in the treatment of stent-related restenosis formation in 100 elective patients with de novo native coronary artery lesions.

2. Methods

For full description of the methods, an expanded “Methods” section is available in the [On-line Data Supplement](#).

3. Results

3.1. Baseline characteristics and procedural outcome

One hundred patients were included in the HEALING IIB study. Four patients were per protocol excluded from post-procedural analysis; two patients did not meet the in- and exclusion criteria, one patient was not on Atorvastatin during 2 weeks pre-procedure as required per protocol and one patient had a post-procedural diameter stenosis of 32% despite post dilatation (see [Fig. 1](#) for flow chart). The baseline patient demographics, lesion characteristics and clinical outcomes of the current HEALING IIB and earlier HEALING II study are summarized in [Tables 1–3](#). The study population had an average age of 64 years, whereas 20% of the patients suffered from diabetes mellitus. Compared to the HEALING II study, patients in the HEALING IIB study had significantly more hypertension, hypercholesterolemia and stable angina and there were more current smokers. On the other hand, there were significantly less previous smokers and patients with unstable angina. At the index procedure, 100% of the patients were initiated on high dose Atorvastatin therapy (80 mg qd) for at least 2 weeks according to the protocol outline. At one month FU, 91% of the patients were still

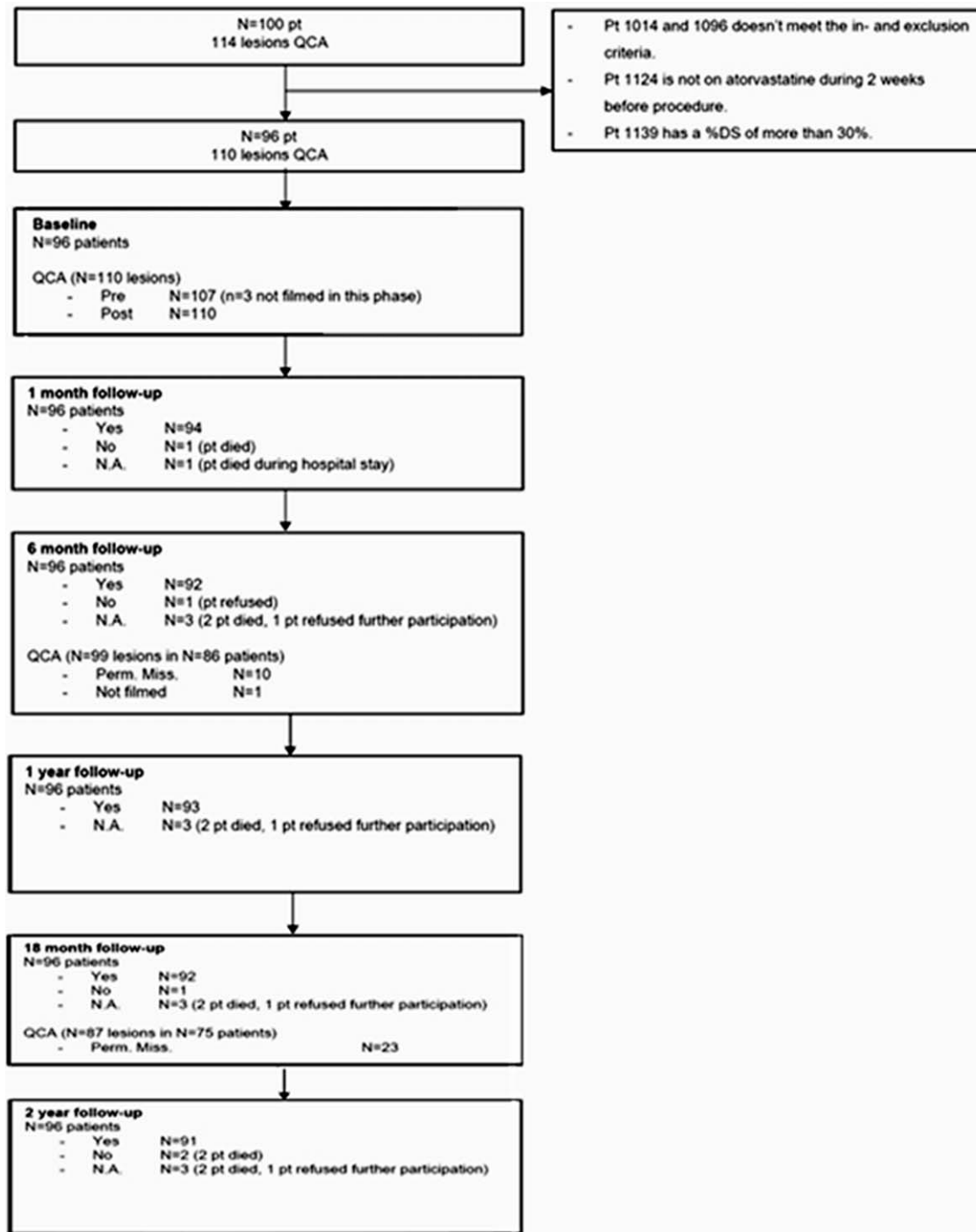


Fig. 1. Flow chart showing enrollment and follow-up of 100 patients.

being treated with Atorvastatin 80 mg qd. In 82 patients, one single index lesion was treated, whereas in 14 patients, 2 lesions in 2 independent coronary arteries received a study stent (total 110 lesions treated). The average lesion length comprised 12.64 ± 5.69 mm in length, with a diameter stenosis of $57.9 \pm 9.9\%$, as assessed by QCA. Angiographic and overall procedural success were respectively 97.3% (107 out of 110 lesions treated) and 93% (89/96 patients; Table 4). A second overlapping EPC capture stent was implanted in three patients to treat a dissection following implantation of the first stent type (A/B dissection), and in eight patients due to incomplete coverage of the target lesion by the first stent. Two patients displayed a transient TIMI II coronary flow following stent deploy-

ment. None of the patients received GPIIb/IIIa inhibitors during or after the index procedure.

3.2. Clinical outcomes

Compliance to clinical FU at 6, 12 and 24 months was 96%, 96% and 95% respectively. Table 3 provides an overview of the major adverse cardiac events (MACE) at 1, 6, 12, 18 and 24 months. Clinical outcomes were comparable with the HEALING II study, as there was only a significant difference in TVR at 18 months. Acute in-stent thrombosis was verified in two patients within the 30 days FU. One patient suffered from an angiographically verified in-stent

Table 2
Lesion characteristics.

Parameter	HEALING II		HEALING IIB	
	#	SD or %	#	SD or %
Study stents per patient	1.1	0.4	1.3	0.5 ^b
Treated segments	63		110	
RCA	24	38.1%	40	36.5%
LM	0	0.0%	0	0.0%
LAD	25	39.7%	43	39.1%
LCX	14	22.2%	27	24.5%
Total stent length [mm]	17.0	2.9	21.4	8.5 ^b
Lesion type ^a	63		107	
A	0	0.0%	1	0.9%
B1	27	42.9%	49	45.8%
B2	36	57.2%	53	49.5%
C	0	0.0%	4	3.7%

LAD, left anterior descending; LCX, left circumflex artery; LM, left main; RCA, right coronary artery

^a According to ACC/AHA classification.

^b $P < 0.0001$.

thrombosis at day one post-implantation and died. Another patient suffered from an angiographically verified acute in-stent thrombosis at day 9 post-implantation and the patient died. This patient received stents in a bifurcation with residual dissection following stent implantation, whereas a second stent could not be implanted. The procedure was assumed not to be a procedural success with suboptimal stent implantation. Both of these events have been adjudicated as cardiac deaths due to a definite in-stent thrombosis by the independent CEC. Finally, one patient had a clinically driven target lesion revascularization (TLR) at 181 days following the index procedure, and 4 days after the re-intervention due to a clinically driven TLR, designated as a secondary, definite in-stent thrombosis. During the re-intervention, the interventionist reported a left main dissection and thrombus in situ in the LAD and left circumflex with normal coronary flow.

Clinically driven TLR by repeat PCI occurred in 6.3% at 6 month FU and increased to 9.4% at 12 month FU. After 12 month FU, no further TLRs were reported and the TLR rate remained stable at 9.4%. Total MACE rate of the patients treated with the EPC capture device was 9.4%, 15.6% and 16.6% at 6, 12 and 24 months respectively (see Fig. 2 for Kaplan–Meier curve). Target vessel failure (clinically driven TVR, recurrent infarction or cardiac death that cannot be attributed to a vessel other than the target vessel) was 7.3% at 6 month FU and 14.6% at 12 and 24 month FU (Table 3).

Angiographic FU occurred in 89.9% (86/96 patients; 99 lesions) at 6 months and in 78.1% (75/96 patients; 87 lesions) at 18 months. The mean in-stent luminal diameter (MLD) in the Genous Stent at 6 months was 1.81 ± 0.68 mm (post-procedural in-stent MLD 2.57 ± 0.41 mm), whereas late luminal loss was 0.76 ± 0.50 mm by QCA (Table 4). At 18-month angiographic FU, mean MLD increased to 1.86 ± 0.68 , whereas late luminal loss significantly decreased to 0.67 ± 0.54 (12% reduction as compared to 6 month FU; 10% reduction using serial matched analysis, $P = 0.001$). There was no difference in late luminal loss between diabetics and non diabetics (0.76 ± 0.56 mm vs. 0.76 ± 0.50 mm).

3.3. Circulating EPC levels in patients receiving the Genous Stent

EPC titer was analyzed before initiation of Atorvastatin 80 qd at screening, at the index procedure (at 2 weeks statin treatment) and at 1 month FU. Blood samples were quantified in a blinded fashion in all 100 patients. At screening, 49% of patients were maintained on some statin therapy at conventional doses. Two weeks following conversion to high dose Atorvastatin, relative EPC levels were increased by 5.6-fold ± 1.30 to 63.4 EPCs/100 μ l whole blood, as compared to baseline values (Fig. 3D), whereas CD34+ circulating hematopoietic cells remained largely unaffected by statin therapy

with an increase of only 12% (Fig. 3A). These data suggest that high dose statin therapy facilitates commitment of the CD34/CD45 hematopoietic cell lineage into the committed endothelial (progenitor) cell fate, rather than recruitment of endothelial progenitor cells and hematopoietic stem cells from the primary niche. EPC levels remained elevated until the 30-day FU after stent implantation.

4. Discussion

The HEALING IIB clinical trial was a multi-centered, open-label, prospective study to evaluate the safety and efficacy of a stent bioengineered to capture circulating EPCs to promote stent re-endothelialization and initiate vascular healing in combination with optimized statin therapy. Previously, post-hoc stratification of study patients in the HEALING II study suggested that in particular patients with low EPC titers responded poorly to the EPC capture stent technology with a late loss and TLR events equivalent to bare metal stents [7]. Moreover, several studies have suggested that cardiovascular risk factors, including hypertension, aging, hypercholesterolemia, and diabetes mellitus, are associated with low EPC titers and EPC dysfunction [9]. Low EPC titer in the HEALING II study was also associated with a lack of statin therapy in these CAD patients (statin use in patients with low vs. normal EPC levels: 41% vs. 92%) [7]. Indeed, statin therapy has been shown to augment EPC levels in vivo, and improve EPC survival, clonal capacity and adhesion in *in vitro* assays by improved eNOS bioavailability, as well as via activation of the PI3-Akt dependent eNOS pathway [9–11]. Therefore, we hypothesized that combined treatment of high-dose statin therapy with the EPC capture stent technology may improve the response of the patient population with low EPC titers, and the overall response to this pro-healing concept of percutaneous coronary intervention.

At enrollment, 79% of CAD patients were already maintained on statin therapy (34% Atorvastatin, 45% other statin therapy). Within two weeks after initiation of high dose Atorvastatin pharmacotherapy, relative EPC levels increased by 5.6-fold at the time of the index procedure and maintained elevated during a 30-day FU. Despite effective EPC recruitment, treatment of elective patients with de-novo coronary artery disease with the EPC capture Genous Stent resulted at 6-month angiographic FU in a late luminal loss of 0.76 ± 0.50 , and a QCA-derived percent volume obstruction of $34 \pm 26\%$ (Table 4). The overall ischemia-driven and non-ischemia-driven revascularization rate at 6-month FU comprised 6.3%, whereas all MACE were 9.4%. These data are not significantly different from the results of the HEALING II study, although MACE seems somewhat increased in the HEALING IIB study. This difference may be explained by the fact that in the Heal-

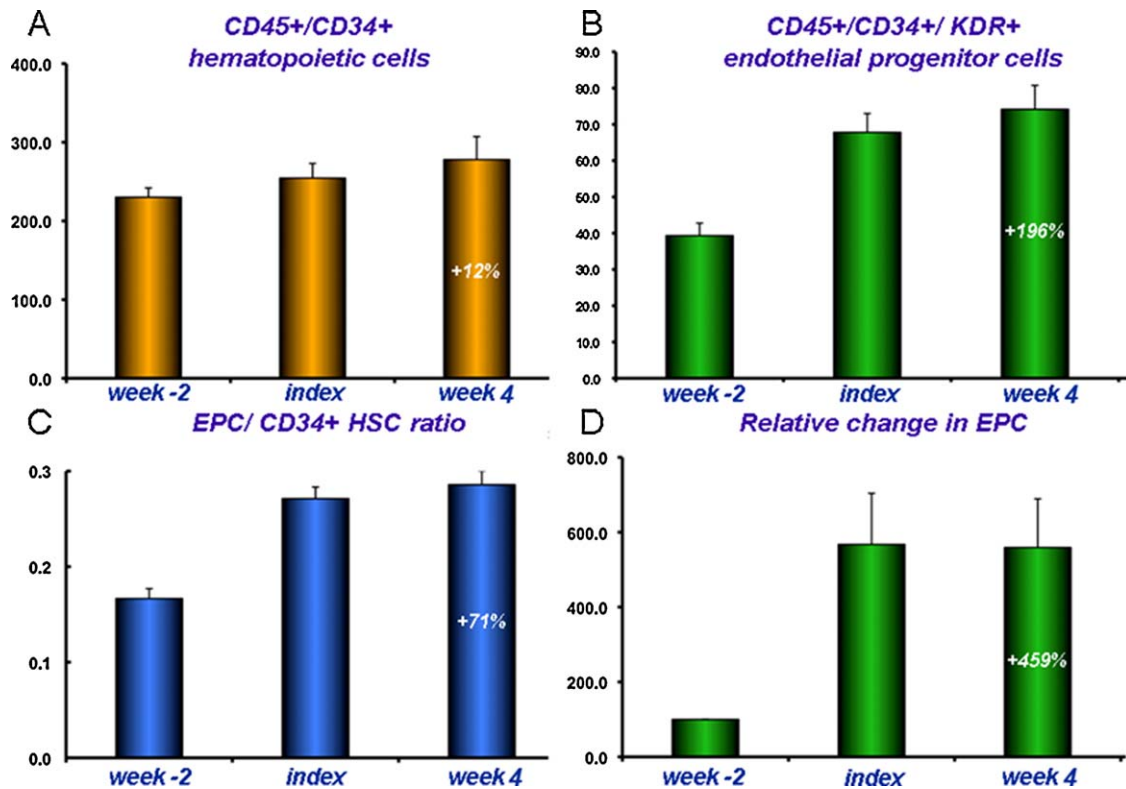


Fig. 2. Kaplan–Meier curve showing the event free survival for major adverse cardiac events (MACE). Mace are defined as the incidence of cardiac death, Q-wave or non Q-wave myocardial infarction, emergency cardiac surgery and clinically justified target lesion revascularization.

ing II study patients with only one vessel disease were included, whereas in the HEALING IIB study, patients with multivessel disease were also included, making them more complex patients and more susceptible to MACE. Consequently, the number of study stents per patient and total stent length was significantly higher in the HEALING IIB study (see Table 2). Remarkably, comparable with the HEALING II study, angiographic late loss was significantly reduced by 0.10 mm (by matched serial analysis, $P=0.001$) between 6 and 18 months. This finding contrasts with findings in DES treated patients, where a progression of late loss is generally observed [12]. Furthermore, one could speculate whether this regression in late luminal loss was reflected in clinical outcome, as MACE and TLR stabilized between 12 and 24 month FU. The question can therefore be raised whether the apparent advantage of DES in comparison with the EPC capture stent is only a temporal advantage, or whether longer-term clinical outcomes will prove otherwise. To address this question, randomized studies comparing DES and the Genous Stent, with clinical and angiographic FU after 24 months are required.

4.1. Re-endothelialization to inhibit in-stent restenosis formation

The assumption that regrowth of endothelium may limit neointimal accumulation has raised inconsistent results in pre-clinical and clinical studies. In gently denudated rat aortas, smooth muscle cell proliferation is not increased subjacent to the areas of endothelial loss [13]. In rat carotid arteries, neointimal accumulation after arterial injury is more related to medial injury than endothelial loss [14]. In balloon-injured rabbit iliofemoral arteries, early restoration of endothelium by autologous endothelial seeding did not decrease neointimal accumulation [15]. Human atherosclerotic plaques have been shown to develop under morphologically intact endothelium [16], whereas endothelialized human coronary stents also contained substantial neointimal hyperplasia [17]. This

suggests that the presence of endothelium and a resistance to intimal growth hence is not inextricably linked. In contrast, in a rabbit arterial balloon injury model, local delivery of VEGF accelerated stent endothelialization and reduced neointimal hyperplasia at 28 days FU [18].

Various studies have shown that circulating EPCs are up-regulated following arterial injury and incorporated at the site of balloon or stent injury to form a new endothelial lining and initiate the vascular repair response [19]. Also, low circulating EPC levels or dysfunctional EPCs in CAD patients were associated with an increased risk of restenosis formation [20]. Stents bearing coatings of antibodies that specifically capture EPCs and immobilize these to the strut surface have been shown to accelerate endothelialization of the stent within 24 h following stent implantation in

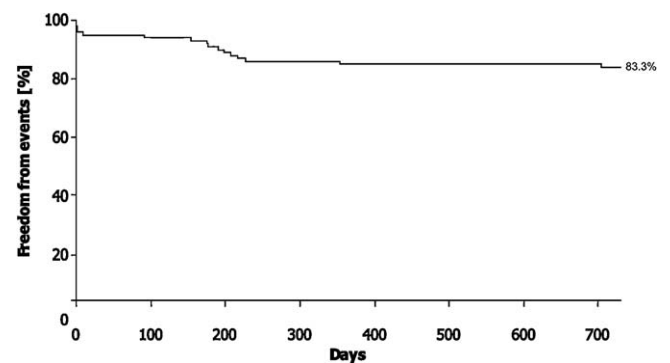


Fig. 3. Effect of high dose Atorvastatin on circulating CD34+ haematopoietic cells and EPC levels. High dose Atorvastatin leads to a mild increase in CD34+ haematopoietic cells (A), whereas absolute and relative EPC count weremarkedly increased (B and D). There was a subsequent increase in EPC/CD34+ haematopoietic stem cell (HSC).

Table 3
Clinical outcomes in HEALING II and HEALING IIB studies.

	At discharge		1 month FU		6 month FU		9 month FU		12 month FU		18 month FU		24 month FU	
	HEALING II	HEALING IIB	HEALING II	HEALING IIB	HEALING II	HEALING IIB	HEALING II	HEALING IIB	HEALING II	HEALING IIB	HEALING II	HEALING IIB	HEALING II	HEALING IIB
	n	n	n	n	n	n	n	n	n	n	n	n	n	n
N	63	96	63	96	63	96	63	96	63	96	63	96	63	96
MACE	0.0%	5.2%	0.0%	0.0%	NA	9.4%	7.9%	15.6%	NA	15.6%	7.9%	7.9%	NA	16.6%
Cardiac Death	0.0%	1.0%	0.0%	0.0%	NA	2.1%	1.6%	2.1%	NA	2.1%	1.6%	1.6%	NA	3.1%
MI	0.0%	4.2%	0.0%	0.0%	NA	5.2%	0.0%	5.2%	NA	5.2%	0.0%	0.0%	NA	5.2%
Q-wave	0.0%	1.0%	0.0%	0.0%	NA	2.1%	0.0%	2.1%	NA	2.1%	0.0%	0.0%	NA	2.1%
Non Q-wave	0.0%	3.1%	0.0%	0.0%	NA	3.1%	0.0%	3.1%	NA	3.1%	0.0%	0.0%	NA	3.1%
TLR clinically driven	0.0%	1.0%	0.0%	0.0%	NA	6.3%	6.3%	11.5%	NA	11.5%	6.3%	6.3%	NA	11.5%
CABG	0.0%	0.0%	0.0%	0.0%	NA	0.0%	0.0%	0.0%	NA	2.1%	0.0%	0.0%	NA	2.1%
re-PCI	0.0%	1.0%	0.0%	0.0%	NA	6.3%	6.3%	9.4%	NA	9.4%	6.3%	6.3%	NA	9.4%
TVR	0.0%	1.0%	0.0%	0.0%	NA	6.3%	20.6%	20.6%	NA	15.6%	25.4%	15.6%	NA	16.6%
TVF	0.0%	2.1%	0.0%	0.0%	NA	7.3%	11.2%	11.2%	NA	14.6%	11.2%	14.6%	NA	14.6%
Stent thrombosis	0.0%	1.0%	0.0%	0.0%	NA	2.1%	0.0%	0.0%	NA	3.1%	0.0%	0.0%	NA	3.1%
Definite/probable	0.0%	1.0%	0.0%	0.0%	NA	2.1%	0.0%	0.0%	NA	3.1%	0.0%	0.0%	NA	3.1%
Definite	0.0%	1.0%	0.0%	0.0%	NA	2.1%	0.0%	0.0%	NA	3.1%	0.0%	0.0%	NA	3.1%
Probable	0.0%	1.0%	0.0%	0.0%	NA	2.1%	0.0%	0.0%	NA	3.1%	0.0%	0.0%	NA	3.1%
Possible	0.0%	0.0%	0.0%	0.0%	NA	0.0%	0.0%	0.0%	NA	0.0%	0.0%	0.0%	NA	0.0%

CABG – coronary artery bypass graft; MACE – major adverse cardiac events; cardiac death, myocardial infarction (Q-wave, non Q-wave, emergent CABG or clinically driven TLR as determined by the CEC). TLR: target lesion revascularization; TVR: target vessel revascularization, clinically and non-clinically driven; TVF: target vessel failure; clinically driven target vessel revascularization, Q-wave or non Q-wave MI, or cardiac death that could be clearly attributed to a vessel other than the target vessel.
*p<0.05

rabbit aortic and porcine iliofemoral and coronary arteries (RGD coating [21], anti-CD105 coating [Active Endothelial Cell Capture by Stents Coated with Antibody against CD105, Song et al. TCT Asia Pacific 2009], and anti-CD34 coating).

However, the role of circulating EPCs on progression of atherosclerosis and neointimal hyperplasia is poorly understood and various lines of research have yielded conflicting results. Whereas Rausher and co-workers demonstrated that bone marrow-derived mononuclear cells attenuated the atherosclerotic burden in ApoE-deficient mice, others have shown that in the ApoE-deficient mice intravenous infusion of bone marrow derived mononuclear cells promoted atherosclerosis formation and in some studies was also associated with a more vulnerable composition of the atherosclerotic lesions with enhanced vascularization, larger lipid cores, thinner fibrous caps and higher numbers of infiltrating CD3 cells [22]. Also, the effect of CD34+ circulating endothelial and smooth muscle progenitor cells on post-injury neointimal hyperplasia is poorly understood. Whereas some studies indicated a benefit on in-stent neointimal hyperplasia in stented pig arterial segments explanted at different time points [23], others have failed to demonstrate a benefit in in-stent neo-intimal hyperplasia in porcine coronary arteries, despite a benefit on EPC capture and accelerated endothelialization (EPC capture in stented porcine coronary arteries increases endothelialization, but does not affect intimal thickening, HM van Beusekom et al., accepted in CCI, 2011). Also, accelerated coverage of PTFE prosthetic vascular in a porcine AV shunt graft model failed to prevent neointimal hyperplasia at the venous anastomosis, and actually, stimulated cellular proliferation led to prominent neointima formation [24]. The current study suggests that despite stimulation of EPC titer in all elective CAD patients, accelerated coverage of the EPC capture stent did not seem to impede restenosis formation and clinical MACE at 6 month FU and questions the paradigm that early re-endothelialization is a prerequisite for appropriate attenuation of neointimal hyperplasia. Even though we were unable to find an early effect on restenosis, there was a significant long term effect in terms of a reduction in late luminal loss between 6 and 18 months. This regression was accompanied by a stabilization of MACE and TLR rates between 12 and 24 months FU.

4.2. Re-endothelialization to inhibit in-stent thrombosis

Alternatively, accelerated re-endothelialization by an EPC capture stent technology may provide a non-thrombogenic coating of the exposed stent struts, thereby reducing the risk of in-stent thrombosis and potentially decreasing or eliminating the need for anti-thrombotic therapy. Recently, we showed in an ex vivo human and baboon shunt model that in-stent thrombosis is decreased in the Genous Stent when compared to BMS [25]. Together with a decrease in mural thrombi, we showed a significant decrease in expression of tissue factor pathway inhibitor (TFPI) and plasminogen activator inhibitor-1 (PAI-1), markers of thrombosis and coagulation, in the Genous Stent compared to BMS. On the contrary, some animal studies of arterial injury have previously suggested that thrombogenicity following arterial injury decreases in the absence of endothelialization. For instance, in balloon-injured rabbit aortas platelet deposition occurred within minutes, but did not increase over the subsequent 24 h [26]. Despite the absence of endothelialization, over the course of a week, the number of vessel-adhered platelets actually decreased, indicating that thrombogenicity decrease preceded endothelial regrowth. Moreover, exposed smooth muscle cells in balloon-injured rat carotid arteries were able to maintain a relatively non-thrombogenic surface [27]. Local delivery of VEGF in stented iliac arteries of non-atherosclerotic rabbits resulted in a near complete re-endothelialization by day 7 following stent implantation

Table 4
Principal effectiveness and safety (results $n = 96$ patients, $n = 110$ lesions).

Effectiveness measures	Post procedure	6 months FU	18 months FU
Angiographic success	97.3% (107/110)		
Procedural success	93.0% (89/96)		
In-stent binary restenosis rate		23.0% (23/99)	
RVD	2.95 ± 0.50 ($n = 110$)	2.79 ± 0.61 ($n = 96$)	2.72 ± 0.60 ($n = 84$)
MLD	2.57 ± 0.41 ($n = 110$)	1.81 ± 0.68 ($n = 99$)	1.86 ± 0.68 ($n = 87$)
% DS in-stent	12.73 ± 6.20 ($n = 110$)	35.2 ± 18.74 ($n = 99$)	31.75 ± 19.96 ($n = 87$)
Stent thrombosis		3.1% (3/96)	3.1% (3/96)
Late loss in-stent (mm)		0.76 ± 0.50 ($n = 99$)	0.67 ± 0.54 ($n = 86$)
Acute gain in-stent (mm)	1.42 ± 0.38 ($n = 107$)		
In-stent malapposition	0.0% (0/62)		
QCA in-stent volume obstruction		32.68 ± 25.2 ($n = 96$)	22.5 ± 28.33 ($n = 84$)

MACE: Major adverse cardiac events: cardiac death, myocardial infarction (Q-wave, non Q-wave, emergent CABG or clinically driven TLR as determined by the CEC; RVD: reference vessel diameter (mm); MLD: minimal luminal diameter (mm); %DS: percent diameter stenosis; numbers are % (counts/available field sample size) or mean \pm standard deviation

versus placebo delivery with an associated reduction of mural thrombus formation. Even though the strength of the inverse correlation between stent endothelialization and the development of organized thrombus was relatively low ($r^2 = .52$), these results suggest that next to endothelialization, other factors play an important role in thrombus suppression [28].

Recent autopsy and angiography studies suggested that following implantation of sirolimus eluting stents (SES) and paclitaxel eluting stents (PES), reendothelialization and arterial healing was incomplete for up to 6–12 months, therefore rendering the vessel more prone to late in-stent thrombosis [29]. More extensive endothelial dysfunction and impeded arterial repair following implantation of SES/PES in remote vascular segments have been suggested by a persistent aberrant coronary vasomotor response to exercise and acetylcholine stimulation of the vascular segments adjacent to the implanted stent. The secondary end points of the HEALING IIB study therefore included in-stent thrombosis at 30 days and incidence of MACE at 6-month FU. Three Patients suffered from a definite in-stent thrombosis at day 1, 9 and 181 days following the index procedure (by ARC definitions). The overall 3% incidence of definite in-stent thrombosis does not suggest an anti-thrombotic capacity of the EPC capture stent technology in the current study; however, all three events had documented significant procedural complications, which might have facilitated the in-stent thrombosis. For example, in the HEALING II study 0% stent thrombosis was reported and in the e-HEALING clinical registry of a real-world population ($n = 4939$) treated with the Genous Stent, the 12 month definite and probable stent thrombosis rate was 1.1% [30]. Moreover, it should be noted that the current study was largely underpowered to obtain a reliable estimate of the stent thrombosis rate with the Genous Stent. The stent thrombosis rate reported in the e-HEALING registry seems to confirm the favorable real world results with the Genous Stent, even in the absence of prolonged dual anti-platelet therapy.

A limitation of the study is the low compliance to 18 month angiographic follow up (78.1%, 75/96), which may have resulted in loss-to-follow up bias and underestimation of the stent thrombosis rate or late luminal loss.

In conclusion, in the HEALING IIB study, 100 elective patients with de novo coronary artery lesions received a Genous Stent in conjunction with HmG-CoA-reductase inhibitors (statins) to stimulate EPC recruitment. Although high dose statin therapy adequately enhanced EPC titers at the index procedure, the EPC capture stent technology did not sufficiently impede clinical restenosis rates and late luminal loss at 6 month angiographic FU. However, a significant reduction in late luminal loss was observed between 6 and 18 month angiographic FU which was accompanied by a stabilization of MACE and TLR rates between 12 and 24 months FU.

Acknowledgement

Study supported by OrbusNeich Medical Technologies, FL, USA.

Appendix A. Supplementary data

Supplementary data associated with this article can be found, in the online version, at doi:10.1016/j.atherosclerosis.2011.06.032.

References

- [1] Serruys PW, Morice MC, Kappetein AP, et al. Percutaneous coronary intervention versus coronary-artery bypass grafting for severe coronary artery disease. *N Engl J Med* 2009;360:961–72.
- [2] Nakazawa G, Finn AV, Joner M, et al. Delayed arterial healing and increased late stent thrombosis at culprit sites after drug-eluting stent placement for acute myocardial infarction patients: an autopsy study. *Circulation* 2008;118:1138–45.
- [3] Hofma SH, van der Giessen WJ, van Dalen BM, et al. Indication of long-term endothelial dysfunction after sirolimus-eluting stent implantation. *Eur Heart J* 2006;27:166–70.
- [4] Walter DH, Cejna M, Diaz-Sandoval L, et al. Local gene transfer of pVEGF-2 plasmid by gene-eluting stents: an alternative strategy for inhibition of restenosis. *Circulation* 2004;110:36–45.
- [5] Nakazawa G, Granada JF, Alviar CL, et al. Anti-CD34 antibodies immobilized on the surface of sirolimus-eluting stents enhance stent endothelialization. *JACC Cardiovasc Interv* 2011;3:68–75.
- [6] Aoki J, Serruys PW, van Beusekom H, et al. Endothelial progenitor cell capture by stents coated with antibody against CD34: the HEALING-FIM (Healthy Endothelial Accelerated Lining Inhibits Neointimal Growth-First In Man) Registry. *J Am Coll Cardiol* 2005;45:1574–9.
- [7] Duckers HJ, Silber S, de Winter R, et al. Circulating endothelial progenitor cells predict angiographic and intravascular ultrasound outcome following percutaneous coronary interventions in the HEALING-II trial: evaluation of an endothelial progenitor cell capturing stent. *EuroIntervention* 2007;3:67–75.
- [8] Duckers HJ, Soullie T, den Heijer P, et al. Accelerated vascular repair following percutaneous coronary intervention by capture of endothelial progenitor cells promotes regression of neointimal growth at long term follow-up: final results of the Healing II trial using an endothelial progenitor cell capturing stent (Genous R stent). *EuroIntervention* 2007;3:350–8.
- [9] Vasa M, Fichtlscherer S, Aicher A, et al. Number and migratory activity of circulating endothelial progenitor cells inversely correlate with risk factors for coronary artery disease. *Circ Res* 2001;89:E1–7.
- [10] Dimmeler S, Aicher A, Vasa M, et al. HMG-CoA reductase inhibitors (statins) increase endothelial progenitor cells via the PI 3-kinase/Akt pathway. *J Clin Invest* 2001;108:391–7.
- [11] Spyridopoulos I, Haendeler J, Urbich C, et al. Statins enhance migratory capacity by upregulation of the telomere repeat-binding factor TRF2 in endothelial progenitor cells. *Circulation* 2004;110:3136–42.
- [12] Aoki J, Abizaid AC, Serruys PW, et al. Evaluation of four-year coronary artery response after sirolimus-eluting stent implantation using serial quantitative intravascular ultrasound and computer-assisted grayscale value analysis for plaque composition in event-free patients. *J Am Coll Cardiol* 2005;46:1670–6.
- [13] Reidy MA, Silver M. Endothelial regeneration. VII. Lack of intimal proliferation after defined injury to rat aorta. *Am J Pathol* 1985;118:173–7.
- [14] Fingerle J, Au YP, Clowes AW, Reidy MA. Intimal lesion formation in rat carotid arteries after endothelial denudation in absence of medial injury. *Arteriosclerosis* 1990;10:1082–7.
- [15] Conte MS, Choudhury RP, Shirakawa M, Fallon JT, Birinyi LK, Choudhury RP. Endothelial cell seeding fails to attenuate intimal thickening in balloon-injured rabbit arteries. *J Vasc Surg* 1995;21:413–21.

- [16] Ross R. The pathogenesis of atherosclerosis: a perspective for the 1990s. *Nature* 1993;362:801–9.
- [17] Anderson PG, Bajaj RK, Baxley WA, Roubin GS. Vascular pathology of balloon-expandable flexible coil stents in humans. *J Am Coll Cardiol* 1992;19:372–81.
- [18] Van Belle E, Maillard L, Tio FO, Isner JM. Accelerated endothelialization by local delivery of recombinant human vascular endothelial growth factor reduces in-stent intimal formation. *Biochem Biophys Res Commun* 1997;235:311–6.
- [19] Rauscher FM, Goldschmidt-Clermont PJ, Davis BH, et al. Aging, progenitor cell exhaustion, and atherosclerosis. *Circulation* 2003;108:457–63.
- [20] George J, Herz I, Goldstein E, Abashidze S, Deutch V, Finkelstein A, et al. Number and adhesive properties of circulating endothelial progenitor cells in patients with in-stent restenosis. *Arterioscler Thromb Vasc Biol* 2003;23:e57–60.
- [21] Blindt R, Vogt F, Astafieva I, et al. A novel drug-eluting stent coated with an integrin-binding cyclic Arg-Gly-Asp peptide inhibits neointimal hyperplasia by recruiting endothelial progenitor cells. *J Am Coll Cardiol* 2006;47:1786–95.
- [22] George J, Afek A, Abashidze A, et al. Transfer of endothelial progenitor and bone marrow cells influences atherosclerotic plaque size and composition in apolipoprotein E knockout mice. *Arterioscler Thromb Vasc Biol* 2005;25:2636–41.
- [23] Granada JF, Inami S, Aboodi MS, et al. Development of a novel prohealing stent designed to deliver sirolimus from a biodegradable abluminal matrix. *Circ Cardiovasc Interv* 2010;3:257–66.
- [24] Rotmans JI, Heyligers JM, Verhagen HJ, et al. In vivo cell seeding with anti-CD34 antibodies successfully accelerates endothelialization but stimulates intimal hyperplasia in porcine arteriovenous expanded polytetrafluoroethylene grafts. *Circulation* 2005;112:12–8.
- [25] Larsen K, Cheng C, Tempel D, et al. Capture of circulatory endothelial progenitor cells and accelerated re-endothelialization of a bio-engineered stent in human *ex-vivo* shunt and rabbit model. *Eur Heart J*, in press.
- [26] Groves HM, Kinlough-Rathbone RL, Richardson M, Moore S, Mustard JF. Platelet interaction with damaged rabbit aorta. *Lab Invest* 1979;40:194–200.
- [27] Clowes AW, Clowes MM, Reidy MA. Kinetics of cellular proliferation after arterial injury. III. Endothelial and smooth muscle growth in chronically denuded vessels. *Lab Invest* 1986;54:295–303.
- [28] Van Belle E, Tio FO, Couffinhal T, Maillard L, Passeri J, Isner JM. Stent endothelialization, time course, impact of local catheter delivery, feasibility of recombinant protein administration, and response to cytokine expedition. *Circulation* 1997;95:438–48.
- [29] Nakazawa G, Ladich E, Finn AV, Virmani R. Pathophysiology of vascular healing and stent mediated arterial injury. *EuroIntervention* 2008;4(Suppl. C):C7–10.
- [30] Silber S, Damman P, Klomp M, et al. Clinical results after coronary stenting with the Genous Bio-engineered R stent: 12-month outcomes of the e-HEALING (Healthy Endothelial Accelerated Lining Inhibits Neointimal Growth) world-wide registry. *EuroIntervention* 2011;6:819–25.