

# Adenosine Stress and Rest T1 Mapping Can Differentiate Between Ischemic, Infarcted, Remote, and Normal Myocardium Without the Need for Gadolinium Contrast Agents



Alexander Liu, MBBS, Rohan S. Wijesurendra, MB BChIR, Jane M. Francis, DCR(R), DNM, Matthew D. Robson, PhD, Stefan Neubauer, MD, Stefan K. Piechnik, PhD, MScEE, Vanessa M. Ferreira, MD, DPHIL

## ABSTRACT

**OBJECTIVES** The aim of this study was to evaluate the potential of T1 mapping at rest and during adenosine stress as a novel method for ischemia detection without the use of gadolinium contrast.

**BACKGROUND** In chronic coronary artery disease (CAD), accurate detection of ischemia is important because targeted revascularization improves clinical outcomes. Myocardial blood volume (MBV) may be a more comprehensive marker of ischemia than myocardial blood flow. T1 mapping using cardiac magnetic resonance (CMR) is highly sensitive to changes in myocardial water content, including MBV. We propose that T1 mapping at rest and during adenosine vasodilatory stress can detect MBV changes in normal and diseased myocardium in CAD.

**METHODS** Twenty normal controls (10 at 1.5-T; 10 at 3.0-T) and 10 CAD patients (1.5-T) underwent conventional CMR to assess for left ventricular function (cine), infarction (late gadolinium enhancement [LGE]) and ischemia (myocardial perfusion reserve index [MPRI] on first-pass perfusion imaging during adenosine stress). These were compared to novel pre-contrast stress/rest T1 mapping using the Shortened Modified Look-Locker Inversion recovery technique, which is heart rate independent. T1 values were derived for normal myocardium in controls and for infarcted, ischemic, and remote myocardium in CAD patients.

**RESULTS** Normal myocardium in controls (normal wall motion, MPRI, no LGE) showed normal resting T1 ( $954 \pm 19$  ms at 1.5-T;  $1,189 \pm 34$  ms at 3.0-T) and significant positive T1 reactivity during adenosine stress compared to baseline ( $6.2 \pm 0.5\%$  at 1.5-T;  $6.3 \pm 1.1\%$  at 3.0-T; all  $p < 0.0001$ ). Infarcted myocardium showed the highest resting T1 of all tissue classes ( $1,442 \pm 84$  ms), without significant T1 reactivity ( $0.2 \pm 1.5\%$ ). Ischemic myocardium showed elevated resting T1 compared to normal ( $987 \pm 17$  ms;  $p < 0.001$ ) without significant T1 reactivity ( $0.2 \pm 0.8\%$ ). Remote myocardium, although having comparable resting T1 to normal ( $955 \pm 17$  ms;  $p = 0.92$ ), showed blunted T1 reactivity ( $3.9 \pm 0.6\%$ ;  $p < 0.001$ ).

**CONCLUSIONS** T1 mapping at rest and during adenosine stress can differentiate between normal, infarcted, ischemic, and remote myocardium with distinctive T1 profiles. Stress/rest T1 mapping holds promise for ischemia detection without the need for gadolinium contrast. (J Am Coll Cardiol Img 2016;9:27-36) © 2016 The Authors. Published by Elsevier. This is an open access article under the CC BY license (<http://creativecommons.org/licenses/by/4.0/>).

From the Division of Cardiovascular Medicine, Radcliffe Department of Medicine, University of Oxford, John Radcliffe Hospital, Oxford, United Kingdom. This study was supported by the National Institute for Health Research Oxford Biomedical Research Centre based at The Oxford University Hospitals Trust, University of Oxford, United Kingdom. Dr. Liu has received research grant support from a British Heart Foundation Clinical Research Training Fellowship (FS/15/11/31233). Drs. Wijesurendra, Neubauer, and Ferreira acknowledge support from the British Heart Foundation Centre of Research Excellence, Oxford, United Kingdom. Dr. Robson is funded by the Medical Research Council. Drs. Robson and Piechnik have patent authorship rights for: 1) U.S. patent pending 61/387,591. SYSTEMS AND METHODS FOR SHORTENED LOOK LOCKER INVERSION RECOVERY (SH-MOLLI) CARDIAC GATED MAPPING OF T1. September 29, 2010. All rights transferred to Siemens Medical; and 2) U.S. patent pending 61/689,067: COLOR MAP DESIGN METHOD FOR IMMEDIATE ASSESSMENT OF THE DEVIATION FROM ESTABLISHED NORMAL POPULATION STATISTICS AND ITS APPLICATION TO CARDIOVASCULAR T1 MAPPING IMAGES. All other authors have reported that they have no relationships relevant to the contents of this paper to disclose.

Manuscript received March 3, 2015; revised manuscript received August 25, 2015, accepted August 27, 2015.

**ABBREVIATIONS  
AND ACRONYMS****CAD** = chronic coronary artery disease**CMR** = cardiac magnetic resonance**LGE** = late gadolinium enhancement**LV** = left ventricular**MBF** = myocardial blood flow**MBV** = myocardial blood volume**ROI** = region of interest**ShMOLLI** = Shortened Modified Look-Locker Inversion recovery

In chronic coronary artery disease (CAD), accurate detection of functional ischemia is important because targeted revascularization improves clinical outcomes (1-3). First-pass myocardial perfusion cardiac magnetic resonance (CMR) during vasodilatory stress directly assesses reductions in microvascular blood flow (MBF), and has demonstrated high diagnostic accuracy for detecting significant coronary stenosis (1-3). However, assessment of MBF alone may not reflect all aspects of ischemia (4-7). Myocardial blood volume (MBV), on the other hand, may be a more comprehensive global marker of ischemia, as it represents the total

volume of capacitance vessels in both the microcirculations and macrocirculations (4-6,8,9). Significant coronary artery stenosis induces capillary recruitment with an increase in resting MBV (9). Myocardial blood volume measurements derived from first-pass contrast-based CMR closely reflect the level of microvascular autoregulation (4,5,9). As a surrogate for epicardial CAD, recent animal studies showed that disturbances in MBV can effectively detect anatomically significant coronary stenoses (4,10), and distinguish their functional relevance (11). Moderate and severe coronary stenoses may be better differentiated using the index of myocardial blood volume reserve than by myocardial perfusion imaging (4). Furthermore, MBV may relate better to cardiomyocyte metabolism by reflecting changes in myocardial oxygen consumption, which is a more reliable marker of cellular ischemia (4,6,11,12). Therefore, MBV determination during vasodilatation and at rest may constitute a more complete assessment of ischemia than MBF (via perfusion imaging) alone.

SEE PAGE 37

Native (pre-contrast) T1 mapping is a novel CMR technique that can potentially improve ischemia detection by detecting MBV and myocardial water content. In MRI, hydrogen-proton spin-lattice relaxation time (T1) is a magnetic property of tissue that is prolonged by increased water content (13,14) and, importantly, depends on blood T1 through its partial volume (14). Each tissue type, such as myocardium, has a specific range of normal T1 values, deviation from which is indicative of disease (13,15-20). By measuring and displaying T1 relaxation times pixel by pixel, native T1 mapping provides a quantitative biomarker of intracellular and extracellular environments of the myocardium without the need for intravenous contrast agents (13). T1 mapping is

highly reproducible with tight normal ranges (13,14), capable of diagnosing a variety of cardiac diseases (13,15,16,18-22). Increased myocardial T1 values act as a surrogate for increased myocardial water (13); hence coronary vasodilatation, which increases MBV (4-6), is expected to prolong T1 and allow detection of microvascular and myocardial blood volume changes during ischemia (9). We have recently demonstrated the ability of stress/rest T1 mapping to detect increases in MBV from coronary vasodilatation in patients with severe aortic stenosis and nonobstructive coronary arteries, with complete reversal and normalization after aortic valve replacement (23). In summary, stress/rest T1 mapping is a highly promising technique for the detection of ischemia and is particularly attractive for applications in patients with CAD.

In this proof-of-principle study, we demonstrate the ability of T1 mapping, during adenosine vasodilatory stress and rest, to distinguish 4 myocardial tissue classes: normal, infarcted, ischemic, and remote myocardium, as a novel gadolinium-free method for ischemia detection. We performed CMR scans in normal controls and patients with known CAD assessing left ventricular (LV) function (cine), viability (late gadolinium enhancement [LGE]), and ischemia (adenosine stress gadolinium first-pass perfusion), and compared them with novel T1 mapping to establish characteristic stress and rest T1 profiles of these 4 myocardial tissues.

**METHODS**

Ethical approval was granted for all study procedures and all subjects gave written informed consent.

**NORMAL CONTROLS.** Twenty normal controls without history of cardiovascular disease, not on cardiovascular medications, and with normal electrocardiograms were recruited. Ten volunteers (7 males,  $33 \pm 10$  years of age) underwent CMR scans at 1.5-T (Avanto, Siemens Healthcare, Erlangen, Germany) and 10 volunteers (7 males,  $36 \pm 11$  years of age) were scanned at 3.0-T (TimTrio, Siemens Medical Solutions), all with identical CMR protocols. All subjects avoided potential adenosine antagonizers (e.g., caffeine) for  $\geq 24$  h before CMR scans.

Cine images were obtained as previously described (23). T1 mapping was performed using the Shortened Modified Look-Locker Inversion recovery (ShMOLLI) sequence, which has been shown to be heart rate independent over a wide range of T1 values (13), as previously described (13,14,18,19,21). In brief, T1 maps were acquired at rest and during peak adenosine stress (140  $\mu\text{g}/\text{kg}/\text{min}$ , intravenously for  $\geq 3$  to 6 min) in 3 short-axis (basal, midventricular, apical) slices

before gadolinium administration and first-pass perfusion (23). The basal slice was carefully planned to exclude LV outflow tract. First-pass perfusion imaging was performed, on matching short-axis slices to T1 maps, during peak adenosine stress with an intravenous bolus of gadolinium (0.03 mmol/kg; Dotarem, Guerbet, Villepinte, France), followed by a 15 ml saline flush (12). Rest perfusion images were acquired >15 min after adenosine discontinuation (12,23). LGE imaging was performed ~8 to 10 min after an additional bolus of gadolinium (0.1 mmol/kg) (12).

**PATIENTS WITH CAD.** Ten patients with angiographically significant stenosis (>50%) in ≥1 coronary artery, who underwent CMR at 1.5-T using cine, adenosine stress/rest T1 mapping, adenosine stress/rest perfusion, and LGE imaging, were included to illustrate the ability of stress/rest T1 mapping to distinguish myocardial tissue classes.

**IMAGE ANALYSIS.** LV function and first-pass myocardial perfusion were analyzed as previously described (23). Short-axis T1 maps were manually contoured to outline the endocardium and epicardium using dedicated software and underwent strict and extensive quality control process as previously described (13-15,18,19,21,23), which resulted in exclusion of 11.7% of segments (for additional details, see the Online Appendix). For normal controls, mean myocardial T1 values were derived from T1 maps at rest and during adenosine stress per subject, per slice, and per segment (American Heart Association 16-segment model) (21). T1 reactivity to adenosine stress was expressed in absolute terms:  $\Delta T1(\text{ms}) = T1_{\text{stress}} - T1_{\text{rest}}$  and as percentages:  $\delta T1(\%) = \Delta T1 \div T1_{\text{rest}} \times 100$ .  $T1_{\text{rest}}$  and  $T1_{\text{stress}}$  represent mean T1 values at rest and during adenosine stress, respectively.

In CAD patients, the mean T1 of ischemic myocardium was measured by placing a region of interest (ROI) in an area corresponding to the area of reversible perfusion defect on first-pass stress and rest imaging but without LGE, accompanied by angiographic evidence of significant coronary stenosis as assessed by an expert interventional cardiologist. Infarcted myocardium on T1 maps was defined by placing a ROI corresponding to an area of infarction on LGE images, defined as enhancement involving the sub-endocardium of >50% transmural, as assessed by 2 experienced observers. To avoid partial volume contamination from the LV blood pool, all infarct ROIs were placed in the core of the infarcts and away from the endocardial and epicardial borders carefully referenced against corresponding cine images in the same phase of the cardiac cycle. Remote myocardial ROI on T1 maps were placed contralateral to the ischemic myocardium in areas without evidence of

first-pass perfusion defects, regional wall motion abnormalities, LGE, or significant upstream angiographic coronary stenosis. A reference ROI was also placed in the LV blood pool.

**STATISTICAL ANALYSIS.** The data are reported as mean ± SD with all tests 2-tailed and parametric, based on Kolmogorov-Smirnov normality checks. Differences in specific individual characteristics, including T1 and relative  $\delta T1$  in selected types of tissue, are tested using separate Student *t* tests, paired whenever possible in same individuals and unpaired between groups. Repeated measures of interslice and intersegmental  $\delta T1$  in normal controls were assessed using analysis of variance with Bonferroni corrected post hoc comparisons. Pearson correlation coefficient (R) was used to assess statistical correlation between samples. Unless otherwise stated, all analyses were performed on single measures per-subject. All analyses were performed using MedCalc Software version 12.7.8.0 (Mariakerke, Belgium). All *p* values <0.05 were considered significant.

## RESULTS

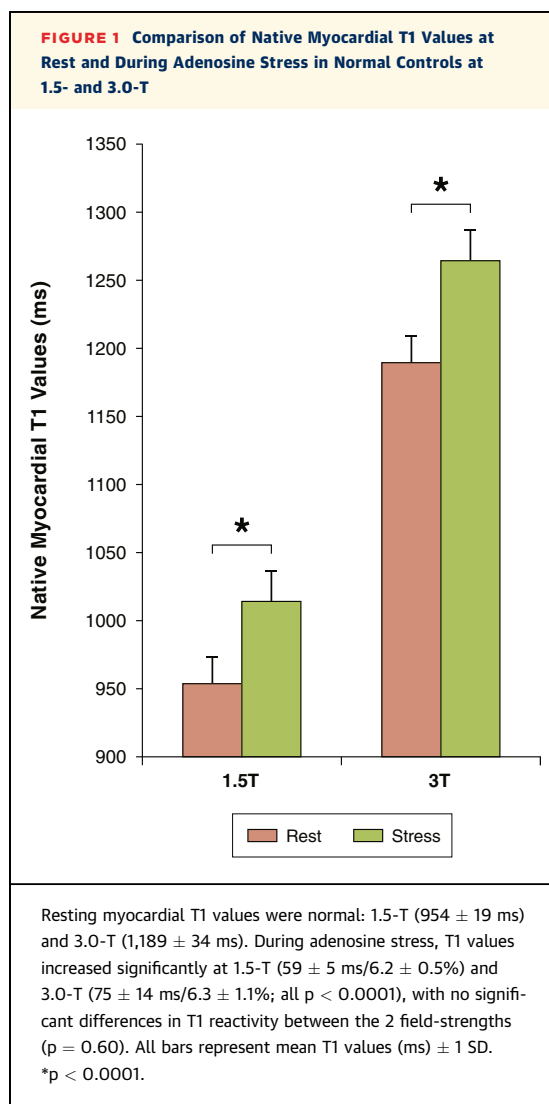
**MYOCARDIAL T1 REACTIVITY IN NORMAL CONTROLS.** All 20 normal controls had normal global and regional LV systolic function (LV ejection fraction  $66 \pm 5\%$ ), myocardial perfusion reserve indices ( $2.0 \pm 0.3$ ), and no LGE (Table 1).

**TABLE 1 Characteristics of Study Subjects**

	1.5-T		3.0-T
	Patients (n = 10)	Controls (n = 10)	Controls (n = 10)
Male	8 (80)	7 (70)	7 (70)
Age, yrs	64 ± 11*	32 ± 10	36 ± 11
Body mass index, kg/m <sup>2</sup>	28 ± 4*	22 ± 2	25 ± 3
Resting heart rate, beats/min	61 ± 8	68 ± 12	64 ± 15
Stress heart rate, beats/min	85 ± 9*	103 ± 11	95 ± 20
Systolic blood pressure, mm Hg	125 ± 9	114 ± 13	125 ± 20
Diastolic blood pressure, mm Hg	76 ± 11	73 ± 10	80 ± 11
Rest rate pressure product, mm Hg·beats/min	7,700 ± 1,400	7,800 ± 1,400	8,100 ± 2,900
Stress rate pressure product, mm Hg·beats/min	10,700 ± 1,700	11,600 ± 1,800	11,900 ± 4,000
Hematocrit, %	46 ± 7	—	—
CMR data			
Left ventricular ejection fraction, %	55 ± 16	66 ± 5	66 ± 5
Myocardial perfusion reserve index	1.9 ± 0.5 (remote) 1.1 ± 0.3 (ischemic)*	2.0 ± 0.2	2.0 ± 0.4
Late gadolinium enhancement, %	16 ± 9*	—	—

Values are n (%) or mean ± SD. \**p* < 0.05 compared to 1.5-T controls.  
 CMR = cardiac magnetic resonance.

Normal control T1 values at rest were within previously published ranges for ShMOLLI:  $954 \pm 19$  ms (1.5-T) and  $1,189 \pm 34$  ms (3.0-T) (13,14,17). Compared to rest, myocardial T1 values during adenosine stress increased significantly at 1.5-T ( $+59 \pm 5$  ms) and 3.0-T ( $+75 \pm 14$  ms; both  $p < 0.0001$ ) (Figure 1). There were no significant differences in  $\delta T1$  between the 2 field strengths ( $\delta T1 = 6.2 \pm 0.5\%$  vs.  $6.3 \pm 1.1\%$ , respectively;  $p = 0.60$ ). Similarly, there were no significant differences between interslice and intersegment  $\delta T1$  values ( $p > 0.13$ , ANOVA) despite apparent per-segment variations in resting myocardial T1 values as previously described (14) (Figure 2B). There was no significant correlation between age and T1 reactivity in the normal controls at 1.5-T ( $R^2 = 0.077$ ,  $p = 0.43$ ) or 3.0-T ( $R^2 = 0.035$ ,  $p = 0.60$ ), over a wide age range (21 to 57 years of age).



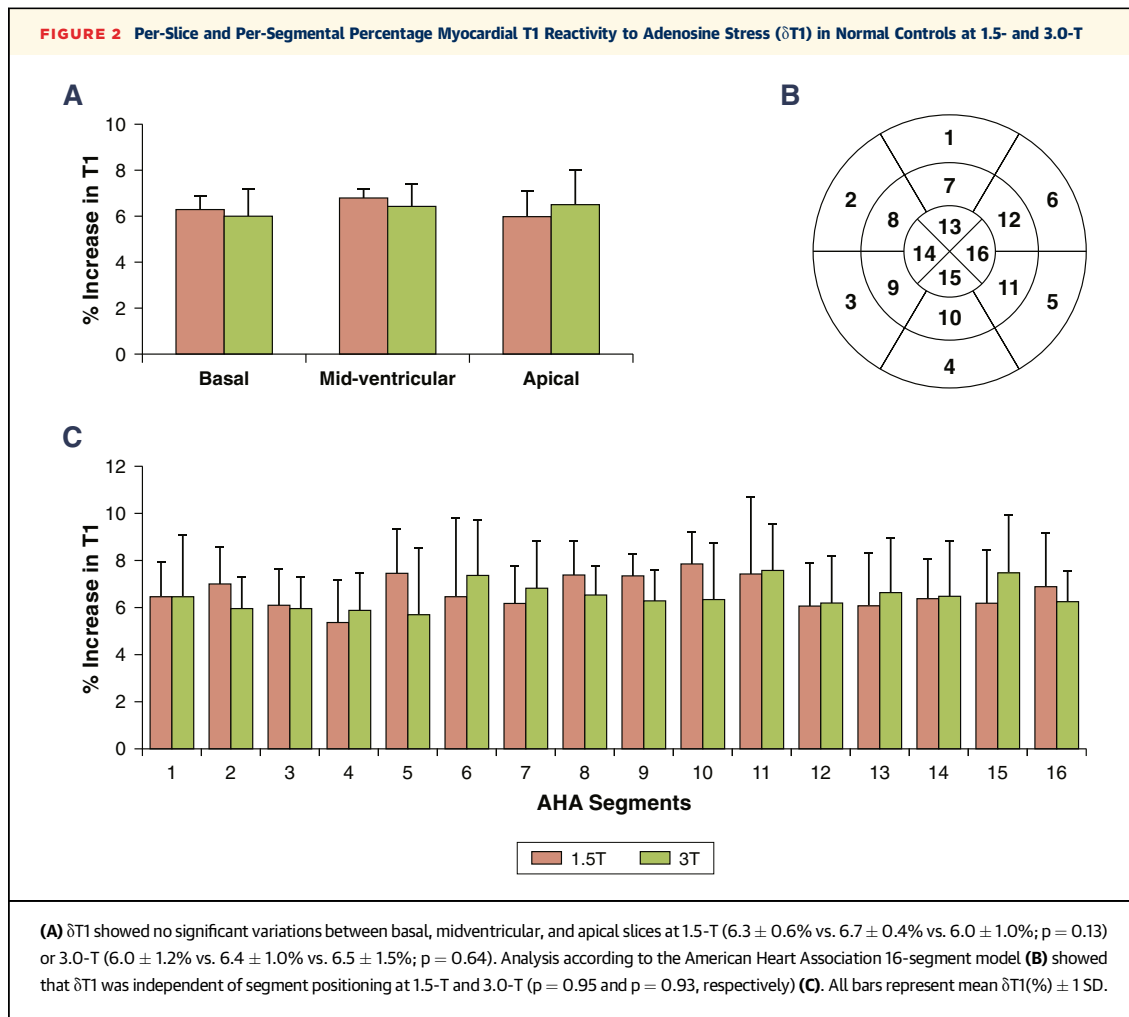
**MYOCARDIAL T1 REACTIVITY IN CAD PATIENTS.** Ten patients with known CAD underwent CMR at 1.5-T (LV function, adenosine stress/rest T1 mapping, and first-pass perfusion, LGE). Each patient demonstrated  $\geq 1$  reversible perfusion defect indicative of inducible ischemia on first-pass perfusion imaging, referenced to  $\geq 1$  angiographically significant coronary lesion ( $>50\%$ ) and without LGE. Additionally, all 10 patients showed evidence of previous myocardial infarction on LGE remote from the ischemic territories (Table 2).

At rest, the remote myocardial T1 ( $955 \pm 17$  ms) was comparable to normal controls at 1.5-T ( $954 \pm 19$  ms;  $p = 0.92$ ). Ischemic myocardial T1 ( $987 \pm 17$  ms) was significantly higher than normal and remote myocardial T1 (all  $p < 0.001$ ). T1 in infarcted myocardium ( $1,442 \pm 84$  ms) was substantially longer than in any other myocardial tissue (all  $p < 0.001$ ) (Figure 3A), and did not correlate with remote ( $R = -0.34$ ,  $p = 0.34$ ) or ischemic ( $R = 0.10$ ,  $p = 0.79$ ) myocardial T1. Moreover, T1 in infarcted myocardium was significantly shorter than in LV blood pool ( $1,555 \pm 66$  ms;  $p = 0.003$ ), with no significant correlations between the 2 ( $R = 0.14$ ,  $p = 0.69$ ), supporting the notion that potential contamination of the infarct T1 by partial volume effects from the LV blood pool is minimal.

There was no significant stress  $\delta T1$  reactivity in ischemic ( $0.2 \pm 0.8\%$ ) or infarcted ( $0.2 \pm 1.5\%$ ) myocardium compared to controls at 1.5-T (all  $p < 0.001$ ). Although remote myocardial  $\delta T1$  reactivity ( $3.9 \pm 0.6\%$ ) was greater than in ischemic and infarcted myocardium (all  $p < 0.001$ ), it was significantly blunted compared to normal controls at 1.5-T ( $6.2 \pm 0.5\%$ ; all  $p < 0.001$ ) (Figure 3B). No significant  $\delta T1$  reactivity was observed in the LV blood pool ( $0.21 \pm 0.7\%$ ).

To check for potential confounding effects of vasodilator medications on myocardial T1, the baseline T1 of patients on nitrate therapy ( $n = 7$ ) was compared to patients without ( $n = 3$ ), and no significant baseline T1 differences were observed in the remote ( $953 \pm 16$  ms vs.  $959 \pm 6$  ms, respectively;  $p = 0.39$ ), ischemic ( $986 \pm 16$  ms vs.  $989 \pm 9$  ms, respectively;  $p = 0.26$ ), or infarcted ( $1,436 \pm 114$  ms vs.  $1,455 \pm 83$  ms, respectively;  $p = 0.39$ ) myocardium between the 2 patient groups. Myocardial tissue characteristics are summarized in Tables 3 and 4.

Figure 4 shows examples of 3 CAD patients with inducible ischemia on first-pass perfusion imaging, myocardial infarctions on LGE and localized corresponding changes on stress/rest T1 maps. Color T1-maps are shown in Online Figure 1.



## DISCUSSION

This proof-of-principle study demonstrates for the first time that normal, remote, and ischemic myocardium have distinctive ranges of T1 reactivity to adenosine vasodilatory stress that can be detected by T1 mapping without gadolinium contrast administration. The finding that T1 reactivity is blunted in remote myocardium of CAD patients compared to normal controls may provide novel insights into disease characteristics of the remote myocardium. Significantly higher resting T1 in ischemic myocardium compared to normal controls and remote regions may potentiate detection of ischemia without vasodilatory stress, in the absence of other causes of T1 elevations at rest (16-18,20,22,24).

**MYOCARDIAL BLOOD VOLUME AS A BIOMARKER FOR ISCHEMIA.** Myocardial ischemia occurs when oxygen supply is inadequate to meet tissue metabolic needs, which is governed by MBF and MBV (7,10).

Myocardial oxygen extraction is near maximal at rest and any increase in oxygen demand is met by an increase in MBF via coronary arteriole vasodilatation and capillary recruitment (7). While the relationships between vascular diameter, flow and blood volume are not straightforward due to differences in reactivity between vessel types (8), MBV and MBF are clearly related and both offer insights into myocardial vascular reserve. Indeed, contrast echocardiography studies demonstrated nonlinear relations between MBV and MBF, especially at higher levels of tissue oxygen consumption (4-6). Recent studies also showed that MBV is reactive to both vasodilatory and inotropic pharmacological agents in coronary artery disease (4-6), with the ability to delineate the functional relevance of coronary stenosis (11).

**POTENTIAL USES OF ADENOSINE STRESS AND REST T1 MAPPING AS A DIAGNOSTIC TOOL FOR ISCHEMIA.** From the perspective of CMR as a diagnostic imaging tool for ischemia, an increase in MBV

<b>TABLE 2 Characteristics of Patients (n = 10) With Coronary Artery Disease</b>	
Male	8 (80)
Age, yrs	64 ± 11
Risk factors	
Current smoker	1 (10)
Ex-smoker	5 (50)
Hypertension	6 (60)
Hypercholesterolemia	5 (50)
Diabetes mellitus	3 (30)
Family history of ischemic heart disease	4 (40)
Medications	
Aspirin	10 (100)
Beta-blocker	10 (100)
ACE inhibitor/angiotensin receptor blocker	5 (50)
Statin	6 (60)
Calcium-channel blocker	3 (30)
Nitrates	3 (30)
CMR data	
≥1 perfusion defect(s) referenced to angiographic stenosis	10 (100)
Full thickness late gadolinium enhancement	4 (40)
Partial thickness late gadolinium enhancement	6 (60)
Age of chronic myocardial infarctions, months	71 ± 70
Angiographic data	
≥1 lesion (>50% visual diameter stenosis)	10 (100)
Left anterior descending artery	5 (40)
Left circumflex artery	4 (50)
Right coronary artery	6 (60)
Values are n (%) or mean ± SD. ACE = angiotensin-converting enzyme; CMR = cardiac magnetic resonance.	

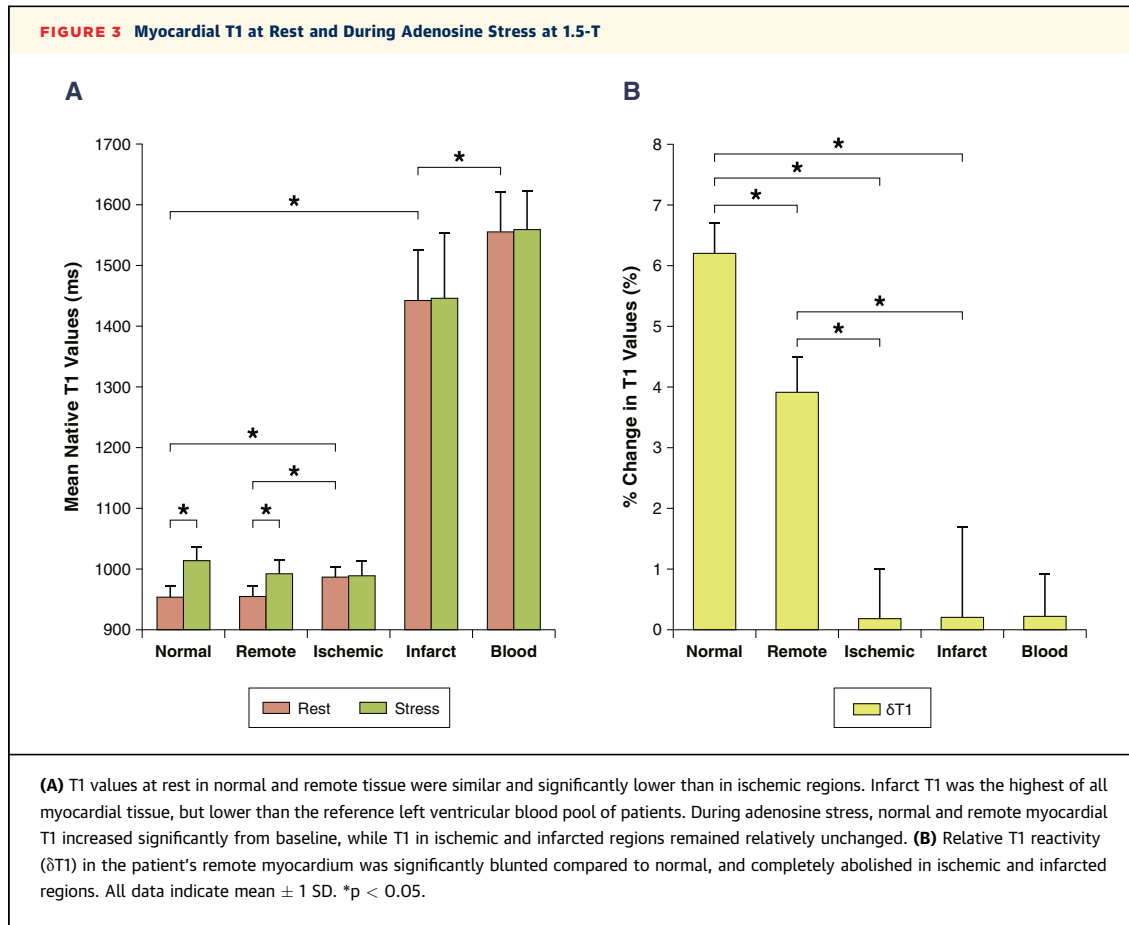
is expected to increase the myocardial water content and prolong T1 relaxation time. T1 mapping offers highly reproducible pixel-wise estimations of myocardial T1, both in normal and pathologic states (15-21,24). Approximately 10% of the myocardial voxel content is occupied by blood volume, which therefore contributes to the myocardial T1 (14) and we now confirm the clear observation of myocardial T1 responses to adenosine vasodilatory stress.

In addition to the stress myocardial T1 response, resting myocardial T1 may also offer additional insights into coronary vascular reserve and function. Notably, ischemic myocardium in CAD patients demonstrate resting T1 values that are nearly as high as in controls during vasodilatory stress, and showed no further reactivity to stress. This strongly suggests that observed elevation in resting T1 in remote myocardium may originate from the intravascular compartment. This may be consistent with maximal compensatory coronary microvascular vasodilatation or increased capillary recruitment downstream from angiographically significant stenosis to maintain adequate tissue oxygen extraction in the face of chronic ischemia (3).

Another interesting point of note is that, in CAD patients, while remote and ischemic myocardium demonstrated the same maximal T1 during stress, this is blunted when compared to controls during maximal vasodilation. Arnold et al. (12) recently demonstrated blunted absolute myocardial perfusion and stress/rest blood oxygen level dependence responses in remote myocardium in a similar patient group to our study, thought to be due to coronary microvascular dysfunction. The origins of the increased resting T1 and the blunted maximal stress T1 response in remote myocardium of patients with CAD compared to normal controls may reflect a degree of microvascular dysfunction, although this is speculative and deserves further investigation.

In this first proof-of-principle study, we relied on widely accepted gadolinium-based CMR techniques (first-pass perfusion and LGE imaging) to define 4 myocardial tissue classes and to demonstrate that normal, infarcted, ischemic, and remote myocardium have distinct stress/rest T1 value profiles that allow their differentiation from each other. Currently, the use of T1 maps alone for immediate visual diagnostics is challenged by intersegmental T1 variations, relatively small “blood versus infarct” T1 differences and interindividual variations in blood T1 (13,14); with further work and clinical validation, however, this proof-of-principle study paves the way for the eventual development of an automated system using stress/rest T1 values that enables clinicians to visually detect ischemic, remote, and infarcted myocardium without the need for gadolinium contrast imaging.

**NATIVE T1 OF CHRONIC MYOCARDIAL INFARCTIONS.** The chronic infarct T1 observed in this study is higher than reported in the literature (25). Because this can only partially be attributed to the known heart rate-dependent underestimation of long T1 values by Modified Look-Locker Inversion Recovery (MOLLI) techniques (13,26), a couple of other explanations are possible. Because the infarcts are subendocardial, there are likely some partial volume effects from the LV blood pool contributing to the high infarct T1. In this study, to estimate the reference T1 for true chronic infarcts, each infarct ROI was placed at the core of the infarct lesion, minimizing partial volume effects of LV blood pool and the surrounding myocardium as much as possible. This is in contrast to previous studies, which either reported T1 values of the entire planimetric infarct area (25) or of the whole myocardial segment (containing both infarct and surrounding myocardium) (15). While infarct T1 may be contaminated by higher LV blood pool T1 or lower surrounding myocardial T1, there were no significant correlations between these tissues in this



study. Moreover, an interesting observation is that the mean infarct age in our patients ( $71 \pm 70$  months) was higher than typically reported in the literature (usually  $\sim 6$  months) (13,15,25). Although myocardial scars form within 2 to 3 months post-infarction, the fibrotic process is known to continue beyond 6 months and may take years to complete (27). It is possible that the higher observed infarct T1 in this study, in the absence of lipomatous metaplasia, may potentially represent more extensive fibrotic remodeling with perhaps greater interstitial space expansion for potential water accumulation (leading to higher T1). However, this hypothesis cannot be fully addressed by the data in this study alone. The validation of chronic infarct T1 would strongly benefit from further studies to assess the impact of the partial volume effect, segmental versus regional ROI analysis, and infarct chronicity.

**ADENOSINE STRESS/REST T1 MAPPING AND HEART RATE VARIATIONS.** Adenosine stress can significantly increase the human heart rate by up to 30 to 40 beats/min in normal controls (1-3,12,23), which is a known confounder for many MOLLI-based T1

mapping techniques (13,25,26). We previously demonstrated that T1 estimation using the ShMOLLI technique is independent of heart rate variations (40 to 100 beats/min) over the applicable range of T1 values in phantoms and simulations at 1.5- and 3.0-T (13). Hence, any potential confounding effects due to technical heart rate dependencies on the findings in this study are negligible, and the observed T1 values most likely reflect true physiologic and

**TABLE 3 CMR Characteristics of Normal, Remote, Ischemic, and Infarcted Myocardial Tissue**

	Normal Controls (1.5-T)	Patients With CAD (1.5-T)		
		Remote	Ischemic	Infarct
Regional wall motion abnormalities	-	-	+	+
Myocardial perfusion reserve index	$2.0 \pm 0.2$	$1.9 \pm 0.5$	$1.1 \pm 0.3$	$1.0 \pm 0.2$
Late gadolinium enhancement	-	-	-	+
T1 value at rest, ms	$954 \pm 19$	$955 \pm 17$	$987 \pm 17$	$1,442 \pm 84$
T1 value at peak adenosine stress, ms	$1,013 \pm 23$	$992 \pm 22$	$989 \pm 24$	$1,445 \pm 107$
$\delta T1$ (% stress reactivity compared to rest)	$6.2 \pm 0.5$	$3.9 \pm 0.6$	$0.2 \pm 0.8$	$0.2 \pm 1.5$

Values are mean  $\pm$  SD.

CAD = chronic coronary artery disease; CMR = cardiac magnetic resonance.

**TABLE 4 T1 Profiles of Myocardial Tissue Based on Rest and Stress Native T1 Mapping**

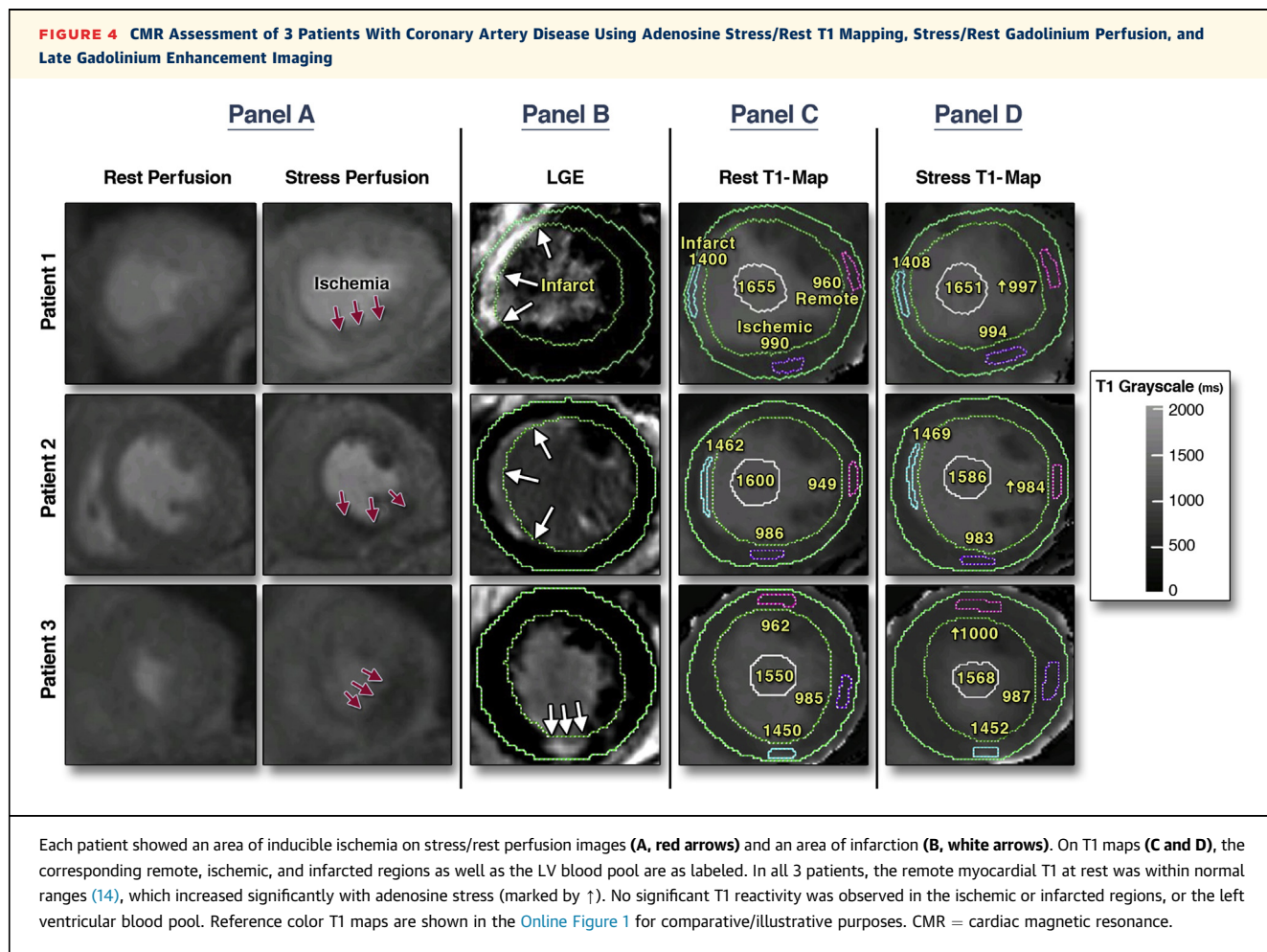
	Normal Controls	Patients With CAD		
		Remote	Ischemic	Infarct
Resting T1	Normal	Normal	↑	↑↑
ΔT1 (% stress reactivity compared to rest)	↑↑ (~6%)	↑ (~4%)	↔ (<1%)	↔ (<1%)

CAD = chronic coronary artery disease.

pathophysiologic changes in controls and patients, respectively. Given the multiple variants of available T1 mapping techniques, it is paramount that studies investigating relationships between resting heart rates and T1 between individuals (14) or stress heart rate responses within individuals are performed using T1 mapping techniques that are proven to be technically stable over the required T1 and heart rate

ranges (28). Overall, the relationship between stress/rest T1 estimation and heart rate is an interesting topic that requires further validation comparing different T1 mapping techniques.

**STUDY LIMITATIONS.** This small proof-of-principle study serves to illustrate the potential of stress and rest T1 mapping in differentiating myocardial tissue classes, and will benefit from a larger cohort to systematically investigate potential age or gender differences in myocardial T1 reactivity to vasodilatory stress. Our normal controls were younger and with a male predominance; however, comparing our findings to those of Mahmud et al. (23) (n = 16 normal controls, 50% male, 63.3 ± 3.4 years of age, rest T1 1,168 ± 27 ms, stress T1 1,238 ± 54 ms, T1 reactivity 6.0 ± 4.2%, 3-T), the normal T1 reactivity of ~6% appears to be independent of age and field strength. The tight normal range of T1 reactivity we observed also supports that any potential bias in the method would be small. Although hematocrit values were within





normal ranges in CAD patients in this study, larger hematocrit variations may be observed in wider clinical populations, which may confound native T1 measures and should be further investigated. Larger clinical and population-based studies would be useful to produce standardized ranges for  $\delta T_1$  and to further investigate any effects of unknown confounders. In this study, ROI were drawn away from the sub-endocardium to minimize partial volume effects; however, placement of ROI closer to the blood pool may be better for detection of subendocardial ischemia. In addition, patients with known and/or high pre-test probability for significant CAD were selected to show typical differences in T1 reactivity between ischemic, remote and infarcted myocardial tissues; future studies with blinded analysis are needed to fully establish sensitivities, specificities, and overall diagnostic accuracy of T1 mapping in patients with a range of pre-test probabilities for CAD, smaller subendocardial infarctions, mixed tissue classes (e.g., peri-infarct ischemia), and including correlations with invasive measures, such as coronary or fractional flow reserves.

## CONCLUSIONS

Adenosine stress and rest T1 mapping can differentiate between normal, infarcted, ischemic, and remote myocardial tissue classes with distinctive T1 profiles. Stress/rest T1 mapping on CMR holds

promise for ischemia detection without the need for gadolinium contrast.

**REPRINT REQUESTS AND CORRESPONDENCE:** Dr. Vanessa Ferreira, Division of Cardiovascular Medicine, Radcliffe Department of Medicine, University of Oxford, John Radcliffe Hospital, Headley Way, Oxford OX3 9DU, United Kingdom. E-mail: [vanessa.ferreira@cardiov.ox.ac.uk](mailto:vanessa.ferreira@cardiov.ox.ac.uk).

## PERSPECTIVES

**COMPETENCY IN MEDICAL KNOWLEDGE:** Adenosine stress and rest T1 mapping is a novel CMR technique that reflects changes in myocardial blood volume through its water content. This proof-of-principle study showed for the first time that stress and rest T1 mapping can differentiate between normal, infarcted, ischemic, and remote myocardium with distinctive T1 profiles, which holds promise for ischemia detection using CMR without the need for gadolinium contrast agents.

**TRANSLATIONAL OUTLOOK:** Future studies are needed to establish the diagnostic performance of stress/rest T1 mapping for detecting ischemia in patients with a range of pre-test probabilities for CAD compared to other tests for ischemia detection, and whether information provided by stress/rest T1 mapping can successfully guide targeted revascularization to improve clinical outcomes and long-term survival of patients with CAD.

## REFERENCES

1. Rieber J, Huber A, Erhard I, et al. Cardiac magnetic resonance perfusion imaging for the functional assessment of coronary artery disease: a comparison with coronary angiography and fractional flow reserve. *Eur Heart J* 2006;27:1465-71.
2. Lockie T, Ishida M, Perera D, et al. High-resolution magnetic resonance myocardial perfusion imaging at 3.0-Tesla to detect hemodynamically significant coronary stenoses as determined by fractional flow reserve. *J Am Coll Cardiol* 2011;57:70-5.
3. Salerno M, Beller GA. Noninvasive assessment of myocardial perfusion. *Circ Cardiovasc Imaging* 2009;2:412-24.
4. McCommis KS, Goldstein TA, Abendschein DR, et al. Roles of myocardial blood volume and flow in coronary artery disease: an experimental MRI study at rest and during hyperemia. *Eur Radiol* 2010;20:2005-12.
5. McCommis KS, Goldstein TA, Zhang H, Misselwitz B, Gropler RJ, Zheng J. Quantification of myocardial blood volume during dipyridamole and dobutamine stress: a perfusion CMR study. *J Cardiovasc Magn Reson* 2007;9:785-92.
6. McCommis KS, Zhang H, Goldstein TA, et al. Myocardial blood volume is associated with myocardial oxygen consumption: an experimental study with cardiac magnetic resonance in a canine model. *J Am Coll Cardiol Img* 2009;2:1313-20.
7. Le DE, Jayaweera AR, Wei K, Coggins MP, Lindner JR, Kaul S. Changes in myocardial blood volume over a wide range of coronary driving pressures: role of capillaries beyond the autoregulatory range. *Heart* 2004;90:1199-205.
8. Piechnik SK, Chiarelli PA, Jezzard P. Modelling vascular reactivity to investigate the basis of the relationship between cerebral blood volume and flow under CO2 manipulation. *Neuroimage* 2008;39:107-18.
9. Wacker CM, Bauer WR. [Myocardial microcirculation in humans—new approaches using MRI]. *Herz* 2003;28:74-81.
10. Lindner JR, Skyba DM, Goodman NC, Jayaweera AR, Kaul S. Changes in myocardial blood volume with graded coronary stenosis. *Am J Physiol* 1997;272:H567-75.
11. Firsche C, Andrassy P, Linka AZ, Busch R, Martinoff S. Adenosine myocardial contrast echo in intermediate severity coronary stenoses: a prospective two-center study. *Int J Cardvasc Imaging* 2007;23:311-21.
12. Arnold JR, Karamitsos TD, Bhamra-Ariza P, et al. Myocardial oxygenation in coronary artery disease: insights from blood oxygen level-dependent magnetic resonance imaging at 3 tesla. *J Am Coll Cardiol* 2012;59:1954-64.
13. Piechnik SK, Ferreira VM, Dall'Armellina E, et al. Shortened Modified Look-Locker Inversion recovery (ShMOLLI) for clinical myocardial T1-mapping at 1.5 and 3 T within a 9 heartbeat breathhold. *J Cardiovasc Magn Reson* 2010;12:69.
14. Piechnik SK, Ferreira VM, Lewandowski AJ, et al. Normal variation of magnetic resonance T1 relaxation times in the human population at 1.5 T using ShMOLLI. *J Cardiovasc Magn Reson* 2013;15:13.
15. Dall'Armellina E, Piechnik SK, Ferreira VM, et al. Cardiovascular magnetic resonance by non-contrast T1-mapping allows assessment of severity of injury in acute myocardial infarction. *J Cardiovasc Magn Reson* 2012;14:15.
16. Bull S, White SK, Piechnik SK, et al. Human non-contrast T1 values and correlation with histology in diffuse fibrosis. *Heart* 2013;99:932-7.
17. Dass S, Suttie JJ, Piechnik SK, et al. Myocardial tissue characterization using magnetic resonance noncontrast T1 mapping in hypertrophic and dilated cardiomyopathy. *Circ Cardiovasc Imaging* 2012;5:726-33.

18. Ferreira VM, Piechnik SK, Dall'Armellina E, et al. Non-contrast T1-mapping detects acute myocardial edema with high diagnostic accuracy: a comparison to T2-weighted cardiovascular magnetic resonance. *J Cardiovasc Magn Reson* 2012;14:42.
19. Ferreira VM, Piechnik SK, Dall'Armellina E, et al. T1 mapping for the diagnosis of acute myocarditis using CMR: comparison to T2-weighted and late gadolinium enhanced imaging. *J Am Coll Cardiol Img* 2013;6:1048-58.
20. Karamitsos TD, Piechnik SK, Banyersad SM, et al. Noncontrast T1 mapping for the diagnosis of cardiac amyloidosis. *J Am Coll Cardiol Img* 2013;6:488-97.
21. Ferreira VM, Piechnik SK, Dall'Armellina E, et al. Native T1-mapping detects the location, extent and patterns of acute myocarditis without the need for gadolinium contrast agents. *J Cardiovasc Magn Reson* 2014;16:36.
22. Sado DM, Maestrini V, Piechnik SK, et al. Non-contrast myocardial T mapping using cardiovascular magnetic resonance for iron overload. *J Magn Reson Imaging* 2014.
23. Mahmud M, Piechnik SK, Levelt E, et al. Adenosine stress native T1 mapping in severe aortic stenosis: evidence for a role of the intravascular compartment on myocardial T1 values. *J Cardiovasc Magn Reson* 2014;16:92.
24. Puntmann VO, Arroyo Ucar E, Hinojar Baydes R, et al. Aortic stiffness and interstitial myocardial fibrosis by native T1 are independently associated with left ventricular remodeling in patients with dilated cardiomyopathy. *Hypertension* 2014;64:762-8.
25. Messroghli DR, Walters K, Plein S, et al. Myocardial T1 mapping: application to patients with acute and chronic myocardial infarction. *Magn Reson Med* 2007;58:34-40.
26. Lee JJ, Liu S, Nacif MS, et al. Myocardial T1 and extracellular volume fraction mapping at 3 tesla. *J Cardiovasc Magn Reson* 2011;13:75.
27. Czubryt MP. Common threads in cardiac fibrosis, infarct scar formation, and wound healing. *Fibrogenesis Tissue Repair* 2012;5:19.
28. Moon JC, Messroghli DR, Kellman P, et al. Myocardial T1 mapping and extracellular volume quantification: a Society for Cardiovascular Magnetic Resonance (SCMR) and CMR Working Group of the European Society of Cardiology consensus statement. *J Cardiovasc Magn Reson* 2013;15:92.

---

**KEY WORDS** adenosine stress, cardiac magnetic resonance, ischemia, ShMOLLI, T1 mapping

---

**APPENDIX** For expanded Methods, Results, and References sections and a supplemental figure, please see the online version of this article.