



## CLINICAL CASE

## Endoscopic Treatment of Early Gastric Obstruction After Sleeve Gastrectomy: Report of Two Cases



Mariana Nuno Costa<sup>a,\*</sup>, Tiago Capela<sup>a</sup>, Isabel Seves<sup>a</sup>, Rui Ribeiro<sup>b</sup>, Ricardo Rio-Tinto<sup>a</sup>

<sup>a</sup> Gastroenterology Department, Centro Hospitalar de Lisboa Central, Lisbon, Portugal

<sup>b</sup> Surgery Department, Centro Hospitalar de Lisboa Central, Lisbon, Portugal

Received 11 May 2015; accepted 1 July 2015

Available online 12 September 2015

### KEYWORDS

Endoscopy,  
Gastrointestinal;  
Gastrectomy/adverse  
effects;  
Gastric Obstruction

**Abstract** Morbid obesity is an epidemic and complex disease which imposes a multidisciplinary approach. Laparoscopic sleeve gastrectomy has become a frequent procedure given its efficacy and safety compared to other surgical options. However, it isn't free from complications. Lax gastric fixation or incorrect positioning of the stomach during surgery can result in early gastric outlet obstruction caused by a volvulus-like mechanism by rotation of the stomach around its anatomic axes. This report refers to two cases of post sleeve gastric torsion resulting in persisting vomiting after initiating oral intake. The diagnosis was confirmed by upper gastrointestinal-contrast study and gastroscopy. In both cases, a fully covered self-expandable metallic stent was inserted which prompted the gastric lumen to become permeable resulting in symptomatic resolution. The stents were removed endoscopically after two and three months. Beyond more than three years of follow-up, the patients remain asymptomatic and no recurring "stenosis" was noticed. In these cases the use of fully covered self-expandable metallic stents demonstrated to be effective and safe in the treatment of post sleeve gastric torsion.

© 2015 Sociedade Portuguesa de Gastreenterologia. Published by Elsevier España, S.L.U. This is an open access article under the CC BY-NC-ND license (<http://creativecommons.org/licenses/by-nc-nd/4.0/>).

### PALAVRAS-CHAVE

Endoscopia  
Gastrointestinal;  
Gastrectomia/efeitos  
adversos;  
Obstrução Gástrica

### Tratamento Endoscópico da Obstrução Gástrica Precoce Após Gastrectomia Tubular: Relato de Dois Casos

**Resumo** A obesidade mórbida é uma doença epidémica complexa, que impõe uma abordagem multidisciplinar. A gastrectomia vertical laparoscópica tornou-se um procedimento frequentemente utilizado dada a sua eficácia e segurança em comparação com outras opções cirúrgicas. Contudo não é isenta de complicações. A fixação gástrica mais laxa ou o posicionamento

\* Corresponding author.

E-mail address: [mariananunocosta@gmail.com](mailto:mariananunocosta@gmail.com) (M.N. Costa).

incorreto do estômago durante a cirurgia pode resultar em obstrução gástrica precoce após a cirurgia, que é provocada por um mecanismo semelhante ao do volvo – por rotação do estômago em torno do seu próprio eixo anatômico. Apresentam-se dois casos de torção gástrica pós gastrectomia tubular, resultando em vômitos persistentes depois do início da dieta oral. O diagnóstico foi confirmado por estudo contrastado gastrointestinal e gastroscopia. Em ambos os casos, foram colocadas próteses metálicas auto-expansíveis totalmente cobertas, restituindo a permeabilidade do lúmen gástrico com resolução sintomática. As próteses foram removidas endoscopicamente ao fim de 2 e 3 meses. Após mais de 3 anos de seguimento, os doentes permanecem assintomáticos e não se verificou “estenose” recorrente. Nestes casos, o uso de próteses metálicas auto-expansíveis totalmente cobertas demonstrou ser eficaz e seguro no tratamento da torção gástrica pós gastrectomia tubular.

© 2015 Sociedade Portuguesa de Gastrenterologia. Publicado por Elsevier España, S.L.U. Este é um artigo Open Access sob a licença de CC BY-NC-ND (<http://creativecommons.org/licenses/by-nc-nd/4.0/>).

## 1. Introduction

Morbid obesity is an epidemic and complex disease which imposes a multidisciplinary approach. Laparoscopic sleeve gastrectomy (LSG) has become a frequent procedure given its efficacy and safety compared to other surgical options. The most common complications are staple line bleeding, strictures that are usually located at the middle or distal portion of the residual stomach, and leaks, which are the most severe and life-threatening.<sup>1</sup> Lax gastric fixation or incorrect positioning of the stomach during surgery can result in early gastric outlet obstruction (EGOO) caused by a volvulus-like mechanism by rotation of all or part of the stomach around its anatomic axes<sup>2</sup> (Fig. 1). We have managed two cases of EGGO, 10 and 24 days after LSG. Both patients suffered from persisting vomiting after initiating oral intake.

## 2. Case report

**Patient one:** A 24-year-old male, longstanding morbidly obese, body mass index (BMI) of 41.8 kg/m<sup>2</sup>, underwent a LSG. The patient was hospitalized for five days with no signs or symptoms of postoperative adverse events. Ten days after LSG, he was admitted with persisting vomits.

**Patient two:** A 25-year-old obese female, with a BMI of 32.3 kg/m<sup>2</sup>, underwent a LSG. There were no technical adverse events. The immediate postoperative period was incident-free and she was discharged four days after surgery. She was admitted with alimentary vomits 20 days after having been discharged.

Gastrografen fluoroscopy revealed gastric “stenosis” in both cases, due to torsion over the main axis of the stomach (Fig. 2). The upper endoscopy showed a widened gastric lumen followed by a rotated segment located at mid-body, resulting in a short “stenosis” (Fig. 3). A fully covered self-expandable metallic stent was used in both cases (Taewoong Niti-S® 28/80mm – patient 1; Boston Scientific Wallflex® 23/105 mm – patient 2; Fig. 4). In both cases, fixation with

endoscopic clips was not required nor any other sort of stent fixation device. The endoscopic procedure prompted the gastric lumen to become permeable resulting in immediate symptomatic resolution. Both patients were discharged on the following day.

After two and three months (patient 1 and patient 2 respectively) the stents were removed by endoscopy on an ambulatory basis. The stents were correctly positioned and no signs of stent migration were noticed. Rat tooth grasping forceps were used to gently pull the proximal end of the stent. Stent removal was easy and only mild and self-limited bleeding was noticed after the procedure.

After over three years of follow-up, the patients remain asymptomatic and no recurring “stenosis” was noticed.



**Figure 1** Schematic representation of gastric torsion.

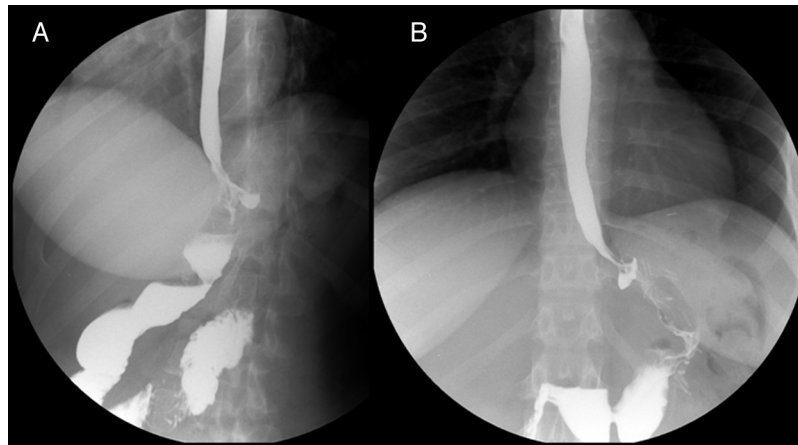


Figure 2 Upper GI-contrast study showing slight flow of contrast in gastric body (A, B).

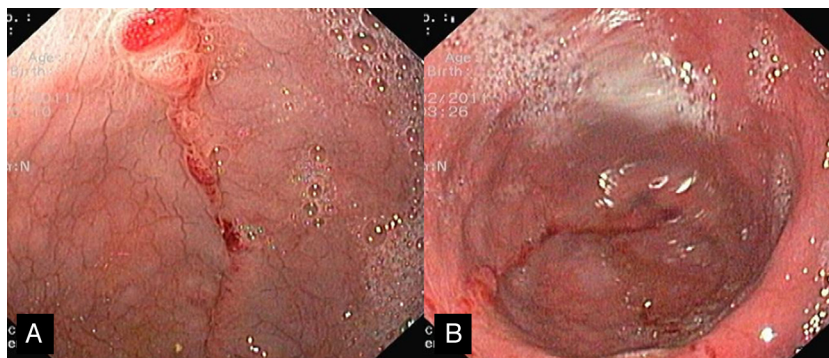


Figure 3 Widened gastric lumen (A) followed by a rotated segment located at mid-body of the stomach (B).

### 3. Discussion

LSG has emerged as a reproducible successful and efficient surgical technique for long-term weight loss stability with regression of most major associated comorbidities.<sup>3</sup> The complication rate for LSG has been described to be 2.9 up to 15.3%.<sup>4</sup> Obstruction after laparoscopic sleeve gastrectomy

is rare but requires early diagnosis and treatment due to a significantly increased morbidity.

The obstruction can result from an anatomical stricture of the gastric tube or from gastric tube's functional obstruction due to twisting by a volvulus-like mechanism. The twisting may occur by misalignment of the staples in the same plane or by the indentation of the incisura within

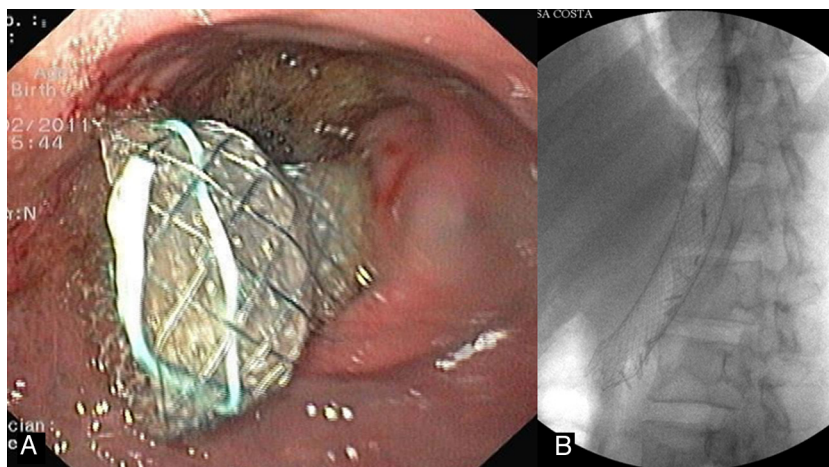


Figure 4 Endoscopic (A) and fluoroscopic (B) view of fully covered self-expandable metallic stent *in situ*.

the gastric lumen, which creates a flap valve producing a functional EGOO. Another cause of obstruction is adhesions of the gastric serosa thappening later on.<sup>3</sup>

Few reports of EGOO after LSG related to this mechanism have been published.<sup>2-7</sup> In one of these cases,<sup>6</sup> a Polyflex® covered esophageal stent (Boston Scientific, Natick, MA, USA) was inserted under fluoroscopic guidance. However the stent migrated up into the esophagus and required surgical removal. The remaining cases were surgically sorted out.

In these cases the use of fully covered self-expandable metallic stents demonstrated to be effective and safe in the treatment of post sleeve gastric torsion. EGOO is a functional gastric tube obstruction that may recur. However, in the reported cases the patients remained asymptomatic during a follow-up of at least three years.

The excellent short-term outcome was expected given that the stents insertion prompted the gastric lumen patency. The good long-term outcome was less expectable and was probably due to the induction of ulceration and fibrosis in the gastric torsion inducing a permanent gastric tunnel.

In case of therapeutic failure these patients would be candidates to surgery aiming to convert the sleeve gastrectomy into a gastric bypass.

## Ethical disclosures

**Protection of human and animal subjects.** The authors declare that no experiments were performed on humans or animals for this study.

**Right to privacy and informed consent.** The authors declare that no patient data appear in this article.

**Confidentiality of data.** The authors declare that they have followed the protocols of their work center on the publication of patient data.

## Conflict of interest

The authors have no conflicts of interest to declare.

## References

1. Dakwar A, Assalia A, Khamaysi I, Kluger Y, Mahajna A. Late complication of laparoscopic sleeve gastrectomy. *Case Rep Gastrointest Med.* 2013;2013:136–53.
2. Del Castillo Déjardin D, Sabench Pereferrer F, Hernández González M, Blanco Blasco S, Cabrera Vilanova A. Gastric volvulus after sleeve gastrectomy for morbid obesity. *Surgery.* 2013;153:431–3.
3. Burgos AM, Csendes A, Braghetto I. Gastric stenosis after laparoscopic sleeve gastrectomy in morbidly obese patients. *Obes Surg.* 2013;23:1481–6.
4. Bellorin O, Lieb J, Szomstein S, Rosenthal RJ. Laparoscopic conversion of sleeve gastrectomy to Roux-en-Y gastric bypass for acute gastric outlet obstruction after laparoscopic sleeve gastrectomy for morbid obesity. *Surg Obes Relat Dis.* 2010;6:566–8.
5. Ferrer JV, Sanahuja Á, Pérez-folqués E, Saiz N, Cester D. Gastric obstruction on the plication of Gastric Sleeve. *Video. BMI.* 2011;5:354–5.
6. Parikh A, Alley JB, Peterson RM, Harnisch MC, Pfluke JM, Tapper DM, et al. Management options for symptomatic stenosis after laparoscopic vertical sleeve gastrectomy in the morbidly obese. *Surg Endosc.* 2012;26:738–46.
7. Uglioni B, Wölnerhanssen B, Peters T, Christoffel-Courtin C, Kern B, Peterli R. Midterm results of primary vs. secondary laparoscopic sleeve gastrectomy (LSG) as an isolated operation. *Obes Surg.* 2009;19:401–6.