

Original Article

Short-term Venous Patency after Implantation of Permanent Pacemakers or Implantable Cardioverter Defibrillators

Takeshi Nakae MD*¹, Yoshihisa Enjoji MD*², Mahito Noro MD*¹, Kaoru Sugi MD*¹

*¹Division of Cardiovascular Medicine, Department of Internal Medicine, Toho University Ohashi Medical Center

*²Division of Electrophysiological Lab. Cardiovascular Center, Kyoto Katsura Hospital

There is little information on venous patency after pacing leads are inserted in veins during pacemaker or implantable cardioverter defibrillator (ICD) implantation. Herein we present a report on venous patency during the immediate postoperative period after permanent pacemaker or ICD implantation.

Subjects and Methods: Twenty-five patients underwent a permanent pacemaker or ICD implantation by venous puncture method, and venography was performed 1 week later. We assessed the pacemaker-implantation side, approach used, implanted device, number of implanted leads, and clinical symptoms.

Results: Narrowing of the vein was found in 14 patients (56%), including 7 patients (28%) with occlusion. Stenosis and occlusion were seen more in patients with left-sided implantation than those with right-sided implantation (71% vs. 25%, $P < 0.05$). ICD implantation was more frequently associated with venous stenosis or occlusion than pacemaker implantation (65% vs. 37.5%, $P < 0.05$). The approach used and the number of leads implanted did not correlate with venous stenosis or occlusion. Six of the 7 patients who developed complete occlusion showed clinical symptoms.

Conclusion: Thrombus formation after pacemaker implantation can occur in the acute stage within 1 week. The incidence of venous stenosis or thrombus formation was higher with left-sided implantation and ICD.

(J Arrhythmia 2010; 26: 30–37)

Key words: Pacemaker, Implantable cardioverter defibrillator, Venography

Introduction

Currently, implantable cardioverter defibrillators (ICDs) are widely used to prevent sudden cardiac death due to cardiac arrest, and permanent pacemakers are usually implanted for bradycardia-related disorders.

To ensure the safety of pacemaker implantation, attempts should be made to prevent the development of complications, such as pneumothorax, by performing preoperative venography. In addition, we can confirm the abnormal location or course of a blood vessel while performing ICD insertion maneuvers.¹⁾ Even if preoperative venography confirms the

Received 27, July, 2009; accepted 13, January, 2010.

Address for correspondence: Takeshi Nakae MD, Division of Cardiovascular Medicine, Department of Internal Medicine, Toho University Ohashi Medical Center, 2-17-6 Ohashi Meguro-ku, Tokyo 153-8515 Japan. Tel: +81-3-3468-1251 Fax: +81-3-3468-1269

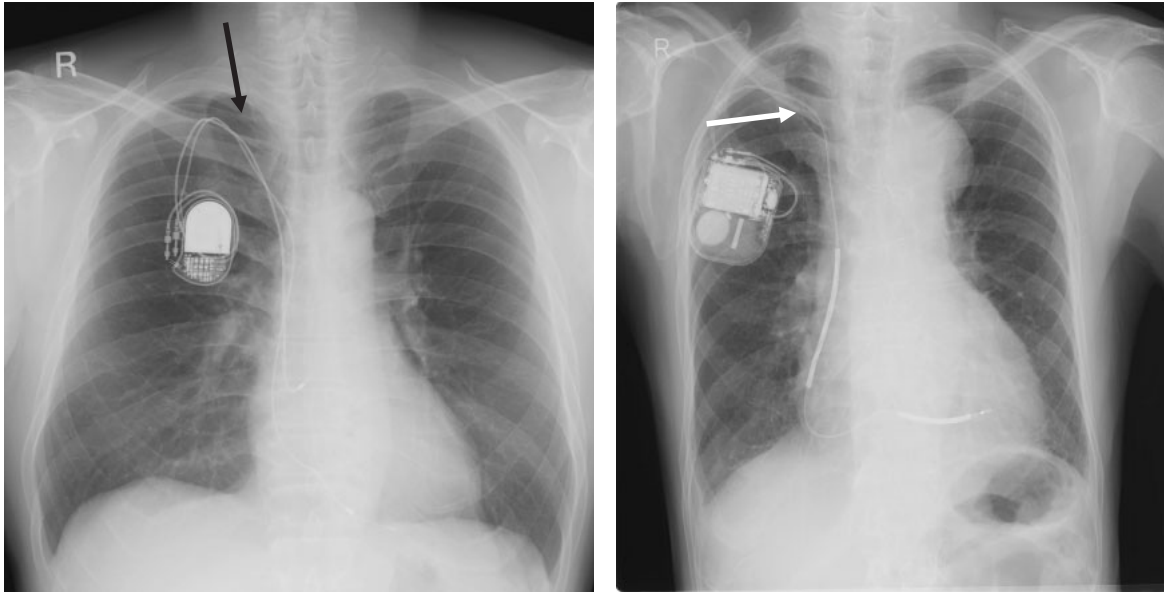


Figure 1 Differences in lead run configuration between the supraclavicular and subclavicular approaches
 Left: supraclavicular approach, Right: subclavicular approach
 Venous puncture was performed at the site indicated with an arrow.

absence of vein occlusion or stenosis, we occasionally experience cases with long-term venous occlusion or stenosis due to permanent pacemaker or ICD implantation.²⁻⁶⁾ However, it has not yet been clarified which factors are associated with stenosis or occlusion of the vein containing the pacemaker leads. There is little information about post-implantation condition of veins in patients after permanent pacemaker or ICD implantation.^{7,8)} Therefore, we examined venous patency during the immediate postoperative period after permanent pacemaker or ICD implantation in patients who were implanted with a device for the first time.

Subjects and Method

We investigated 25 patients who underwent permanent pacemaker or ICD implantation at Toho University Ohashi Medical Center for treatment of symptomatic bradycardia or as a preventive measure against sudden cardiac death due to cardiac arrest. There were 18 males and 7 females, with an average age of 65 years. They included 17 patients with ICD implantation and 8 patients with pacemaker implantation. All patients underwent surgery using the venous puncture method. The supraclavicular approach technique involves puncture of the subclavian vein at the supraclavicular fossa, and the subclavicular approach technique involves puncture of the subclavian vein inferior to the midpoint of the clavicle (**Figure 1**).

To assess the presence of a venous stenosis or occlusion caused by thrombus formation, venography was performed 1 week later through a peripheral vein in the arm on the device-implanted side using 20 ml of iopamil as a contrast medium. We explained the venography procedure to 35 consecutive patients but 10 of the patients refused contrast medium administration. Twenty-five of the 35 patients agreed to undergo the venography. Therefore this study did not include consecutive patients. All enrolled patients provided informed consent for the procedures.

We assessed sex, age, underlying diseases, lead diameter, the pacemaker-implanted side (left or right), the approach (supraclavicular or subclavicular), the implanted device (pacemaker or ICD), the number of implanted leads, and the patient's clinical symptoms.

The implanted devices were as follows: KDR701, KDR703 and KSR701 (Kappa700) permanent pacemakers, and 7229CX (gen) and 7273 (gen) ICDs (Medtronic Inc.); 5332, 5338, and 2405 MS permanent pacemakers (St. Jude Medical), and 1381 and 1480 permanent pacemakers (Guidant). All of the lead materials were made of silicon.

A serum creatinine value of > 2.0 mg/dl was considered a contraindication for the use of contrast material because such a value is suggestive of renal dysfunction. However, no patient in this study had a serum creatinine level of > 2.0 mg/dl.

There was a difference in the lead run configuration between the supraclavicular and subclavicular approaches (**Figure 1**).

Table 1 Characteristics and parameters

number	sex	age	underlying disease	Type of device	Number of lead	lead diameter (F)	insertion site	puncture site
1	M	82	VT	ICD (DDD)	2	7, 9	L	I
2	M	62	VT	ICD (DDD)	2	9, 9	L	S
3	F	57	AVB	PM (DDD)	2	8, 8	L	S
4	M	90	AVB	PM (DDD)	2	7, 7	R	S
5	M	51	SSS	PM (DDD)	2	8, 8	R	S
6	F	82	AVB	PM (DDD)	2	8, 8	R	S
7	M	71	Brugada synd.	ICD (VVI)	1	11	L	S
8	M	69	VT	ICD (DDD)	2	9, 11	L	I
9	M	80	AVB	PM (DDD)	2	8, 8	R	S
10	M	66	VF	ICD (DDD)	2	9, 11	L	I
11	M	38	AVB	PM (DDD)	2	8, 8	L	S
12	M	74	VF	ICD (DDD)	2	9, 11	L	I
13	M	75	VT	ICD (VVI)	1	11	R	I
14	M	68	VT	ICD (DDD)	2	9, 9	L	S
15	M	32	VT	ICD (DDD)	2	9, 9	L	I
16	M	42	VF	ICD (DDD)	2	7, 9	L	S
17	F	62	VT,	ICD (VVI)	1	11	L	I
18	F	64	SSS	PM (DDD)	2	9, 9	R	S
19	M	70	VT	ICD (VVI)	1	9	L	I
20	F	69	VF	ICD (DDD)	2	9, 9	L	S
21	F	68	Brugada synd.	ICD (VVI)	1	9	R	I
22	M	57	VT	ICD (VVI)	1	9	L	S
23	F	69	AVB	PM (DDD)	2	8, 8	R	S
24	M	59	Brugada synd.	ICD (VVI)	1	9	L	I
25	M	62	VF	ICD (VVI)	1	9	L	I

VT: Ventricular tachycardia, AVB: Atrioventricular block, SSS: Sick sinus syndrome, VF: Ventricular fibrillation, ICD: Implantable cardioverter defibrillator, PM: Pacemaker, L: Left, R: Right, I: subclavicular approach, S: supraclavicular approach

There were no patients with persistent or paroxysmal atrial fibrillation. All of the patients with sick sinus syndrome were type II.

Lesions having a reduction in diameter of greater than 75% were defined as “stenoses”, and lesions with complete disruption as “occlusions”.

Statistical analyses were performed using the chi-square test with clinical manifestation as the parameter. A P value < 0.05 was considered clinically significant.

Results

The analysis data of the 25 patients in whom we obtained results are shown in **Tables 1** and **2**.

The pacemakers and ICDs were implanted from the left side of the chest in 17 patients, and from the right side in 8 patients. Needle puncture to insert the pacing leads was performed using the supraclavicular approach in 14 patients and the subclavicular approach in 11 patients. A single lead was implanted

in 8 patients, and 2 leads for atrial and ventricular pacing in 17 patients. The details are outlined in **Table 3**.

The details of the 17 patients in whom needle puncture was performed on the left side are presented in **Figure 2**, while those of the 8 patients in whom the puncture was performed from the right side are shown in **Figure 3**.

Narrowing of the vein far from the puncture site was found in 14 patients (54%) (**Table 4**). The venous stenosis image is shown in **Figure 4**. This patient was an 82-year-old male, with idiopathic ventricular tachycardia. He was implanted a 2-lead ICD using the left subclavicular approach. A venous stenosis developed far from the puncture site 1 week after implantation. A complete occlusion occurred in 7 patients (28%); in five of these patients, collateral circulation had developed. Patients with a left-sided implantation had more stenosis or occlusion than those with a right-sided implantation (71% vs. 25%, P < 0.05). ICD implantation was more closely

Table 2 Clinical symptoms and venography 1 week after the implantation

number	clinical manifestation	Radiologic finding after one week
1	EUL	complete obstruction, collateral (+)
2	nothing	stenosis,
3	nothing	stenosis
4	nothing	not particular
5	nothing	NP
6	nothing	NP
7	nothing	stenosis
8	SB, EUL	complete obstruction, collateral (+)
9	nothing	stenosis
10	SB	stenosis
11	nothing	stenosis
12	nothing	complete obstruction, collateral (+)
13	SB, EUL	complete obstruction, collateral (+)
14	nothing	NP
15	nothing	NP
16	nothing	NP
17	SB, EUL	complete obstruction, collateral (+)
18	nothing	NP
19	SB	NP
20	nothing	NP
21	nothing	NP
22	SB	complete obstruction, collateral (-)
23	nothing	NP
24	EUL	complete obstruction, collateral (-)
25	nothing	stenosis

EUL: Edema of upper limb, SB: Subcutaneous bleeding, NP: Not particular

Table 3 Distribution by puncture site, device, and lead numbers in 25 patients

Insertion	L/R	17/8
Puncture	S/I	14/11
Device	ICD/PM	17/8
Lead number	2/1	17/8

There were 17 patients in whom implantation had been performed from the left side. A subclavicular approach was used in 11 of these patients.

L: Left, R: Right, S: supraclavicular approach, I: subclavicular approach, ICD: Implantable cardioverter defibrillator, PM: Pacemaker

associated to venous stenosis or occlusion than was pacemaker implantation (65% vs. 37.5%, $P < 0.05$). The approach used and the number of leads implanted did not correlate with venous stenosis or occlusion. Of the 7 patients who developed a complete occlusion at the central site of the puncture in the vein, 6 showed clinical symptoms such as pain in the arm. One patient in whom collateral circulation had effectively developed did not complain of any occlusion-related symptoms.

All 7 patients with occlusion were implanted with ICDs, and they consisted of 41% of the 17 cases with ICD implantation. There was no significant correlation between the number of leads used and venous occlusion. However, occlusions appeared in patients who were implanted with a 9F or larger lead. Occlusions were more frequent in the left-side implantation group (86%), and in the subclavicular approach group (86%).

Discussion

Short-term follow-up venography 1 week after pacemaker implantation by venous puncture in order to evaluate venous stenosis and occlusion has not been reported previously. One week after the pacemaker implantation, 7 patients (28%) had venous occlusion. None of the patients had a venous stenosis or occlusion at the puncture site, but it occurred at a site central to the puncture in each instance.

Severe stenosis or complete occlusion of the subclavian vein after pacemaker implantation has been reported in 15–65% of cases.^{9–16)} The incidence

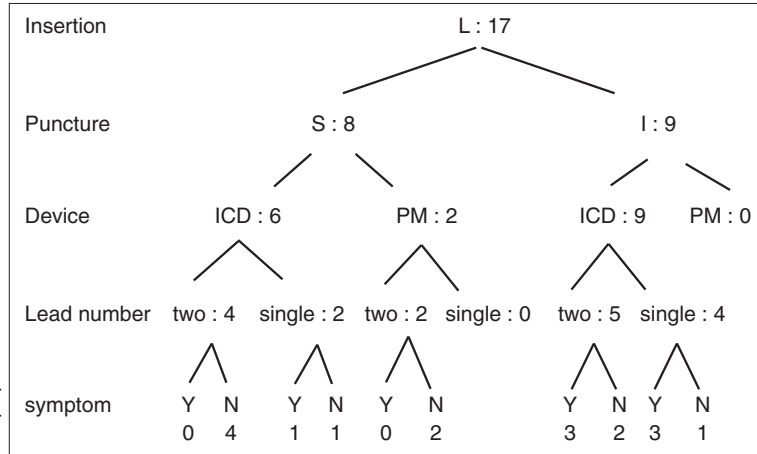


Figure 2 Distribution by puncture site, device, and lead number, in 17 patients with the device inserted from the left side. The subclavicular approach was used in 9 of these patients. An ICD was implanted in all of these patients.

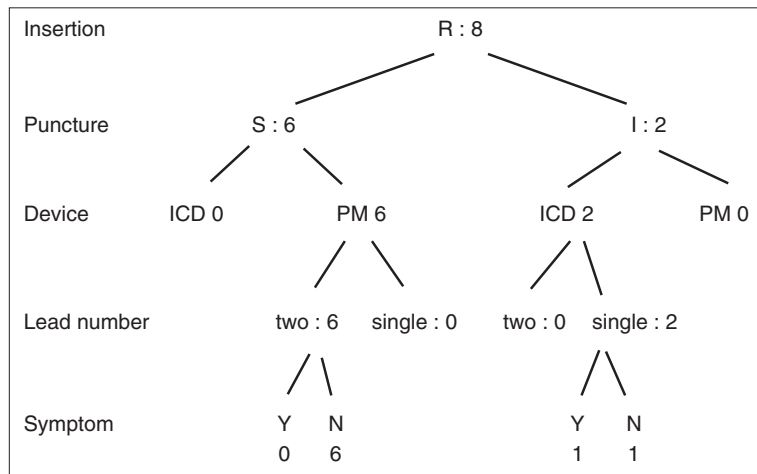


Figure 3 Distribution by puncture site, device, and lead number, in 8 patients in whom the device was inserted from the right side. The supraclavicular approach was used in 6 of these patients. A pacemaker was implanted in all of these patients.

Table 4 Differences in puncture site, device, and lead number, among 14 patients who developed thrombus.

Insertion	L/R	12/2	P < 0.05
Puncture	S/I	6/8	NS
Device	ICD/PM	11/3	P < 0.05
Lead number	2/1	8/6	NS
Occlusion in 7 cases			
Clinical symptom	Yes/No	6/1	P < 0.01

There was a significant increase in venous stenosis among the left-sided pacemaker and implantable cardioverter defibrillator (ICD) implanted patients.

L: Left, R: Right, S: supraclavicular approach, I: subclavicular approach, ICD: Implantable cardioverter defibrillator, PM: Pacemaker, NS: Not Significant

of acute venous thrombosis following pacemaker implantation is reportedly low,¹⁷⁾ while that of chronic thrombotic occlusion of the subclavian vein

or inferior vena cava is 0.35–0.5%.^{18,19)} In the present study, venous stenosis or occlusion developed in 56% of patients within 1 week after pacemaker implantation; the subclavicular approach was performed in 32% of the patients, and the supraclavicular approach, in 24%. There were no significant differences in venous stenosis among the groups based on the approach used.

The reported risk factors for thrombosis leading to stenosis include pacing mode, implantation site, multiple leads, hormone therapy, prior history of venous thrombosis, temporary pre-operative pacemaker use, and infections.^{9–11,17,20,21)} Some reports have suggested an increased risk in venous thrombosis following implantation of a 2-lead DDD pacemaker,^{20,22)} whereas other reports have shown no correlation of thrombosis with the number of leads used.^{23,24)} Therefore, the number of leads is not considered to have a direct effect. Our results showed no significant differences in risk among the

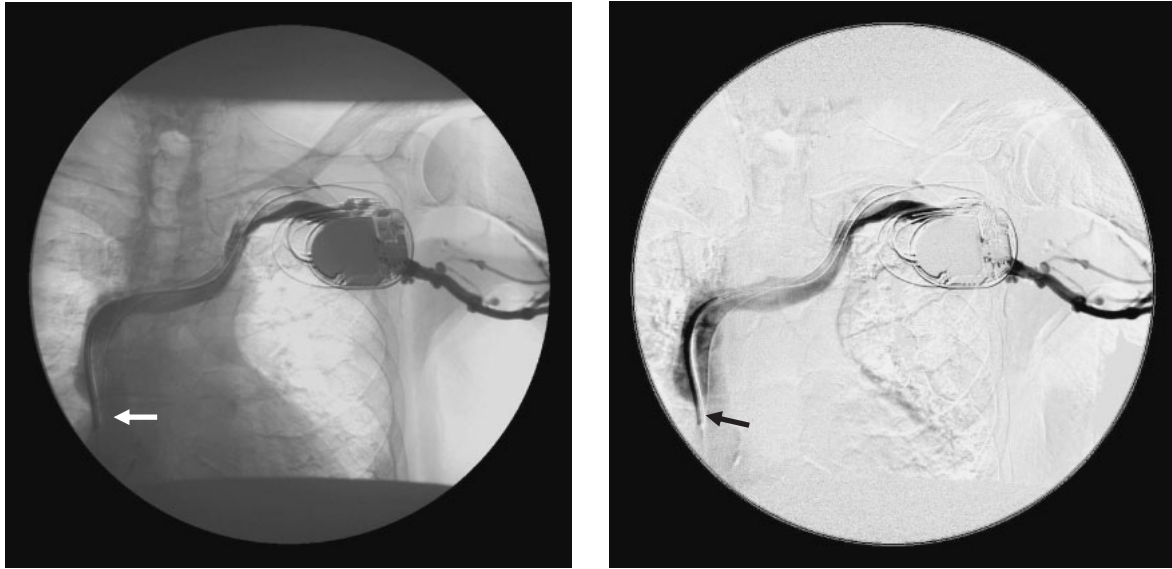


Figure 4 Occlusion of the vein.

An 82-year-old, male, with idiopathic ventricular tachycardia. A 2-lead ICD was implanted from the left side using the subclavicular approach. Venous stenosis occurred central to the puncture site, as shown in the venography performed 1 week after the implantation. Left: venography, Right: digital subtraction angiography

groups based on the number of leads. Our results indicate that ICD-implanted patients tend to develop a venous stenosis or occlusion more frequently than pacemaker-implanted patients. This may be due to the fact that the diameter of the ICD lead is larger than that of the pacemaker'.

Venous stenosis occurred with a significantly greater frequency in the left-sided than right-sided implantation. A higher occlusion rate with left-sided implantation than with right-sided implantation has been reported to be due to longer leads, which are used for anatomical reasons, and increased contact area within the vein.¹⁰⁾ Our study also showed a significantly higher occlusion rate in patients with left-sided implantation, and this may be attributed to longer leads and increased vein contact area required for left-sided implantation.

In addition, vessel lead tension differs from right-sided implantation in the anatomic perspective. With left-sided implantation, there may be increased irritation due to greater mechanical pressure between the lead and vein wall. There are also anatomical differences between the left and right brachiocephalic veins; the left brachiocephalic vein is longer and runs nearly horizontally. Therefore, while the right brachiocephalic vein joins the superior vena cava in a gentle arc, the left brachiocephalic vein joins the superior vena cava at an obtuse angle, which causes increased mechanical pressure in the latter case. ICDs were implanted from the left side in more patients, and this may have influenced the results.

Venous blood stagnation is also a factor in thrombus formation. When blood flow is almost zero, plasma factor IX is activated by factor IX-activating enzyme in red blood cell membranes, and the intrinsic coagulation reaction is activated.²⁵⁾ Because erythrocyte activation of factor IX and blood-clotting reactions are promoted by individual red blood cells with decreased shear flow,²⁵⁾ veins with pacemaker leads are more prone to thrombus formation.

In this study, leads were inserted by venous puncture in all patients. Lesions were located in the vein at locations central to, and far removed from, the puncture sites, suggesting that the surgical technique did not substantially contribute to the venous stenosis.

Although high rates of subclavian vein stenosis after pacemaker implantation have been reported, the incidence of clinical manifestations such as upper limb edema is relatively low at about 5%.^{10,11,14,16,26)} In the present study, during the acute stage within 1 week after surgery, 6 of the 7 patients with a venous occlusion developed upper limb edema and/or subcutaneous bleeding; however, one patient had no clinical manifestations. Furthermore, some patients with superior vena cava syndrome, have not been reported to have any symptoms.^{5,27,28)}

Based on the standard principle of performing pacemaker implantation on the side of the non-dominant arm, many medical facilities use the left-sided approach. Thus, the risk for venous stenosis

may be high in many patients with a pacemaker. With aging of the population, numerous patients will require long-term devices such as pacemakers. In addition to the replacement of pacemaker batteries, leads will also have to be replaced to increase device longevity. In such patients, future reimplantation may be necessary. Considering this future need for reimplantation, a right-sided approach might be preferable for implanting the initial device.

Hypercoagulability after pacemaker implantation has been reported.^{12,29-32)} Even among patients with normal subclavian veins, elevated levels of thrombin-antithrombin complex (TAT) and D-dimer have been reported,^{29,30)} which can lead to other thrombotic complications, including pulmonary embolism. Indeed, high rates of thrombotic complications, including pulmonary embolism, have been reported after pacemaker implantation.²³⁾ Although some thrombotic disorders cannot be identified by routine hematologic data alone, because of potential thrombotic complications after pacemaker implantation, elevated TAT and D-dimer levels have been suggested as predictive factors for subclavian vein thrombosis.³³⁾ However, TAT and D-dimer levels were not measured in the present study.

Our study did not evaluate the effects of antiplatelet or anticoagulant drugs on venous thrombosis. However, given the hypercoagulable state and the high incidence of subclavian vein thrombosis that often occurs after pacemaker implantation, the use of antiplatelet or anticoagulant drugs may be recommended.

Limitations

This study did not evaluate the effects of antiplatelet or anticoagulant drugs on venous thrombosis. In addition, we did not evaluate coagulation abnormalities during the short postoperative period or the level of TAT, D-dimer, and the thrombosis originate factor.

Prior to venography, informed consent was obtained from all patients included in this study. However, many patients did not agree to undergo venography because of the risk of side effects and the adverse effects related to administering a contrast agent. Therefore, the number of cases available for evaluation was somewhat low.

The implantation side was chosen based on the operator's expertise. Therefore, we did not randomly select the side, which may have caused the difference between the left and right sides.

Venography was not performed before implanting the pacemakers or ICDs. Therefore, a venous

stenosis might have been found before the operation in some cases.

Multivariable analysis could not be performed because the number of variable samples were small. A further study with a larger sample size is warranted. A long-term follow-up of our patient series would also provide additional information.

Conclusion

Venous stenosis or occlusion developed in 56% of the patients during the acute stage within 1 week after pacemaker implantation. However, venous stenosis or occlusion did not occur at the puncture site, but developed at sites central to the puncture. The incidence of venous stenosis or thrombus formation was significantly higher with left-sided implantation and implantation of ICD. Even with cases of venous occlusion with thrombus formation, no clinical manifestations could be observed due to the development of collateral blood circulation.

References

- 1) Abe Y, Kadowaki K, Munehisa M, et al: Contrast venography prior to permanent pacemaker implantation. *J Arrhythmia* 2003; 19: 25-29 [in Japanese]
- 2) Melzer C, Lembcke A, Ziemer S, et al: Pacemaker-induced superior vena cava syndrome: clinical evaluation of long-term follow-up. *Pacing Clin Electrophysiol* 2006; 29: 1346-1351
- 3) Park HW, Kim W, Cho JG, et al: Multiple pacing lead-induced superior vena cava syndrome: successful treatment by balloon angioplasty. *J Cardiovasc Electrophysiol* 2005; 16: 221-223.
- 4) Sako H, Hadama T, Shigemitsu O, et al: An implantation of DDD epicardial pacemaker through ministernotomy in a patient with a superior vena cava occlusion. *Pacing Clin Electrophysiol* 2003; 26: 778-780
- 5) Lanciego C, Rodriguez M, Rodriguez A, et al: Permanent pacemaker-induced superior vena cava syndrome: successful treatment by endovascular stent. *Cardiovasc Intervent Radiol* 2003; 26: 576-579
- 6) Slonim SM, Semba CP, Sze DY, et al: Placement of SVC stents over pacemaker wires for the treatment of SVC syndrome. *J Vasc Interv Radiol* 2000; 11: 215-219
- 7) Antonelli D, Turgeman Y, Kaveh Z, et al: Short-term thrombosis after transvenous permanent pacemaker insertion. *Pacing Clin Electrophysiol* 1989; 12: 280-282
- 8) Spittell PC, Hayes DL: Venous complications after insertion of a transvenous pacemaker. *Mayo Clin Proc* 1992; 67: 258-265
- 9) Yamada M, Sekiguchi S, Narisawa T: The effects of long-term transvenous pacemaker lead on venous routs: assessments by venography and pathological findings. *Jpn J Phlebol* 1994; 5: 57-61 [in Japanese]
- 10) Shirakawa H, Shimizu T, Aida H: The incidence of venous thrombosis and asymptomatic pulmonary embo-

- lism following long-term transvenous pacing. *Jpn J Cardiac Pacing Electrophysiol* 1992; 18: 556–562 [in Japanese]
- 11) Nomura H, Ninomiya K, Matsuzaki H: Venous disturbance (stenosis or occlusion) following long-term transvenous pacing. *Jpn J Cardiac Pacing Electrophysiol* 1994; 10: 526–529 [in Japanese]
 - 12) Ito T, Tanouchi J, Nishino M: The relationship between venous thrombosis and hypercoagulability after permanent transvenous pacemaker implantation. *Jpn J Cardiac Pacing Electrophysiol* 1995; 11: 47–50 [in Japanese]
 - 13) Goto Y, Abe T, Sekine S, Sakurada T: Long-term thrombosis after transvenous permanent pacemaker implantation. *Pacing Clin Electrophysiol* 1998; 21: 1192–1195
 - 14) Stoney WS, Addestone RB, Alford WC Jr, et al: The incidence of venous thrombosis following long-term transvenous pacing. *Ann Thorac Surg* 1976; 22: 166–170
 - 15) Kondo N, Bando S, Kinoshita M: The study on the incidence of subclavian venous thrombosis and the changes of blood coagulation in the cases with transvenous permanent pacemaker implantation. *Cardioangiolog* 1997; 42: 66–70 [in Japanese]
 - 16) Hondo T, Teragawa H, Munemori M: A study on subclavian venous thrombosis and pulmonary embolism in patients with permanent pacemaker. *J Hiroshima Med Ass* 1997; 50: 918–920 [in Japanese]
 - 17) Rozmus G, Daubert JP, Huang DT, Rosero S, et al: Venous thrombosis and stenosis after implantation of pacemakers and defibrillators. *J Interv Card Electrophysiol* 2005; 13: 9–19
 - 18) McCotter CJ, Angle JF, Prudente LA: Placement of transvenous pacemaker and ICD leads across total chronic occlusions. *Pacing Clin Electrophysiol* 2005; 28: 921–925
 - 19) Kar AK, Ghosh S, Majumdar A: Venous obstruction after permanent pacing. *Indian Heart J* 2005; 52: 431–433
 - 20) Koike R, Sasaki M, Kuroda K: Venous abnormalities associated with transvenous DDD pacing leads. *Jpn J Artif Organs* 1989; 18: 858–861 [in Japanese]
 - 21) Bracke F, Meijer A, Van Gelder B: Venous occlusion of the access vein in patients referred for lead extraction: influence of patient and lead characteristics. *Pacing Clin Electrophysiol* 2003; 26: 1649–1652
 - 22) Blair TP, Seibel J Jr, Goodreau J, et al: Surgical relief of thrombotic superior vena cava obstruction caused by endocardial pacing catheter. *Ann Thorac Surg* 1982; 33: 511–515
 - 23) Komatsu T, Nakamura S, Saitou E: Analysis of clinical profiles and efficacy of anti-platelet therapy to the patients with asymptomatic pulmonary embolism associated with following long-term transvenous pacing. *J Arrhythmia* 1998; 14: 391–396 [in Japanese]
 - 24) Kai H, Honma T, Imaizumi T: Superior vena cava syndrome caused by multiple pacing leads. *Heart* 2001; 86: 80
 - 25) Kaibara M: Thrombus formation and blood flow—Focusing on venous thrombus. *Japanese Society of Biorheology* 2004; 18: 82–90 [in Japanese]
 - 26) Bakir I, La Meir M, Degrieck I, et al: Contralateral replacement of pacemaker and leads following laser sheath extraction and concomitant stenting for superior vena cava syndrome. *Pacing Clin Electrophysiol* 2005; 28: 1131–1134
 - 27) Mazzetti H, Dussaut A, Tentori C, et al: Superior vena cava occlusion and/or syndrome related to pacemaker leads. *Am Heart J* 1993; 125: 831–837
 - 28) Francis CM, Starkey IR, Errington ML, et al: Venous stenting as treatment for pacemaker-induced superior vena cava syndrome. *Am Heart J* 1995; 129: 836–837
 - 29) Ito T, Tanouchi J, Kato J: Prethrombotic state due to hypercoagulability in patients with permanent transvenous pacemakers. *Angiology* 1997; 48: 901–906 [in Japanese]
 - 30) Abe Y, Kosakata M, Nogami K: The study of blood coagulation before and after transvenous pacemaker implantation. *Kokyu to Junkan* 1995; 43: 589–593 [in Japanese]
 - 31) Chan AW, Bhatt DL, Wilkoff BL, et al: Percutaneous treatment for pacemaker-associated superior vena cava syndrome. *Pacing Clin Electrophysiol* 2002; 25: 1628–1633
 - 32) Lindsay HS, Chennells PM, Perrins EJ: Successful treatment by balloon venoplasty and stent insertion of obstruction of the superior vena cava by an endocardial pacemaker lead. *Br Heart J* 1994; 71: 363–365
 - 33) Kinoshita M, Bando S, Sakabe K: The study of blood coagulation and the incidence of subclavian venous thrombosis after transvenous permanent pacemaker implantation. *J Arrhythmia* 2000; 16: 42–47 [in Japanese]